

## CASE REPORT

## A rare find of a maxillary third molar with five roots: a case report of an unusual morphology

OANA CELLA ANDREI<sup>1)</sup>, GABRIELA CIAVOI<sup>2)</sup>, MAGDALENA NATALIA DINA<sup>3)</sup>, LIANA TODOR<sup>2)</sup>, DANIELA IOANA TÄRLUNGEANU<sup>1)</sup>, RUXANDRA MÄRGÄRIT<sup>4)</sup>

<sup>1)</sup>Department of Prosthodontics, Faculty of Dentistry, Carol Davila University of Medicine and Pharmacy, Bucharest, Romania

<sup>2)</sup>Department of Dental Medicine, Faculty of Medicine and Pharmacy, University of Oradea, Romania

<sup>3)</sup>Department of Dental Techniques, Faculty of Midwifery and Nursing, Carol Davila University of Medicine and Pharmacy, Bucharest, Romania

<sup>4)</sup>Department of Restorative Odontotherapy, Faculty of Dentistry, Carol Davila University of Medicine and Pharmacy, Bucharest, Romania

### Abstract

Third molars are frequently absent or impacted; their unpredictable prevalence and morphology, with frequent anatomical variations, is a challenge for the practitioner. The number of roots of the upper third molars vary from one to five, but five roots upper third molars' cases are extremely rare. The case reported here is of a normotrophic male patient, with no significant general medical history, having extracted an impacted maxillary upper molar, with an unusual position and dimensions and five completely separated formed roots, orientated in diverse directions. It highlights the importance of using the correct surgical technique, without excessive pressure, for avoiding the fracture of the maxillary tuberosity, the displacement of the molar into the pterygopalatine fossa or the opening of the maxillary sinus, especially in the absence of good quality imagistic information like cone-beam computed tomography. The case presented in this paper is very rare and highlights the significance of anatomical knowledge, which is mandatory for managing these cases, to avoid trauma, accidents, and complications and to maintain an optimal time of extraction, since such variations occur, and the conventional radiographs do not offer enough data to clarify the diagnosis.

**Keywords:** upper third molar, morphology, five roots.

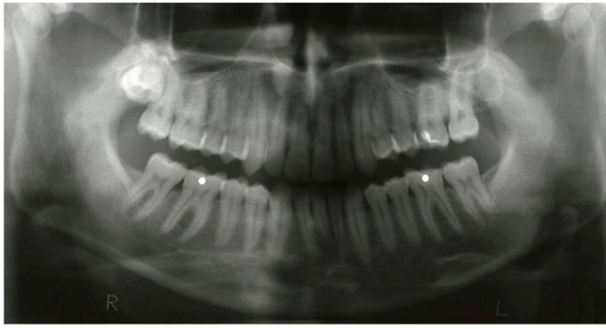### Introduction

In modern humans, third molars are frequently absent or impacted. However, their prevalence and morphology are important to all specialties of dentistry (surgical, restorative, prosthetic, orthodontic, endodontic); many studies collected data about their presence, shape, and gender differences. Phylogenetic tendencies and changes in diet are associated with fewer teeth, with populational variations regarding the geographic region, ethnic group, gender, maxillary or mandibular jaw, craniofacial morphology, craniofacial deformities, such as cleft lip and palate, or genetic factors involved in tooth agenesis [1-4]. A higher incidence of agenesis among the third molars, together with a general higher prevalence in maxilla compared to mandible, has been reported for tooth number 18 in several studies [4-6]. Reduction in the size of the jaw can be associated not only with impact, but also with anatomical variations of third molar's shape and dimensions; they also frequently present abnormalities in position; therefore, after multiple extractions in the posterior area of the jaws, those molars are difficult to differentiate from distomolars [7]. Still, the anatomy of the upper third molars has been described by some authors as unpredictable; from 150 such molars, they found that 15% had one root, 32% had two roots, 45% had three roots, and 7% had four roots [8]. In another

study, the number of roots in maxillary third molar teeth ranges from one to five; but the prevalence of accessory roots in maxillary molar teeth is low [9]. Guerisoli *et al.* found a great anatomical variability in their investigation of 155 maxillary third molars using diaphanization; they reported only one case of maxillary third molar having five independent roots and five root canals [10]. However, to the best of our knowledge, the occurrence and extraction of a five-rooted maxillary upper molar has only been mentioned, but not yet reported in the literature.

### Case presentation

A 32-year-old Romanian normotrophic male patient came to the dental office accusing pain in the right upper side of the mouth. The general medical history was not significant. At the clinical examination, no possible cause of such pain was detected on the right side of the oral cavity. A panoramic radiograph (Figure 1) revealed the presence of the completely impacted right upper third molar (tooth number 1.8), in an unusual position, with the occlusal face of the crown buccally positioned, and with almost no visibility of the roots. The patient asked for the removal of the tooth and denied the use of a cone-beam computed tomography (CBCT) due to financial reasons.



**Figure 1 – Panoramic radiograph showing the right upper third molar; the roots are barely visible.**

Local infiltration of an anesthetic solution was performed (4% Articaine with Adrenaline 1:200 000 as a vasoconstrictor). A full-thickness triangular flap was raised to gain adequate access, using a horizontal incision along the tuberosity and a vertical releasing incision from the buccal vestibule to the mesial interdental papillae of the second molar. A periosteal elevator was used to elevate the flap, exposing a part of the crown of the impacted third molar and the vestibular cortical bone. The tooth presented a rare and unusual angulation, being horizontally placed, almost perpendicular to the second molar, with the crown facing the cheek. The highest point of the third molar was below the cervical line of the second molar. The bone removal was performed using a straight handpiece and a round surgical bur, irrigated with saline solution. Using elevators to luxate the tooth and avoiding excessive pressure, the surrounding alveolar bone was expanded to allow an unimpeded pathway for tooth removal. Care was taken to avoid fracturing the maxillary tuberosity, displacing the molar into the pterygopalatine fossa or opening the maxillary sinus. After tooth extraction and curettage of the follicular socket, the flap was brought to its original position and the wound was closed with 3-0 silk sutures.

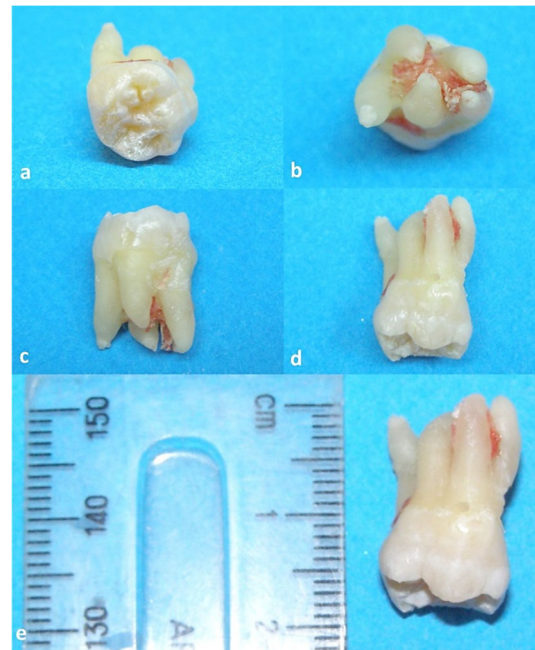
The extracted molar was an intact (Figure 2a), multi-rooted tooth, having five completely separated formed roots (Figure 2b), each of them rather robust, having curvatures and being orientated in diverse directions (Figure 2, c and d); also, its dimensions were unusually large for an upper third molar, its length being approximately 19 mm and the mesiodistal length of the crown was approximately 11 mm (Figure 2e). Small bone parts situated between the roots were trapped and removed with the tooth.

Postoperative medication instructions included 600 mg Ibuprofen for 3–5 days and Amoxicillin 1000 mg, 1/12 h, for seven days. The major complaints referred to by the patient were inflammation and some discomfort related to the chewing ability, with no other complications.

## ☒ Discussions

Upper third molar's extraction can be considered a routine procedure in dental offices. However, impacted molars create difficulties related to lack of visibility, fragility of the tuberosity, proximity of the maxillary sinus. The difficulty of extraction always depends on root morphology, number and divergence; also, it is increased when the roots are completely formed. In our case, both the number, shape and orientation of the roots but also the unusual dimension

of the molar created difficulties during surgical procedure; that could be partially avoided with the aid of a CBCT investigation, since the panoramic radiography failed to offer the necessary information.



**Figure 2 – The upper right third molar: (a) Occlusal view; (b) Apical view of the five apices; (c) The five completely separated formed roots; (d) Curvature of the roots orientated in various directions; (e) 19 mm root length.**

The most common variants of the maxillary third molars are considered to be the single, double and three rooted, either separate or fused; a study on a Thai population found that half (51%) of the maxillary third molars had three separate roots; the other half had fused or conical roots [11]. In a Romanian population, Todor *et al.* found two, three or four roots and 15 versions concerning their number and orientation; half of molars in the study had a single root [12]. Out of the 200 maxillary third molars extracted and included in a study on an Indian population, 56% had single/fused roots, 24% had two separate roots, 13% had three separate roots and 7% had four separate roots; the authors concluded that the maxillary third molar has the most variation in tooth root morphology [13]; still, they did not find any of such teeth having five formed, separate roots. In a study conducted on a Jordanian subpopulation, authors found that the majority (74.2%) of maxillary molars had three roots and that roots fusion was found in 70.1% of maxillary molars [14]. Complete separation of all three roots was observed by Pécora *et al.* on only 18.8% of the third maxillary molars [15]. Other authors found that, in a Turkish population, 35.5% of the maxillary third molars were single-rooted [16]. A case of a male patient presenting four separate roots with four distinct canals in a maxillary third molar was presented as a rare variation [17].

In a study aiming to assess root canal morphology of third molars of a Mexican population, authors used CBCT images and found that the upper third molars have a greater frequency of fused (57.9%) and cone-shaped roots (27.2%) than of separate roots. Their results showed that most cases of molars with separate roots had distal curvature towards

the middle third of the mesiobuccal root (35%), and that 28.8% of their distobuccal roots were more typically straight along their longitudinal axis. In 18.7% of cases, the palatal root was aligned with the longitudinal axis, while in other 18.7% of cases it was aligned with the palatal side, in the latter cases being longer ( $11.7 \pm 1.7$  mm) and having a greater diameter in each of its three sections (cervical  $4.8 \pm 0.9$  mm, middle  $4 \pm 1.1$  mm, and apical  $2.8 \pm 0.9$  mm) [18]. In our case, the mesiobuccal root was straight and divergent, the mesiopalatal root was curved distally, the palatal root was curved only in the apical third, the distobuccal root was curved only in the apical third and the distopalatal root was slightly curved from the middle. Four of the roots were comparable in dimensions; the mesiopalatal root was the shortest and the palatal root was slightly longer than the others. The whole length of the tooth was approximately 19 mm and the mesiodistal length of the crown was approximately 11 mm.

In a review that aimed to analyze and compare the accuracy of panoramic imaging to CBCT in evaluating the relationship between posterior maxillary tooth roots and the maxillary sinus, the authors found that a panoramic image is sufficient only when the roots are distanced from the sinus; on the contrary, in cases where the roots are either laterally or medially projecting over the sinus, they found that panoramic images generally misinterpret this position, so a CBCT will properly assess oral surgery risk in these cases [19]. Our case could surely benefit from three dimensional images offered by CBCT, since conventional radiography technique failed in clarifying either the roots number nor their anatomy; still, the case presented here is extremely rare, the surgical technique would not change and the decision to use CBCT as a routine procedure must be well balanced, for several reasons including costs and radiation dose. Extraction of third maxillary molars should be made using atraumatic principles to avoid fracturing the maxillary tuberosity; studies show that a tooth with large divergent roots or an abnormal number of roots is a risk factor for such accidents [20]. In our case, using the right technique and avoiding excessive pressure were a key factor in preserving the tuberosity and minimizing the postoperative pain and complications.

## ☒ Conclusions

Extraction of third molars can be a routine procedure in dental practice; however, their unpredictable morphological variations can make the procedure more difficult and riskier. A CBCT can be helpful in cases where the conventional radiographies do not offer enough data to clarify the diagnosis. The case presented in this paper is very rare and highlights the significance of anatomical knowledge, which is mandatory for managing these cases, to avoid trauma or accidents like root or tuberosity fracture, to avoid complications and to maintain an optimal time of extraction.

## Conflict of interests

The authors declare that there is no conflict of interests.

## Authors' contribution

Oana Cella Andrei and Gabriela Ciavoi equally contributed to this article.

## References

- [1] Moghadam MG, Etemadi F, Akbari N. The relationship between agenesis of third molar and craniofacial morphology in orthodontic patients. *J Int Soc Prev Community Dent*, 2018, 8(4): 304–308. [https://doi.org/10.4103/jispcd.JISPCD\\_110\\_18](https://doi.org/10.4103/jispcd.JISPCD_110_18) PMID: 30123761 PMID: PMC6071352
- [2] Fernandez CCA, Pereira CVCA, Luiz RR, Faraco IM Jr, Marazita ML, Arnaudo M, de Carvalho FM, Poletta FE, Mereb JC, Castilla EE, Orioli IM, de Castro Costa M, Vieira AR. Third molar agenesis as a potential marker for craniofacial deformities. *Arch Oral Biol*, 2018, 88:19–23. <https://doi.org/10.1016/j.archoralbio.2018.01.010> PMID: 29358133 PMID: PMC6034603
- [3] Scheiwiller M, Oeschger ES, Gkantidis N. Third molar agenesis in modern humans with and without agenesis of other teeth. *PeerJ*, 2020, 8:e10367. <https://doi.org/10.7717/peerj.10367> PMID: 33240669 PMID: PMC7678444
- [4] Sujon MK, Alam MK, Rahman SA. Prevalence of third molar agenesis: associated dental anomalies in non-syndromic 5923 patients. *PLoS One*, 2016, 11(8):e0162070. <https://doi.org/10.1371/journal.pone.0162070> PMID: 27580050 PMID: PMC5006966
- [5] Singh N, Chaudhari S, Chaudhari R, Nagare S, Kulkarni A, Parkarwar P. A radiographic survey of agenesis of the third molar: a panoramic study. *J Forensic Dent Sci*, 2017, 9(3):130–134. [https://doi.org/10.4103/jfo.jfds\\_59\\_16](https://doi.org/10.4103/jfo.jfds_59_16) PMID: 29657489 PMID: PMC5887635
- [6] Kaur B, Sheik S, Pallagatti S. Radiographic assessment of agenesis of third molars and para-radicular third molar radiolucencies in population of age group 18–25 years old: a radiographic survey. *Arch Oral Res*, 2012, 8(1):13–18. <https://pesquisa.bvsalud.org/portal/resource/pt/lil-698596>
- [7] Dăguci C, Burlibaşa M, Mărgărit R, Tănăsescu LA, Dăguci L, Bătăiosu M, Scricieiu M, Andrei OC. Maxillary distomolars: case reports, differential diagnosis and literature review. *Rom J Morphol Embryol*, 2017, 58(4):1617–1622. PMID: 29556665
- [8] Sidow SJ, West LA, Liewehr FR, Loushine RJ. Root canal morphology of human maxillary and mandibular third molars. *J Endod*, 2000, 26(11):675–678. <https://doi.org/10.1097/00004770-200011000-00011> PMID: 11469300
- [9] Ahmed HMA, Abbott PV. Accessory roots in maxillary molar teeth: a review and endodontic considerations. *Aust Dent J*, 2012, 57(2):123–131; quiz 248. <https://doi.org/10.1111/j.1834-7819.2012.01678.x> PMID: 22624750
- [10] Guerisoli DM, de Souza RA, de Sousa Neto MD, Silva RG, Pécora JD. External and internal anatomy of third molars. *Braz Dent J*, 1998, 9(2):91–94. PMID: 10219121
- [11] Alavi AM, Opasanon A, Ng YL, Gulabivala K. Root and canal morphology of Thai maxillary molars. *Int Endod J*, 2002, 35(5):478–485. <https://doi.org/10.1046/j.1365-2591.2002.00511.x> PMID: 12059921
- [12] Todor L, Matei RI, Muşiu G, Porumb A, Ciavoi G, Cuc EA, Ţeţu A, Domocoş D, Scrobotă I, Todor SA, Coroi MC. Morphological study of upper wisdom tooth. *Rom J Morphol Embryol*, 2018, 59(3):873–877. PMID: 30534828
- [13] Shivpuri A, Mitra R, Hema R. A retrospective analysis of the root morphology of maxillary and mandibular third molars. *Acta Sci Dent Sci*, 2018, 2(5):32–34. <https://actascientific.com/ASDS-2-5.php>
- [14] Ahmad IA, Azzeh MM, Zwiri AM, Abu Haija MAS, Diab MM. Root and root canal morphology of third molars in a Jordanian subpopulation. *Saudi Endod J*, 2016, 6(3):113–121. <https://doi.org/10.4103/1658-5984.189350> [https://journals.lww.com/senj/Fulltext/2016/06030/Root\\_and\\_root\\_canal\\_morphology\\_of\\_third\\_molars\\_in.1.aspx](https://journals.lww.com/senj/Fulltext/2016/06030/Root_and_root_canal_morphology_of_third_molars_in.1.aspx)
- [15] Pécora JD, Woelfel JB, Sousa Neto MD. Morphologic study of the maxillary molars. 1. External anatomy. *Braz Dent J*, 1991, 2(1):45–50. PMID: 1819354
- [16] Sert S, Sahinkesen G, Topçu FT, Eroğlu SE, Oktay EA. Root canal configurations of third molar teeth. A comparison with first and second molars in the Turkish population. *Aust Endod J*, 2011, 37(3):109–117. <https://doi.org/10.1111/j.1747-4477.2010.00254.x> PMID: 22117717
- [17] Venumuddala V, Moturi S, Satish, Reddy ES. Endodontic management in a rare variant of maxillary third molar with two palatal roots and root canals: a case report. *MOJ Anat Physiol*, 2020, 7(4):121–124. <https://doi.org/10.15406/mojap.2020.07.00301> <https://medcraveonline.com/MOJAP/endodontic-management-in-a-rare-variant-of-maxillary-third-molar-with-two-palatal-roots-and-root-canals-a-case-report.html>

- [18] Olguín MTG, Amarillas EED. Root canal morphology of third molars. *Rev ADM*, 2017, 74(1):17–24. <https://www.medigraphic.com/cgi-bin/new/resumenI.cgi?IDARTICULO=70658>
- [19] Kirkham-Ali K, La M, Sher J, Sholapurkar A. Comparison of cone-beam computed tomography and panoramic imaging in assessing the relationship between posterior maxillary tooth roots and the maxillary sinus: a systematic review. *J Investig Clin Dent*, 2019, 10(3):e12402. <https://doi.org/10.1111/jicd.12402> PMID: 30693662
- [20] Thirumurugan K, Munzanoor RR, Prasad GA, Sankar K. Maxillary tuberosity fracture and subconjunctival hemorrhage following extraction of maxillary third molar. *J Nat Sci Biol Med*, 2013, 4(1):242–245. <https://doi.org/10.4103/0976-9668.107317> PMID: 23633874 PMCID: PMC3633290

**Corresponding authors**

Liana Todor, Associate Professor, DMD, PhD, Department of Dental Medicine, Faculty of Medicine and Pharmacy, University of Oradea, 10 1 December Square, 410068 Oradea, Bihor County, Romania; Phone +40723–517 100, e-mail: [liana.todor@gmail.com](mailto:liana.todor@gmail.com)

Daniela Ioana Tărlungeanu, Assistant Professor, DMD, PhD, Department of Prosthodontics, Faculty of Dentistry, Carol Davila University of Medicine and Pharmacy, 37 Dionisie Lupu Street, Sector 2, 020021 Bucharest, Romania; Phone +40723–862 665, e-mail: [ioanatarlungeanu@gmail.com](mailto:ioanatarlungeanu@gmail.com)

*Received: January 29, 2023*

*Accepted: May 12, 2023*