Rom J Morphol Embryol 2024, 65(2):257–265 ISSN (print) 1220–0522, ISSN (online) 2066–8279 doi: 10.47162/RJME.65.2.12

ORIGINAL PAPER

RJME
Romanian Journal of Morphology & Embryology
http://www.rjme.ro/

Implementing an integrated molecular classification for gastric cancer from endoscopic biopsies using on-slide tests

SIMONA COSTACHE[1,2], ADELINA BALTAN[1,2], SOFIA DIAZ MCLYNN[2], MATTIA PEGORARO[2], REBECCA DE HAVILLAND[2], MATTHEW PORTER[2], ANA LERGA[2], TERESA THOMAS[2], ALINA ELENA CHEFANI[2], SARAH WEDDEN[3], KIM BILLINGHAM[4], CORRADO D'ARRIGO[2]

[1] *PhD Student, Doctoral School, Carol Davila University of Medicine and Pharmacy, Bucharest, Romania*

[2] *Department of Histopathology, Poundbury Cancer Institute, Dorchester, Dorset, UK*

[3] *Cancer Diagnostic Quality Assurance Services (CADQAS), Dorchester, Dorset, UK*

[4] *Department of Histopathology, Great Western Hospital, Marlborough Road, Swindon, Wiltshire, UK*

Abstract

The availability of more effective biological therapy can improve outcomes of gastric cancer (GC), but most patients do not have access to personalized treatment. GC molecular classification helps identify patients suitable for specific therapies and provides useful prognostic information. To date, only a small number of patients have access to molecular classification. We proposed a working molecular classification that can be delivered using on-slide tests available in most histopathology laboratories. We used eight on-slide tests [*in situ* hybridization (ISH) for Epstein–Barr virus-encoded small ribonucleic acid (EBER) and immunohistochemistry (IHC) for MutL homolog 1 (MLH1), PMS1 homolog 2 (PMS2), MutS homolog 2 (MSH2), MutS homolog 6 (MSH6), E-cadherin, *β*-catenin and p53] to classify GC into one of six categories: GC associated with Epstein–Barr virus (GC-EBV), GC mismatch repair deficient (GC-dMMR), GC with epithelial–mesenchymal transition (GC-EMT), GC with chromosomal instability (GC-CIN), GC genomically stable (GC-GS) and GC not otherwise specified (GC-NOS)/indeterminate. The classification has provision also for current and future on-slide companion diagnostic (CDx) tests necessary to select specific biological therapies and, as proof of principle, in this study we used three CDx tests currently required for the management of GC [human epidermal growth factor receptor 2 (Her2), programmed cell death-ligand 1 (PD-L1) 22C3 and Claudin18.2 (CLDN18.2)]. This paper describes the necessary tissue pathways and laboratory workflow and assesses the feasibility of using this classification prospectively on small endoscopic biopsies of gastric and gastroesophageal junction adenocarcinoma. This work demonstrates that such molecular classification can be implemented in the context of a histopathology diagnostic routine with little impact on turnaround times and laboratory capacity. The widespread adoption of a molecular classification for GC will help refine prognosis and guide the choice of more appropriate biological therapy for these patients.

Keywords: gastric cancer, molecular classification, p53, Claudin18.2, PD-L1, Her2.

Introduction

Cancer of the stomach or of the gastroesophageal junction (GEJ) (here referred collectively as gastric cancer or GC) remains a major cause of morbidity and mortality [1]. The outcome for these patients can be improved with more effective biological treatment [2]. For this, GC needs to be subdivided into groups enriched for responders for each specific therapy, typically using predictive biomarkers. Better prognostic and predictive data is provided by molecular classification for GC [3–6], as opposed to the traditional taxonomic classification [7].

Comprehensive multi-omnics studies have identified molecular subtypes of GC linked to prognosis and response to treatment. Based on the assessment of two different patient populations, *The Cancer Genome Atlas Consortium* (TCGA) and *Asian Cancer Research Group* (ACRG) proposed different molecular classifications that have some overlaps [4–6]. Unfortunately, molecular classifications remain available only to a minority of GC patients because it requires comprehensive high-cost genomics and transcriptomics, for which there is a conspicuous lack of capacity worldwide.

Subsequently, several groups tried to deliver molecular classification based on small numbers of markers, however they used different nomenclature and often different tests or different interpretative algorithms [8–11]. Therefore, there was a need for harmonization of the terminology, test repertoire and interpretation.

Recently, we proposed an inclusive working classification based on on-slide tests that can be delivered by histopathology using existing resources [12]. The classification includes determination of Laurén's subtypes using Hematoxylin–Eosin (HE)-stained sections and the status of eight on-slide biomarkers using *in situ* hybridization (ISH) and immunohistochemistry (IHC) [13]. We used a cohort of GC resection cases to assess the feasibility of delivering the classification [14] of GC into one of six categories: GC associated with Epstein–Barr virus (GC-EBV), GC mismatch repair deficient (GC-dMMR), GC with epithelial–

This is an open-access article distributed under the terms of a Creative Commons Attribution-NonCommercial-ShareAlike 4.0 International Public License, which permits unrestricted use, adaptation, distribution and reproduction in any medium, non-commercially, provided the new creations are licensed under identical terms as the original work and the original work is properly cited.

mesenchymal transition (GC-EMT), GC with chromosomal instability (GC-CIN), GC genomically stable (GC-GS) and GC not otherwise specified (GC-NOS)/indeterminate. We also assessed the feasibility of integrating into this classification a number of predictive on-slide companion diagnostic (CDx) tests required for the management of GC patients. These included human epidermal growth factor receptor 2 (Her2), programmed cell death-ligand 1 (PD-L1) and Claudin18.2 (CLDN18.2).

Our previous study was performed on tissue from surgical excisions [14]. For a significant proportion of GC patients, the only tissue available are endoscopic biopsies. These present challenges such as identification of invasive component *versus* high-grade (HG) dysplasia, limited amounts of tissue and ability to assess heterogeneity. In addition, endoscopic biopsy is often a superficial mucosal sample, with different tumor microenvironment than carcinoma in deeper portions of the gastric or esophageal wall. In an attempt to mimic the small amount of biopsy tissue, our previous study used tissue microarrays (TMAs), but we are mindful that the TMA cores were chosen from the most representative areas of the tumor and did not contain normal mucosa.

Aim

In this present study, we therefore wanted to understand if this classification can be delivered using endoscopic biopsies, with all the limitations intrinsic to these samples. This paper describes the required tissue pathways and laboratory workflows and assessing the feasibility using a proposed a molecular classification prospectively on small endoscopic biopsy of GC.

Materials and Methods

Study group

We used two different cohorts of patients with GC diagnosed on endoscopic biopsy. The retrospective cohort included 24 consecutive archival cases of gastric or GEJ adenocarcinoma from which we had formalin-fixed paraffin-embedded (FFPE) blocks with sufficient tissue to allow for new sections to be cut. The prospective cohort comprised 30 consecutive patients with gastric or GEJ adenocarcinoma confirmed by endoscopic biopsy received in the diagnostic routine between May and November 2023.

Laboratory work

For each case, 16 sections from FFPE tissue were cut at 3 μm onto TOMO® slides. Each case was stained with an HE and a panel of on-slide tests for the molecular classification that comprised of ISH for Epstein–Barr virus-encoded small ribonucleic acid (EBER) and IHC for MutL homolog 1 (MLH1), PMS1 homolog 2 (PMS2), MutS homolog 2 (MSH2), MutS homolog 6 (MSH6), E-cadherin, β-catenin and p53. Additional CDx tests included IHC for PD-L1 using the 22C3 clone, CLDN18.2 and Her2 and, where necessary, Her2 dual-color dual-hapten brightfield *in situ* hybridization (DDISH). All tests were performed on Ventana Benchmark instruments using reagents and protocols described in the literature [14].

Slide assessment

Stained slides were digitized using a P1000 scanner (3DHistech, Hungary), with a primary magnification of ×36. Digital slides were stored in SlideCenter v3.1 (3DHistech, Hungary) and studied using CaseViewer v2.6 (3DHistech, Hungary) on monitors with 4K resolution. The ease in which invasive carcinoma can be distinguished from area of HG dysplasia was qualified for each case using a three-tier system: no difficulties, mild and major difficulties in interpretation using an HE-stained section.

Each case was annotated for presence of sufficient diagnostic material and turnaround time (TAT). Discordant cases were reviewed in conference and a consensus diagnosis reached. A time and motion study was undertaken to provide an indication of the additional resources needed to assess all the biomarkers and provide a final classification. This was done by measuring the time needed by a pathologist to examine a case that had been previously diagnosed as carcinoma and for which all the additional biomarkers were prepared and digitized.

Molecular algorithm

Each test was interpreted independently by two pathologists (SC & CD) and cases were assigned to a molecular diagnostic category and Laurén subtype using algorithms described previously [14] and summarized in Figure 1.

Briefly, the tests were examined hierarchically starting with ISH for EBER. If this was positive in the tumor cells (TCs), the case was classified as GC-EBV; if negative, the next set of tests for mismatch repair (MMR) was assessed. This included four IHC markers (MLH1, PMS2, MSH2 and MSH6). If carcinoma lacked nuclear staining for any of these markers, the tumor was classified as GC-dMMR; if the tumor expressed all four markers, we examined the next set of tests (IHC for E-cadherin and β-catenin). Carcinoma that lacked membrane expression or had aberrant expression (cytoplasmic or nuclear) for one or both markers was classified as GC-EMT; if the carcinoma had preserved membrane expression for both markers, we proceeded to examine the expression pattern of p53 by IHC. The expression of p53 was defined as wild type (p53wt) or mutant (p53m), according to Köbel *et al.* [15]. Briefly, mutant patterns include strong and diffuse nuclear staining in ≥80% of TCs, cytoplasmic staining and diffuse lack of staining. Wild-type patterns were confined to nuclear staining of variable intensities and affecting <80% of TCs. Carcinoma with p53m was classified as GC-CIN, whereas carcinoma with p53wt as GC-GS. The hierarchical system allowed classification even when some of the downstream biomarkers could not be interpreted, but the carcinoma was already assigned to a molecular subgroup, otherwise the case was set in the GC-NOS category.

Interpretation of oncology biomarkers

Interpretation of the CDx biomarkers followed published guidelines. In particular, PD-L1 was assessed using the combined positive score (CPS) with a positivity threshold of 5; CLDN18.2 was regarded positive if there was membrane staining of strong or moderate staining intensity in ≥75% of TCs; Her2 was considered positive if IHC score was 3+ or 2+ and DDISH amplified, according to the latest *American Society of Clinical Oncology/College of American Pathologists* (ASCO/CAP) guidelines [16–23].

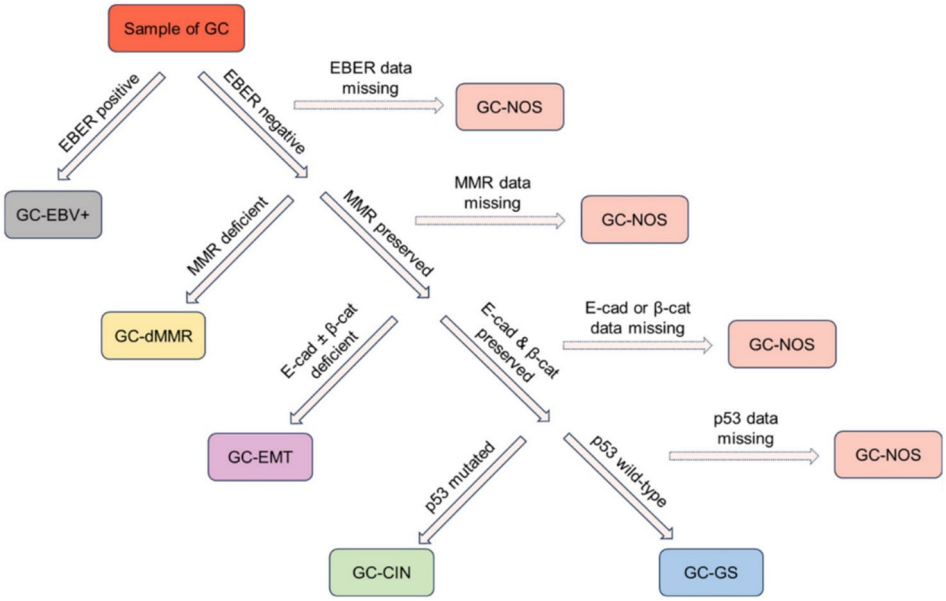

Figure 1 – ***Interpretation algorithm for the hierarchical classification. β-cat: Beta-catenin; E-cad: E-cadherin; EBER: Epstein–Barr virus-encoded small ribonucleic acid; GC: Gastric cancer; GC-CIN: GC with chromosomal instability; GC-dMMR: GC mismatch repair deficient; GC-EBV: GC associated with Epstein–Barr virus; GC-EMT: GC with epithelial–mesenchymal transition; GC-GS: GC genomically stable; GC-NOS: GC not otherwise specified; MMR: Mismatch repair.***

Results

Our study included 11 female (F) and 43 male (M) patients, with a mean age of 72.9 years. Table 1 provides detailed information of age and gender of the patients in each of the two endoscopic biopsy cohorts. All the tests performed in this study were interpretable, except for a single case where the CLDN18.2 slide had no diagnostic material (tumor tissue exhausted). Details of the molecular subgroups in all patients as well as in each cohort (retrospective and prospective) are in Table 2. An example of a case is provided in Figure 2 (A–L). Overall, there were no GC-EBV, 1/54 (2%) cases of GC-dMMR, 10/54 (19%) cases of GC-EMT, 24/54 (44%) cases of GC-CIN, 13/54 (24%) cases of GC-GS and 6/54 (11%) cases of GC-NOS. The six cases of GC-NOS were all in the prospective cohort and were due to failure to order all the additional tests for molecular classification, although some biomarkers (PD-L1 and Her2) were performed. Laurén intestinal type was the predominant subtype in all categories except GC-EMT, were the cases were divided equally between diffuse and intestinal types. No loss of E-cadherin and/or *β*-catenin was found in the GC-dMMR; there were no p53m cases in the GC-dMMR and four cases were in the GC-EMT category (three p53 overexpression and one p53 loss). In the GC-CIN category, 18 cases had p53 overexpression, five cases had p53 loss and one case had both cytoplasmic and overexpression. A detailed immunological profile for each of GC categories is in Table 3.

In Figure 3 (A–I), there are examples of the various p53 IHC patterns.

The proportion of Her2-positive cases was 9/54 (17%), with the majority in GC-CIN and GC-GS (each 4/9) and a single case in GC-EMT. There were 37/54 (69%) PD-L1-positive cases, and these were predominantly in GC-CIN (18/37 or 49%) and GC-GS (7/37 or 19%). We also found 20/47 cases positive for CLDN18.2, most of which were within GC-CIN (12/20 or 60%), with 4/20 (20%) in both GC-EMT and GC-GS.

Table 1 – ***Gender and age of patients in the cohorts studied***

	Retrospective (*n*=24)	Prospective (*n*=30)	Overall (*n*=54)
Male [%]	75	83	79
Female [%]	25	17	21
Median age [years]	76.1	69.6	72.85

n: No. of cases.

Table 2 – ***Proportion of each molecular subgroup in the retrospective, prospective and combined cohorts***

	GC-EBV	GC-dMMR	GC-EMT	GC-CIN	GC-GS	GC-NOS
Retrospective study (*n*=24)	0%	4% (*n*=1)	33% (*n*=8)	25% (*n*=6)	38% (*n*=9)	0%
Her2(+)	–	0%	13% (*n*=1)	17% (*n*=1)	22% (*n*=2)	–
PD-L1(+)	–	100% (*n*=1)	50% (*n*=4)	33% (*n*=2)	33% (*n*=3)	–
CLDN18.2(+)	–	0%	38% (*n*=3)	17% (*n*=1)	44% (*n*=4)	–
Prospective study (*n*=30)	0%	0%	7% (*n*=2)	60% (*n*=18)	13% (*n*=4)	20% (*n*=6)
Her2(+)	–	–	0%	17% (*n*=3)	50% (*n*=2)	0%
PD-L1(+)	–	–	100% (*n*=2)	89% (*n*=16)	100% (*n*=4)	83% (*n*=5)
CLDN18.2(+)	–	–	50% (*n*=1)	61% (*n*=11)	0%	–
Combined (*n*=54)	0%	2% (*n*=1)	19% (*n*=10)	44% (*n*=24)	24% (*n*=13)	11% (*n*=6)
Her2(+)	–	0%	10% (*n*=1)	17% (*n*=4)	31% (*n*=4)	0%
PD-L1(+)	–	100% (*n*=1)	60% (*n*=6)	75% (*n*=18)	54% (*n*=7)	83% (*n*=5)
CLDN18.2(+)	–	0%	40% (*n*=4)	50% (*n*=12)	31% (*n*=4)	–

CLDN18.2: Claudin18.2; GC: Gastric cancer; GC-CIN: GC with chromosomal instability; GC-dMMR: GC mismatch repair deficient; GC-EBV: GC associated with Epstein–Barr virus; GC-EMT: GC with epithelial–mesenchymal transition; GC-GS: GC genomically stable; GC-NOS: GC not otherwise specified; Her2: Human epidermal growth factor receptor 2; *n*: No. of cases; PD-L1: Programmed cell death-ligand 1. The proportion of companion diagnostic (CDx) biomarkers was calculated as percentage of each molecular subtype.

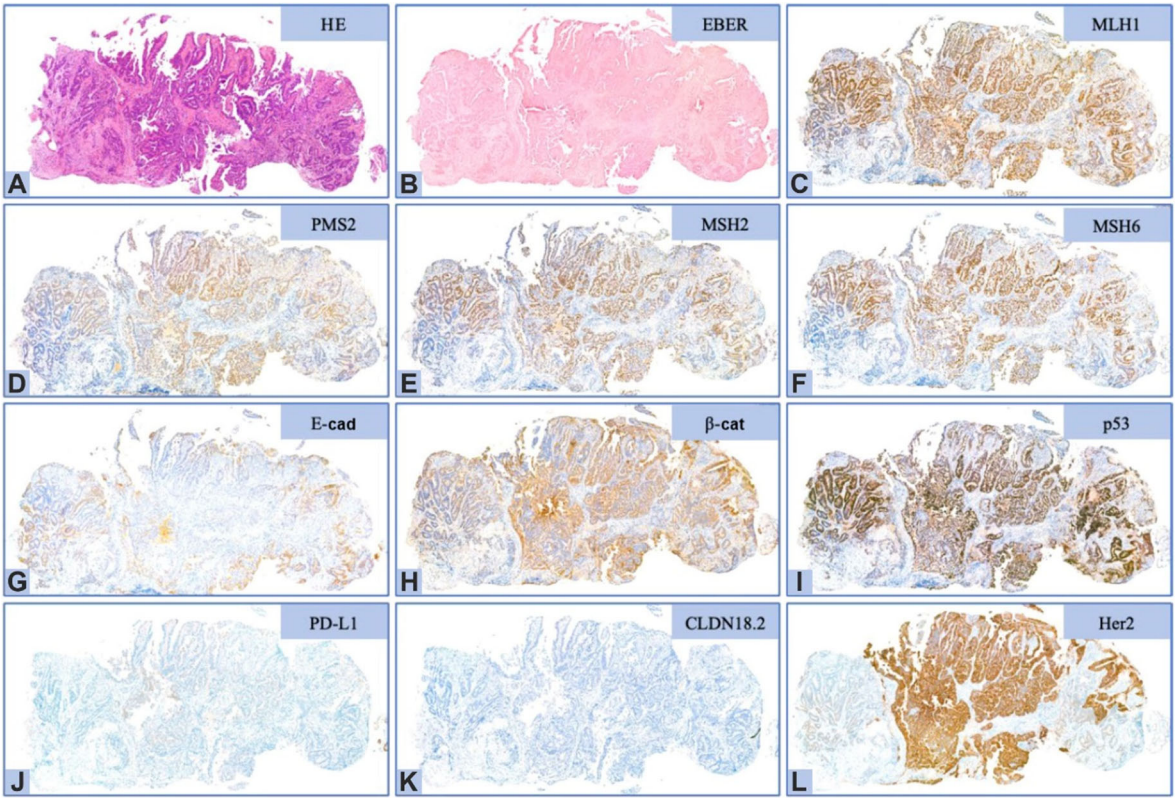

Figure 2 – ***Example of assessment of biomarkers for molecular classification. Case No. 2 of retrospective cohort. Final diagnosis: GC-CIN, Laurén intestinal type. (A) HE shows Laurén intestinal type; (B) ISH for EBER is negative; (C–F) IHC for MMR enzymes (MLH1, PMS2, MSH2 and MSH6) shows nuclear preserved expression; (G and H) IHC for E-cad and β-cat show preserved membrane staining; (I) IHC for p53 shows strong and diffuse nuclei staining in ≥80% of TCs (p53m). Further CDx biomarkers: (J) PD-L1 is negative (CPS<5); (K) CLDN18.2 is negative (no membrane staining); and (L) Her2 is positive (IHC score 3+). All microphotographs were taken at digital magnification of ×3.5. β-cat: Beta-catenin; CDx: Companion diagnostic; CLDN18.2: Claudin18.2; CPS: Combined positive score; E-cad: E-cadherin; EBER: Epstein–Barr virus-encoded small ribonucleic acid; GC-CIN: GC with chromosomal instability; HE: Hematoxylin–Eosin; Her2: Human epidermal growth factor receptor 2; IHC: Immunohistochemistry; ISH: In situ hybridization; MLH1: MutL homolog 1; MSH2: MutS homolog 2; MSH6: MutS homolog 6; MMR: Mismatch repair; p53m: p53 mutated; PD-L1: Programmed cell death-ligand 1; PMS2: PMS1 homolog 2; TC: Tumor cell.***

Table 3 – ***Detailed immunological profile for each GC molecular subgroup in the combined cohort***

	GC-EBV	GC-dMMR	GC-EMT	GC-CIN	GC-GS	GC-NOS
Combined study (*n*=54)	0%	2% (1/54)	19% (10/54)	44% (24/54)	24% (13/54)	11% (6/54)
EBV$^{(+)}$	n/a	0%	0%	0%	0%	n/a
EBV$^{(-)}$	n/a	100% (1/1)	100% (10/10)	100% (24/24)	100% (13/13)	n/a
dMMR	n/a	100% (1/1)	0%	0%	0%	n/a
pMMR	n/a	0%	100% (10/10)	100% (24/24)	100% (13/13)	n/a
E-cad$^{(+)}$	n/a	100% (1/1)	50% (5/10)	100% (24/24)	100% (13/13)	n/a
E-cad$^{(-)}$	n/a	0%	50% (5/10)	0%	0%	n/a
β-cat$^{(+)}$	n/a	100% (1/1)	0%	100% (24/24)	100% (13/13)	n/a
β-cat$^{(-)}$	n/a	0%	100% (10/10)	0%	0%	n/a
p53m	n/a	0%	40% (4/10)	100% (24/24)	0%	n/a
p53wt	n/a	100% (1/1)	60% (6/10)	0%	100% (13/13)	n/a
Her2$^{(+)}$	n/a	0%	10% (1/10)	17% (4/24)	31% (4/13)	0%
Her2$^{(-)}$	n/a	100% (1/1)	90% (9/10)	83% (20/24)	69% (9/13)	100% (6/6)
PD-L1$^{(+)}$	n/a	100% (1/1)	60% (6/10)	75% (18/24)	54% (7/13)	83% (5/6)
PD-L1$^{(-)}$	n/a	0%	40% (4/10)	25% (6/24)	46% (6/13)	17% (1/6)
CLDN18.2$^{(+)}$	n/a	0%	40% (4/10)	50% (12/24)	31% (4/13)	n/a
CLDN18.2$^{(-)}$	n/a	100% (1/1)	60% (6/10)	50% (12/24)	69% (9/13)	n/a

CDx: Companion diagnostic; dMMR: Deficient MMR; GC: Gastric cancer; GC-CIN: GC with chromosomal instability; GC-dMMR: GC mismatch repair deficient; GC-EBV: GC associated with Epstein–Barr virus; GC-EMT: GC with epithelial–mesenchymal transition; GC-GS: GC genomically stable; GC-NOS: GC not otherwise specified; MMR: Mismatch repair; *n*: No. of cases; n/a: Not applicable; p53m: p53 mutated; p53wt: p53 wild-type; pMMR: Proficient MMR. The proportion of CDx biomarkers was calculated as percentage of each molecular subtype. EBV$^{(+)/(-)}$: Presence/absence of Epstein–Barr virus; E-cad$^{(+)}$/*β*-cat$^{(+)}$: Presence of membrane staining for E-cadherin/*β*-catenin; E-cad$^{(-)}$/*β*-cat$^{(-)}$: Loss of membrane staining or aberrant cytoplasmic or nuclear staining for E-cadherin/*β*-catenin; Her2$^{(+)/(-)}$: Human epidermal growth factor receptor 2 positive/negative; PD-L1$^{(+)/(-)}$: Programmed cell death-ligand 1 positive/negative; CLDN18.2$^{(+)/(-)}$: Claudin18.2 positive/negative.

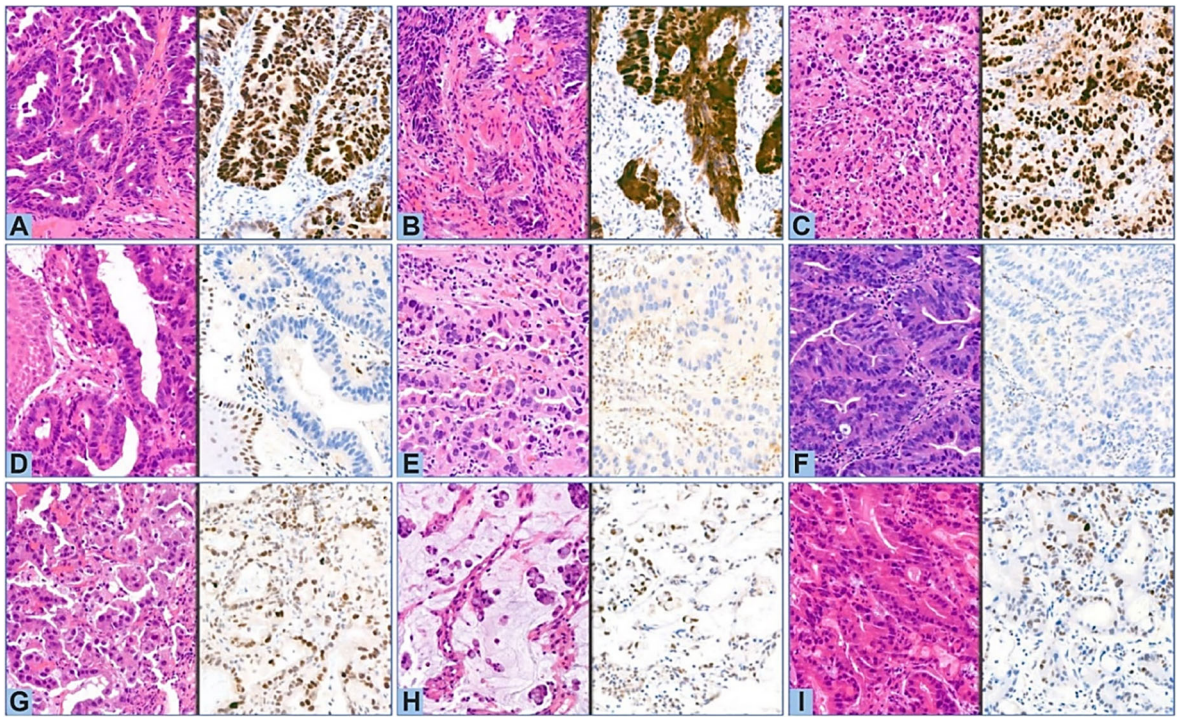

Figure 3 – ***Patterns of p53 IHC staining. Paired HE and p53 IHC. Top row (A–C): IHC p53m overexpressed pattern (strong and diffuse nuclear staining in ≥80% TCs). Middle row (D–F): IHC p53m null pattern (no staining in TCs). Bottom row (G–I): p53wt pattern (nuclear staining of variable intensity in ≥1% TCs). All microphotographs were taken at digital magnification of ×20. HE: Hematoxylin–Eosin; IHC: Immunohistochemistry; p53m: p53 mutated; p53wt: p53 wild-type; TC: Tumor cell.***

The time and motion study showed that pathologists required an average of 3.5 minutes per case to assess and score each of the biomarkers. With respect to the difficulty in interpretation, 43 (79.7%) cases were classified as having no difficulties, nine (16.6%) cases were classified as having mild interpretative difficulties and two (3.7%) cases had major interpretative difficulties.

Discussions

Molecular classification of GC is important because it provides relevant prognostic and predictive data. Numerous studies have linked molecular subtypes with survival and benefits of adjuvant chemotherapy [24]. For instance, GC-EBV has the best prognosis in terms of relapse-free survival and overall survival, GC-GS has the worst prognosis, while GC-dMMR has an intermediate prognosis and GC-CIN seems to have an intermediate prognosis and a better response to adjuvant chemotherapy [25].

Several groups attempted to provide molecular classification of GC using different nomenclature, different tests and different interpretative algorithms [8–11]. We proposed an inclusive working molecular classification based on on-slides tests that provides harmonization and can be delivered by histopathology using existing resources. In a study of GC resection specimens, we demonstrated the feasibility of using this classification, however this study left a number of unanswered questions [14]. For example, will endoscopic biopsies contain sufficient tissue for this proposed classification? Will pre-analytical conditions impact on test interpretation? How easy is the assessment of biomarkers on small and superficial samples of carcinoma? Such questions are pertinent, since the endoscopic biopsy is the only tumor tissue available for a significant proportion of GC patients. A molecular classification system must therefore be robust on such specimens. In addition, having implemented molecular classifications for other tumor sites into the diagnostic routine we are aware that it is essential to assess how the data is communicated to and used by the clinicians and how the additional tests impact on the existing resources of the service, including tissue availability, test capacity and TAT [26–29].

Prevalence of molecular subgroups

Compared with the data we obtained on excision specimens [14], the prevalence of each molecular subgroup in endoscopic biopsy differs primarily in the incidence of GC-dMMR (20% in the study from resection specimen and 2% in the endoscopic biopsy study) and GC-EBV (no cases were found in this study, compared to 6% in the resection specimen study). There is also a major difference in the proportion of GC-CIN (23% in the study from resection specimen and 44% in the endoscopic biopsy study. It is worth noting that 38% of the GC-dMMR found in the resection specimen study also have p53 mutant pattern (which, in the absence of dMMR, would have led to classify these cases as GC-CIN). More importantly, while the endoscopic biopsy cohorts had no selection bias and included all patients presenting with carcinoma, the cohort of patients in the resection study was intrinsically biased because it was restricted to operable patients and the operable cohort may be enriched of cases intrinsically less aggressive. This would explain the relative abundance of GC-EBV and GC-dMMR in the operable cohort. Ultimately there are important difference of gender and age in these cohorts: the patients in the current study were on average seven years older than those of the cohort used in the study of

gastric resections specimens, which also had a M:F ratio of 1.94, compared to 3.73 in this present study. While we can speculate on the reasons for the differences in prevalence of the various molecular subgroups in these two studies, neither was designed to assess molecular subgroup prevalence.

Practical considerations over the implementation

Timely execution of our classification required coordination with laboratory staff. We cut all the necessary sections upfront after a diagnosis of invasive carcinoma. We found that 16 spare sections were sufficient. We only had a single case (from a total of 54) where tissue was exhausted, and a single test could not be performed (CLDN18.2). Whilst a step-by-step approach would save reagent costs, it would increase time for both technicians and pathologists and would ultimately be more expensive to the service. Finally, as shown previously [12] planning of all tests upfront allows laboratory staff to optimize the use of immunostainers and minimize the impact on capacity, paradoxically even creating more capacity [30].

An important element to consider is the pathologist's time required to interpret all these tests. A time and motion study performed using digital slides has shown that this classification would add an average of 3.5 minutes per case to the pathologist's workload. It is possible that the time required for assessment using glass slides may be less. This does not consider the time required to train the pathologist in the interpretation of these biomarkers and the time required to maintain competence. The TAT for reporting were not affected by the need to interpret the additional biomarkers.

In our retrospective study, the laboratory batched all the tests for the 24 cases. This ideal scenario was inherently efficient and resulted in minimal burden to the laboratory but did not allow to assess the real impact on the diagnostic routine. The prospective study provided an indication of the difficulties of implementing this classification within diagnostic routine. In the prospective arm of this study, we had a high number (six or 20%) of GC-NOS due to test failure. This was not due to analytical failure, lack of diagnostic tissue or uninterpretable test results but to the reporting pathologist neglecting to request further tests once a diagnosis of invasive carcinoma was obtained. Such a large proportion of "test failure" in the prospective arm is a reminder of the difficulties of implementing reflex testing in a diagnostic histopathology workflow. We suspect we would have had even higher test failure if we implemented a step-by-step approach.

A major difficulty in assessing these biomarkers on endoscopic biopsy is the identification of the invasive carcinoma *versus* HG dysplasia. 16.6% of our cases presented mild interpretative difficulties and 3.7% presented major interpretative difficulties. It will require studies on paired biopsy and excision samples to demonstrate whether biopsies are truly representative. Small biopsies will continue to be vulnerable to sampling errors in heterogeneous tumors and we recommend repeating these tests if additional tumor tissue becomes available.

Correct interpretation of all the on slides tests is key for the successful implementation of this classification. There is consensus on the scoring and interpretation of all of the biomarkers we used in the study apart from p53 [16–20, 31–34]. Interpretation of p53 IHC remains contentious, with numerous groups using interpretative algorithms and cut offs for positivity that differ significantly and makes comparison challenging [35–37]. It is important to remember that, for the purpose of this classification, this IHC is intended to be an assessment of the mutation status of tumor protein p53 (*TP53*) gene, and that the algorithm should clearly differentiate between p53m and p53wt, rather than provide a numerical quantification of p53 immunostaining.

The *TP53* gene encodes for a key regulator of apoptosis and is the most commonly mutated gene in human cancer [38]. In this classification, however, its mutation status is used as surrogate marker to identify tumor with CIN. A certain degree of CIN is present in most tumors, but large-scale losses, gains and rearrangements of deoxyribonucleic acid (DNA) are the hallmark of a group of genetically unstable tumors that behave differently from all others. In fact, CIN is included in the molecular classifications of tumors from several sites [39]. It is important to remember that, even within a single tumor site, this represents a heterogeneous group of diseases that will require further dissection in future. From the practical point of view, it is useful to recognize these tumors because of the specific treatment challenges they pose, including their propensity for continuous large amplitude genetic evolution [40].

Several tumor sites (*e.g.*, gynecological cancer, hematolymphoid cancer, head and neck cancer, colorectal cancer, cancer of soft tissues, etc.) use mutation status of *TP53* gene inferred by p53 IHC for classification and prognosis [41–45]. p53wt protein has a short half-life, resulting in reduced IHC staining. P53 pathogenic mutations can change the p53 staining pattern in a number of ways. The missense mutations in the region encoding the DNA-binding domain (the most prevalent mutations) lead to impaired degradation of the p53 protein mediated by mouse double minute 2 (MDM2) [46]. This lack of degradation results in accumulation of p53 in the nucleus that, in IHC terms, gives strong and diffuse staining. Alternatively, they may result in loss of epitopes recognized by the IHC antibodies, which translates in lack of staining. Lack of staining may be also the result of *TP53* deletion. In addition, some mutations may cause inappropriate intracellular localization of the protein (for instance intracytoplasmic rather than nuclear) [15].

Conversely, expression of p53wt is regulated by certain intracellular pathways and alterations of these pathways may result in overexpression or lack of expression of p53 that is not the consequence of *TP53* gene mutation. There has been concern that amplification of MDM2 may result in IHC p53m null pattern in the absence of *TP53* mutation. In a recent study, Sung *et al.* (2022) investigated the p53 IHC status in 134 solid tumors that included 77% of cases with *TP53* mutation and correlated the IHC status with *TP53* mutation and MDM2 amplification. They found that IHC p53wt pattern can predict absence of pathogenic mutation in *TP53* with 68% sensitivity (Se), 100% specificity (Sp), 100% positive predictive value (PPV) and 91% negative predictive value (NPV); the p53m overexpression pattern can predict in-frame alterations in the DNA binding domain of p53 with 100% Se, 82% Sp, 87% PPV and 100% NPV;

the p53m null pattern can predict mutations associated with significant disruption of protein coding sequences with 86% Se, 97% Sp, 89% PPV and 96% NPV. Importantly, these studies showed that MDM2 alterations were not associated with IHC p53m patterns [47].

While awareness of the factors that regulate p53 expression is essential for the accurate interpretation of p53 IHC, the Se and Sp to predict *TP53* mutation status by IHC depends also on the analytical performance of the IHC test [48, 49]. It is not surprising that different antibody clones and staining protocols have been shown to affect outcomes. In relation to the influence of specific IHC protocols, it is worth noting that in the past 5–7 years there has been a quantum change in the Se of the clinical IHC assays for p53. This coincided with the use of p53 status to assess aggressiveness or histological grade in several solid tumor sites. Hence, dilution of the primary antibody has gone from 1:400 or even 1:800 to 1:100 or 1:200 [50].

In summary, an algorithm that assesses *TP53* mutational status from p53 IHC needs to assess staining on the whole TC population. IHC patterns are null (no staining in any of the TCs), aberrant (cytoplasmic staining in ≥80% of the TCs ± nuclear staining), overexpressed (strong nuclear staining in ≥80% of the TCs) and wild-type (nuclear staining of variable intensity in ≥1% of the TCs). The null, overexpressed and aberrant patterns are associated with mutation and are referred to as p53m pattern [15].

This classification has the potential to deliver timely and important prognostic information to the multi-disciplinary team (MDT)/Tumor Board. Prognostic data is currently derived from other studies that use similar but not identical subgroups. Outcome data is now required to annotate more precisely the molecular subgroups defined by this classification. Good communication with clinicians is also critical and the pathology report may need to contain comments on the clinical implications of the molecular subgroups that could instruct MDT discussions.

Conclusions

This on-slide working classification can be used with small endoscopic biopsies, requires minor modification on the existing tissue pathways and can be delivered with short TAT, fitting the requirements of cancer patients. There is no doubt adding more information to a cancer diagnosis increases the cost of the diagnostic service and consideration should always be given as to whether the increase expenditure is offset by improvements in outcomes or savings in unnecessary therapy. Additional predictive on-slide biomarkers for therapy selection are likely to continue to emerge. Having an established framework for on-slide molecular classification in the diagnostic routine will facilitate implementation of new biomarkers, but training is still required.

Conflict of interests

The authors declare that they have no conflict of interests.

References

[1] Sung H, Ferlay J, Siegel RL, Laversanne M, Soerjomataram I, Jemal A, Bray F. Global Cancer Statistics 2020: GLOBOCAN estimates of incidence and mortality worldwide for 36 cancers in 185 countries. CA Cancer J Clin, 2021, 71(3):209–249. https://doi.org/10.3322/caac.21660 PMID: 33538338

[2] Rawla P, Barsouk A. Epidemiology of gastric cancer: global trends, risk factors and prevention. Prz Gastroenterol, 2019, 14(1):26–38. https://doi.org/10.5114/pg.2018.80001 PMID: 30944675 PMCID: PMC6444111

[3] Hu X, Wang Z, Wang Q, Chen K, Han Q, Bai S, Du J, Chen W. Molecular classification reveals the diverse genetic and prognostic features of gastric cancer: a multi-omics consensus ensemble clustering. Biomed Pharmacother, 2021, 144:112222. https://doi.org/10.1016/j.biopha.2021.112222 PMID: 34607103

[4] Cancer Genome Atlas Research Network. Comprehensive molecular characterization of gastric adenocarcinoma. Nature, 2014, 513(7517):202–209. https://doi.org/10.1038/nature13480 PMID: 25079317 PMCID: PMC4170219

[5] Cristescu R, Lee J, Nebozhyn M, Kim KM, Ting JC, Wong SS, Liu J, Yue YG, Wang J, Yu K, Ye XS, Do IG, Liu S, Gong L, Fu J, Jin JG, Choi MG, Sohn TS, Lee JH, Bae JM, Kim ST, Park SH, Sohn I, Jung SH, Tan P, Chen R, Hardwick J, Kang WK, Ayers M, Hongyue D, Reinhard C, Loboda A, Kim S, Aggarwal A. Molecular analysis of gastric cancer identifies subtypes associated with distinct clinical outcomes. Nat Med, 2015, 21(5): 449–456. https://doi.org/10.1038/nm.3850 PMID: 25894828

[6] Wong SS, Kim KM, Ting JC, Yu K, Fu J, Liu S, Cristescu R, Nebozhyn M, Gong L, Yue YG, Wang J, Ronghua C, Loboda A, Hardwick J, Liu X, Dai H, Jin JG, Ye XS, Kang SY, Do IG, Park JO, Sohn TS, Reinhard C, Lee J, Kim S, Aggarwal A. Genomic landscape and genetic heterogeneity in gastric adenocarcinoma revealed by whole-genome sequencing. Nat Commun, 2014, 5:5477. https://doi.org/10.1038/ncomms6477 PMID: 25407104

[7] World Health Organization (WHO) Classification of Tumours Editorial Board. Digestive system tumours. 5th edition, vol. 1, WHO Classification of Tumours, International Agency for Research on Cancer (IARC) Press, Lyon, France, 2019. https://publications.iarc.fr/Book-And-Report-Series/Who-Classification-Of-Tumours/Digestive-System-Tumours-2019

[8] Setia N, Agoston AT, Han HS, Mullen JT, Duda DG, Clark JW, Deshpande V, Mino-Kenudson M, Srivastava A, Lennerz JK, Hong TS, Kwak EL, Lauwers GY. A protein and mRNA expression-based classification of gastric cancer. Mod Pathol, 2016, 29(7):772–784. https://doi.org/10.1038/modpathol.2016.55 PMID: 27032689

[9] Ramos MFKP, Pereira MA, Amorim LC, de Mello ES, Faraj SF, Ribeiro U, Hoff PMG, Cecconello I, de Castria TB. Gastric cancer molecular classification and adjuvant therapy: is there a different benefit according to the subtype? J Surg Oncol, 2020, 121(5):804–813. https://doi.org/10.1002/jso.25792 PMID: 31797380

[10] Ahn S, Lee SJ, Kim Y, Kim A, Shin N, Choi KU, Lee CH, Huh GY, Kim KM, Setia N, Lauwers GY, Park DY. High-throughput protein and mRNA expression-based classification of gastric cancers can identify clinically distinct subtypes, concordant with recent molecular classifications. Am J Surg Pathol, 2017, 41(1):106–115. https://doi.org/10.1097/PAS.0000000000000756 PMID: 27819872

[11] Zhao C, Feng Z, He H, Zang D, Du H, Huang H, Du Y, He J, Zhou Y, Nie Y. Protein expression-based classification of gastric cancer by immunohistochemistry of tissue microarray. PLoS One, 2020, 15(10):e0238836. https://doi.org/10.1371/journal.pone.0238836 PMID: 33095797 PMCID: PMC7584200

[12] Costache S, Sajin M, Wedden S, D'Arrigo C. A consolidated working classification of gastric cancer for histopathologists (Review). Biomed Rep, 2023, 19(3):58. https://doi.org/10.3892/br.2023.1640 PMID: 37614984 PMCID: PMC10442765

[13] Laurén P. The two histological main types of gastric carcinoma: diffuse and so-called intestinal-type carcinoma: an attempt at a histo-clinical classification. Acta Pathol Microbiol Scand, 1965, 64(1):31–49. https://doi.org/10.1111/apm.1965.64.1.31 PMID: 14320675

[14] Costache S, de Havilland R, Diaz McLynn S, Sajin M, Baltan A, Wedden S, D'Arrigo C. Implementing an on-slide molecular classification of gastric cancer: a tissue microarray study. Cancers (Basel), 2023, 16(1):55. https://doi.org/10.3390/cancers16010055 PMID: 38201483 PMCID: PMC10778243

[15] Köbel M, Ronnett BM, Singh N, Soslow RA, Gilks CB, McCluggage WG. Interpretation of P53 immunohistochemistry in endometrial carcinomas: toward increased reproducibility. Int J Gynecol Pathol, 2019, 38(1 Suppl 1):S123–S131. https://doi.org/10.1097/PGP.0000000000000488 PMID: 29517499 PMCID: PMC6127005

[16] Hofmann M, Stoss O, Shi D, Büttner R, van de Vijver M, Kim W, Ochiai A, Rüschoff J, Henkel T. Assessment of a HER2 scoring system for gastric cancer: results from a validation study. Histopathology, 2008, 52(7):797–805. https://doi.org/10.1111/j.1365-2559.2008.03028.x PMID: 18422971

[17] Abrahao-Machado LF, Scapulatempo-Neto C. HER2 testing in gastric cancer: an update. World J Gastroenterol, 2016, 22(19):4619–4625. https://doi.org/10.3748/wjg.v22.i19.4619 PMID: 27217694 PMCID: PMC4870069

[18] Scheel AH, Penault-Llorca F, Hanna W, Baretton G, Middel P, Burchhardt J, Hofmann M, Jasani B, Rüschoff J. Physical basis of the 'magnification rule' for standardized immunohistochemical scoring of HER2 in breast and gastric cancer. Diagn Pathol, 2018, 13(1):19. https://doi.org/10.1186/s13000-018-0696-x PMID: 29530054 PMCID: PMC5848460

[19] Kulangara K, Hanks DA, Waldroup S, Peltz L, Shah S, Roach C, Juco JW, Emancipator K, Stanforth D. Development of the combined positive score (CPS) for the evaluation of PD-L1 in solid tumors with the immunohistochemistry assay PD-L1 IHC 22C3 pharmDx. Meeting Abstract: 2017 ASCO Annual Meeting I, J Clin Oncol, 2017, 35(15 Suppl):e14589. https://doi.org/10.1200/JCO.2017.35.15_suppl.e14589 https://ascopubs.org/doi/10.1200/JCO.2017.35.15_suppl.e14589

[20] van Laarhoven HWM, Derks S. Claudin-18.2 targeting by Zolbetuximab: results of SPOTLIGHT in perspective. Lancet, 2023, 401(10389):1630–1631. https://doi.org/10.1016/S0140-6736(23)00732-8 PMID: 37068506

[21] Shah MA, Ajani JA, Al-Batran SE, Bang YJ, Catenacci DVT, Enzinger PC, Ilson DH, Kim SS, Lordick F, Shitara K, Van Cutsem E, Arozullah A, Raizer JJ, Park JW, Xu R. Zolbetuximab + CAPOX *versus* CAPOX in first-line treatment of claudin18.2^{+}/HER2^{-} advanced/metastatic gastric or gastroesophageal junction adenocarcinoma: GLOW phase 3 study. Meeting Abstract: 2022 ASCO Gastrointestinal Cancers Symposium, J Clin Oncol, 2022, 40(4 Suppl):TPS365. https://doi.org/10.1200/JCO.2022.40.4_suppl.TPS365 https://ascopubs.org/doi/10.1200/JCO.2022.40.4_suppl.TPS365

[22] Sahin U, Türeci Ö, Manikhas G, Lordick F, Rusyn A, Vynnychenko I, Dudov A, Bazin I, Bondarenko I, Melichar B, Dhaene K, Wiechen K, Huber C, Maurus D, Arozullah A, Park JW, Schuler M, Al-Batran SE. FAST: a randomised phase II study of Zolbetuximab (IMAB362) plus EOX *versus* EOX alone for first-line treatment of advanced CLDN18.2-positive gastric and gastro-oesophageal adenocarcinoma. Ann Oncol, 2021, 32(5):609–619. https://doi.org/10.1016/j.annonc.2021.02.005 PMID: 33610734

[23] Choi S, Park S, Kim H, Kang SY, Ahn S, Kim KM. Gastric cancer: mechanisms, biomarkers, and therapeutic approaches. Biomedicines, 2022, 10(3):543. https://doi.org/10.3390/biomedicines10030543 PMID: 35327345 PMCID: PMC8945014

[24] Alsina M, Arrazubi V, Diez M, Tabernero J. Current developments in gastric cancer: from molecular profiling to treatment strategy. Nat Rev Gastroenterol Hepatol, 2023, 20(3):155–170. https://doi.org/10.1038/s41575-022-00703-w PMID: 36344677

[25] Sohn BH, Hwang JE, Jang HJ, Lee HS, Oh SC, Shim JJ, Lee KW, Kim EH, Yim SY, Lee SH, Cheong JH, Jeong W, Cho JY, Kim J, Chae J, Lee J, Kang WK, Kim S, Noh SH, Ajani JA, Lee JS. Clinical significance of four molecular subtypes of gastric cancer identified by The Cancer Genome Atlas Project. Clin Cancer Res, 2017, 23(15):4441–4449. https://doi.org/10.1158/1078-0432.CCR-16-2211 PMID: 28747339 PMCID: PMC5785562

[26] Wedden S, Miller K, Frayling IM, Thomas T, Chefani A, Miller K, Hamblin A, Taylor JC, D'Arrigo C. Colorectal cancer stratification in the routine clinical pathway: a district general hospital experience. Appl Immunohistochem Mol Morphol, 2019, 27(6):e54–e62. https://doi.org/10.1097/PAI.0000000000000631 PMID: 29985199

[27] Talhouk A, McAlpine JN. New classification of endometrial cancers: the development and potential applications of genomic-based classification in research and clinical care. Gynecol Oncol Res Pract, 2016, 3:14. https://doi.org/10.1186/s40661-016-0035-4 PMID: 27999680 PMCID: PMC5154099

[28] Fremond S, Andani S, Barkey Wolf J, Dijkstra J, Melsbach S, Jobsen JJ, Brinkhuis M, Roothaan S, Jurgenliemk-Schulz I, Lutgens LCHW, Nout RA, van der Steen-Banasik EM, de Boer SM, Powell ME, Singh N, Mileshkin LR, Mackay HJ, Leary A, Nijman HW, Smit VTHBM, Creutzberg CL, Horeweg N, Koelzer VH, Bosse T. Interpretable deep learning model to predict the molecular classification of endometrial cancer from haematoxylin and eosin-stained whole-slide images: a combined analysis of the PORTEC randomised trials and clinical cohorts. Lancet Digit Health, 2023, 5(2):e71–e82. https://doi.org/10.1016/S2589-7500(22)00210-2 PMID: 36496303

[29] Alexa M, Hasenburg A, Battista MJ. The TCGA molecular classification of endometrial cancer and its possible impact on adjuvant treatment decisions. Cancers (Basel), 2021, 13(6):1478. https://doi.org/10.3390/cancers13061478 PMID: 33806979 PMCID: PMC8005218

[30] Thomas T, Wedden S, Afzal N, Mikel J, D'Arrigo C. Use of prospective multiplex immunohistochemistry to redefine tissue pathways of diagnostic core biopsy of prostate. Appl Immunohistochem Mol Morphol, 2022, 30(9):585–591. https://doi.org/10.1097/PAI.0000000000001033 PMID: 36083158 PMCID: PMC9531989

[31] Gulley ML, Glaser SL, Craig FE, Borowitz M, Mann RB, Shema SJ, Ambinder RF. Guidelines for interpreting EBER *in situ* hybridization and LMP1 immunohistochemical tests for detecting Epstein–Barr virus in Hodgkin lymphoma. Am J Clin Pathol, 2002, 117(2):259–267. https://doi.org/10.1309/MMAU-0QYH-7BHA-W8C2 PMID: 11863222

[32] McCarthy AJ, Capo-Chichi JM, Spence T, Grenier S, Stockley T, Kamel-Reid S, Serra S, Sabatini P, Chetty R. Heterogenous loss of mismatch repair (MMR) protein expression: a challenge for immunohistochemical interpretation and microsatellite instability (MSI) evaluation. J Pathol Clin Res, 2019, 5(2):115–129. https://doi.org/10.1002/cjp2.120 PMID: 30387329 PMCID: PMC6463865

[33] Burandt E, Lübbersmeyer F, Gorbokon N, Büscheck F, Luebke AM, Menz A, Kluth M, Hube-Magg C, Hinsch A, Höflmayer D, Weidemann S, Fraune C, Möller K, Jacobsen F, Lebok P, Clauditz TS, Sauter G, Simon R, Uhlig R, Wilczak W, Steurer S, Minner S, Krech R, Dum D, Krech T, Marx AH, Bernreuther C. E-cadherin expression in human tumors: a tissue microarray study on 10,851 tumors. Biomark Res, 2021, 9(1):44. https://doi.org/10.1186/s40364-021-00299-4 PMID: 34090526 PMCID: PMC8180156

[34] Montgomery E, Folpe AL. The diagnostic value of beta-catenin immunohistochemistry. Adv Anat Pathol, 2005, 12(6):350–356. https://doi.org/10.1097/01.pap.0000194628.58501.71 PMID: 16330931

[35] Hwang HJ, Nam SK, Park H, Park Y, Koh J, Na HY, Kwak Y, Kim WH, Lee HS. Prediction of *TP53* mutations by p53 immunohistochemistry and their prognostic significance in gastric cancer. J Pathol Transl Med, 2020, 54(5):378–386. https://doi.org/10.4132/jptm.2020.06.01 PMID: 32601264 PMCID: PMC7483024

[36] Ando K, Oki E, Saeki H, Yan Z, Tsuda Y, Hidaka G, Kasagi Y, Otsu H, Kawano H, Kitao H, Morita M, Maehara Y. Discrimination of p53 immunohistochemistry-positive tumors by its staining pattern in gastric cancer. Cancer Med, 2015, 4(1):75–83. https://doi.org/10.1002/cam4.346 PMID: 25354498 PMCID: PMC4312120

[37] Yildirim M, Kaya V, Demirpence O, Gunduz S, Bozcuk H. Prognostic significance of p53 in gastric cancer: a meta-analysis. Asian Pac J Cancer Prev, 2015, 16(1):327–332. https://doi.org/10.7314/apjcp.2015.16.1.327 PMID: 25640374

[38] Wang H, Guo M, Wei H, Chen Y. Targeting p53 pathways: mechanisms, structures, and advances in therapy. Signal Transduct Target Ther, 2023, 8(1):92. https://doi.org/10.1038/s41392-023-01347-1 PMID: 36859359 PMCID: PMC9977964

[39] Drews RM, Hernando B, Tarabichi M, Haase K, Lesluyes T, Smith PS, Morrill Gavarró L, Couturier DL, Liu L, Schneider M, Brenton JD, Van Loo P, Macintyre G, Markowetz F. A pan-cancer compendium of chromosomal instability. Nature, 2022, 606(7916):976–983. https://doi.org/10.1038/s41586-022-04789-9 PMID: 35705807 PMCID: PMC7613102

[40] Patil S, Jahagirdar S, Khot M, Sengupta K. Studying the role of chromosomal instability (CIN) in GI cancers using patient-derived organoids. J Mol Biol, 2022, 434(3):167256. https://doi.org/10.1016/j.jmb.2021.167256 PMID: 34547328

[41] Li X, Luo D, Zhang L, Li Q, Fan J, Zhang J, Huang B, Yang M, Nie X, Chang X, Pan H. Accurate interpretation of p53 immunohistochemical patterns is a surrogate biomarker for *TP53* alterations in large B-cell lymphoma. BMC Cancer, 2023, 23(1):

1008. https://doi.org/10.1186/s12885-023-11513-x PMID: 37858047 PMCID: PMC10588220

[42] Li J, Wang J, Su D, Nie X, Liu Y, Teng L, Pang J, Wu H, Liang Z. p53 immunohistochemistry patterns are surrogate biomarkers for *TP53* mutations in gastrointestinal neuroendocrine neoplasms. Gastroenterol Res Pract, 2021, 2021:2510195. https://doi.org/10.1155/2021/2510195 PMID: 34956360 PMCID: PMC8695011

[43] Tessier-Cloutier B, Kortekaas KE, Thompson E, Pors J, Chen J, Ho J, Prentice LM, McConechy MK, Chow C, Proctor L, McAlpine JN, Huntsman DG, Gilks CB, Bosse T, Hoang LN. Major p53 immunohistochemical patterns in *in situ* and invasive squamous cell carcinomas of the vulva and correlation with *TP53* mutation status. Mod Pathol, 2020, 33(8):1595–1605. https://doi.org/10.1038/s41379-020-0524-1 PMID: 32203095

[44] Vermij L, Léon-Castillo A, Singh N, Powell ME, Edmondson RJ, Genestie C, Khaw P, Pyman J, McLachlin CM, Ghatage P, de Boer SM, Nijman HW, Smit VTHBM, Crosbie EJ, Leary A, Creutzberg CL, Horeweg N, Bosse T; TransPORTEC consortium. p53 immunohistochemistry in endometrial cancer: clinical and molecular correlates in the PORTEC-3 trial. Mod Pathol, 2022, 35(10):1475–1483. https://doi.org/10.1038/s41379-022-01102-x PMID: 35752743 PMCID: PMC7613653

[45] Thoenen E, Curl A, Iwakuma T. *TP53* in bone and soft tissue sarcomas. Pharmacol Ther, 2019, 202:149–164. https://doi.org/10.1016/j.pharmthera.2019.06.010 PMID: 31276706 PMCID: PMC6746598

[46] Munisamy M, Mukherjee N, Thomas L, Pham AT, Shakeri A, Zhao Y, Kolesar J, Rao PPN, Rangnekar VM, Rao M. Therapeutic opportunities in cancer therapy: targeting the p53–MDM2/MDMX interactions. Am J Cancer Res, 2021, 11(12):5762–5781. PMID: 35018225 PMCID: PMC8727821

[47] Sung YN, Kim D, Kim J. p53 immunostaining pattern is a useful surrogate marker for *TP53* gene mutations. Diagn Pathol, 2022, 17(1):92. https://doi.org/10.1186/s13000-022-01273-w PMID: 36471402 PMCID: PMC9720942

[48] Guedes LB, Almutairi F, Haffner MC, Rajoria G, Liu Z, Klimek S, Zoino R, Yousefi K, Sharma R, De Marzo AM, Netto GJ, Isaacs WB, Ross AE, Schaeffer EM, Lotan TL. Analytic, preanalytic, and clinical validation of p53 IHC for detection of *TP53* missense mutation in prostate cancer. Clin Cancer Res, 2017, 23(16):4693–4703. https://doi.org/10.1158/1078-0432.CCR-17-0257 PMID: 28446506 PMCID: PMC5559307

[49] Köbel M, Piskorz AM, Lee S, Lui S, LePage C, Marass F, Rosenfeld N, Mes Masson AM, Brenton JD. Optimized p53 immunohistochemistry is an accurate predictor of *TP53* mutation in ovarian carcinoma. J Pathol Clin Res, 2016, 2(4):247–258. https://doi.org/10.1002/cjp2.53 PMID: 27840695 PMCID: PMC5091634

[50] Sabapathy K, Lane DP. Understanding p53 functions through p53 antibodies. J Mol Cell Biol, 2019, 11(4):317–329. https://doi.org/10.1093/jmcb/mjz010 PMID: 30907951 PMCID: PMC6487784

Corresponding author

Simona Costache, MD, PhD Student, Doctoral School, Carol Davila University of Medicine and Pharmacy, 8 Eroii Sanitari Avenue, Sector 5, 050474 Bucharest, Romania; Phone +44 7485 386911, +40 723 678076, e-mail: simona.costache.anapat@gmail.com

Received: March 18, 2024

Accepted: June 3, 2024