Rom J Morphol Embryol 2024, 65(2):185–193 ISSN (print) 1220–0522, ISSN (online) 2066–8279 doi: 10.47162/RJME.65.2.04

ORIGINAL PAPER

RJME
Romanian Journal of Morphology & Embryology
http://www.rjme.ro/

Prognostic implications of immunohistochemistry in patients with endometrial cancer

MARIA-BIANCA ANCA-STANCIU[1–3], ANDREI MANU[1–3], MARIA VICTORIA OLINCA[4,5], BOGDAN CĂTĂLIN COROLEUCĂ[2,3], DIANA-ELENA COMANDAŞU[2,3], CIPRIAN ANDREI COROLEUCĂ[2,3], CĂLINA MAIER[2,3], ELVIRA BRĂTILĂ[2,3]

[1)] *PhD Student, Doctoral School, Carol Davila University of Medicine and Pharmacy, Bucharest, Romania*

[2)] *Department of Obstetrics and Gynecology, Carol Davila University of Medicine and Pharmacy, Bucharest, Romania*

[3)] *Department of Obstetrics and Gynecology, Prof. Dr. Panait Sîrbu Clinical Hospital of Obstetrics and Gynecology, Bucharest, Romania*

[4)] *Department of Anatomical Pathology, Carol Davila University of Medicine and Pharmacy, Bucharest, Romania*

[5)] *Department of Anatomical Pathology, Prof. Dr. Panait Sîrbu Clinical Hospital of Obstetrics and Gynecology, Bucharest, Romania*

Abstract

Various histological cell types, high histological grade, extensive myometrial invasion, and the presence of lymphovascular involvement are recognized as risk factors for disease development. Individuals carrying mutations in MutL homolog 1 (*MLH1*), MutS homolog 2 (*MSH2*), MutS homolog 6 (*MSH6*), or postmeiotic segregation increased 2 (*PMS2*) genes face an increased susceptibility to both endometrial and colorectal malignancies, with a lifetime risk ranging from 40% to 60%. This research aimed to investigate the prevalence of specific immunohistochemical (IHC) markers and microsatellite instability in endometrial carcinomas and explore potential associations with patient characteristics and clinical outcomes. Out of 58 patients with comprehensive follow-up data, a subgroup of 21 cases underwent rigorous IHC evaluation, involving estrogen receptor (ER), progesterone receptor (PR), Ki67, MLH1, MSH2, MSH6, PMS2, and p53 markers. Statistical analysis, employing the χ^2 (*chi*-squared) test, was conducted to assess the connection between individual IHC markers and clinical outcomes, with particular emphasis on the influence of radiation, chemotherapy, or brachytherapy treatment, as well as the occurrence of recurrence or mortality. Notably, significant correlations were observed in cases where MSH2 and MSH6 exhibited positive results, indicating their association with the use of chemotherapy and brachytherapy. However, the analysis pertaining to *International Federation of Gynecology and Obstetrics* (FIGO) stage or tumor grade did not reveal any statistically significant relationships with these parameters.

Keywords: endometrial cancer, immunohistochemistry, radiotherapy, chemotherapy.

Introduction

Endometrial carcinoma (EC) stands as the prevailing gynecological malignancy afflicting American women, and in 2022, it is estimated to have contributed to approximately 39 300 new cases and 6600 fatalities [1]. Many women with early-stage EC experience recurrence and eventually pass away from the illness, despite receiving definitive surgical treatment. Factors such as specific histological cell types, high histological grade, extensive myometrial invasion, and the involvement of lymphovascular pathways are established risk determinants for disease progression [2]. Obesity, unopposed estrogen states (such as polycystic ovarian syndrome), early menarche or late menopause and genetic cancer syndromes such as Lynch syndrome (LS) and Cowden syndrome are all risk factors for EC [3]. Conversely, protective factors against EC include experiencing multiple pregnancies (multiparity) and use of oral contraceptives. Of particular significance is LS, an inherited condition stemming from germline mutations within genes responsible for deoxyribonucleic acid (DNA) mismatch repair (MMR). This syndrome accounts for approximately 3% of all instances of endometrial malignancies [2]. Individuals harboring mutations in genes such as MutL homolog 1 (*MLH1*), MutS homolog 2 (*MSH2*), MutS homolog 6 (*MSH6*), or postmeiotic segregation increased 2 (*PMS2*) face an escalated risk for both endometrial and colorectal cancers, with a lifetime risk ranging from 40% to 60% [3]. Furthermore, these individuals carry a lifetime susceptibility of 9% to 12% for ovarian cancer [4].

In recent years, there has been a notable upswing in the integration of molecular analysis and tailored molecular-based therapies in the context of patient-centered care for EC [5]. This reflects the growing emphasis on leveraging molecular insights to inform treatment strategies, optimizing the management of this complex malignancy.

Aim

The aim of this study was to investigate potential correlations between specific immunohistochemical (IHC) characteristics and post-surgical prognosis in patients diagnosed with EC. By analyzing the expression patterns of these IHC markers, we aimed to elucidate their potential prognostic significance in predicting disease outcomes following surgical intervention. Through comprehensive

This is an open-access article distributed under the terms of a Creative Commons Attribution-NonCommercial-ShareAlike 4.0 International Public License, which permits unrestricted use, adaptation, distribution and reproduction in any medium, non-commercially, provided the new creations are licensed under identical terms as the original work and the original work is properly cited.

examination and statistical analysis of patient samples, we seek to identify any associations between the expression levels of these markers and key clinical parameters, such as disease recurrence, overall survival, and response to treatment. Ultimately, our goal was to contribute valuable insights into the development of more accurate prognostic tools and personalized treatment strategies for patients undergoing surgical management of EC.

Patients, Materials and Methods

We identified a total of 58 patients who had received a pathological diagnosis of EC through a retrospective analysis. Surgical staging procedures were carried out on all patients at the Prof. Dr. Panait Sîrbu Clinical Hospital of Obstetrics and Gynecology, Bucharest, Romania, between 2020 and 2022. Approval for this research inquiry was obtained from the Institutional Review Boards of the Prof. Dr. Panait Sîrbu Clinical Hospital of Obstetrics and Gynecology. A prospective study was conducted to collect socio-demographic, lifestyle, and medical data. Clinical information was extracted from medical and pathology records, including details about histological subtypes (endometrioid, serous, clear cell, carcinosarcoma), tumor stage (I, II, III, and IV), tumor grade (1, 2, and 3), presence of lymphovascular space invasion (LVSI; yes, no/unknown), and adjuvant therapy (brachytherapy, chemotherapy, radiotherapy; whether any of these treatments were administered or not). The staging of cases was performed according to the criteria established by the *International Federation of Gynecology and Obstetrics* (*Fédération Internationale de Gynécologie et d'Obstétrique* – FIGO) in 2009. Each slide was individually assessed to confirm the diagnosis, histological subtype, and grade. Further in our study, we performed IHC staining on 4 µm thick whole tissue sections using the following antibodies: anti-estrogen receptor (ER, clone 6F11), anti-progesterone receptor (PR, clone 1A6), anti-p53 (clone DO7), anti-Ki67 (clone MIB1), anti-MLH1 (clone M1), anti-MSH2 (clone G219-1129), anti-MSH6 (clone SP93), and anti-PMS2 (clone A16-4), following the manufacturer's guidelines. For p53 immunostaining, we categorized our interpretation into two groups: wild-type or mutated, encompassing over-expression or null patterns. Regarding the IHC expression of MLH1, MSH2, MSH6, and PMS2, adjacent normal tissue and surrounding tissue lymphocytes were utilized as internal positive controls for each case. The classification of MMR immunohistochemistry was also divided into two categories: intact or deficient, based on the nuclear staining of the tumor compared to the corresponding internal control. To quantify the expressions of ER, PR, and Ki67, we calculated the percentage of positive tumoral nuclei. In cases with suboptimal specimen fixation, as occasionally observed in hysterectomy specimens, staining patterns displayed shifts from well-fixed to less well-fixed areas. In these cases, the interpretation of staining predominantly depended on the well-fixed regions.

A total of 58 patients underwent evaluation, with only 21 of them undergoing immunohistochemistry tests on the specimens following surgical intervention. The purpose of these tests was to determine whether there is a correlation between the expression of specific IHC characteristics and the prognosis of the disease after surgery.

Results

Patients' characteristics, surgical interventions, follow-up

Comprehensive follow-up data was available for all the patients. Out of the total sample size of 58 patients, a subset of 21 individuals had a satisfactory immunohistochemistry analysis, while the remaining patients did not undergo this specific diagnostic test. The mean age at the diagnostic of the disease for the entire sample was 62.1±9.53 years (Table 1). The average body mass index (BMI) in this group was 31.91 kg/m^2, ranging from 20.7 kg/m^2 to 44.4 kg/m^2, which typically falls into the category of degree I obesity. At the initial diagnosis, only 10 individuals in the patient cohort were identified as smokers. The primary presenting symptom prompting medical consultation was post-menopausal metrorrhagia, which occurred in around 86.2% of the cases. Two individuals were diagnosed with breast cancer and subsequently had surgical intervention. Additionally, they were receiving Tamoxifen medication as part of their treatment regimen at the moment of presentation. Table 1 offers detailed information in relation to the patients' personal medical backgrounds.

Table 1 – *Patients' characteristics*

Patients' characteristics	Values
Mean age [years]	62.1±9.53
Mean BMI [kg/m^2]	31.91±5.58
Environment (U/R) [*n* / %]	U (41 / 70%); R (18 / 30%)
Smoking [*n* / %]	10 / 17.24%
Post-menopausal metrorrhagia [*n* / %]	50 / 86.2%
High blood pressure [*n* / %]	44 / 75.86%
Diabetes mellitus [*n* / %]	12 / 20.86%
Cardiac disease (ischemic heart disease or others) [*n* / %]	5 / 8.62%
Thyroid affliction [*n* / %]	11 / 18.96%
Dyslipidemia [*n* / %]	15 / 25.86%

BMI: Body mass index; *n*: No. of patients; R: Rural; U: Urban.

The major surgical technique that occurred most often was laparotomy for total hysterectomy with bilateral salpingo-oophorectomy, accounting for 58.62% of cases (Figure 1).

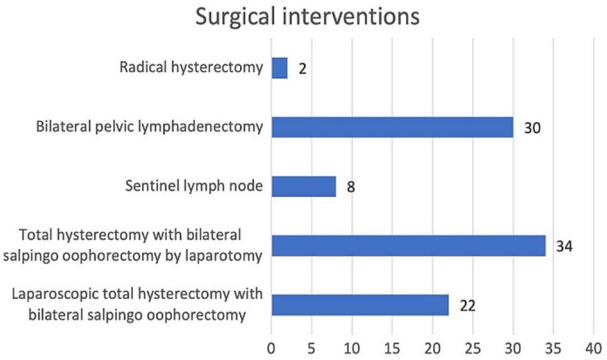

Figure 1 – *Graphical representation of the various surgical interventions performed.*

Laparoscopic total hysterectomy with bilateral salpingo-oophorectomy was performed in 37.93% of the cases. Two cases had class B1 radical hysterectomy. In a total of eight

cases, the sentinel lymph node was solely identified and examined by laparoscopic procedures, employing either Indocyanine Green or Methylene Blue as the contrasting agent. A total of 30 individuals had bilateral pelvic lymphadenectomy, which was done using either laparoscopic or laparotomy techniques. All cases were conducted without any difficulties during the surgical procedure, and the immediate postoperative progress was favorable.

The macroscopic examination of hysterectomy specimens revealed that the tumor was diffuse throughout the uterine cavity in 87.7% of cases and developed in a polyp in 12% of cases (Figure 2, A and B).

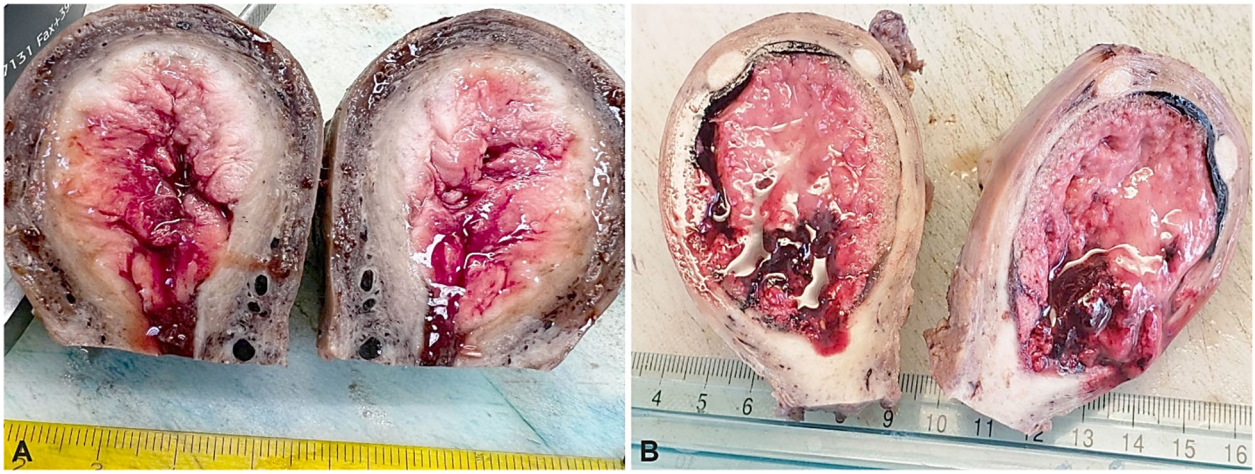

Figure 2 – ***Macroscopic features of endometrial carcinoma: tumoral mass with irregular borders, diminished consistency, with areas of necrosis and hemorrhage. Comparative view of the tumor's growth patterns and spread within the uterine structure: (A) Carcinoma invasively penetrating more than half of the myometrium; (B) Carcinoma developed within an endometrial polyp.***

According to histological analysis, endometrioid adenocarcinoma was the predominant histological type, accounting for 87.93% of cases. Non-endometrioid carcinomas comprised 10 (10.34%) cases, including four cases of serous carcinoma and two cases of clear cell carcinoma (Figure 3, A–D). Myometrial invasion was observed in all cases, with it exceeding 50% of the myometrial thickness in 42 (72.41%) cases. Seven cases showed lymphovascular invasion, and five cases showed perineural invasion was observed in five of these cases. In the majority (96.5%) of cases, the characteristic myometrial infiltration pattern was classical. However, one case exhibited an atypical infiltration pattern known as the MELF pattern, characterized by microcystic, elongated, and fragmented glands. This particular case involved a grade 2 endometrioid carcinoma. Furthermore, in two (13%) cases, we observed the colonization of adenomyosis foci.

The tumors were classified based on the *World Health Organization* (WHO) criteria. Among the endometrioid malignancies, 26 were categorized as grade 1 (G1), 22 were classified as grade 2 (G2), and 10 were designated as grade 3 (G3). The assignment of *FIGO* stages to all patients was determined by evaluating intraoperative and pathological evidence. In our series, tumor staging revealed 40 cases at stage IA, 16 at stage IB, two at stage II at the time of the diagnostic.

In the conducted investigation, it was shown that none of the patients needed neoadjuvant therapy. In two cases, radiation as a standalone treatment modality sufficed, whereas in one case brachytherapy alone was considered sufficient. In 10 cases, the administration of radiotherapy was required, either in conjunction with chemotherapy in eight cases or with brachytherapy in eight cases.

The follow-up duration for our study ranged from one to four years. At the point of last communication, there were 54 individuals who were alive without any discernible signs of illness, while two individuals were still alive but had experienced a documented relapse (vaginal recurrence). Additionally, one individual had passed away due to the condition, while another individual had succumbed to circumstances unrelated to the sickness [coronavirus disease 2019 (COVID-19) infection].

Immunohistochemical analysis

As previously mentioned, immunohistochemistry was conducted in 21 cases. A comprehensive assessment was conducted on a set of markers, including ER (Figure 4), PR, Ki67, vimentin, MLH1, MSH2, MSH6, PMS2, p53. The maximum count seen in each specimen was recorded: 71.42% had positive staining for ER, 57.14% had positive staining for PR, 8.62% displayed mutated pattern for p53 (Figure 5, A and B) and Ki67 (Figure 6, A and B) varied between 15% and 80%. The deficiency of MMR status was determined when the IHC analysis revealed a total absence of nuclear expression in carcinoma cells for one or more MMR proteins, including MLH1, MSH2, MSH6, and PMS2, indicating microsatellite instability (MSI): seven cases showed loss of both MLH1 and PMS2, three cases showed loss of both MSH2 and MSH6 and one case showed isolated loss of PMS2. Conversely, in the rest of the cases all four MMR proteins showed nuclear expression on IHC, suggesting a microsatellite stable (MSS) status (Figure 7).

A study using the χ^2 (*chi*-squared) test (Pearson's correlation) was conducted to examine the relationship between each IHC marker and clinical outcome, specifically in relation to treatment with radiation, chemotherapy, or brachytherapy, as well as the occurrence of recurrence or mortality.

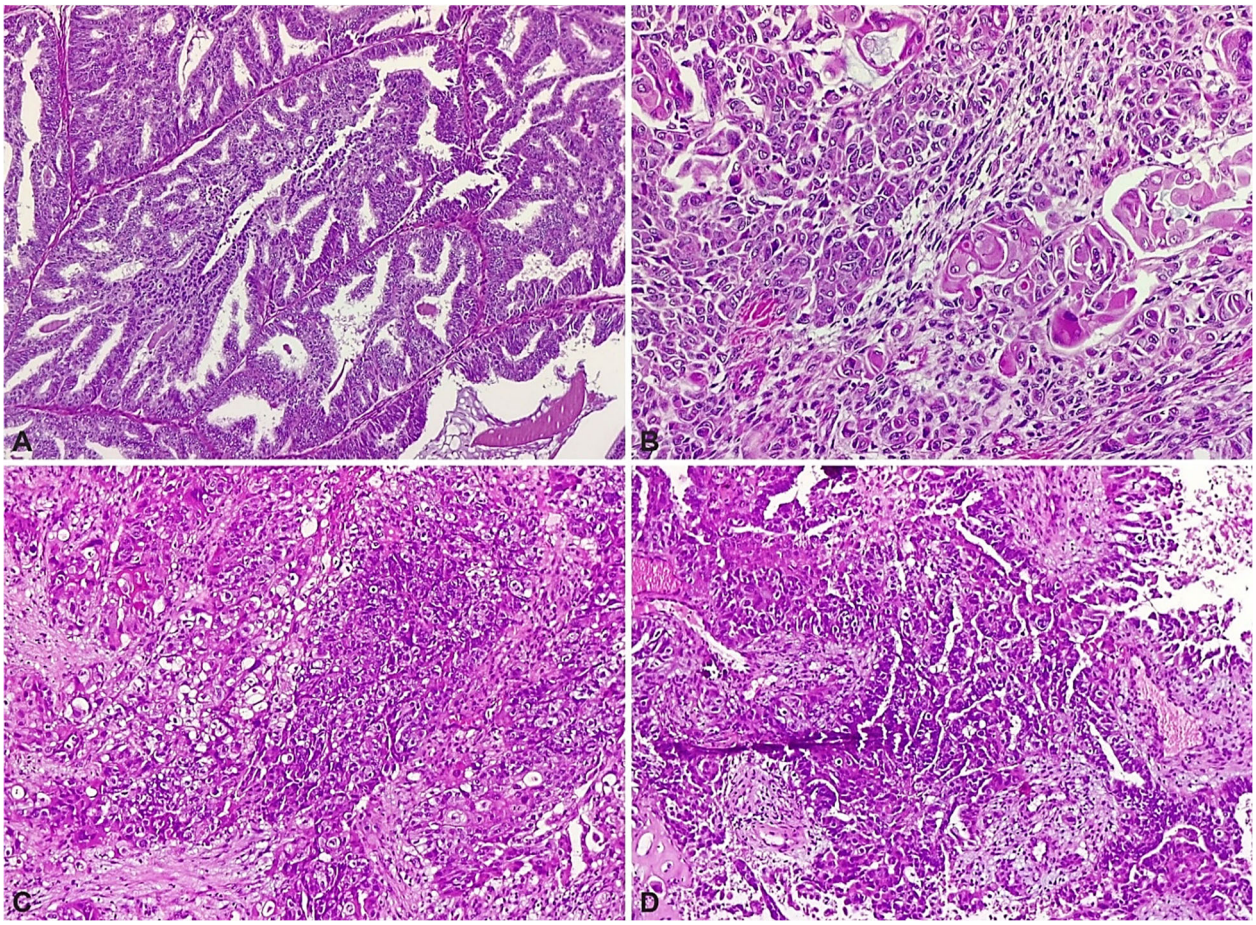

Figure 3 – ***Histological features of endometrial carcinoma: (A) G1 endometrioid adenocarcinoma – well-differentiated glandular structures, low-grade nuclei; (B) G2 endometrioid adenocarcinoma with areas of squamous metaplasia; (C) G3 endometrioid adenocarcinoma – poorly differentiated tumor cell nests that are mostly solid, with little to no glandular formation; (D) Serous carcinoma – prominent nuclear atypia, papillary structures. HE staining: (A, C and D) ×40; (B) ×100. HE: Hematoxylin–Eosin.***

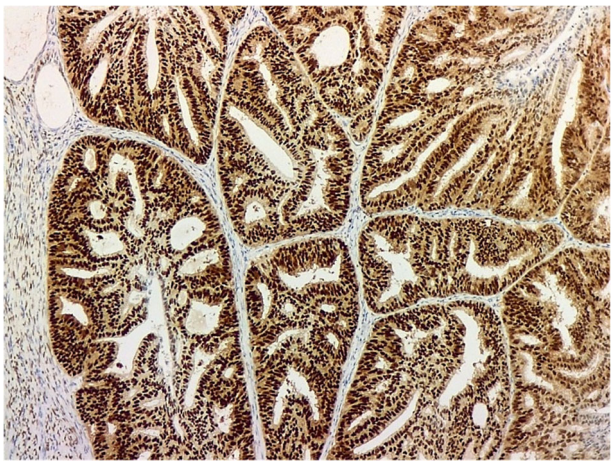

Figure 4 – ***ERs positive in tumoral cells. IHC staining, ×40. ER: Estrogen receptor; IHC: Immunohistochemical.***

The analysis included variables such as *FIGO* stage of disease, tumor grade and each individual IHC marker. Upon doing individual analyses of each marker, it was determined that there exists no statistically significant association (p>0.05) between the ER, PR, p53 immunomarkers and the likelihood of receiving postoperative treatment including radiation, chemotherapy, or brachytherapy and also there was no statistically significant correlations between these immunomarkers and the probability of disease recurrence. No statistically significant associations were identified between the presence of MLH1 or PMS2 and the aforementioned variables. No statistically significant link was identified between the *FIGO* stage or tumor grade and the same factors, as per the investigation conducted to explore this relationship.

In contrast, concerning the Ki67 immunomarker, our examination using the χ^2 test unveiled a statistically significant relationship between Ki67 immunoexpression and the requirement for brachytherapy as part of the treatment regimen (p=0.027). However, no statistically significant associations were detected between Ki67 immunoexpression and the administration of chemotherapy or radiotherapy, nor were any significant links established between Ki67 immunoexpression and the occurrence of disease recurrences.

After analysis of the findings related to MSH2, it becomes evident that a statistically significant association exists between the presence of this marker and the administration of chemotherapy (p=0.017) and brachytherapy (p=0.033). However, no statistically significant correlation is seen between MSH2 and chemotherapy or the likelihood of recurrence. Similar findings of statistical significance were seen in cases with MSH6 positive – a statistically significant association between expression of the marker and chemotherapy (p=0.017) and brachytherapy (p=0.033).

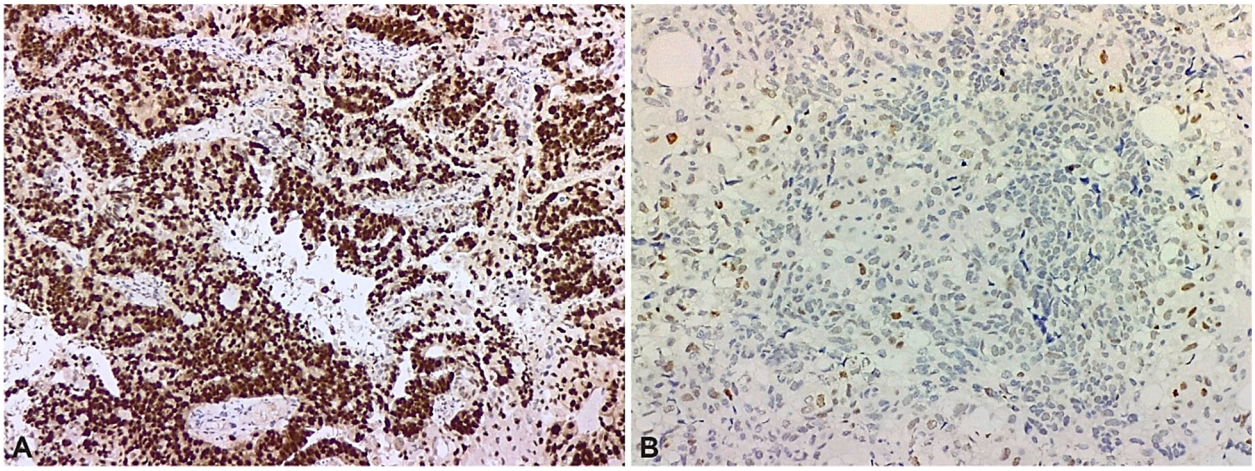

Figure 5 – ***p53 immunostaining: (A) Mutated type p53 immunostaining showing an intense and abnormal accumulation of p53 protein within the cell nuclei, which suggests a mutation in the TP53 gene; (B) Wild-type p53 immunostaining reveals a weaker and less extensive staining pattern, indicative of the normal regulatory role of p53 in the cell. IHC staining: (A) ×40; (B) ×100. IHC: Immunohistochemical; TP53: Tumor protein p53.***

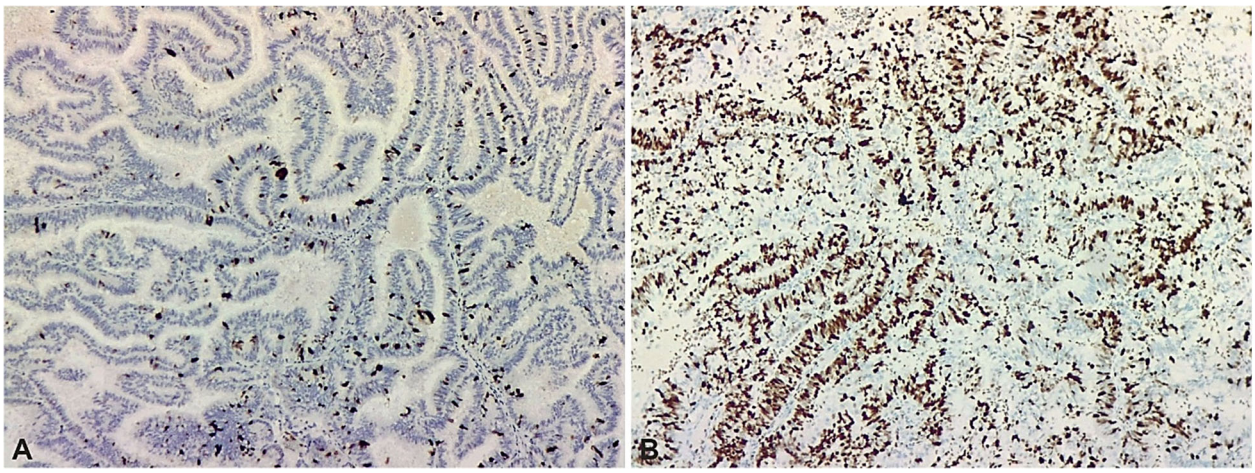

Figure 6 – ***Ki67 immunostaining in tumor cells, with two different levels of positivity: (A) 15% positivity rate, indicating a lower PI; (B) 80% positivity rate, suggesting a higher PI. IHC staining: (A and B) ×40. IHC: Immunohistochemical; PI: Proliferative index.***

Discussions

The joint effort on EC conducted by *The Cancer Genome Atlas* (TCGA) has successfully discovered four unique prognostic subtypes of EC [6]. These subtypes were determined based on genetic anomalies, holding considerable implications for the potential tailoring of adjuvant therapy with greater precision. The molecular categorization demonstrates a significant association with patient prognosis and has the potential to enhance the identification of early-stage patients who might potentially derive benefits from adjuvant therapy. Nevertheless, the implementation of genomic technologies, such as genome sequencing, can incur significant costs and present technical challenges, particularly in the context of extracting DNA from tissue samples [7, 8].

These four EC subgroups are defined as follows:

(*1*) DNA polymerase epsilon (POLE) ultra-mutated: characterized by an exceptionally high mutation burden in the exonuclease domain of the *POLE* gene, resulting in the inactivation of *POLE* and the failure of DNA proofreading during replication.

(*2*) MSI hypermutated: exhibiting a heightened level of MSI, which contributes to a high mutation rate.

(*3*) Copy-number low (no specific molecular profile – NSMP): this subgroup lacks a distinct molecular profile and is identified by the preservation of p53 and MMR IHC expression.

(*4*) Copy-number high (p53 abnormal – p53abn): characterized by abnormal p53 IHC expression, including complete loss and/or overexpression of the p53 protein [6].

The mismatch repair deficient (MMRd) tumor phenotype accounts for around 17–33% of all cases of endometrial malignancies [9]. Initially, the molecular profile in question was seen in individuals diagnosed with LS, a hereditary condition associated with a 60% lifetime probability of developing EC [9]. Moreover, the presence of a particular molecular genetic modification, arising from a malfunction in the human (*h*)*MLH1*, *hMSH2*, *hMSH6* or *hPMS2* MMR genes, has been seen in sporadic tumors referred to as MMRd or Lynch-like syndrome tumors. Tumors that do not exhibit any abnormalities in the MMR genes are categorized as mismatch repair proficient (MMRp) [10]. Recent research has established that employing aberrant p53 immunohistochemistry is a reliable approach for identifying cases with tumor protein p53 (*TP53*) gene mutations in endometrial

malignancies [9]. These mutations are found in around 25% of all EC cases [10, 11]. The use of abnormal p53 IHC in biopsies has shown a specificity of 94% and a sensitivity of 91% [11]. The prevalence of *POLE* mutations in endometrial malignancies is 8.59%, with a majority of these changes being observed in early stages (I–II) at a rate of 89.51% [12]. Additionally, a significant proportion of these mutations are found in tumors of the highest grade (3), accounting for 51.53% of cases [12]. Several IHC markers have been investigated in previous studies, including ER, PR, human epidermal growth factor receptor 2 (HER2) and Ki67. However, none of these markers have demonstrated consistent enough results to be routinely used for the subclassification of EC [13].

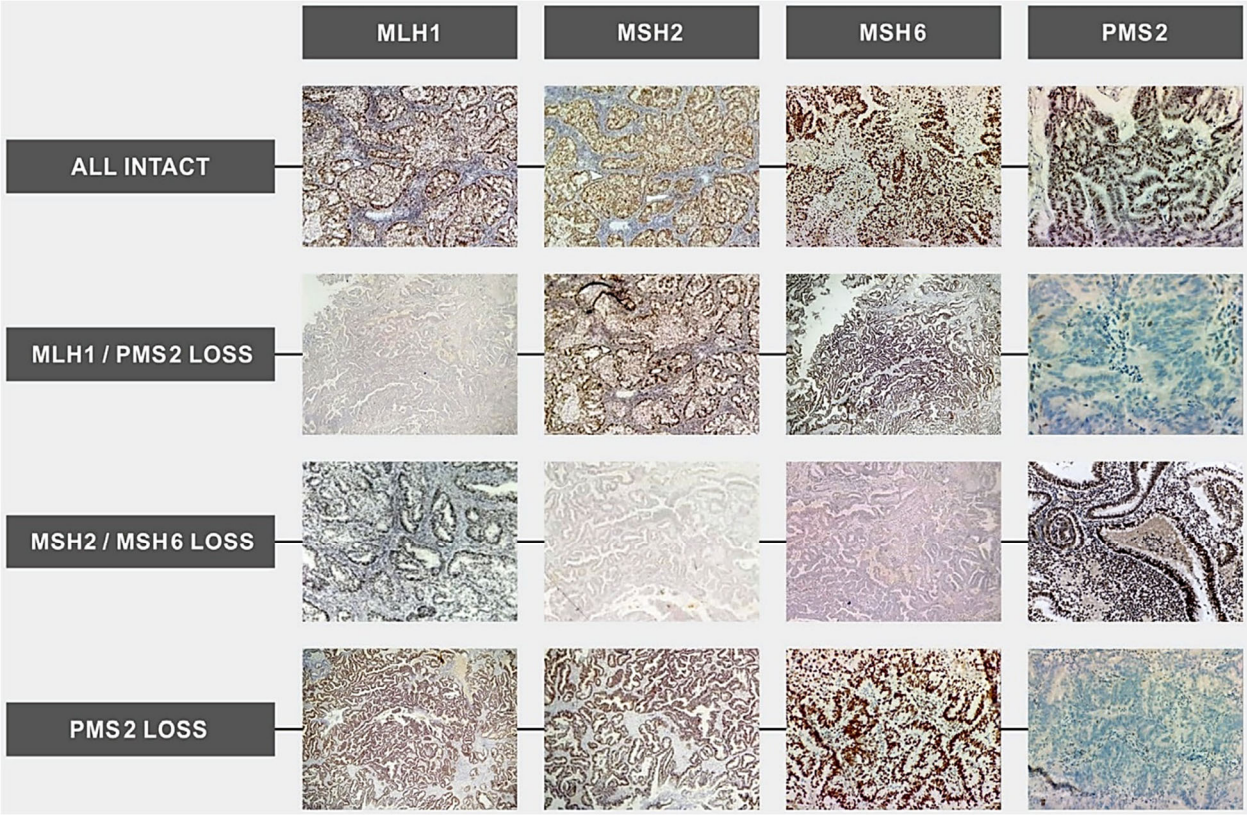

Figure 7 – ***MMR immunoreactivity – different pattern expression of MMR proteins in cells (MLH1, MSH2, MSH6, and PMS2). Each row indicates different combinations of protein loss. The top row shows all proteins intact, indicating normal MMR function. The subsequent rows show loss of different proteins: MLH1 and PMS2 loss, MSH2 and MSH6 loss, and isolated PMS2 loss (IHC staining). IHC: Immunohistochemical; MLH1: MutL homolog 1; MMR: Mismatch repair; MSH2: MutS homolog 2; MSH6: MutS homolog 6; PMS2: Postmeiotic segregation increased 2.***

Over the course of the last decade, there has been notable progress in both the study and practical use of immunohistochemistry markers across a range of malignant and non-malignant medical conditions. Consequently, it is plausible that each of the markers under investigation has the potential to indicate a higher likelihood of malignancy if its expression deviates from normal [2]. Moreover, these markers might potentially be targeted in the future for therapy that is specifically customized at the molecular level (Table 2).

Table 2 – ***Immunohistochemical markers. Adapted from Gossett et al. [14]***

Immunomarker	Function	Role in tumorigenesis
p53	The process of arresting the cell cycle is used to facilitate DNA repair and to induce apoptosis.	The absence of the wild-type gene results in uncontrolled proliferation.
ER	A diverse array of regulatory functions.	The regulatory influence on several additional pathways is characterized by uncertainty and complexity.
PR	A diverse array of regulatory functions.	The regulatory influence on several additional pathways is intricate and characterized by a state of uncertainty.
Ki67	The gene is ubiquitously expressed in both normal and cancerous tissues throughout the cell cycle, with the exception of the G0 phase.	The observed phenomenon indicates an increase in cellular division and mitotic activity.

DNA: Deoxyribonucleic acid; ER: Estrogen receptor; PR: Progesterone receptor.

During the early 1990s the primary emphasis in the study of hereditary nonpolyposis colorectal cancer (HNPCC) progression was directed towards investigating mutations occurring in the *MLH1* and *MSH2* genes [15]. Initially, it was hypothesized that the four MMR proteins only operated as a heterodimer complex [15]. In the event that one of the two proteins (MLH1 with PMS2 and MSH2 with MSH6) was absent, the complex would cease to function, and the expression of the other protein would be inhibited [16]. Therefore, the use of four proteins in immunohistochemistry enhances the detection of instances with MMR deficiency. Furthermore, Goodfellow *et al.* conducted a study with a

cohort of 1002 patients diagnosed with EC [17]. Their findings revealed that the most prevalent problem in the DNA MMR system was the loss of *MLH1*, followed by combined losses of *MSH2* and *MSH6*, and then isolated loss of *MSH6* [17]. Multiple papers have shown a higher occurrence of *MSH6* mutations in patients with EC compared to patients with HNPCC tumors [17]. Therefore, it is essential to do IHC screening on individuals diagnosed with EC using the four specified proteins [18]. The correlation between MMR deficient tumors and outcomes in women diagnosed with EC remains incompletely established. Several research has shown a significant increase in survival rates among women with MMR deficient tumors [19]. However, other studies have reported worse outcomes or no discernible changes [20]. The findings of subsequent studies with varying designs assessing survival using multivariate analysis reported inconsistent results regarding these associations [19, 20, 21, 22]. On the other hand, one study, which analyzed 109 patients with endometrioid and non-endometrioid subtypes of EC, found no association between tumor MMR-deficiency and survival [23]. In contrast, another study involving 191 patients reported improved survival for MMR-deficient EC based on immunohistochemistry results [24]. Furthermore, no association between tumor MMR class and outcome was observed in a study of 1024 patients with epigenetic MMR defective EC or "probable MMR mutation" [25]. This latest investigation involving 466 women revealed that endometrioid *MLH1*-methylated MMR-deficient EC cases exhibited a significantly lower recurrence-free survival rate according to the univariate analysis ($p<0.001$) [26]. Previous studies have shown that MSH6 may serve as a possible prognostic indicator in EC. Specifically, elevated levels of MSH6 in hysterectomy tissue have been linked to unfavorable outcomes and the presence of non-endometrioid subtypes [27, 28]. Emerging evidence suggests that MSH6 serves as an independent prognostic factor for survival outcomes in a subset of EC patients. Specifically, individuals falling within this category may face increased risks of disease recurrence despite their low-grade histological profile. Several investigations have demonstrated that the presence of MSH6 in endometrioid low-grade histology serves as an independent prognostic factor for unfavorable survival outcomes [29].

Recognizing the prognostic significance of MSH6 expression in endometrioid low-grade histology has clinical implications. Despite their histological classification, patients with MSH6 expression may warrant more vigilant follow-up and a reconsideration of treatment strategies. This subgroup represents a minority, approximately 7% of the population [29], but their increased risk of recurrence underscores the need for individualized care. These findings emphasize the importance of personalized treatment strategies and closer surveillance for individuals falling into this category. In summary, a thorough evaluation of MSH6 may hold the potential to enhance the prognostic assessment of pre-operative EC patients, ultimately aiding in the stratification of patients for invasive surgical procedures and additional therapeutic interventions [28, 29]. While our current investigation did not establish a definitive correlation between MMR status, specifically MSH2 or MSH6, and the overall prognosis of the disease, we did identify a notable association between these factors and the likelihood of requiring chemotherapy or brachytherapy.

In relation to their correlation with other clinico-pathological factors, it was observed that ER exhibited a significant association with grade 1–2 tumors [30]. Conversely, positive PR expression demonstrated a significant association with various favorable prognostic factors, such as reduced myometrial invasion, endometrioid histology, grade 1–2 tumors and the absence of lymph node involvement [31]. Numerous studies have shown the correlation between ER and PR expression and several favorable clinicopathological characteristics, such as endometrioid histology, well-differentiated tumor, and limited myometrial invasion [32–34]. Nevertheless, our investigation was unable to establish a correlation between the expressions of ER, PR, and other prognostic variables.

The presence of a p53 mutation is a significant prognostic indicator for both serous and endometrioid tumors [35]. The determination of *TP53* gene mutation status was conducted using immunohistochemistry to assess p53 expression, categorizing it as either wild-type or mutant. Previous research has highlighted a noteworthy correlation between p53 expression and high-grade tumors, disease stage, cervical involvement, and adnexal involvement. Additionally, it has been observed that endometrioid carcinoma with wild type p53 exhibited a two-year disease-free survival rate of 100%, whereas the p53 mutant variety had a rate of 86.2% [35]. In the current study, approximately 15.9% of patients were reclassified into the high-risk category, necessitating the consideration of chemotherapy and radiation treatment. This reclassification was based on the assessment of their p53 mutation status, in accordance with the *European Society of Gynecologic Oncology* (ESGO)–*European Society of Radiation Therapy and Oncology* (ESTRO) 2021 Consensus classification [36]. However, in the present investigation, we did not identify any statistically significant correlation between p53 expression and prognostic variables.

Study limitations

The extent of our research is limited due to the small number of patients included in our study, and an even smaller subset underwent IHC analysis. As a result, the applicability of our findings to a more extensive range of patients is restricted. To validate our results effectively, it is imperative to conduct randomized trials involving larger and more diverse patient cohorts. While our study of EC and IHC analysis provides valuable insights, it is important to acknowledge its limitations. Primarily, the study was conducted at a single center, potentially limiting the generalizability of our findings to broader populations. The small number of subjects included in the study further restricts the statistical power and may introduce biases that could impact the robustness of our conclusions. Additionally, the retrospective nature of the study design poses inherent limitations, such as the reliance on existing medical records and potential inconsistencies in data collection. Furthermore, variations in laboratory techniques and interpretations of IHC staining across different pathologists may introduce variability in the results. Despite these limitations, our study serves as a foundation for future research endeavors aimed at validating our findings in larger, multicenter cohorts and exploring additional factors that may influence the prognostic significance of IHC markers in EC.

Conclusions

Although the current study could not definitively uncover an IHC marker that may effectively differentiate prognostic implications, our research efforts are ongoing in order to identify molecular markers that may better fulfill this objective. The use of tumor banking and collaborative efforts among different institutions should enhance the meaningfulness and statistical power of IHC assessment in a substantial percentage of early-stage endometrial malignancies. It is our belief that the molecular profiling of tumors in individual patients has the potential to enhance prognostication and customize therapy, hence enabling the development of more targeted and less harmful treatment approaches. The research suggests that immunohistochemistry may be used to evaluate somatic p53 mutations in endometrial samples, regardless of their histological characteristics. This finding may contribute to the identification of aggressive tumors, thereby facilitating the customization of surgical procedures, the development of appropriate adjuvant treatments and the establishment of effective follow-up protocols. Immunohistochemistry including the expression of all four proteins, together with methylation of the *MLH1* promoter, continues to be the preferred diagnostic method due to its reproducibility, cost-effectiveness, and suitability for regular clinical use. The use of molecular categorization, such as MMRd tumors, has played a crucial role in the determination of prognosis.

Funding

This research received no external funding.

Institutional Review Board Statement

The study was conducted in accordance with the Declaration of Helsinki and approved by the Institutional Ethics Committee of Prof. Dr. Panait Sîrbu Clinical Hospital of Obstetrics and Gynecology, Bucharest, Romania.

Informed Consent Statement

Informed consent was obtained from all subjects involved in the study.

Data Availability Statement

The data are contained within the article.

Conflict of interests

The authors declare no conflict of interests.

References

[1] American Cancer Society (ACS). Cancer facts & figures 2022. ACS, Atlanta, GA, USA, 2022. https://www.cancer.org/research/cancer-facts-statistics/all-cancer-facts-figures/cancer-facts-figures-2022.html

[2] Burris HA 3rd. Docetaxel (Taxotere) plus trastuzumab (Herceptin) in breast cancer. Semin Oncol, 2001, 28(1 Suppl 3):38–44. https://doi.org/10.1053/sonc.2001.22815 PMID: 11301373

[3] Creasman WT, Morrow CP, Bundy BN, Homesley HD, Graham JE, Heller PB. Surgical pathologic spread patterns of endometrial cancer: a Gynecologic Oncology Group study. Cancer, 1987, 60(8 Suppl):2035–2041. https://doi.org/10.1002/1097-0142(19901015)60:8+<2035::aid-cncr2820601515>3.0.co;2-8 PMID: 3652025

[4] Lu KH, Broaddus RR. Endometrial cancer. N Engl J Med, 2020, 383(21):2053–2064. https://doi.org/10.1056/NEJMra1514010 PMID: 33207095

[5] Giaquinto AN, Broaddus RR, Jemal A, Siegel RL. The changing landscape of gynecologic cancer mortality in the United States. Obstet Gynecol, 2022, 139(3):440–442. https://doi.org/10.1097/AOG.0000000000004676 PMID: 35115431 PMCID: PMC8857029

[6] Cancer Genome Atlas Research Network; Kandoth C, Schultz N, Cherniack AD, Akbani R, Liu Y, Shen H, Robertson AG, Pashtan I, Shen R, Benz CC, Yau C, Laird PW, Ding L, Zhang W, Mills GB, Kucherlapati R, Mardis ER, Levine DA. Integrated genomic characterization of endometrial carcinoma. Nature, 2013, 497(7447):67–73. https://doi.org/10.1038/nature12113 PMID: 23636398 PMCID: PMC3704730

[7] Talhouk A, McConechy MK, Leung S, Li-Chang HH, Kwon JS, Melnyk N, Yang W, Senz J, Boyd N, Karnezis AN, Huntsman DG, Gilks CB, McAlpine JN. A clinically applicable molecular-based classification for endometrial cancers. Br J Cancer, 2015, 113(2):299–310. https://doi.org/10.1038/bjc.2015.190 PMID: 26172027 PMCID: PMC4506381

[8] Talhouk A, McConechy MK, Leung S, Yang W, Lum A, Senz J, Boyd N, Pike J, Anglesio M, Kwon JS, Karnezis AN, Huntsman DG, Gilks CB, McAlpine JN. Confirmation of ProMisE: a simple, genomics-based clinical classifier for endometrial cancer. Cancer, 2017, 123(5):802–813. https://doi.org/10.1002/cncr.30496 PMID: 28061006

[9] Meyer LA, Broaddus RR, Lu KH. Endometrial cancer and Lynch syndrome: clinical and pathologic considerations. Cancer Control, 2009, 16(1):14–22. https://doi.org/10.1177/107327480901600103 PMID: 19078925 PMCID: PMC3693757

[10] Fishel R, Kolodner RD. Identification of mismatch repair genes and their role in the development of cancer. Curr Opin Genet Dev, 1995, 5(3):382–395. https://doi.org/10.1016/0959-437x(95)80055-7 PMID: 7549435

[11] Singh N, Piskorz AM, Bosse T, Jimenez-Linan M, Rous B, Brenton JD, Gilks CB, Köbel M. p53 immunohistochemistry is an accurate surrogate for *TP53* mutational analysis in endometrial carcinoma biopsies. J Pathol, 2020, 250(3):336–345. https://doi.org/10.1002/path.5375 PMID: 31829441

[12] Jumaah AS, Salim MM, Al-Haddad HS, McAllister KA, Yasseen AA. The frequency of *POLE*-mutation in endometrial carcinoma and prognostic implications: a systemic review and meta-analysis. J Pathol Transl Med, 2020, 54(6):471–479. https://doi.org/10.4132/jptm.2020.07.23 PMID: 32867011 PMCID: PMC7674757

[13] Li M, Zhao L, Qi W, Shen D, Li X, Wang J, Wei L. Clinical implications and prognostic value of five biomarkers in endometrial carcinoma. Chin-Ger J Clin Oncol, 2013, 12(12):586–591. https://doi.org/10.1007/s10330-013-1229-4 https://link.springer.com/article/10.1007/s10330-013-1229-4

[14] Gossett DR, Alo P, Bristow RE, Galati M, Kyshtoobayeva A, Fruehauf J, Montz FJ. Inability of immunohistochemistry to predict clinical outcomes of endometrial cancer patients. Int J Gynecol Cancer, 2004, 14(1):145–151. https://doi.org/10.1111/j.1048-891x.2004.014028.x PMID: 14764043

[15] Leach FS, Polyak K, Burrell M, Johnson KA, Hill D, Dunlop MG, Wyllie AH, Peltomaki P, de la Chapelle A, Hamilton SR, Kinzler KW, Vogelstein B. Expression of the human mismatch repair gene *hMSH2* in normal and neoplastic tissues. Cancer Res, 1996, 56(2):235–240. PMID: 8542572

[16] Fishel R, Lescoe MK, Rao MR, Copeland NG, Jenkins NA, Garber J, Kane M, Kolodner R. The human mutator gene homolog *MSH2* and its association with hereditary nonpolyposis colon cancer. Cell, 1993, 75(5):1027–1038. https://doi.org/10.1016/0092-8674(93)90546-3 PMID: 8252616

[17] Goodfellow PJ, Billingsley CC, Lankes HA, Ali S, Cohn DE, Broaddus RJ, Ramirez N, Pritchard CC, Hampel H, Chassen AS, Simmons LV, Schmidt AP, Gao F, Brinton LA, Backes F, Landrum LM, Geller MA, DiSilvestro PA, Pearl ML, Lele SB, Powell MA, Zaino RJ, Mutch D. Combined microsatellite instability, *MLH1* methylation analysis, and immunohistochemistry for Lynch syndrome screening in endometrial cancers from GOG210: an NRG Oncology and Gynecologic Oncology Group study. J Clin Oncol, 2015, 33(36):4301–4308. https://doi.org/10.1200/JCO.2015.63.9518 PMID: 26552419 PMCID: PMC4678181

[18] Devlin LA, Graham CA, Price JH, Morrison PJ. Germline *MSH6* mutations are more prevalent in endometrial cancer patient cohorts than hereditary non polyposis colorectal cancer cohorts. Ulster Med J, 2008, 77(1):25–30. PMID: 18269114 PMCID: PMC2397009

[19] Black D, Soslow RA, Levine DA, Tornos C, Chen SC, Hummer AJ, Bogomolniy F, Olvera N, Barakat RR, Boyd J. Clinicopathologic significance of defective DNA mismatch repair in endometrial carcinoma. J Clin Oncol, 2006, 24(11):1745–1753. https://doi.org/10.1200/JCO.2005.04.1574 PMID: 16549821

[20] Garg K, Shih K, Barakat R, Zhou Q, Iasonos A, Soslow RA. Endometrial carcinomas in women aged 40 years and younger: tumors associated with loss of DNA mismatch repair proteins comprise a distinct clinicopathologic subset. Am J Surg Pathol, 2009, 33(12):1869–1877. https://doi.org/10.1097/PAS.0b013e3181bc9866 PMID: 19898223

[21] Mackay HJ, Gallinger S, Tsao MS, McLachlin CM, Tu D, Keiser K, Eisenhauer EA, Oza AM. Prognostic value of microsatellite instability (MSI) and PTEN expression in women with endometrial cancer: results from studies of the NCIC Clinical Trials Group (NCIC CTG). Eur J Cancer, 2010, 46(8):1365–1373. https://doi.org/10.1016/j.ejca.2010.02.031 PMID: 20304627

[22] Diaz-Padilla I, Romero N, Amir E, Matias-Guiu X, Vilar E, Muggia F, Garcia-Donas J. Mismatch repair status and clinical outcome in endometrial cancer: a systematic review and meta-analysis. Crit Rev Oncol Hematol, 2013, 88(1):154–167. https://doi.org/10.1016/j.critrevonc.2013.03.002 PMID: 23562498

[23] Newtson AM, Salinas EA, McDonald ME, Miller M, Keeney M, Devor E, Gonzalez-Bosquet J. Identification of clinical-molecular characteristics associated with recurrent endometrial cancer. Abstracts presented at the 2017 Western Association of Gynecologic Oncologists (WAGO) Annual Meeting, Gynecol Oncol, 2017, 147(1):200. https://doi.org/10.1016/j.ygyno.2017.07.035 https://www.gynecologiconcology-online.net/article/S0090-8258(17)31052-1/abstract

[24] Zighelboim I, Goodfellow PJ, Gao F, Gibb RK, Powell MA, Rader JS, Mutch DG. Microsatellite instability and epigenetic inactivation of *MLH1* and outcome of patients with endometrial carcinomas of the endometrioid type. J Clin Oncol, 2007, 25(15):2042–2048. https://doi.org/10.1200/JCO.2006.08.2107 PMID: 17513808

[25] McMeekin DS, Tritchler DL, Cohn DE, Mutch DG, Lankes HA, Geller MA, Powell MA, Backes FJ, Landrum LM, Zaino R, Broaddus RD, Ramirez N, Gao F, Ali S, Darcy KM, Pearl ML, DiSilvestro PA, Lele SB, Goodfellow PJ. Clinicopathologic significance of mismatch repair defects in endometrial cancer: an NRG Oncology/Gynecologic Oncology Group study. J Clin Oncol, 2016, 34(25):3062–3068. https://doi.org/10.1200/JCO.2016.67.8722 PMID: 27325856 PMCID: PMC5012715

[26] Cosgrove CM, Cohn DE, Hampel H, Frankel WL, Jones D, McElroy JP, Suarez AA, Zhao W, Chen W, Salani R, Copeland LJ, O'Malley DM, Fowler JM, Yilmaz A, Chassen AS, Pearlman R, Goodfellow PJ, Backes FJ. Epigenetic silencing of *MLH1* in endometrial cancers is associated with larger tumor volume, increased rate of lymph node positivity and reduced recurrence-free survival. Gynecol Oncol, 2017, 146(3):588–595. https://doi.org/10.1016/j.ygyno.2017.07.003 PMID: 28709704 PMCID: PMC5601318

[27] Tangjitgamol S, Kittisiam T, Tanvanich S. Prevalence and prognostic role of mismatch repair gene defect in endometrial cancer patients. Tumour Biol, 2017, 39(9):1010428317725834. https://doi.org/10.1177/1010428317725834 PMID: 28946809

[28] Esselen KM, Boruta DM, del Carmen M, Schorge JO, Goodman A, Growdon WB. Defining prognostic variables in recurrent endometrioid endometrial cancer: a 15-year single-institution review. Int J Gynecol Cancer, 2011, 21(6):1078–1083. https://doi.org/10.1097/IGC.0b013e31821872f4 PMID: 21633304

[29] McConechy MK, Talhouk A, Leung S, Chiu D, Yang W, Senz J, Reha-Krantz LJ, Lee CH, Huntsman DG, Gilks CB, McAlpine JN. Endometrial carcinomas with *POLE* exonuclease domain mutations have a favorable prognosis. Clin Cancer Res, 2016, 22(12):2865–2873. https://doi.org/10.1158/1078-0432.CCR-15-2233 PMID: 26763250

[30] Creasman WT, Soper JT, McCarty KS Jr, McCarty KS Sr, Hinshaw W, Clarke-Pearson DL. Influence of cytoplasmic steroid receptor content on prognosis of early stage endometrial carcinoma. Am J Obstet Gynecol, 1985, 151(7):922–932. https://doi.org/10.1016/0002-9378(85)90671-4 PMID: 3985057

[31] Hanekamp EE, Gielen SCJP, Smid-Koopman E, Kühne LC, de Ruiter PE, Chadha-Ajwani S, Brinkmann AO, Grootegoed JA, Burger CW, Huikeshoven FJ, Blok LJ. Consequences of loss of progesterone receptor expression in development of invasive endometrial cancer. Clin Cancer Res, 2003, 9(11):4190–4199. PMID: 14519645

[32] Miyamoto T, Watanabe J, Hata H, Jobo T, Kawaguchi M, Hattori M, Saito M, Kuramoto H. Significance of progesterone receptor-A and -B expressions in endometrial adenocarcinoma. J Steroid Biochem Mol Biol, 2004, 92(3):111–118. https://doi.org/10.1016/j.jsbmb.2004.07.007 PMID: 15555905

[33] Jeon YT, Park IA, Kim YB, Kim JW, Park NH, Kang SB, Lee HP, Song YS. Steroid receptor expressions in endometrial cancer: clinical significance and epidemiological implication. Cancer Lett, 2006, 239(2):198–204. https://doi.org/10.1016/j.canlet.2005.08.001 PMID: 16168561

[34] Jongen V, Briët J, de Jong R, ten Hoor K, Boezen M, van der Zee A, Nijman H, Hollema H. Expression of estrogen receptor-alpha and -beta and progesterone receptor-A and -B in a large cohort of patients with endometrioid endometrial cancer. Gynecol Oncol, 2009, 112(3):537–542. https://doi.org/10.1016/j.ygyno.2008.10.032 PMID: 19108875

[35] Vermij L, Léon-Castillo A, Singh N, Powell ME, Edmondson RJ, Genestie C, Khaw P, Pyman J, McLachlin CM, Ghatage P, de Boer SM, Nijman HW, Smit VTHBM, Crosbie EJ, Leary A, Creutzberg CL, Horeweg N, Bosse T; TransPORTEC consortium. p53 immunohistochemistry in endometrial cancer: clinical and molecular correlates in the PORTEC-3 trial. Mod Pathol, 2022, 35(9):1475–1483. https://doi.org/10.1038/s41379-022-01102-x PMID: 35752743 PMCID: PMC7613653

[36] Tresa A, Sambasivan S, Rema P, Dinesh D, Sivaranjith J, Nair SP, Mathew A, Ammu JV, Kumar A. Clinical profile and survival outcome of endometrial cancer with *p53* mutation. Indian J Surg Oncol, 2022, 13(3):580–586. https://doi.org/10.1007/s13193-022-01523-9 PMID: 36187514 PMCID: PMC9515295

Corresponding author

Maria Victoria Olinca, Associate Professor, MD, PhD, Department of Anatomical Pathology, Carol Davila University of Medicine and Pharmacy, 37 Dionisie Lupu Street, Sector 2, 020021 Bucharest, Romania; Phone +40723–510 631, e-mail: maria.olinca@umfcd.ro

Received: January 20, 2024

Accepted: May 10, 2024