

LETTER TO THE EDITOR

Vascular foam cell dots in thyroid angioma-like lesions: fine needle aspiration or contrast substance-related lesions?

ADRIANA HANDRA-LUCA^{1,2)}, HABIB MOHAMED BEN ROMDHANE¹⁾

¹⁾APHP GHU Avicenne, Bobigny, France

²⁾University Paris Nord, UFR SMBH Bobigny, France

Keywords: thyroid, blood vessel, foam cell dot, treatment.

To the Editor,

Sir,

Thyroid vascular proliferation possibly related to post-fine needle aspiration (FNA) regeneration is rarely reported [1]. We would like to point out an additional lesion that may be observed in post-regenerative angioma-type lesions, those of subendothelial foam cell dots [2]. We have detected such lesions in surgically resected thyroid adenomas (one case) or adenoma-like nodules in goiter (five cases). FNA was performed in two cases; contrast-substance injection for imaging was performed in four cases. Prothrombin time and cephalin-activated ratio were abnormal in two cases. The age range was 61–82 years. The medical history revealed: chemotherapy (lung adenocarcinoma – one case), Sandostatin treatment (pancreatic neuroendocrine carcinoma – one case), arterial hypertension (five cases), dyslipidemia (three cases), diabetes (one case) and cardiac stent procedure (one case). The angioma-like aggregates (1–12/thyroid specimen) were located in the hyperplastic adenoma-type nodules (in goiter) and in the adenoma. They measured 1–10 mm. Vascular parietal, subendothelial, non-obliterating foam cell dots were seen in these lesions (Figure 1). Rare sheets of 2–5 macrophages were also noted in two nodules.

Here we report vascular, subendothelial foam cell dots in thyroid angioma-like lesions detected in adenoma or goiter adenoma-like nodules. These lesions may belong to the same spectrum of lesions as those reported by Sapino *et al.*, but of “onion-skin” appearance, involving also thyrocytes [3]. The results of this study suggest that such lesions may occur also independently from a history of FNA procedures. Factors such as age-related vascular changes, dyslipidemia or clotting disorders may interfere with the genesis of these lesions along with contrast-substance injection. To mention would be the presence of similar lesions in schwannomas [4], the common medical history elements with the present series of cases being the puncture and contrast substance injection procedures.

In conclusion, vascular, subendothelial foam cell dots may be detected in angioma-like nodules of thyroid adenoma or goiter. The precise background is difficult to specify, possibly multifactorial.

Disclosure statement

The authors do not have conflicts of interest.

Funding sources

There was no funding source.

Acknowledgments

The authors thank Professor Anna Sapino and Antonella Meloni, Dr Salvador Diaz-Cano, Dr Stergios Polyzos, Isabelle Alexandre, Dr Gilles Despréaux, Dr Thomas Leger, as well as Pierre Pausicles, Stéphane Chambris, Nicolas Luppino, Valérie Ipotesi, Nathalie Delva, Christine Alvares, the NCA/Avicenne, CMDP/APHP and BIUM teams.

References

- [1] Tsang K, Duggan MA. Vascular proliferation of the thyroid. A complication of fine-needle aspiration. Arch Pathol Lab Med, 1992, 116(10):1040–1042.
- [2] Cotran RS, Kumar V, Collins T. Robbins pathologic basis of disease. 6th edition, W.B. Saunders Co., Philadelphia, 1999.
- [3] Sapino A, Papotti M, Macri L, Satolli MA, Bussolati G. Intranodular reactive endothelial hyperplasia in adenomatous goiter. Histopathology, 1995, 26(5):457–462.
- [4] Taconet S, Gorphe P, Handra-Luca A. Adult sublingual schwannoma with angioma-like features and foam cell vascular change. Folia Neuropathol, 2014, 52(3):298–302.

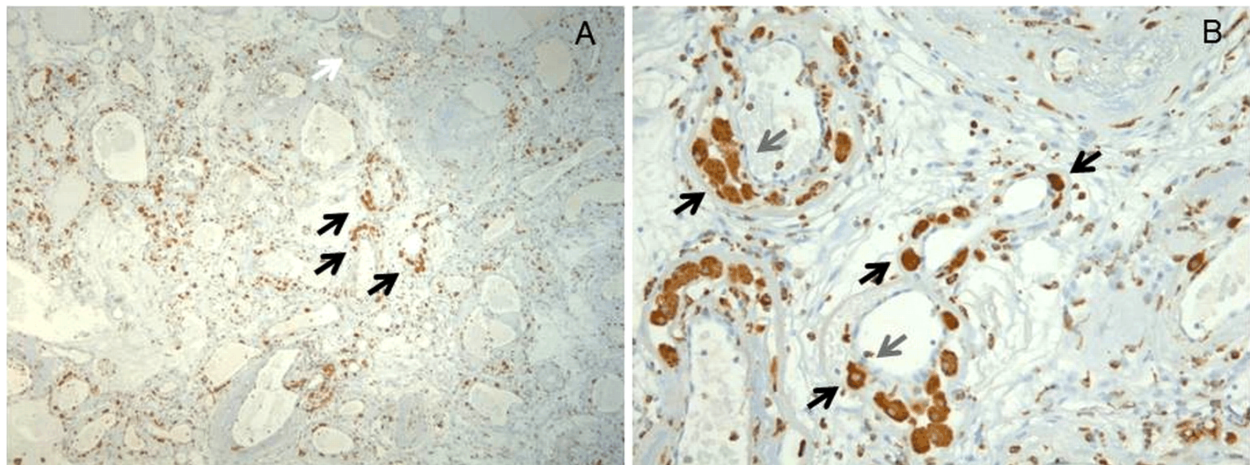


Figure 1 – Perivascular, subendothelial foam cell dots were detected in angioma-like lesions of thyroid nodules: (A and B) Foam cell dots/black arrow, endothelium/gray arrow, thyroid vesicles/white arrow. Hematoxylin–Eosin staining: (A) $\times 50$; (B) $\times 400$.

Corresponding author

Adriana Handra-Luca, MD, PhD, Service d'Anatomie pathologique, APHP GHU Avicenne, Université Paris Nord Sorbonne Cité, 125 rue Stalingrad, 93009 Bobigny, France; Phone 0033 148955555, deck 52047, secretariat 55601, Fax 0033 1489555602 / 5480, e-mails: adriana.handra-luca@aphp.fr, adriana.handra-luca@hotmail.com, adriana.handra-luca@univ-paris13.fr

Received: December 27, 2018

Accepted: April 4, 2019