

UPA effects on endometrium – what is the significance?

LIANA PLEȘ^{1,2)}, ROMINA-MARINA SIMA^{1,2)}, DELIA CARP²⁾, COSMIN FLORESCU³⁾,
 MIHAI CORNEL TRAIAN DIMITRIU^{1,3)}, CRÎNGU ANTONIU IONESCU^{1,3)}

¹⁾Department of Obstetrics–Gynecology and Neonatology, "Carol Davila" University of Medicine and Pharmacy, Bucharest, Romania

²⁾Department of Obstetrics and Gynecology, "Bucur" Maternity, "St. John" Clinical Hospital, Bucharest, Romania

³⁾Department of Obstetrics and Gynecology, "St. Pantelimon" Emergency Clinical Hospital, Bucharest, Romania

Abstract

Introduction: Selective progesterone receptor modulators (SPRMs), such as Mifepristone, Asoprisnil, Ulipristal acetate (UPA) and Vilaprisan, were tested for their antiproliferative effects on uterine fibroids. In Romania, despite the UPA availability, physicians remained reserved on the lack of experience and concerns about the safety of the drug on endometrium. **Patients, Materials and Methods:** We performed an observational study on premenopausal women with symptomatic uterine fibroids. The patients received UPA in doses of 5 mg for 12–13 weeks. The fibroids dimensions and endometrium thickness were recorded at before and after the treatment. The pathological samples were assessed by two pathologists, and they recorded progesterone receptor modulator associated endometrial changes (PAEC) as extensive PAEC (EPAEC), minimally PAEC (MPAEC), absent PAEC (APAEC) and Ki67 immunoexpression in endometrium. **Results:** A number of 57 women were introduced in our study and we had a dropout of one patient. The fibroid dimensions and endometrial thickness decreased after UPA. The pathological exam of the endometrium revealed: APAEC in 26.8% of cases, MPAEC in 60.7% of cases and EPAEC in 12.5% of cases. EPAEC were more frequent in patients with larger fibroids. PAEC had a strong correlation with Ki67 index ($p \leq 0.01$). PAEC were more frequent in older women ($p \leq 0.01$). Ki67 had a higher expression in EPAEC – mean: 69% (range: 63–75%), standard deviation (SD): 3.95. **Conclusions:** UPA treatment decreased fibroids dimension and improved patients' symptoms in our study. EPAEC was associated with abundant Ki67 antigen. UPA administration for three months is a safe method without endometrial atypia but longer protocols require extended studies about the proliferative potential of the endometrium.

Keywords: Ulipristal acetate (UPA), endometrium, fibroids, Ki67 immunoexpression.

Introduction

Uterine fibroids are the most common benign tumors in reproductive age women, which affect about 24 million women in Europe [1]. Although not all are symptomatic in many cases, the symptoms can affect life quality, reproduction and can be invalidating. The symptoms that prompt patients to seek medical treatment are usually heavy menstrual bleeding or menorrhagia. So far, the curative treatment for symptomatic cases was surgical with or without conservative aim depending on many factors. For young women who did not accomplish their reproductive aims, surgery is not an acceptable alternative and other medical non-surgical methods are required [2].

Selective progesterone receptor modulators (SPRMs) were tested since 2002 [3] for their antiproliferative effects on uterine fibroids and since many studies reported benefits in uterine bleeding control and fibroids volume reduction [4]. SPRMs are a class of drugs that includes Mifepristone, Asoprisnil, Ulipristal acetate (UPA) and the new Vilaprisan who exhibits both agonist and antagonist effects on uterine progesterone receptors [5, 6].

UPA is an approved treatment for uterine fibroids since 2012. The course of treatment consists in 12–13 weeks of 5/10 mg daily and its action on myometrium is antiproliferative, antifibrotic and proapoptotic, finally producing a fibroid volume reduction up to 45% [7].

The SPRMs specific endometrial changes were proved completely reversible after treatment but they remain one

of the main concerns when prescribing UPA. In Romania, despite the UPA is available, physicians remained reserved on the lack of experience and concerns about the safety of the drug on endometrium.

In the present study, we have proposed to evaluate the effects of UPA on uterine fibroids and the endometrium.

Patients, Materials and Methods

We performed an observational study on premenopausal women with symptomatic uterine fibroids. The study was conducted in two Units – one public ("Bucur" Maternity, "St. John" Clinical Hospital, Bucharest, Romania) and one private (Ego Metacs Medical Cabinet, Bucharest), between September 2014–May 2017. We obtained ethical approval and patient's informed consent for treatment and study.

The study included premenopausal women with uterine fibroids that either asked conservative management or exhibited abnormal menstrual patterns, mainly heavy bleeding preoperative. They received UPA in doses of 5 mg daily, starting with the first or second menstrual day, for 12–13 weeks.

At the beginning of the UPA, the patients undergone a clinical check, blood count and endometrial biopsy either by dilatation and curettage (D&C) or by hysteroscopy. Transvaginal ultrasound was performed by three trained experienced sonographers and the uterine fibroids were mapped, and measured. Endometrial thickness was recorded

as well. In order to reduce biases and avoid interobservers variability for the outcome, we considered only the largest diameter of the largest fibroid and the same patient was examined by the same doctor at the beginning and at the end.

During the treatment, the patients kept a chart of the vaginal bleeding and other symptoms related to UPA.

At the end of the treatment courses, the patients were examined both clinical and by ultrasound. The fibroids dimensions and endometrium thickness were recorded. Blood count and endometrial biopsy were performed by D&C or at the surgery time, if the patients undergone hysterectomy. The biological material harvested by biopsy was fixed in 10% formalin, included in paraffin, and stained with Hematoxylin–Eosin (HE). The pathological samples were assessed by two pathologists. At the treatment course interruption, all the endometrial probes undergone evaluation of Ki67 immunoexpression.

The primary study objective was to assess UPA effect and safety on endometrium in terms of premalignant or malignant lesions absence and to assess cell proliferation within the stromal and glandular compartments of the endometrium by Ki67 immunoexpression. For this, 3 µm-thick sections were made of the paraffin material, which were passed on poly-L-lysine slides. Then, the biological material was processed into the usual immunohistochemical technique, using the anti-Ki67 antibody (monoclonal mouse anti-human Ki67, clone MIB-1, 1:50 dilution, Dako) and 3,3'-Diaminobenzidine (DAB) chromogen.

For statistic reasons, we divided the progesterone receptor modulator associated endometrial changes (PAEC) featuring endometrium in three groups: extensive PAEC (EPAEC), minimally PAEC (MPAEC) and absent PAEC (APAEC) changes. All samples had normal flat epithelium with ovalar nuclei and without nuclear atypia and rare mitoses.

EPAEC grouped endometrial samples with widespread cystic dilatation of glands with or without vascular thickening.

MPAEC exhibited several dilated, tortuous glands or partial dilated gland with normal vascular appearance.

APAEC showed no cystic dilated glands.

Secondary outcomes were fibroid dimensions reduction, bleeding control by amenorrhea and pregnancies.

The data were analyzed using Statistical Package for Social Sciences (SPSS) version 19.0. We analyzed the characteristics of all patients using descriptive statistic tests, then each group separately. Pearson's correlation was used as appropriate and two-sided *p*-values of <0.05 were considered to indicate statistical significance.

Results

A number of 57 women were introduced in our study and we had a dropout of one woman. The main group characteristics are illustrated in Table 1. The age of the patients included in our group varied between 26 and 50 years, the mean age being 37.75 years. Most women (80.7%) had the main symptom of repeated bleeding and only 17.3% infertility. Applying UPA treatment resulted in a significant reduction of the uterine fibroids, some disappearing altogether. Also, a reduction in endometrial thickness following UPA treatment was also observed.

Table 1 – The study group characteristics

Group characteristics		
Age [years]	37.75 years (mean)	(min. 26 years, max. 50 years, SD: 6.17)
Symptoms	80.7%	19.3%
bleeding/infertility	bleeding	infertility
Endometrial thickness before UPA [mm]	9.82 mm (mean)	(min. 5 mm, max. 19 mm, SD: 3.22)
Endometrial thickness after UPA [mm]	8.81 mm (mean)	(min. 3.5 mm, max. 17 mm, SD: 2.87)
Fibroids dimensions before UPA [cm]	4.43 cm (mean)	(min. 1.3 cm, max. 12 cm, SD: 4.43)
Fibroids dimensions after UPA [cm]	3.05 cm (mean)	(min. 0 cm, max. 10 cm, SD: 1.66)
Bleeding control	Yes 83.9%	No 16.1%
Surgery	Yes 12.5%	No 87.5%

UPA: Ulipristal acetate; SD: Standard deviation.

All patients underwent endometrial biopsy before UPA treatment. We observed that the pathological results distribution was: adenomatous–polypoid hyperplasia in 29.8% of cases, endometrial polyps in 17.5% of cases, simple hyperplasia 38.6% cases and disharmonic endometrium in 14% cases. The pathological exam correlated with endometrial thickness before procedure ($p \leq 0.01$).

In this study, all patients underwent three courses of treatment with UPA. The fibroid dimensions and endometrial thickness decreased after UPA. After treatment, we observed that pathological exam revealed: APAEC in 26.8% of cases, MPAEC in 60.7% of cases and EPAEC in 12.5% of cases (Figure 1, a–d). We identified that, according to PAEC distribution from our study group, we have the following results (Table 2).

Table 2 – Group characteristics according to PAEC distribution

Group characteristics	APAEC	MPAEC	EPAEC
Age [years]	36.46 years (mean) (min. 27 years, max. 49 years, SD: 6.31)	37.64 years (mean) (min. 26 years, max. 50 years, SD: 6.58)	37.87 years (mean) (min. 37.75 years, max. 38 years, SD: 0.17)
Endometrial thickness before UPA [mm]	9.02 mm (mean) (min. 5 mm, max. 17.5 mm, SD: 3.26)	10.26 mm (mean) (min. 6.5 mm, max. 19 mm, SD: 3.47)	9.64 mm (mean) (min. 7.5 mm, max. 12 mm, SD: 1.67)
Endometrial thickness after UPA [mm]	8.18 mm (mean) (min. 6 mm, max. 11 mm, SD: 3.26)	8.87 mm (mean) (min. 5 mm, max. 17 mm, SD: 2.94)	8.18 mm (mean) (min. 6 mm, max. 11 mm, SD: 1.75)
Fibroids dimensions before UPA [cm]	3.98 cm (mean) (min. 1.3 cm, max. 6 cm, SD: 1.08)	4.6 cm (mean) (min. 1.67 cm, max. 12 cm, SD: 1.91)	4.22 cm (mean) (min. 2.88 cm, max. 7 cm, SD: 1.42)
Fibroids dimensions after UPA [cm]	2.68 cm (mean) (min. 1.1 cm, max. 4.8 cm, SD: 0.94)	3.09 cm (mean) (min. 0 cm, max. 10 cm, SD: 1.96)	3.65 cm (mean) (min. 2 cm, max. 5.4 cm, SD: 1.18)
Ki67 labeling index	34.07% (mean) (min. 30%, max. 38%, SD: 2.712)	48.5% (mean) (min. 21%, max. 65%, SD: 7.042)	69% (mean) (min. 63%, max. 75%, SD: 3.95)

UPA: Ulipristal acetate; PAEC: Progesterone receptor modulator associated endometrial changes; APAEC: Absent PAEC; MPAEC: Minimally PAEC; EPAEC: Extensive PAEC; SD: Standard deviation.

Sometimes, the endometrial glands appear cystic dilated, distorted, with less secretion inside. Also, few cells have been found in mitosis, both at the gland and stroma. In all examined courses, changes in endometrial glands after UPA treatment were benign. The endometrial vascular network appeared low, which explains the reduction of menstrual bleeding and tendency to amenorrhea in some patients.

The endometrial tree varied in microscopic appearance, depending on the age of the patients. In younger patients, it was rich in cells, with small inflammatory infiltrates and microhemorrhagia. In older patients, the stroma was poorer in cells, but richer in collagen fibers. We believe that the microscopic changes of the endometrium after treatment with UPA should be correlated with the menstrual cycle and the age of the patients.

From Table 2 is relevant that in our study EPAEC were more frequent in patients with larger fibroids. Using Pearson's correlation, we observed that PAEC had a strong correlation with Ki67 labeling index ($p \leq 0.01$). We also identified that patients age correlated with PAEC: PAEC were more frequent in older women ($p \leq 0.01$).

Using anti-Ki67 antibody immunomarking for all patients (Figure 2, a–d), it was observed that Ki67 labeling index was extensive in EPAEC (min. 63%) (Figure 3).

Regarding patients outcome, we observed that majority had symptoms control in 83.9% of cases after UPA treatment and only 12.5% of them underwent surgical intervention. We did not have any correlation between age, fibroid dimension, endometrium thickness, PAEC, Ki67 labeling index with surgical intervention or symptoms control.

Discussions

Studies have demonstrated that UPA promotes specific effects in uterine smooth cells, consisting in reducing proliferation and inducing apoptosis [8], which may explain the fibroid size reduction by up to 30%. Meanwhile, the effects of the SPRMs on normal endometrium through they can contribute to bleeding rapid arrest are still incompletely understood [6, 9–11].

UPA administration is associated with morphological changes of specific type that were not previously encountered and received a specific name from the specialists that studied the phenomenon: progesterone receptor modulator associated endometrial changes (PAEC). PAEC include cystic dilatation of the endometrial glands, and specific changes of the vascular aspects and fibroblasts, mimicking dilated cystic glandular endometrial hyperplasia. The mechanism by which this occurs is unknown [12].

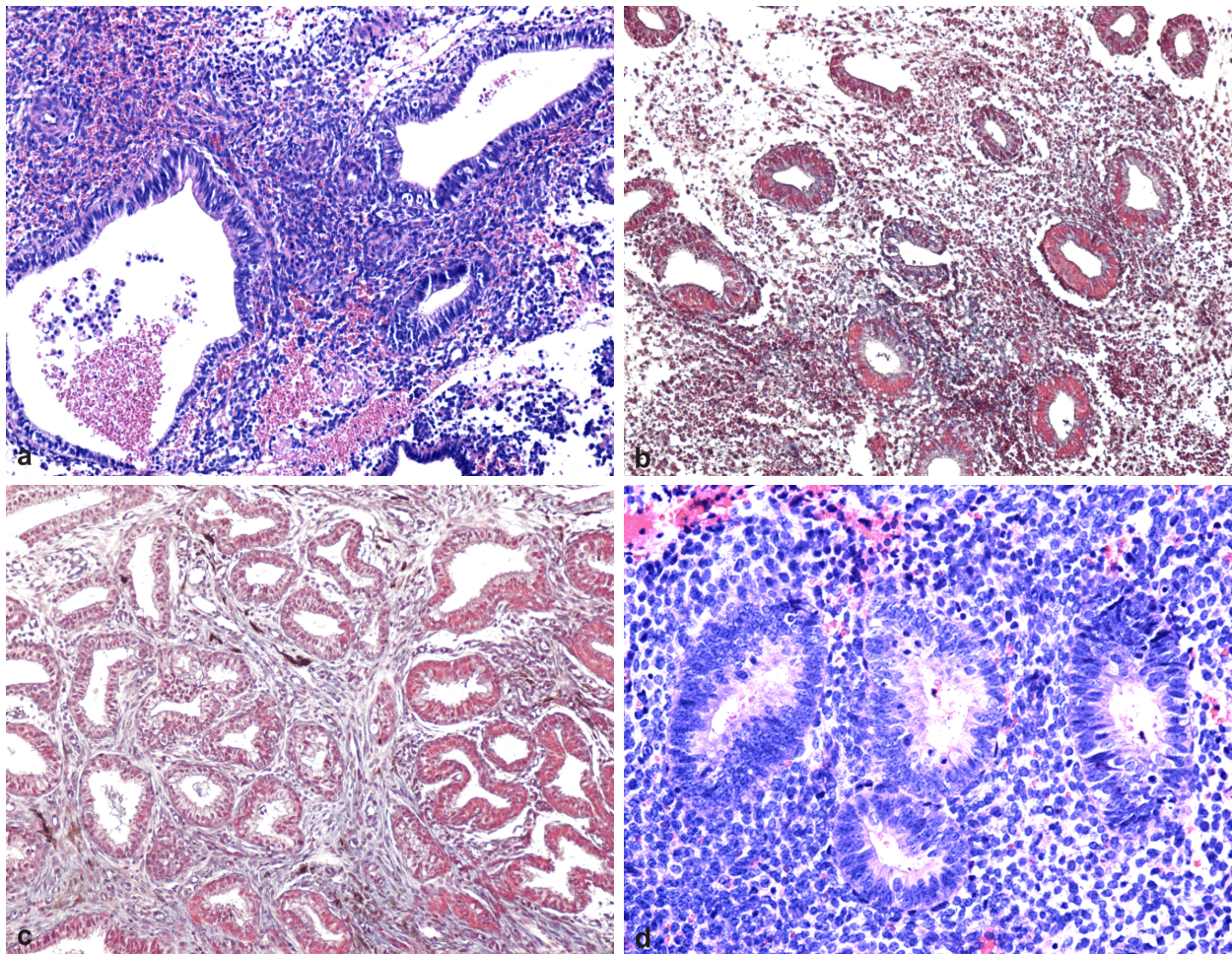


Figure 1 – Morphological appearance of the endometrium associated with SPRM administration: asymmetry of stromal and epithelial growth resulting in heterogeneous and extensive cystically dilated glands (a and b), admixed mitotic activity and secretory differentiation (c), and focal stromal breakdown (d). HE staining: (a–c) $\times 100$; (d) $\times 200$. SPRM: Selective progesterone receptor modulator; HE: Hematoxylin–Eosin.

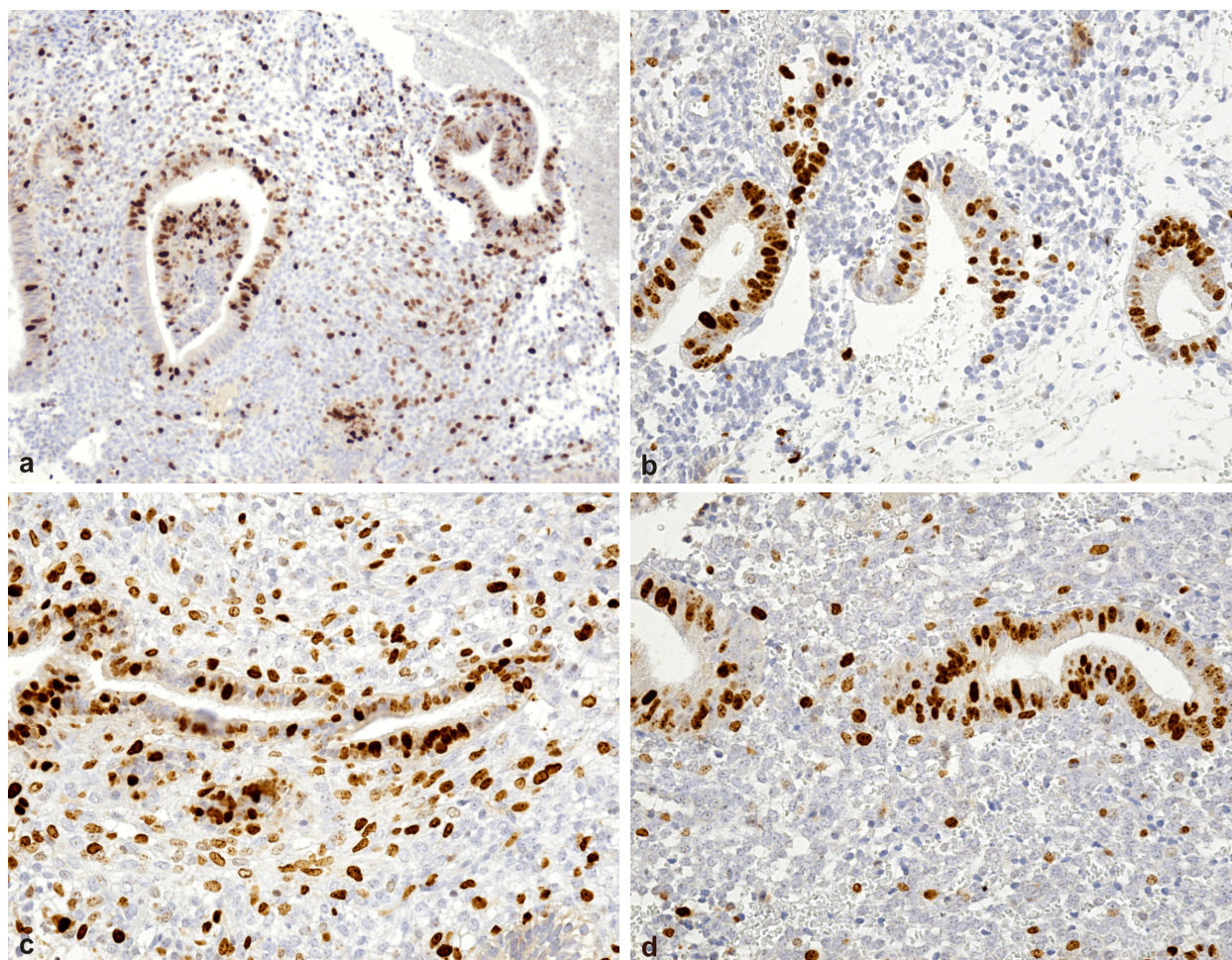


Figure 2 – Assessment of cell proliferation on immunostained endometrial samples: both endometrial epithelial and stromal cells exhibit nuclear immunoreactivity with antibodies against Ki67 protein – marker of cell proliferation; high Ki67 labeling index for both epithelial and stromal cells (a and b), and high Ki67 index for epithelial cells and low Ki67 index for stromal cells (c and d). Anti-Ki67 antibody immunomarking: (a) $\times 100$; (b–d) $\times 200$.

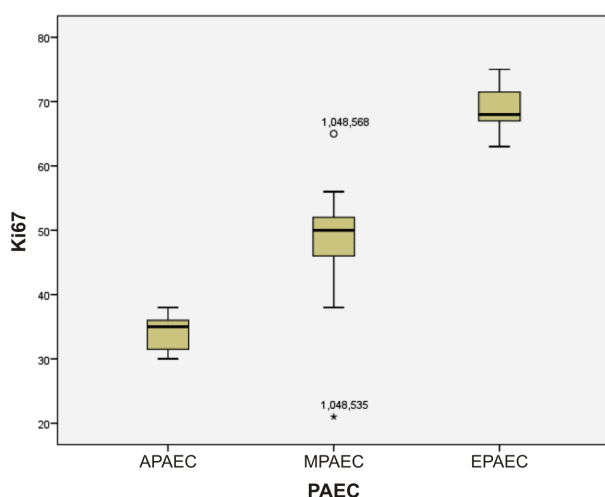


Figure 3 – Patients distribution according to PAEC and Ki67 labeling index. PAEC: Progesterone receptor modulator associated endometrial changes; APAEC: Absent PAEC; MPAEC: Minimally PAEC; EPAEC: Extensive PAEC.

Donnez *et al.* (2012) reported that a 3-month course of UPA induces PAEC in 2/3 of treated women. Following the endometrium aspects, they found that six months after the treatment arrest no further specific changes were

present, so PAEC are completely reversible [7, 13]. The incidence of endometrial hyperplasia after two courses of treatment was less than 1%, which is about the same incidence as in women of the same age that underwent endometrium biopsies for abnormal uterine bleeding [14].

The endometrial thickness before and after UPA treatment was evaluated in a few studies but it was observed that it decreased [14, 15]. We have the same report in our study.

The histological appearance of PAEC reveals inactive and proliferating epithelium, asymmetry of stromal and epithelial growth with prominent cystically dilated glands. This kind of pattern has been observed in almost 60% of patients treated with UPA for three months. These changes disappear after treatment is stopped and menstruation occurs and they should not be confused with unopposed estrogen effect or endometrial hyperplasia. In our study, PAEC were more frequent in older women ($p \leq 0.01$), possible explained by a more instable epithelium.

The Ki67 antigen is a nuclear protein with variable levels during the cell life cycle: high levels in active phases of cell cycle (G1, S, G2, and M phases), low levels in G0 and absent in rest phase. Its expression is associated with tumor cell proliferation and growth;

therefore, it is used as a proliferation marker in routine pathological investigation [16].

The Ki67 protein is extensively used as a prognostic and predictive marker for cancer diagnosis and treatment.

Although many studies were dedicated to identify the correlation of Ki67 levels in different clinico-pathological types of cervical carcinoma, in order to assess the prognosis of cervical cancer, the relationships between them are not clear [17–19]. In a recent study, the authors investigated the relationship of Ki67 and FasL (a member of the tumor necrosis factor family) and cervical cancer. The study advanced the hypothesis that the proliferative and invasive capacities of the malignant cells are promoted by cathepsin activity of tumor-associated macrophages Ki67 induced [20].

In our study, we found no endometrial atypia but high percentage of Ki67. The question is that it can be or not an index for progression towards more severe lesions of the endometrium – comparison to Ki67 presence in other premalignancies or normal epithelium and from here the need to follow-up whenever radical surgery is not involved?

In a study, there was no evidence that SPRMs-induced cell proliferation rates are significantly higher than those in endometrium secretory phase are. The levels of Ki67 labeling index were lower than those in the proliferative phase are in both compartments – stromal and epithelial. The findings are similar for the endometrium Ki67 levels observed also with other SPRMs [20, 21] but there are insufficient studies to investigate in a quantitative manner the Ki67 levels evolution in UPA administration. Low proliferative activity of the endometrium in UPA-treated women has not been elucidated. In our study, we observed that UPA decreased fibroids dimension and endometrial thickness. The incidence of extensive PAEC was 12.5% with a correspondent of Ki67 labeling index of 63%. EPAEC appeared more frequent in older woman but without important significance. PAEC had a strong correlation with Ki67 labeling index, overall without differences in endometrial proliferative or secretory phase.

The strengths of our study were: protocol respected with base biopsy and follow-up biopsy and endometrial cell proliferation evaluation. Strong point of it is the evaluation of Ki67 labeling index in all biopsies and a weak point is that it could be useful to do the same on biopsies before to compare. Limitations of our study were small group of patients because of reticence and treatment costs, no prolonged courses of treatment and no post-treatment distance follow-up.

✉ Conclusions

UPA treatment decreased fibroids dimension and improved patients' symptoms in our study. EPAEC was associated with abundant Ki67 antigen. The significance of this finding is not clear but was not associated with obvious atypia thus the progression toward malignancy is very unlikely. UPA administration for three months is a safe method without endometrial atypia but longer protocols require extended studies about the proliferative potential of the endometrium.

Conflict of interests

The authors declare that they have no conflict of interests.

References

- [1] Baird DD, Dunson DB, Hill MC, Cousins D, Schectman JM. High cumulative incidence of uterine leiomyoma in black and white women: ultrasound evidence. *Am J Obstet Gynecol*, 2003, 188(1):100–107.
- [2] Tropeano G, Amoroso S, Scambia G. Non-surgical management of uterine fibroids. *Hum Reprod Update*, 2008, 14(3): 259–274.
- [3] Chegini N, Ma C, Tang XM, Williams RS. Effects of GnRH analogues, 'add-back' steroid therapy, antiestrogen and anti-progestins on leiomyoma and myometrial smooth muscle cell growth and transforming growth factor-beta expression. *Mol Hum Reprod*, 2002, 8(12):1071–1078.
- [4] Chabbert-Buffet N, Meduri G, Bouchard P, Spitz IM. Selective progesterone receptor modulators and progesterone antagonists: mechanisms of action and clinical applications. *Hum Reprod Update*, 2005, 11(3):293–307.
- [5] Wagenfeld A, Saunders PT, Whitaker L, Critchley HO. Selective progesterone receptor modulators (SPRMs): progesterone receptor action, mode of action on the endometrium and treatment options in gynecological therapies. *Expert Opin Ther Targets*, 2016, 20(9):1045–1054.
- [6] Kalampokas T, Kamath M, Boutas I, Kalampokas E. Ulipristal acetate for uterine fibroids: a systematic review and meta-analysis. *Gynecol Endocrinol*, 2016, 32(2):91–96.
- [7] Donnez J, Tatarchuk TF, Bouchard P, Puscasiu L, Zakharenko NF, Ivanova T, Ivanova T, Ugocsai G, Mara M, Jilla MP, Bestel E, Terrill P, Osterloh I, Loumaye E; PEARL I Study Group. Ulipristal acetate *versus* placebo for fibroid treatment before surgery. *N Engl J Med*, 2012, 366(5):409–420.
- [8] Spitz IM. Progesterone antagonists and progesterone receptor modulators: an overview. *Steroids*, 2003, 68(10–13):981–993.
- [9] Mutter GL, Bergeron C, Deligdisch L, Ferenczy A, Glant M, Merino M, Williams AR, Blithe DL. The spectrum of endometrial pathology induced by progesterone receptor modulators. *Mod Pathol*, 2008, 21(5):591–598.
- [10] De Milliano I, Van Hattum D, Ket JCF, Huirne JAF, Hehenkamp WJK. Endometrial changes during ulipristal acetate use: a systematic review. *Eur J Obstet Gynecol Reprod Biol*, 2017, 214:56–64.
- [11] Simon J, Catherino WH, Segars J, Blakesley R, Chan A, Sniukiene V, Al-Hendy A. First US-based phase 3 study of ulipristal acetate (UPA) for symptomatic uterine fibroids (UF): results of VENUS-I. *Fertil Steril*, 2016, 106(3 Suppl):e376.
- [12] Williams AR, Bergeron C, Barlow DH, Ferenczy A. Endometrial morphology after treatment of uterine fibroids with the selective progesterone receptor modulator, ulipristal acetate. *Int J Gynecol Pathol*, 2012, 31(6):556–569.
- [13] Williams AR, Critchley HO, Osei J, Ingamells S, Cameron IT, Han C, Chwalisz K. The effects of the selective progesterone receptor modulator asoprisnil on the morphology of uterine tissues after 3 months treatment in patients with symptomatic uterine leiomyomata. *Hum Reprod*, 2007, 22(6):1696–1704.
- [14] Donnez J, Tomaszewski J, Vázquez F, Bouchard P, Lemieszczuk B, Baró F, Nouri K, Selvaggi L, Sadowski K, Bestel E, Terrill P, Osterloh I, Loumaye E; PEARL II Study Group. Ulipristal acetate *versus* leuprolide acetate for uterine fibroids. *N Engl J Med*, 2012, 366(5):421–432.
- [15] Milošević J, Djordjević B, Tasic MB. Influence of menopausal status on frequency and pathohistological features of endometrial hyperplasia and carcinoma in patients with abnormal uterine bleeding. *Acta Medica Medianae*, 2008, 47(2):33–37.
- [16] Fauser BC, Donnez J, Bouchard P, Barlow DH, Vázquez F, Arriagada P, Skouby SO, Palacios S, Tomaszewski J, Lemieszczuk B, Williams AR. Safety after extended repeated use of ulipristal acetate for uterine fibroids. *PLoS One*, 2017, 12(3):e0173523.
- [17] Kanthiya K, Khunnarong J, Tangjitgamol S, Puripat N, Tanvanich S. Expression of the p16 and Ki67 in cervical squamous intraepithelial lesions and cancer. *Asian Pac J Cancer Prev*, 2016, 17(7):3201–3206.

- [18] Xing Y, Wang C, Wu J. Expression of geminin, p16, and Ki67 in cervical intraepithelial neoplasm and normal tissues. *Medicine (Baltimore)*, 2017, 96(26):e7302.
- [19] Brăila AD, Krastev BM, Mihai-Zamfir E, Caraveţeanu DC, Al Krayem N, Brăila M, Velea R, Neacşu A. Uteroplacental apoplexy associated with invasive cervical neoplasm. *Rom J Morphol Embryol*, 2017, 58(4):1465–1470.
- [20] Pereira-Castro I, Costa AM, Oliveira MJ, Barbosa I, Rocha AS, Azevedo L, da Costa LT. Characterization of human NLZ1/ZNF703 identifies conserved domains essential for proper subcellular localization and transcriptional repression. *J Cell Biochem*, 2013, 114(1):120–133.
- [21] Wilkens J, Williams AR, Chwalisz K, Han C, Cameron IT, Critchley HO. Effect of asoprisnil on uterine proliferation markers and endometrial expression of the tumour suppressor gene, PTEN. *Hum Reprod*, 2009, 24(5):1036–1044.

Corresponding author

Romina-Marina Sima, Assistant Professor, MD, PhD, Department of Obstetrics–Gynecology and Neonatology, “Carol Davila” University of Medicine and Pharmacy, Department of Obstetrics and Gynecology, “Bucur” Maternity, “St. John” Clinical Hospital, 10 Între Gîrle Street, Sector 4, 040294 Bucharest, Romania; Phone +40741–071 243, e-mail: romina.sima@yahoo.es

Received: December 10, 2018

Accepted: March 1, 2019