

CASE REPORT

An unusual digital neural loop in a cadaver with bilateral high branching median nerves – case report

LOGAN BALE, NATASHA BRANDT, NAOMI ENOS

Department of Basic Sciences, University of Western States, Portland, Oregon, USA

Abstract

Digital neural loops are present in the palms of most individuals. They can arise within the common palmar digital nerves (CPDNs) or proper palmar digital nerves (PPDNs). Typically, common palmar digital arteries (CPDAs) pass through digital neural loops, however there are reports of loops forming around the superficial palmar arch or proper palmar digital arteries (PPDAs). We describe an unusual digital neural loop that involved both a CPDN and a PPDN. To our knowledge, this is the first documented case of a digital neural loop of this type and therefore anatomists and surgeons may benefit from an awareness of its existence. A modification to a current classification system for digital neural loops is presented to include this novel loop. Interestingly, the cadaver documented in this report featured a high division of the median nerve in each forearm. On both sides, the ulnar component of the bifid median nerve followed an intramuscular course in which it pierced the flexor digitorum superficialis and then continued into the palm as the 3rd CPDN. A brief review of the literature is provided for both digital neural loops and the high division of the median nerve variant. Documented muscle associations noteworthy to the bifid median nerve are discussed. Developmental connections, if any, that exist between the unique digital neural loop and the high division of the median nerve are not speculated upon.

Keywords: hand, median nerve, arteries, cadaver.

Introduction

Digital neural loops were first described in 1887 by Hartmann [1]. Modern studies have shown that digital neural loops are common findings, identified in 81% [2], 92% [3], and 100% [4] of dissected palms. Little attention has been given to digital neural loops in the anatomical and medical fields despite the evidence that they are normal anatomical structures.

As summarized in previously proposed classification systems [2, 3], several different patterns exist for both the position of digital neural loops within the palm and the type of arteries that penetrate the loops. Digital neural loops reported in the literature have been found exclusively within the common palmar digital nerves (CPDNs) or proper palmar digital nerves (PPDNs). The loop documented in this case was novel because it included a ramus that spanned between a CPDN and PPDN. The 2nd common palmar digital artery (CPDA) penetrated the unusual loop.

The median nerve is known to demonstrate several variations. One such anomaly is a high division, also known as a bifid median nerve. The pooled prevalence of this variant is 2.6% [5] based on cadaveric [6–9] and intraoperative studies [10–12]. The high division of the median nerve variation was found bilaterally in the forearms of this cadaver. Each bifid median nerve displayed an anomalous course whereby the ulnar component of the nerve traveled through a portion of the flexor digitorum superficialis (FDS) muscle before entering the palm as the 3rd CPDN. While seemingly rare, this presentation was similar to a case report documented by Natsis [13].

It is possible that the digital neural loop and/or high division of the median nerve (particularly its intramuscular course) may have contributed to clinical symptoms for

this individual. However, the donor cadaver's health records are not available to faculty at our institution, and thus the potential clinical relevance of the anatomical findings cannot be determined with certainty.

Case presentation

An unusual digital neural loop was identified in the right palm of a 48-year-old male cadaver during routine educational dissection (Figure 1). A ramus that contributed to the formation of the digital neural loop arose from the ulnar side of the 3rd CPDN, approximately 1.5 cm proximal to the CPDN's bifurcation into PPDNs. The ramus was 3.5 cm long and passed distally through the interdigital fold to merge with the PPDN on the ulnar side of the 3rd digit. The loop was penetrated by the 2nd CPDA. Unlike the digital neural loops described in previous works [1–3, 14], this loop involved both a CPDN and a PPDN. We propose an update to the existing classification system for digital neural loops to include a loop of similar type to the one described herein (Figure 2).

Aside from the digital neural loop in the right palm, this cadaver also exhibited bilateral, symmetrical bifid median nerves. The radial component of each median nerve was larger (0.4 cm in thickness) than the ulnar division (0.2 cm in thickness). The point of the median nerve's bifurcation was approximately 9 cm proximal to the base of the thenar eminence. After dividing, the ulnar component of the bifid median nerve coursed for 3 cm and then pierced the FDS muscle (Figure 3). The portion of the muscle that the nerve traveled through inserted onto the intermediate phalanx of the third digit via an unremarkable tendon. A small defect was present in the FDS to accommodate the passage of the nerve.

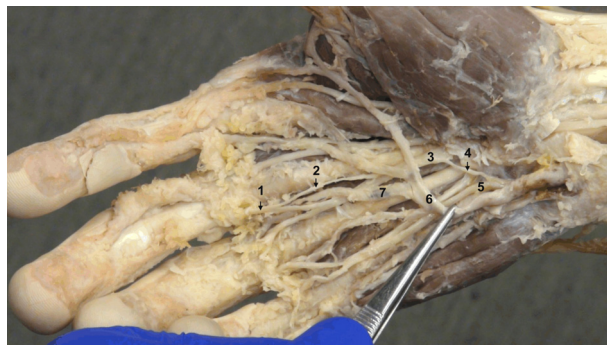


Figure 1 – Right palm, ulnar artery displaced to ulnar side. 1: Proper palmar digital nerve, ulnar side of middle finger; 2: Ramus contributing to digital neural loop; 3: 3rd common palmar digital nerve; 4: Berrettini anastomosis; 5: Ulnar nerve; 6: Superficial palmar arch; 7: 2nd common palmar digital artery.

The radial and ulnar components of the median nerve passed deep to the flexor retinaculum and into the palm. At this point, the ulnar portion of the bifid median nerve was comparable to the 3rd CPDN of a typical median nerve. The PPDNs associated with the 3rd CPDN were unremarkable aside from the contribution to the previously described digital neural loop within the right palm.

A union of the median and ulnar nerves, known as the Berrettini anastomosis, was present in both hands. Each Berrettini anastomosis was approximately 1.5 cm long and spanned from the 4th CPDN (of the superficial branch of the ulnar nerve) to the 3rd CPDN (of the median nerve). The ulnar nerve's contribution to the anastomosis was deep to the superficial palmar arch and the median nerve's portion was located at the medial border of the flexor pollicis longus muscle. As per the classification

system of Loukas *et al.* [15], this Berrettini anastomosis was similar in appearance to subtype III-B, however because of the bifid nature of the median nerve the anastomosis would have been functionally similar to subtype I-A.

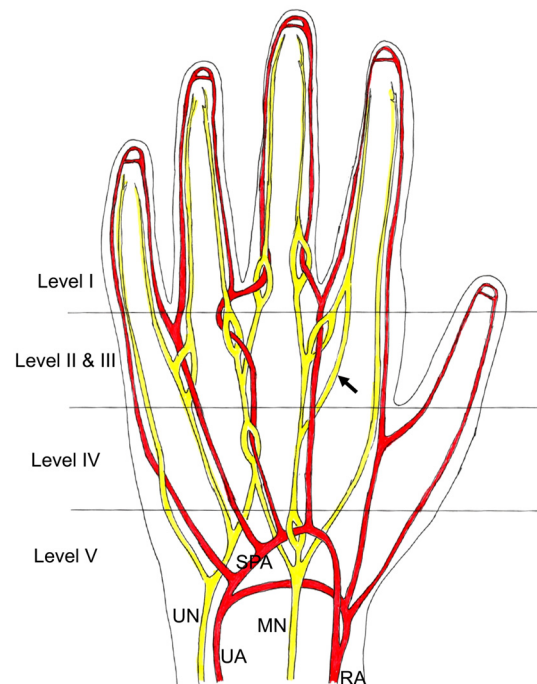


Figure 2 – Right palm – adapted from Niumsawatt & Rozen's [14] classification of neural loops, which was modified from Lee *et al.* [2]. RA: Radial artery; UA: Ulnar artery; MN: Median nerve; UN: Ulnar nerve; SPA: Superficial palmar arch; arrow: Novel digital neural loop spanning CPDN and PPDN.

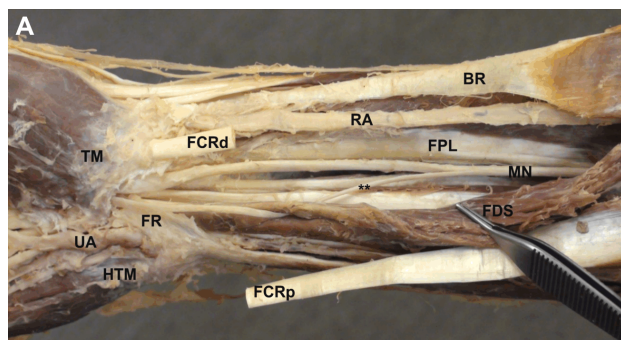


Figure 3 – (A) Right anterior forearm, palmaris longus muscle reflected. MN: Median nerve proximal to bifurcation; **: Ulnar component of bifid median nerve; FDS: Flexor digitorum superficialis muscle – radial head reflected; FCRp: Flexor carpi radialis tendon – cut proximal end; FCRd: Flexor carpi radialis tendon – cut distal end; FR: Flexor retinaculum – partially removed; UA: Ulnar artery; HTM: Hypothenar muscles; TM: Thenar muscles; FPL: Flexor pollicis longus tendon; RA: Radial artery; BR: Brachioradialis tendon. (B) Charcoal drawing of right anterior forearm.

Discussions

Digital neural loops are common structures, yet they are not typically represented in anatomical texts or atlases. When originally reported, Hartmann described several types of digital neural loops in two of the three hands that he investigated [1]. Since then, a small number of cadaveric studies have attempted to determine the prevalence of digital neural loops: Lee *et al.* identified them in 98 of 121 palms [2], Gotani & Gilbert in 47 of 51 palms [3], and Barreiro & Huelin in 30 of 30 palms [4]. Despite their high prevalence, relatively few cadaveric

[1–4, 16–19] and surgical reports [14, 20, 21] have been published to document digital neural loops.

Various means of classifying digital neural loops have been proposed in the past. Hartmann categorized digital neural loops according to their basic appearance, including the “boutonnière” and “ellipse” types [1]. Gotani & Gilbert aimed to classify the various types of digital neural loops by examining their anatomical characteristics within the 2nd–4th interdigital spaces [3]. Lee *et al.* created a classification system that focused on how digital neural loops divide and the location at which the penetrating artery passes through the loop [2]. Niumsawatt & Rozen

later modified the work of Lee *et al.* to include a previously unidentified type of digital neural loop, one that is formed by a penetrating PPDA [14]. We suggest that the type of digital neural loop described in this report, one that is similar to Hartmann's "ellipse" but involves both a CPDN and a PPDN in the formation of the loop, is distinctive and should be added to the classification pioneered by Lee *et al.*

The following arteries, listed in order of most common to least common, have been shown to penetrate digital neural loops: 2nd CPDA, 1st CPDA, 3rd CPDA, superficial palmar arch, radialis indicis, and 4th CPDA [2]. In this case, the 2nd CPDA passed through the digital neural loop. In rare instances, digital neural loops have played a role in compression of palmar neurovascular structures. One surgical case involved the presence of a digital neural loop that led to compression of a PPDN and occlusion of the penetrating CPDA after a crush injury of the hand [21]. It was surmised that the PPDN was compressed due to pulsatile flow through the penetrating CPDA [21]. Hofmann & Ruchelsman reported an atraumatic case in which the presence of a digital neural loop led to hemidigital anesthesia of the 4th digit [20]. Successful surgical outcomes were accomplished in the two aforementioned cases with transposition of the CPDA out of the digital neural loop [20, 21].

The Berrettini anastomosis (sensory) and the Riche–Cannieu anastomosis (motor) are two well reviewed [22, 23] palmar anastomoses that unite the median and ulnar nerves. The Berrettini anastomosis was discovered bilaterally in the palms of the cadaver documented here, but the Riche–Cannieu anastomosis was not identified on either side. If present, the Riche–Cannieu anastomosis can lead to the complete innervation of the thenar muscles by the ulnar nerve [24]. Variations of the Berrettini anastomosis and Riche–Cannieu anastomosis can involve proper palmar digital nerves [15, 25], however these communicating branches should not be confused with the unique digital neural loop described in this report.

The high division of the median nerve is one of many documented anomalies of the median nerve. Lanz found this variation in seven of 246 (2.8%) hands during surgical intervention and termed it a Group III variation within his classification system of median nerve anomalies at the carpal tunnel [10]. The reported prevalence of the high division of the median nerve has varied from 0.3% [11] to 11.5% [6]. Henry *et al.*, in a systematic review and meta-analysis that relied on information from a total of seven studies (four cadaveric and three intraoperative, $n=1123$ hands), found the pooled prevalence of the high division of the median nerve to be 2.6% [5].

A persistent median artery is often associated with a bifid median nerve, although the artery was not identified in this cadaver. During development, the median artery supplies blood to the hand but typically regresses after the 8th week of gestation. Al-Qattan *et al.* advocated that the bifid median nerve variant should be classified into six subcategories; two of these subcategories were based on the presence of persistent median vessels (with and without pathology) [26].

Various muscular or tendinous elements have been found in association with bifid median nerves, including: an accessory lumbrical [27], accessory palmaris longus

[28], palmaris profundus [29], and FDS [13, 30–33]. In the cadaver reported in the present case, the ulnar component of the bifid median nerve pierced the muscle bulk of FDS. The portion of FDS that the nerve traveled through was continuous with a grossly unremarkable tendon to the middle finger. This presentation is similar to a previously reported case in which the ulnar portion of a bifid median nerve first pierced FDS and then continued as the 3rd CPDN [13].

Other noteworthy relationships of the bifid median nerve and FDS, although not identical to this case, have been documented. A portion of a bifid median nerve traveled through the tendon of FDS (at the musculo-tendinous junction) to the 3rd digit, which possibly caused compression of the nerve during flexion [30]. Due to an anomalous course, a tendon of FDS traveled between a bifurcated median nerve [31]. Skie & Ciocanel related an unusual finding in which the tendon of FDS to the index finger penetrated the median nerve [32]. In another case, an anomalous muscle that arose from FDS was found to penetrate the median nerve, causing the nerve to bifurcate [33].

The relationship of the bifid median nerve and the previously mentioned muscles/tendons often leads to clinical symptoms of carpal tunnel syndrome. If each division of a bifid median nerve exists in its own carpal tunnel, a finding reported by several authors [34–36], both tunnels must be released to effectively treat acute carpal tunnel syndrome [26]. Unfortunately, the authors of this case do not have the opportunity to correlate the reported anatomical findings with the donor cadaver's health history. If the donor did present with symptoms during his life, it may have been prudent to excise a portion of FDS to free the ulnar component of the bifid median nerve.

✚ Conclusions

A unique digital neural loop was found in the right palm of this cadaver. The loop involved both a CPDN and PPDN. To our knowledge, a digital neural loop of this type has not been previously noted in the literature. We suggest modifying an existing classification system of digital neural loops to include the novel loop. This cadaver also featured bifid median nerves. The ulnar component of each median nerve pierced the FDS prior to entering the palm as the 3rd CPDN. A possible developmental relationship between the bifid median nerve and unique neural loop is not speculated upon.

Acknowledgments

The authors wish to thank individuals who donate their bodies and tissues for the advancement of education and research. Special thanks to Charles Everts, Aaron Fox, Khashi Jafari, Zachary Lovell, and Nicholas Shelton for their careful dissection. Funding provided by University of Western States.

Conflict of interests

The authors declare no conflicts of interest.

References

- [1] Hartmann H. Note sur l'anatomie des nerfs de la paume de la main. Bull Mém Soc Anat Paris, 1887, 62(5):860–864.

- [2] Lee JY, Kim YR, Kim JN, Choi HG, Song WC, Koh KS. Penetration of the digital nerves by the common palmar digital arteries in human cadavers. *J Hand Surg Am*, 2010, 35(12):2022–2026.
- [3] Gotani H, Gilbert A. Hartmann's boutonnière: an anatomical study of digital neural loop penetrations in the palm. *J Hand Surg Br*, 1999, 24(1):35–37.
- [4] Barreiro FJJ, Huelin JG. Etude des rapports vasculaires des nerfs superficiels de la région palmaire. *C R Soc Anat Paris*, 1976, 1:1–7.
- [5] Henry BM, Zwinczewska H, Roy J, Vikse J, Ramakrishnan PK, Walocha JA, Tomaszewski KA. The prevalence of anatomical variations of the median nerve in the carpal tunnel: a systematic review and meta-analysis. *PLoS One*, 2015, 10(8):e0136477.
- [6] Agarwal P, Gupta S, Yadav P, Sharma D. Cadaveric study of anatomical variations of the median nerve and persistent median artery at wrist. *Indian J Plast Surg*, 2014, 47(1):95–101.
- [7] Barbe M, Bradfield J, Donathan M, Elmaleh J. Coexistence of multiple anomalies in the carpal tunnel. *Clin Anat*, 2005, 18(4):251–259.
- [8] Mackinnon SE, Dellon AL. Anatomic investigations of nerves at the wrist: I. Orientation of the motor fascicle of the median nerve in the carpal tunnel. *Ann Plast Surg*, 1988, 21(1):32–35.
- [9] Olave E, Prates JC, Gabrielli C, Pardi P. Morphometric studies of the muscular branch of the median nerve. *J Anat*, 1996, 189(Pt 2):445–449.
- [10] Lanz U. Anatomical variations of the median nerve in the carpal tunnel. *J Hand Surg Am*, 1977, 2(1):44–53.
- [11] Ahn DS, Yoon ES, Koo SH, Park SH. A prospective study of the anatomic variations of the median nerve in the carpal tunnel in Asians. *Ann Plast Surg*, 2000, 44(3):282–287.
- [12] Tountas CP, Bihrie DM, MacDonald CJ, Bergman RA. Variations of the median nerve in the carpal canal. *J Hand Surg Am*, 1987, 12(5 Pt 1):708–712.
- [13] Natsis K. High origin of the third digital branch of the median nerve. *Anatomy*, 2016, 10(1):71–74.
- [14] Niumsawatt V, Rozen WM. Digital neural loops: classification and implications of variation in hand surgery. *J Reconstr Microsurg*, 2014, 30(1):21–23.
- [15] Loukas M, Louis RG Jr, Stewart L, Hallner B, DeLuca T, Morgan W, Shah R, Mlejnek J. The surgical anatomy of ulnar and median nerve communications in the palmar surface of the hand. *J Neurosurg*, 2007, 106(5):887–893.
- [16] Patil J, Kumar N, Aithal AP, Swamy RS, Mohandas Rao KG. An eccentric anatomical variation of palmar vascular pattern: report of surgical challenging vascular variation. *J Med Sci*, 2016, 36(6):240–242.
- [17] Angelov AK, Jeleu L. A case of distal ulnar nerve variation – presence of sensory loop around the hook of the hamate bone. *Rev Arg Anat Clin*, 2014, 6(2):95–98.
- [18] Tian D, Fu M. Anatomic variation of the common palmar digital nerves and arteries. *J Korean Neurosurg Soc*, 2015, 57(3):219–220.
- [19] Venkatesan V, Ratnasamy S, Sriram K. Digital neural loops – a rare anatomic variation. *J Anat Soc India*, 2008, 57(2):155–157.
- [20] Hofmann KJ, Ruchelsman DE. Symptomatic neural loop causing hemidigital anesthesia: case report. *J Hand Surg Am*, 2012, 37(10):1994–1996.
- [21] Spinner RJ, Varela CD, Urbaniak JR. Digital nerve penetration by a digital artery in a patient with neurovascular symptoms: a case report. *J Hand Surg Am*, 1996, 21(6):1101–1103.
- [22] Wynter S, Dissabandara L. A comprehensive review of motor innervation of the hand: variations and clinical significance. *Surg Radiol Anat*, 2018, 40(3):259–269.
- [23] Roy J, Henry BM, Pekala PA, Vikse J, Saganiak K, Walocha JA, Tomaszewski KA. Median and ulnar nerve anastomoses in the upper limb: a meta-analysis. *Muscle Nerve*, 2016, 54(1):36–47.
- [24] Bölükbaşı O, Turgut M, Akyol A. Ulnar to median nerve anastomosis in the palm (Riches–Cannieu anastomosis). *Neurosurg Rev*, 1999, 22(2–3):138–139.
- [25] Sarikcioglu L, Sindel M. A variant of the Cannieu–Riche communication: case report. *Morphologie*, 2002, 86(273):35–37.
- [26] Al-Qattan MM, Al-Zahrani K, Al-Omawi M. The bifid median nerve re-visited. *J Hand Surg Eur Vol*, 2009, 34(2):212–214.
- [27] Schultz RJ, Endler PM, Huddleston HD. Anomalous median nerve and an anomalous muscle belly of the first lumbrical associated with carpal–tunnel syndrome. *J Bone Joint Surg Am*, 1973, 55(8):1744–1746.
- [28] Crandall RC, Hamel AL. Bipartite median nerve at the wrist. Report of a case. *J Bone Joint Surg Am*, 1979, 61(2):311.
- [29] Jones DPG. Bilateral palmaris profundus in association with bifid median nerve as a cause of failed carpal tunnel release. *J Hand Surg Am*, 2006, 31(5):741–743.
- [30] Fernandez-Garcia S, Pi-Folguera J, Estallo-Matino F. Bifid median nerve compression due to a musculotendinous anomaly of FDS to the middle finger. *J Hand Surg Br*, 1994, 19(5):616–617.
- [31] Park JJ, Choi JG, Son BC. Carpal tunnel syndrome caused by bifid median nerve in association with anomalous course of the flexor digitorum superficialis muscle at the wrist. *Nerve*, 2017, 3(1):21–23.
- [32] Skie M, Ciocanel D. Anomaly of flexor digitorum superficialis penetrating through the median nerve: case report. *J Hand Surg Am*, 2010, 35(1):27–29.
- [33] Atoni AD, Oyinbo CA. Anatomic variation of the median nerve associated with an anomalous muscle of the forearm. *Folia Med (Plovdiv)*, 2017, 59(1):106–109.
- [34] Amadio P. Bifid median nerve with a double compartment within the transverse carpal canal. *J Hand Surg Am*, 1987, 12(3):366–368.
- [35] Berry MG, Vijn V, Percival NJ. Bifid median nerve: anatomical variant at the carpal tunnel. *Scand J Plast Reconstr Surg Hand Surg*, 2003, 37(1):58–60.
- [36] Szabo RM, Pettey J. Bilateral median nerve bifurcation with an accessory compartment within the carpal tunnel. *J Hand Surg Am*, 1994, 19(1):22–23.

Corresponding author

Logan Bale, Instructor, MS, Department of Basic Sciences, University of Western States, 2900 NE 132nd Avenue, Portland, Oregon 97230, USA; Phone 1–503–251–2843, e-mail: lbale@uws.edu

Received: September 13, 2017

Accepted: March 25, 2018