

Femtosecond-LASIK outcomes using the VisuMax[®]–MEL[®] 80 platform for mixed astigmatism refractive surgery

HORIA TUDOR STANCA¹⁾, MIHNEA MUNTEANU²⁾, DRAGOȘ CĂTĂLIN JIANU³⁾,
 ANDREI GHEORGHE MARIUS MOTOC⁴⁾, CRISTIAN RADU JECAN¹⁾, BOGDANA TĂBĂCARU¹⁾,
 SIMONA STANCA¹⁾, MARIA ALEXANDRA PREDA²⁾

¹⁾Department of Ophthalmology, "Carol Davila" University of Medicine and Pharmacy, Bucharest, Romania

²⁾Department of Ophthalmology, "Victor Babeș" University of Medicine and Pharmacy, Timișoara, Romania

³⁾Department of Neurology, "Victor Babeș" University of Medicine and Pharmacy, Timișoara, Romania

⁴⁾Department of Anatomy and Embryology, "Victor Babeș" University of Medicine and Pharmacy, Timișoara, Romania

Abstract

Aim: To evaluate the predictability, efficacy and safety of Femtosecond–laser-assisted *in situ* keratomileusis (LASIK) procedure for mixed astigmatism. **Patients, Materials and Methods:** We prospectively evaluated for 12 months 74 eyes (52 patients) with mixed astigmatism that underwent Femtosecond-LASIK treatment. The preoperative mean refractive sphere value was $+1.879 \pm 1.313$ diopters (D) and the mean refractive cylinder value was -4.169 ± 1.091 D. The anterior corneal flap was cut using the VisuMax[®] femtosecond laser and then the stromal ablation was done using the MEL[®] 80 excimer laser. **Results:** Mean age was 30.22 ± 6.421 years with 61.53% female patients. Postoperative spherical equivalent at 12 months was within ± 0.5 D of emmetropia in 75.8% of eyes and within ± 1 D in 97.3% of eyes. Postoperative uncorrected distance visual acuity was equivalent to or better than the preoperative corrected distance visual acuity in 91.9% of eyes. Compared to the preoperative corrected distance visual acuity (CDVA), 8.1% of eyes gained one line, 2.7% gained two lines and 2.7% gained three lines of visual acuity. **Conclusions:** Femtosecond-LASIK using the VisuMax[®]–MEL[®] 80 platform appears to have safe, effective and predictable results in mixed astigmatic eyes. The results are impressive for high refractive error treatment and for improvement of both uncorrected and corrected distance visual acuity.

Keywords: Femtosecond-LASIK, FemtoLASIK, mixed astigmatism.

Introduction

The evolution of ophthalmic femtosecond and excimer lasers technology has enabled treatment of increasingly high refractive errors as mixed astigmatism, characterized by an irregular shape of the cornea in which one meridian is myopic and the other is hyperopic [1]. When mixed astigmatism is treated, the refractive error is segregated in two cylinder components of opposite sign and axis [2], on the cornea being applied both a myopic and a hyperopic treatment [1]. The treatment plan involves flattening the cornea in the myopic meridian and steepening it in the hyperopic meridian, removing as little corneal stroma as possible [3].

There have been several reports of mixed astigmatism laser-assisted *in situ* keratomileusis (LASIK) in the past [3–15], two of them using the femtosecond laser instead of the conventional microkeratomes [3, 7].

Alió del Barrio *et al.*, published in 2017 a study performed on 80 eyes with three months follow-up and 50 eyes with six months follow-up. The authors concluded that that laser *in situ* keratomileusis using excimer platforms with cyclotorsion control, fast repetition rate, and optimized aspheric profiles offers secure and stable results, in correcting refractive errors. Six months after the laser surgery, 80% of eyes had a spherical equivalent around ± 0.5 diopters (D) and 96% around ± 1 D [4].

Nowadays, LASIK is the most common refractive

surgery procedure for the correction of myopia, hyperopia and astigmatism. One of the serious surgical complications is corneal ectasia due to the loss of the biomechanical integrity of the cornea, the corneal stroma becomes progressively thinner, the cornea steeper, irregular astigmatism appears, and the distance visual acuity decreases. The incidence of post-LASIK ectasia is approximately of 0.66% [5].

In our study, we evaluated the predictability, efficacy and safety of Femtosecond-LASIK (FemtoLASIK) procedure for mixed astigmatism.

Patients, Materials and Methods

Patients

We treated by FemtoLASIK technique 74 eyes (52 patients) for mixed astigmatism. All the FemtoLASIK operations were performed in the Metropolitan Hospital in Bucharest, Romania, between September 1, 2012 and August 31, 2014. The study was approved by the Hospital's Ethical Committee and all patients signed an informed consent after being informed about the benefits and risks of the procedure.

The patients were followed-up prospectively at one day and one, three, six and 12 months, as scheduled. One patient, treated on both eyes, was lost to follow-up.

A physical examination (including a neurological

examination) was performed at presentation by a neurologist.

Inclusion criteria for surgery were: age of 22 years or over, stable refractive error for at least two years before surgery, no ocular diseases, no previous ocular surgery or ocular trauma, central endothelial cell count more than 2000 cells/mm², normal central and peripheral retina or treated by photocoagulation when at-risk peripheral lesions were present, good general health. Exclusion criteria for surgery were: insufficient corneal thickness for laser ablation (estimated residual thickness of the stromal bed less than 300 µm after treatment), severe dry eyes, evidence or suspect of keratoconus, pregnancy, lactation, autoimmune or immunodeficiency disorders, any general disease and poor compliance.

Preoperative assessment

The preoperative ocular examination included: uncorrected (UDVA) and corrected distance visual acuity (CDVA), manifest, fogging and cycloplegic refractions, tonometry, keratometry, white-to-white (WTW) corneal diameter, corneal pachymetry, topography and tomography (Scheimpflug), pupillometry, corneal endothelial cell count, anterior segment slit-lamp biomicroscopy and mydriatic funduscopy.

The refraction and the tonometry were measured with the autorefracto/kerato/tonometer Tonoref II (Nidek Co., Ltd., Japan). The WTW diameter was measured with the IOLMaster[®] 500 (Carl Zeiss Meditec AG, Germany). The corneal endothelial cells were evaluated with the Tomey EM-3000 Specular Microscope (Tomey Corporation, Japan). The central corneal thickness was measured with the ultrasound pachymeter UP-1000 (Nidek Co., Ltd., Japan) and correlated with the optical pachymetry measurements taken with the Schwind Sirius[®] (Schwind Eye-Tech-Solutions GmbH & Co., Germany) and Orbscan[®] II Anterior Segment Analyzer (Technolas Perfect Vision GmbH, Germany). Keratometry and topographies were performed with both the Schwind Sirius[®], a device which combines a Scheimpflug camera with a Placido disc corneal topographer [16] and the Orbscan[®] II, which combines scanning slit with Placido disc technology [17]. Pupilometry measurements (taken with the Schwind Sirius[®]) were performed in three lighting conditions (scotopic at 0.4 lux, mesopic at 4 lux and photopic at 40 lux) and in a special lighting condition which monitor pupil dilation from fully photopic (500 lux) to absence of light [16].

Patients should have discontinued contact lens wearing two weeks prior to all corneal investigations and then, two weeks before the surgery.

Surgical procedure

All surgeries were performed by the same surgeon (H.T.S.) using the same protocol and technique. The surgical attempted postoperative result was to achieve an UDVA similar to the preoperative CDVA. In patients operated in both eyes, the procedures were done successively, starting with the right eye.

The eyelids were wiped with two sterile swabs softened with 10% Povidone-iodine and then with a dry sterile swab. A sterile drape was used to tape the lid lashes out of the surgical field. Before surgery, we used topical anesthesia with Oxybuprocaine 0.4% (Benoxi, Unimed Pharma Ltd.,

Slovakia) and an eyelid speculum was properly placed. The patient was positioned with the eye to be treated under the femtosecond laser (VisuMax[®], Carl Zeiss Meditec, Germany) integrated surgical microscope. A curved suction contact glass cup was chosen according to the WTW diameter of the treated eye and was applied on the cornea. As the patient fixed the laser target light, the surgeon achieved an appropriate centration and initiated the automatic suction. The patient was then asked not to move the eye or the head. When the suction was complete, the surgeon initiated the femtosecond corneal flap cutting, the laser being preset by default at a wavelength of 1043 nm and a laser pulse frequency of 500 kHz. The anterior flap parameters were set as follows: diameter of 7.9–8.8 mm, depth of 100–130 µm, hinge width of 3.84 mm, corresponding with a 50° angle, superior hinge position and side cut angle of 90°. According to situation, the fellow eye was treated identically to the first for flap creation. After that, the patient was relocated to the excimer laser.

The flap was first dissected and lifted with an IntraLase[®] double-ended flap lifter (Katena Products, Inc., USA) and the corneal bed was dried with K-Sponge II Spears (Katena Products, Inc., USA).

The underlying stroma was treated for refractive correction using an excimer laser (MEL[®] 80, Carl Zeiss Meditec, Germany), which is using a wavelength of 193 nm, 250 Hz frequency and a fluence of 180 mJ/cm². Calibration was done before each surgical session. The eye to be treated was aligned beneath the laser aperture and the ultrarapid infrared eye tracking camera system. During the surgery, patients fixated on the laser's target light.

The optical zone was 6.5 mm in 68 eyes and 6.25 mm in six eyes, according to the refractive error to be treated, scotopic pupil size, corneal thickness and flap diameter. Using the "Aberration Smart Ablation" excimer laser profile, the mean ablation depth was 58.11±15.129 µm (range: 30 to 102 µm). After the ablation was done, the corneal stromal bed was rinsed thoroughly with a cold sterile balanced salt solution. Then, the flap was repositioned, the flap margins were dried with K-Sponge II Spears and the lid speculum was removed. Moxifloxacin 0.5% (Vigamox, Alcon Courveur NV, Belgium) and artificial tears (Systane Ultra, Alcon Courveur NV, Belgium) drops were instilled in the treated eye and a disposable plano contact lens (Air Optix Aqua Night & Day, Alcon Eye Care a Novartis Company) was applied. According to situation, we performed the excimer ablation in the fellow eye according to the same protocol.

Thirty minutes after the surgery, patients were examined at the slit lamp to check the flap position and its regularity and to assess the interface clarity.

Postoperative treatment and evaluation

Immediately after surgery, we prescribed topical eye drops to be used: Moxifloxacin 0.5%, q.d.s. for one week and Pranoprofen 0.1% (Pranoflog, SIFI SpA., Italy) t.d.s. for two weeks. Artificial tears were prescribed for at least four times daily, 12 months.

First appointment was in the first day postoperative when, after the removal of the bandage contact lens, we have done an evaluation which consisted in measurement of manifest refraction, UDVA and slit lamp examination. After this visit we also prescribed topical steroids, Fluorometolone 0.2% (Flumetol, Farmila Thea Farma-

ceutici SpA., Italy), which we recommended to be applied q.d.s for two weeks, then tapered gradually (t.d.s., then b.d.s. and then q.d., two weeks each).

The next postoperative examinations were carried out at one, three, six and 12 months when we measured UDVA and CDVA, manifest refraction, tonometry, corneal topography and we performed slit-lamp examination. In the postoperative period, the cycloplegic refraction was measured only for those patients with a low degree of visual satisfaction or having the visual acuity uncorrelated with the manifest refraction.

Data analysis and statistics

Patient data were collected on case forms and centralized into an Excel® database (ver. 14.0, Microsoft Corp.) for subsequent analysis. Data analysis was performed using Statistical Package for the Social Sciences (SPSS) software (ver. 20, IBM® SPSS® Statistics, IBM Corp.).

Prior to statistical analysis, all visual acuities results were converted to logarithm of the minimal angle of resolution of visual acuity (*logMAR* scale).

For the statistical analysis of the postoperative refractive data, we used only the manifest refraction as the postoperative cycloplegic refraction was not performed to all eyes at all postoperative visits.

After checking the normality of continuous variables distributions by the Shapiro–Wilk test, statistical analysis aimed to evaluate postoperative outcomes using either the paired-samples *t*-test or the Wilcoxon signed-rank test. The statistical significance was set at *p*-value less than 0.05.

Outcome analysis was performed according to the Standard Graphs for Reporting Refractive Surgery [18, 19].

Results

We included in our study 74 eyes (42 right eyes and 32 left eyes) from 52 patients (32 females and 20 males). The mean age was 30.22 ± 6.421 years old (range: 22 to 46 years old).

Visual acuity

The mean *logMAR* CDVA before surgery was 0.072 ± 0.108 , 50 eyes had a preoperative CDVA of 20/20 (0 *logMAR*) or better and 24 eyes had a preoperative CDVA between 20/25 (0.1 *logMAR*) and 20/40 (0.3 *logMAR*) (Figure 1A).

Figure 1C represents the safety graph, indicating that at 12 months postoperatively, 86.5% of eyes had an unchanged CDVA and 13.5% of eyes gained at least one line of visual acuity postoperatively. No eye lost lines of preoperative CDVA at any follow-up visit.

A Wilcoxon signed-rank test showed that the preoperative *logMAR* UDVA of 0.313 ± 0.158 significantly improved to 0.096 ± 0.119 ($z = -5.118$, $p < 0.0005$) one month after the surgery, remained stable at 0.098 ± 0.133 ($z = -0.321$, $p = 0.748$) until the six months postoperative visit and thereafter continued to improve to 0.073 ± 0.098 ($z = -2.864$, $p = 0.004$) at 12 months follow-up visit.

After 12 months following surgery, the gain in *logMAR* lines of UDVA was 2.43 ± 0.959 (range: 1 to 5 lines).

At 12 months postoperatively, 86.5% of eyes had UDVA 20/30 (0.18 *logMAR*) or better. An UDVA equivalent to or better than the preoperative CDVA was obtained in 91.9% of treated eyes (Figure 1B).

Refraction

The preoperative manifest and cycloplegic refraction data are presented in Table 1. The manifest and cycloplegic mean sphere refractions were positive correlated ($r = 0.74$, $p < 0.0005$), between them being found a statistically significant difference from $+1.879 \pm 1.313$ D to $+2.597 \pm 1.091$ D ($p < 0.0005$), with a hyperopic shift of 0.718 ± 0.891 D. The preoperative cycloplegic mean cylinder refraction did not statistically significantly differ from the preoperative manifest mean cylinder refraction ($p = 0.869$, paired samples *t*-test).

The mean manifest preoperative refraction was improved from the first postoperative day, after 12 months of follow-up, being reduced with 1.642 ± 1.424 D of sphere and 2.851 ± 0.849 D of astigmatism. All postoperative manifest refraction data are presented in Table 2.

Refractive outcomes are also shown in Figure 1. Figure 1F shows the evolution of refraction after the surgery and its stability in time.

The predictability (percentage of eyes with different residual refractive error) at all postoperative visits is demonstrated in Table 3.

Table 1 – The preoperative manifest and cycloplegic refraction data

Parameter	Diopters [mean±SD, range]
Manifest sphere	$+1.879 \pm 1.313$, -0.5 to $+4.25$
Manifest cylinder	-4.169 ± 1.091 , -6.25 to -2.25
Manifest SEQ	-0.222 ± 1.185 , -3.5 to $+2.125$
Manifest vector length	3.64 ± 0.898 , 1.789 to 5.859
Cycloplegic sphere	$+2.597 \pm 1.091$, $+0.5$ to $+4.5$
Cycloplegic cylinder	-4.161 ± 1.034 , -6.25 to -2.25

SD: Standard deviation; SEQ: Spherical equivalent.

Table 2 – All postoperative manifest refraction data

Parameter	Diopters [mean±SD, range]	<i>p</i> -value ^a
Manifest sphere		
Postoperative 1 day	$+0.243 \pm 0.847$, -2.5 to $+2$	$< 0.0001^b$
Postoperative 1 month	$+0.27 \pm 0.508$, -1 to $+1.25$	0.819^b
Postoperative 3 months	$+0.446 \pm 0.574$, -0.75 to $+2.25$	0.036^c
Postoperative 6 months	$+0.46 \pm 0.502$, -1 to $+1.25$	0.609^c
Postoperative 12 months	$+0.534 \pm 0.445$, -0.75 to $+1.25$	0.086^b
Manifest cylinder		
Postoperative 1 day	-1.23 ± 0.764 , -3 to 0	$< 0.0001^b$
Postoperative 1 month	-1.284 ± 0.648 , -3 to -0.25	0.532^b
Postoperative 3 months	-1.324 ± 0.702 , -3 to 0	0.534^b
Postoperative 6 months	-1.209 ± 0.673 , -2.75 to 0	0.015^b
Postoperative 12 months	-1.189 ± 0.652 , -2.5 to -0.25	0.597^b
Manifest SEQ		
Postoperative 1 day	-0.493 ± 0.52 , -2.125 to $+0.745$	0.206^b
Postoperative 1 month	-0.507 ± 0.384 , -1.625 to $+0.125$	0.663^c
Postoperative 3 months	-0.439 ± 0.383 , -1.5 to $+0.125$	0.07^b
Postoperative 6 months	-0.375 ± 0.39 , -1.625 to $+0.25$	0.074^b
Postoperative 12 months	-0.327 ± 0.33 , -1.125 to $+0.25$	0.119^b

Parameter	Diopters [mean±SD, range]	p-value ^a
Manifest vector length		
Postoperative 1 day	1.384±0.831, 0.25 to 3.092	<0.0001 ^c
Postoperative 1 month	1.402±0.71, 0.25 to 3.411	0.826 ^b
Postoperative 3 months	1.415±0.761, 0 to 3.354	0.839 ^b
Postoperative 6 months	1.297±0.723, 0 to 2.85	0.018 ^b
Postoperative 12 months	1.262±0.678, 0.279 to 2.648	0.422 ^b

SD: Standard deviation; ^aStatistical significance of the difference when compared to the mean of the preoperative visit at the 1 day evaluation or compared to the mean of the previous postoperative visit for the rest of evaluations; ^bPaired samples t-test; ^cWilcoxon signed rank test; P-values represents the statistical significance of the difference between two consecutive visits; SEQ: Spherical equivalent.

Regarding the mean refractive manifest astigmatism, at the last postoperative visit, 18.92% and 54.05% of the

eyes were less than 0.5D and less than 1D, respectively (Figure 1G). Correlation between target-induced astigmatism (TIA) and surgically induced astigmatism (SIA) was positive and moderate ($r^2=0.4252$, slope=0.892, intercept=0.39D, $p<0.0005$), observing under correction (Figure 1H). Figure 1I reveals the histogram of the angle of error, showing that the axis of the SIA was within 5 degrees of the axis of the TIA for 51.35% of the eyes.

Table 3 – The predictability (percentage of eyes with different residual refractive error) at all postoperative visits

Postoperative visit	±0.5 diopters of emmetropia [%]	±1 diopter of emmetropia [%]
1 day	64.8	81
1 month	59.5	83.8
3 months	64.8	94.6
6 months	73	97.3
12 months	75.7	97.3

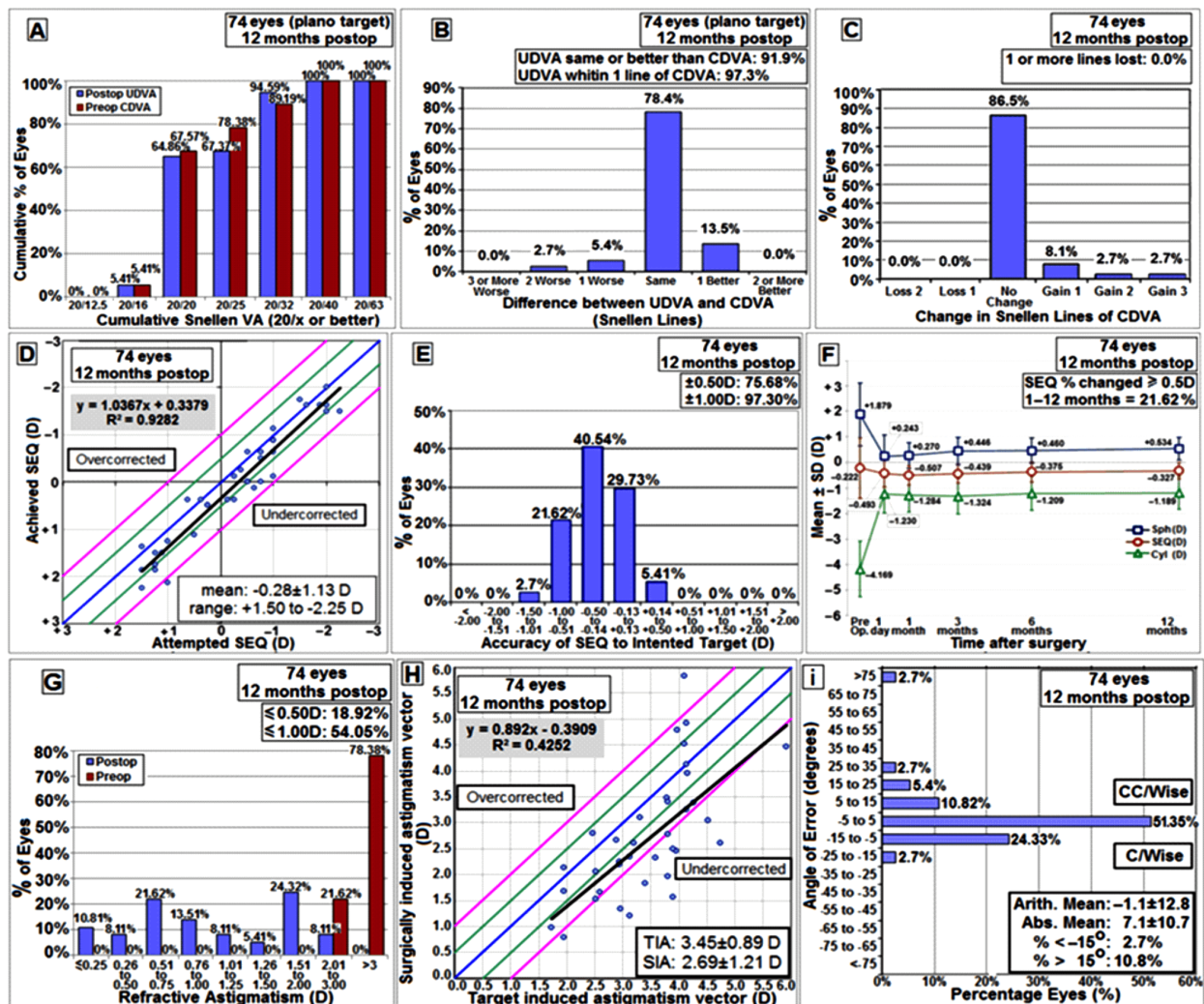


Figure 1 – Visual (A–C), refractive (D–E) and astigmatism (F–I) outcomes of 74 eyes that underwent FemtoLASIK surgery for mixed astigmatism. The figure demonstrates results after 12 months of (A) summary of postoperative uncorrected distance visual acuity (UDVA) and preoperative corrected distance visual acuity (CDVA), (B) efficacy, shown as gained and lost Snellen lines of UDVA compared to preoperative CDVA, (C) safety, shown as gained and lost Snellen lines of postoperative CDVA, compared to preoperative CDVA, (D) spherical equivalent (SEQ) attempted vs. achieved, (E) SEQ refractive accuracy, (F) stability of spherical (Sph), cylinder (Cyl) and SEQ refraction, (G) summary of preoperative and postoperative refractive astigmatism, (H) target induced astigmatism vector (TIA) vs. surgically induced astigmatism vector (SIA) and (I) summary of refractive astigmatism angle of error. D: Diopters; Postop: Postoperative; Preop: Preoperative.

Corneal thickness

The preoperative corneal thickness was $549 \pm 26.414 \mu\text{m}$ (range: 496 to $642 \mu\text{m}$). It significantly decreased to $508.49 \pm 26.328 \mu\text{m}$ (range: 445 to $551 \mu\text{m}$) at one month postoperatively ($p < 0.0005$, paired samples t -test) and afterwards did not significantly changed either at six months ($p = 0.414$, paired samples t -test) or at 12 months ($p = 0.533$, paired samples t -test) postoperatively.

Complications

We encountered no major intraoperative or postoperative complications. After 12 months of follow-up, none of the eyes developed corneal ectasia.

In addition to the SEQ, we used in our analysis the vector length value, which could differentiate between eyes with similar SEQ refractions but with different astigmatism degrees. As shown in Tables 1 and 3, the mean SEQ did not undergone any significantly change throughout the follow-up period, whereas the vector length was significantly improved in the first postoperative day and between the third and the sixth postoperative months, then remaining constant. In addition, the vector length was strongly correlated with the manifest cylinder all over the follow-up period (Table 4), being therefore a good parameter in quantifying postoperative retinal image distortion.

Table 4 – The vector length was strongly correlated with the manifest cylinder all over the follow-up period, being therefore a good parameter in quantifying post-operative retinal image distortion

Follow-up visit	r-value	p-value
Preoperative	-0.886	<0.0001
1 day postoperative	-0.974	<0.0001
1 month postoperative	-0.989	<0.0001
3 months postoperative	-0.994	<0.0001
6 months postoperative	-0.991	<0.0001
12 months postoperative	-0.994	<0.0001

Values of Pearson's product moment correlation coefficient between the vector length and manifest cylinder at different follow-up visits.

Discussions

In our study, the predictability of the SEQ in the intended target was 75.8% within $\pm 0.5\text{D}$ and 97.3% within $\pm 1\text{D}$, respectively. These data are in accordance with most previous reports in the literature [8, 12, 13], except the work of Alio *et al.*, in 2013, where is reported an unexplained low predictability [3] (Table 5).

Concerning UDVA, in the present study, 86.5% of eyes had UDVA 20/30 (0.18 logMAR) or better. The same UDVA is reported to be achieved in 100% of eyes by Khalifa *et al.*, in 2009 [8] and by Stonecipher *et al.*, in 2010 [7]. Kilavuzoğlu *et al.* reported, in their study published in 2016, a visual acuity of 20/25 (0.1 logMAR) or better in 70% of eyes treated with WaveLight excimer laser and in 100% of eyes treated with Technolas excimer laser. The cause of our slightly lower efficacy compared to other studies may be our preoperative CDVA of 20/30

(0.18 logMAR) or lower in 32.43% of eyes. A published study reported a postoperative UDVA of 20/20 (0 logMAR) or better in 98.3% [5] of eyes, while other studies reports same UDVA in 53% [12] and 51% [10] of operated eyes. An UDVA of 20/40 (0.3 logMAR) or better is reported by Salz *et al.*, in 2002 [13], in 94.4% of cases.

Table 5 – In our study, the predictability of the spherical equivalent (SEQ) in the intended target was 75.8% within $\pm 0.5\text{D}$ and 97.3% within $\pm 1\text{D}$, respectively. These data are in accordance with most previous reports in the literature [8, 12, 13], except the work of Alio *et al.*, in 2013, where is reported an unexplained low predictability [3]

Study	Follow-up period [months]	± 0.5 diopters of emmetropia [%]	± 1 diopter of emmetropia [%]
Alio <i>et al.</i> [3]	3	26.9	65.3
Khalifa <i>et al.</i> [8]	3	80	100
Carones <i>et al.</i> [12]	6	79.2	98.1
Salz <i>et al.</i> [13]	12	73.7	94.7

Of our treated mixed astigmatic eyes, 91.9% obtained an UDVA equivalent to or better than the preoperative CDVA. The eyes with postoperative UDVA inferior to preoperative CDVA were the result of a myopic over-correction as the laser procedure was performed according to the fogging and cycloplegic refractions, not to the manifest refraction. For these eyes, the result should be interpreted in time, according with the patient's age at the moment of surgery.

In the present study, no eye lost CDVA postoperatively as well as in other published studies [8, 13, 20]. However, several other articles report a loss of one line of CDVA in about 10% [7, 21] or 15.4% [3] of eyes, whereas a loss of two or more lines of CDVA is reported in 0.8% [10], 5.76% [3] or 10% [22] of cases in different other studies.

The surgical purpose in mixed astigmatic eyes is to reduce as much as possible both the sphere and the cylinder, so that the blur circle formed on the retina by the spherocylindrical residual refractive error to be as narrow as possible [23].

Biomechanical changes in corneal stroma are due to the disruption of collagen lamellae by the photorefractive process, resulting in loss of corneal stromal tensile strength, decrease in elasticity and changes in shape and refractive power [24]. In our study, the mean preoperative manifest sphere significantly decreased in the first postoperative day and then gradually increased until the end of follow-up but with only a statistically significant difference between the first and the third month (Table 2). As far as that goes the mean preoperative manifest cylinder power, it significantly decreased in the first postoperative day and then suffered insignificant changes, except between the third and the sixth month when it decreased significantly once more (Table 2).

In eyes with mixed astigmatism, as those treated in our study, the SEQ does not provide adequate information about the preoperative and postoperative image distortion and visual quality [23].

In order to characterize the refractive status of the astigmatic eyes, there were described several refractive parameters. The defocus equivalent, described for the first time by Holladay *et al.*, in 1991 [23], is equal to the sum of the absolute value of the SEQ plus half the absolute value of the cylinder in the cycloplegic eyes or is equal to half the absolute value of the cylinder in eyes where accommodation is allowed [22]. On a graphical representation of a refractive error, where the horizontal axis represents meridian orientation and the vertical axis represents excess refractive power, the amount of retinal blur is related to the mismatch between the curve and the baseline [25]. The root-mean-squared error [25] and the area between the curve and the baseline [25] are two parameters that quantify this blur. The highest correlation with the retinal blur and the visual acuity in cases of mixed astigmatism has another parameter, the vector length [25]. The vector length is equal to the square root of the sum between the square of the absolute value of the spherical equivalent and the square of the absolute value of the cylinder [25].

As both the sphere and the cylinder values were reduced, the distortion of retinal image was smaller allowing us to achieve a better postoperative CDVA with at least one line in 13.5% of eyes.

We have not encountered any intraoperative event or major postoperative complication. Mild adverse events as reduced corneal sensitivity, dry eye syndrome, haze, night visual disturbances or reduced contrast sensitivity were not analyzed since we mainly focused our research on visual and refractive outcomes. As our work included a small number of treated eyes and a short period of follow-up, future reports on longer-term and larger cohorts will be salutary to detect regression rate and potential corneal ectasia.

✉ Conclusions

Femtosecond-LASIK utilizing the VisuMax[®]–MEL[®] 80 platform appears to be a suitable option to correct selected cases of mixed astigmatism, the procedure being safe, effective and quite predictable if an adequate preoperative evaluation is done. The postoperative results at one year are impressive for correction of mixed astigmatic refractive errors, with significant improvement in UDVA, but we consider that a slight adjustment of the excimer laser ablation profile nomogram could be done according with certain calculations, which will be presented in future works.

Disclosure

The authors have no financial or proprietary interest in any device presented in this study.

References

- [1] Bovet JJ, Chiou A. Wavefront optimize and astigmatism correction with the allegretto excimer laser. In: Goes FJ, Bovet JJ, Pajic B, Wang Y, Nassaralla BA (eds). Instant clinical diagnosis in ophthalmology: refractive surgery. Series editors: Garg A, Rosen E. Jaypee Brothers Medical Publishers (P) Ltd., New Delhi, India, 2009, 210.
- [2] Titiyal JS, Ahuja R, Sharma N. Indications and contraindications of LASIK. In: Vajpayee RB, Sharma N, Melki SA, Sullivan L (eds). Step by step LASIK surgery. Jaypee Brothers Medical Publishers (P) Ltd., New Delhi, India, 2003, 8.
- [3] Alió JL, Pachkoria K, El Aswad A, Plaza-Puche AB. Laser-assisted *in situ* keratomileusis in high mixed astigmatism with optimized, fast-repetition and cyclotorsion control excimer laser. *Am J Ophthalmol*, 2013, 155(5):829–836.
- [4] Alió del Barrio JL, Tiveron M, Plaza-Puche AB, Amesty MA, Casanova L, García MJ, Alió JL. Laser-assisted *in situ* keratomileusis with optimized, fast-repetition, and cyclotorsion control excimer laser to treat hyperopic astigmatism with high cylinder. *Eur J Ophthalmol*, 2017, 27(6):686–693.
- [5] Yang E, Roberts CJ, Mehta JS. A review of corneal biomechanics after LASIK and SMILE and the current methods of corneal biomechanical analysis. *J Clin Exp Ophthalmol*, 2015, 6(6):507.
- [6] Lukenda A, Martinović ZK, Kalauz M. Excimer laser correction of hyperopia, hyperopic and mixed astigmatism: past, present, and future. *Acta Clin Croat*, 2012, 51(2):299–304.
- [7] Stonecipher KG, Kezirian GM, Stonecipher K. LASIK for mixed astigmatism using the ALLEGRETTO WAVE: 3- and 6-month results with the 200- and 400-Hz platforms. *J Refract Surg*, 2010, 26(10):S819–S823.
- [8] Khalifa M, El-Kateb M, Shaheen MS. Iris registration in wavefront-guided LASIK to correct mixed astigmatism. *J Cataract Refract Surg*, 2009, 35(3):433–437.
- [9] De Ortueta D, Haecker C. Laser *in situ* keratomileusis for mixed astigmatism using a modified formula for bitoric ablation. *Eur J Ophthalmol*, 2008, 18(6):869–876.
- [10] Jin GJ, Merkley KH, Lyle WA. Laser *in situ* keratomileusis for primary and secondary mixed astigmatism. *Am J Ophthalmol*, 2005, 139(6):1019–1027.
- [11] Varley GA, Huang D, Rapuano CJ, Schallhorn S, Boxer Wachler BS, Sugar A; Ophthalmic Technology Assessment Committee Refractive Surgery Panel, American Academy of Ophthalmology. LASIK for hyperopia, hyperopic astigmatism, and mixed astigmatism: a report by the American Academy of Ophthalmology. *Ophthalmology*, 2004, 111(8):1604–1617.
- [12] Carones F, Vigo L, Scandola E. Laser *in situ* keratomileusis for hyperopia and hyperopic and mixed astigmatism with LADARVision using 7 to 10-mm ablation diameters. *J Refract Surg*, 2003, 19(5):548–554.
- [13] Salz JJ, Stevens CA; LADARVision LASIK Hyperopia Study Group. LASIK correction of spherical hyperopia, hyperopic astigmatism, and mixed astigmatism with the LADARVision excimer laser system. *Ophthalmology*, 2002, 109(9):1647–1656; discussion 1657–1658.
- [14] Azar DT, Primack JD. Theoretical analysis of ablation depths and profiles in laser *in situ* keratomileusis for compound hyperopic and mixed astigmatism. *J Cataract Refract Surg*, 2000, 26(8):1123–1136.
- [15] Chayet AS, Magallanes R, Montes M, Chavez S, Robledo N. Laser *in situ* keratomileusis for simple myopic, mixed, and simple hyperopic astigmatism. *J Refract Surg*, 1998, 14(2 Suppl): S175–S176.
- [16] Savini G, Barboni P, Carbonelli M, Hoffer KJ. Repeatability of automatic measurements by a new Scheimpflug camera combined with Placido topography. *J Cataract Refract Surg*, 2011, 37(10):1809–1816.
- [17] Auffarth GU, Tetz MR, Biazid Y, Völcker HE. Measuring anterior chamber depth with Orbscan Topography System. *J Cataract Refract Surg*, 1997, 23(9):1351–1355.
- [18] Reinstein DZ, Archer TJ, Randleman JB. JRS standard for reporting astigmatism outcomes of refractive surgery. *J Refract Surg*, 2014, 30(10):654–659.
- [19] Waring GO 3rd. Standard graphs for reporting refractive surgery. *J Refract Surg*, 2000, 16(4):459–466.
- [20] Chayet S, Montes M, Gómez L, Rodríguez X, Robledo N, MacRae S. Bitoric laser *in situ* keratomileusis for the correction of simple myopic and mixed astigmatism. *Ophthalmology*, 2001, 108(2):303–308.
- [21] Albarrán-Diego C, Muñoz G, Montés-Micó R, Alió JL. Bitoric laser *in situ* keratomileusis for astigmatism. *J Cataract Refract Surg*, 2004, 30(7):1471–1478.
- [22] Rueda L, Pineda-Fernández A, Huang D, Nur J. Laser *in situ* keratomileusis for mixed and simple myopic astigmatism

- with the Nidek EC-5000 Laser. J Refract Surg, 2002, 18(3): 234–238.
- [23] Holladay JT, Lynn MJ, Waring GO 3rd, Gemmill M, Keehn GC, Fielding B. The relationship of visual acuity, refractive error, and pupil size after radial keratotomy. Arch Ophthalmol, 1991, 109(1):70–76.
- [24] Tanzer DJ, Brunstetter T, Zeber R, Hofmeister E, Kaupp S, Kelly N, Mirzaoff M, Sray W, Brown M, Schallhorn S. Laser *in situ* keratomileusis in United States Naval aviators. J Cataract Refract Surg, 2013, 39(7):1047–1058.
- [25] Raasch TW. Spherocylindrical refractive errors and visual acuity. Optom Vis Sci, 1995, 72(4):272–275.

Corresponding author

Dragoş Cătălin Jianu, Professor of Neurology, MD, PhD, Senior Consultant Neurologist, Department of Neurology, “Victor Babeş” University of Medicine and Pharmacy, “Pius Brînzeu” Emergency County Hospital, 156 Liviu Rebreanu Street, IX Floor, Room 938, 300736 Timișoara, Romania; Phone/Fax +40256–486 956, Mobile +40723–626 527, e-mail: dcjianu@yahoo.com

Received: November 21, 2017

Accepted: June 17, 2018