

# Morphological assessment of the mandibular canal trajectory in edentate subjects

VICTOR NIMIGEAN<sup>1)</sup>, VALENTIN DANIEL SÎRBU<sup>2)</sup>, VANDA ROXANA NIMIGEAN<sup>3)</sup>, DANIELA GABRIELA BĂDIȚĂ<sup>4)</sup>, ALEXANDRU POLL<sup>1)</sup>, SIMONA ANDREEA MORARU<sup>3)</sup>, DIANA LORETA PĂUN<sup>5)</sup>

<sup>1)</sup>Department of Anatomy, Faculty of Dental Medicine, "Carol Davila" University of Medicine and Pharmacy, Bucharest, Romania

<sup>2)</sup>Department of Implant Prosthetic Therapy, Faculty of Dental Medicine, "Carol Davila" University of Medicine and Pharmacy, Bucharest, Romania

<sup>3)</sup>Department of Oral Rehabilitation, Faculty of Dental Medicine, "Carol Davila" University of Medicine and Pharmacy, Bucharest, Romania

<sup>4)</sup>Department of Physiology, Faculty of Dental Medicine, "Carol Davila" University of Medicine and Pharmacy, Bucharest, Romania

<sup>5)</sup>Department of Endocrinology, Faculty of Medicine, "Carol Davila" University of Medicine and Pharmacy, Bucharest, Romania

## Abstract

**Background:** The mandibular canal and its content represent the vital structure, which can complicate dentoalveolar surgical procedures in the posterior region of the mandible. The purpose of the present study was to determine the path the mandibular canal takes in relation to the horizontal and the vertical anatomical reference planes in edentate subjects, in order to minimize the risk of affecting its neurovascular content during various oral surgery procedures. **Materials and Methods:** Morphometric evaluations were performed on 12 dried fully edentulous human mandibles and on cone-beam computed tomography (CBCT) cross-sectional images of the mandible, from 20 patients with either partial or complete edentulism. Both methods were utilized, in three target areas (corresponding to the second premolar, to the first molar and to the second molar regions), in order to measure the distance between the mandibular canal and the following reference points: (i) the lateral (buccal) surface of the mandible (MC-BS distance); (ii) the medial (lingual) surface of the mandible (MC-LS distance); (iii) the alveolar surface of the mandible (MC-AS distance). The results were statistically processed in Stata MP/13 software package using analysis of variance (ANOVA) test. **Results:** The mandibular canal crossed the trabecular bone from the posterior towards the anterior, and from the lingual towards the buccal, reaching the premolar region, distal to the mental foramen, where it was located in the centre of the trabecular bone, main topographic pattern encountered in 27 (84.37%) of the cases. In five (15.63%) of the cases, in the premolar region, the mandibular canal was located near the buccal cortical plate. The mandibular canal descended from the second molar region towards the premolar region, main topographic pattern found in 28 (87.5%) of the cases. In four (12.5%) cases, the mandibular canal had a descending trajectory in the molar regions and it took a slightly ascending course in the premolar region. **Conclusions:** According to the results, the second molar region represents the highest risk area in the accidental injury to the content of the mandibular canal, during various oral surgery procedures.

**Keywords:** morphometrics, cross-sectional anatomy, CBCT, trajectory pattern, dental implants.

## Introduction

In dental medicine, the main maxillomandibular anatomic obstacles in various surgical procedures are the mandibular canal and the floor of the maxillary sinus, as well as the alveolar bone dehiscences and fenestration [1–4].

Dental implants restorations are the therapeutic options most requested by patients in the case of lateral edentulous areas located posterior to the remaining natural teeth. There also are difficult clinical cases, from a therapeutic standpoint, like in the case of edentation in a mandible with severe bone atrophy, which requires a certain type of mandibular canal management.

The major risk area for implant-prosthetic treatment in the mandible is the posterior region of its body, where the mandibular canal is located. In edentate subjects, the canal has a varying trajectory, and sometimes it may even vary between the two hemi-mandibles of the same individual. Therefore, in order to avoid affecting the

neurovascular content of the mandibular canal during oral implant surgery, the trajectory of the mandibular canal and its anatomic variations should be precisely determined [5–7].

After teeth loss, the top of the residual alveolar bone becomes a crest or a surface, and, depending on mandibular remodeling subsequent to dental extractions, the diameter of the mandibular canal becomes smaller, and its trajectory in the mandibular body alters [6].

Today, when oral rehabilitation by means of implant-prosthetics has become routine, frequent placement of dental implants in the posterior mandible has led to an increase in the number of neurosensory impairments and post-operative bleeding [6–10].

For this reason, implants osteotomies in the posterior mandible should only be prepared after determining the pathway of the mandibular canal [11, 12].

The purpose of the present study was to obtain a precise evaluation of the trajectory the mandibular canal takes in relation to the horizontal and the vertical

anatomical reference planes, in edentate human subjects, in order to determine a topographic pattern that could help practitioners in reaching the adequate therapeutic decision for every clinical case. The measurements were performed using both dried mandibles and cone-beam computed tomography (CBCT) data, the double evaluation of the trajectory of the mandibular canal being more eloquent and of high accuracy.

## Materials and Methods

Morphometric evaluations were performed on 12 dried fully edentulous human mandibles, available at the Division of Anatomy, Faculty of Dental Medicine, “Carol Davila” University of Medicine and Pharmacy, Bucharest, Romania, and on CBCT cross-sectional images of the mandible, from 20 patients with either mandibular lateral edentulous areas located posterior to the remaining natural teeth, or complete mandibular edentulism. The patients underwent CBCT imaging for dental treatment purpose. The investigations were conducted according to the current national legislation, and each patient gave informed consent to the use of his X-ray examination in scientific research.

Three mandibular buccal–lingual sections performed behind the mental foramen (in the region of the second premolar which we called the premolar region, in the region of the first molar which we called the first molar region, and in the region of the second molar which we called the second molar region) were analyzed by means of both methods (on dried edentate human mandibles and on imaging data), both on the left and right sides.

In order to obtain as precise of a distinction as possible between the regions (premolar, first and second molar regions), we took into account the mesiodistal crown dimensions of the second premolar, the first molar and the second molar. Thus, the mean value of the mesiodistal crown width was 7.1 mm for the second premolar, 11.4 mm for the first molar and 10.8 mm for the second molar. We also took into account the minimum and maximum values of the same mesiodistal crowns width, 5.2 and 9.5 mm for the second premolar, 9.8 and 14.5 mm for the first molar, and 9.6 and 13 mm for the second molar [13].

To fulfill the objectives of the present study, we determined the distance between the mandibular canal and the following reference points:

- the alveolar surface (top of the alveolar ridge) of the mandible (MC-AS distance);
- the buccal (lateral) surface of the mandible (MC-BS distance);
- the lingual (medial) surface of the mandible (MC-LS distance).

The dried human mandibles were sectioned using a circular diamond edge saw blade, with a diameter of 40 mm, held by a mandrel and activated by a micromotor handpiece running at conventional speed, continually cooled with saline solution. The measurements were made with a Workzone digital caliper (Globaltronics GmbH & Co. KG, Singapore). Some of the sections were photographed with a Canon DS 126191 digital camera.

The machine used for the CBCT was a NewTom VGi imaging unit, with the following technical parameters: 110 kV, 1–20 mA, X-ray emission during a period of 18 seconds, and effective dose being 100  $\mu$ SV. Data were processed using Planmeca Romexis<sup>®</sup> Viewer on a computer with the following specifications: Intel<sup>®</sup> Core™ i7 Processor, 16 GB System Memory, NVIDIA GTS 250 graphics card, Hard Disk 2 TB, Windows 10 Pro Operating System. The measurements expressed in millimeters, on mandibular sections, are at a scale of 1:1.

The results obtained both by the direct and by the imaging methods were processed in Stata MP/13 software package using analysis of variance (ANOVA) test. *P*-value  $\leq 0.05$  was considered statistically significant.

## Results

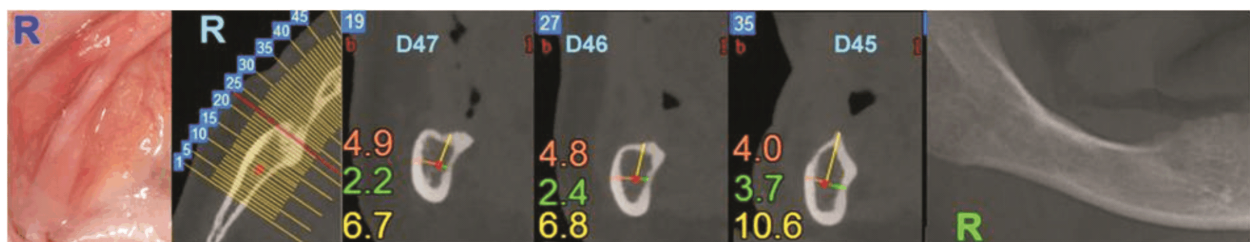All the analyzed cases bilaterally exhibited a single mandibular canal.

The most suggestive results are presented in the following Figures and Tables.

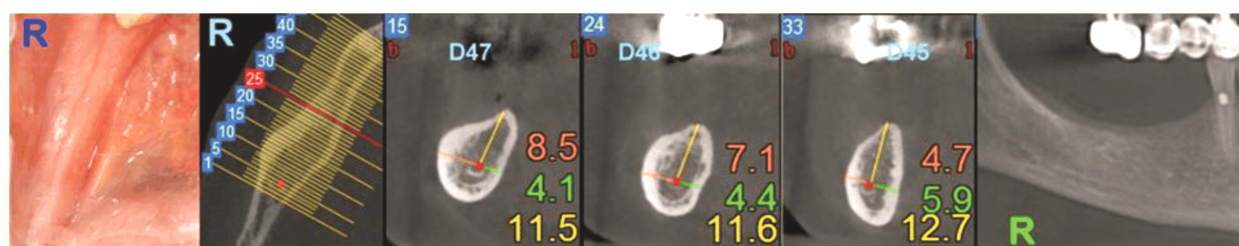A series of mandibular cross-sections carried out through CBCT and morphometrically evaluated, can be observed in Figures 1 and 2.

In Figures 3 and 4, morphometric evaluations on cross-sections of dried mandibles are shown.

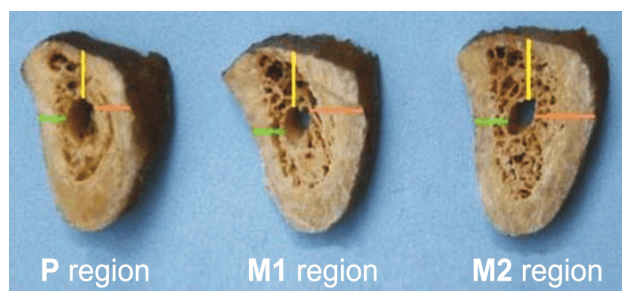
In the following Tables (1–6), statistically processed analysis of the three studied parameters can be observed. It must be noted that *N* – No. of cases, *SD* – Standard deviation, *SE* – Standard error, and 95% *CI* – 95% Confidence interval for the average.



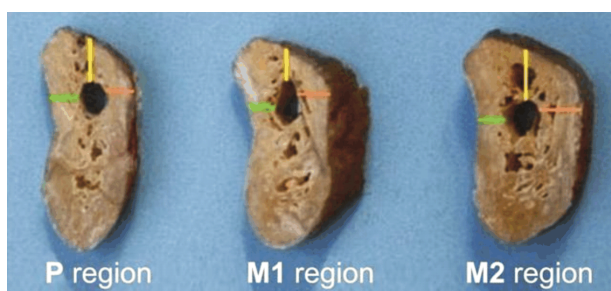
**Figure 1** – CBCT: right (R) hemi-mandible. Buccal-lingual sections at the level of the premolar, first and second molar regions. Orange – MC-BS distance; yellow – MC-AS distance; green – MC-LS distance. CBCT: Cone-beam computed tomography; MC-BS distance: Distance between the mandibular canal and the buccal (lateral) surface of the mandible; MC-AS distance: Distance between the mandibular canal and the alveolar surface of the mandible of the level of the premolar, first and second molar regions; MC-LS distance: Distance between the mandibular canal and the lingual (medial) surface of the mandible.



**Figure 2 – CBCT: right (R) hemi-mandible. Bucco-lingual sections at the level of the premolar, first and second molar regions. Orange – MC-BS distance; yellow – MC-AS distance; green – MC-LS distance. CBCT: Cone-beam computed tomography; MC-BS distance: Distance between the mandibular canal and the buccal (lateral) surface of the mandible; MC-AS distance: Distance between the mandibular canal and the alveolar surface of the mandible of the level of the premolar, first and second molar regions; MC-LS distance: Distance between the mandibular canal and the lingual (medial) surface of the mandible.**



**Figure 3 – Right hemi-mandible. Bucco-lingual sections at the level of the premolar, first and second molar regions. Orange – MC-BS distance; yellow – MC-AS distance; green – MC-LS distance. MC-BS distance: Distance between the mandibular canal and the buccal (lateral) surface of the mandible; MC-AS distance: Distance between the mandibular canal and the alveolar surface of the mandible of the level of the premolar, first and second molar regions; MC-LS distance: Distance between the mandibular canal and the lingual (medial) surface of the mandible.**



**Figure 4 – Left hemi-mandible. Bucco-lingual sections at the level of the premolar, first and second molar regions. Orange – MC-BS distance; yellow – MC-AS distance; green – MC-LS distance. MC-BS distance: Distance between the mandibular canal and the buccal (lateral) surface of the mandible; MC-AS distance: Distance between the mandibular canal and the alveolar surface of the mandible of the level of the premolar, first and second molar regions; MC-LS distance: Distance between the mandibular canal and the lingual (medial) surface of the mandible.**

Table 1 illustrates the results regarding the distance between the mandibular canal and the lateral (buccal) surface of the mandibular body (MC-BS distance), measured on CBCT, on the three levels. This distance, varied between 2.2–5.2 mm at the level of the premolar region, between 3.1–7.1 mm at the level of the region of first molar, and between 3.5–8.5 mm at the level of the region of second molar. The mean values of this distance were as follows: 3.97 mm at the level of the premolar region, 5.12 mm at the level of the first molar region, and 5.87 mm at the level of the second molar region.

Table 2 illustrates the results regarding the distance between the mandibular canal and the lateral (buccal) surface of the mandibular body (MC-BS distance), measured on dried mandibles, on the three levels. This distance, varied between 3.5–7 mm at the level of the premolar region, between 4–7 mm at the level of the region of first molar, and between 4–7.4 mm at the level of the second molar. The mean values of this distance were as follows: 4.89 mm at the level of the second premolar, 5.47 mm at the level of the first molar and 5.69 mm at the level of the second molar region.

Table 3 illustrates the results regarding the distance between the mandibular canal and the medial (lingual) surface of the mandibular body (MC-LS distance), measured on CBCT, on the three levels. This distance varied between 2.2–7.7 mm at the level of the premolar

region, between 1.2–6.8 mm at the level of the first molar region, and between 1.2–4.6 mm at the level of the second molar region. The mean values of this distance were: 4.43 mm at the level of the premolar region, 3.34 mm at the level of the first molar region, and 3.23 mm at the level of the second molar region.

Table 4 illustrates the results regarding the distance between the mandibular canal and the medial (lingual) surface of the mandibular body (MC-LS distance), measured on dried mandibles, on the three levels. This distance varied between 4–7.4 mm at the level of the premolar region, between 2.5–6.1 mm at the level of the first molar region, and between 2.5–5.2 mm at the level of the second molar region. The mean values of this distance were: 5.69 mm at the level of the premolar region, 3.85 mm at the level of the first molar region, and 3.6 mm at the level of the second molar region.

Table 5 illustrates the results regarding the distance between the mandibular canal and the mandibular alveolar surface (top of the alveolar ridge) (MC-AS distance), measured on CBCT, on the three levels. This distance varied between 3–20 mm in the premolar region, between 3–16.8 mm in the first molar region, and between 2.1–15.5 mm in the second molar region. The statistical analysis proved that this distance had the following mean values: 11.03 mm in the premolar region, 9.6 mm in the first molar region, and 8.46 mm in the second molar region.

Region	N	Mean	SD	MC-LS distance [mm]				
				SE	95% CI	Minimum	Median	Maximum
				Right				
Premolar	12	5.71	0.31	1.06	5.03–6.38	4	5.15	7.1
First molar	12	3.84	0.3	1.05	3.17–4.51	2.5	3.75	6.1
Second molar	12	3.53	0.23	0.8	3.02–4.04	2.5	3.4	5.1
ANOVA test; $p=0.0005$								



MC-LS distance [mm]								
Region	N	Mean	SD	SE	95% CI	Minimum	Median	Maximum
<i>Left</i>								
Premolar	12	5.68	0.29	1	5.04–6.31	4.4	5.3	7.4
First molar	12	3.87	0.27	0.94	3.27–4.46	2.8	3.75	6
Second molar	12	3.68	0.22	0.78	3.18–4.17	2.8	3.5	5.2

ANOVA test;  $p < 0.0001$ 

MC-LS distance: Distance between the mandibular canal and the lingual (medial) surface of the mandible; N: No. of cases; SD: Standard deviation; SE: Standard error; CI: Confidence interval; ANOVA: Analysis of variance.

Table 5 – MC-AS distance (measurements on CBCT images)

MC-AS distance [mm]								
Region	N	Mean	SD	SE	95% CI	Minimum	Median	Maximum
<i>Right</i>								
Premolar	20	10.97	1.01	4.53	8.85–13.09	3.1	11.7	17
First molar	20	9.53	0.94	4.22	7.55–11.51	3	11.25	16.8
Second molar	20	8.34	0.83	3.7	6.61–10.07	2.5	9.1	13.4
<i>Left</i>								
Premolar	20	11.09	1.12	5.02	8.74–13.44	3	11.35	20
First molar	20	9.67	1.03	4.61	7.51–11.83	3.2	10.1	16.5
Second molar	20	8.58	0.95	4.26	6.58–10.57	2.1	8.95	15.5

ANOVA test;  $p = 0.1856$ ANOVA test;  $p = 0.1753$ 

MC-AS distance: Distance between the mandibular canal and the alveolar surface of the mandible of the level of the premolar, first and second molar regions; CBCT: Cone-beam computed tomography; N: No. of cases; SD: Standard deviation; SE: Standard error; CI: Confidence interval; ANOVA: Analysis of variance.

Table 6 – MC-AS distance (measurements on dried mandibles)

MC-AS distance [mm]								
Region	N	Mean	SD	SE	95% CI	Minimum	Median	Maximum
<i>Right</i>								
Premolar	12	6.38	0.81	2.81	4.60–8.17	3	6	12.7
First molar	12	5.27	0.61	2.11	3.93–6.61	3	5	10.1
Second molar	12	4.58	0.41	1.4	3.68–5.47	3	4.3	8
<i>Left</i>								
Premolar	12	6.38	0.77	2.68	4.67–8.08	3.5	5.5	12
First molar	12	5.43	0.49	1.7	4.34–6.51	3.3	5.1	9
Second molar	12	4.66	0.38	1.32	3.82–5.5	3.2	4.4	7.7

ANOVA test;  $p < 0.0001$ 

MC-AS distance: Distance between the mandibular canal and the alveolar surface of the mandible of the level of the premolar, first and second molar regions; N: No. of cases; SD: Standard deviation; SE: Standard error; CI: Confidence interval; ANOVA: Analysis of variance.

## Discussions

In the statistical analysis, we did not take into account the gender of the patients, because specialized literature does not point out obvious differences regarding the trajectory of the mandibular canal, between females and males. The age of the patients was not taken into account because we were only interested in the extent of alveolar atrophy, irrespective of the age of its onset. We also did not take into account the third molar region, because it is an unused area for oral implants placement.

The values obtained on dried mandibles and on CBCT images in the case of MC-BS and MC-LS distances were similar, the differences not exceeding 1.2 mm. In the case of MC-AS distance, there were significant differences, exceeding 1.2 mm between the values obtained on dried mandibles and on CBCT images, because we only analyzed fully edentulous dried mandibles, with a higher degree of atrophy, while by means of imaging data we also analyzed partially edentulous mandibles, with a lesser

degree of atrophy. Regarding the data obtained studying the parameters on both the left and right sides, these were comparable and similar, with differences not exceeding 1 mm.

In order to determine the transverse (buccal–lingual) trajectory of the mandibular canal in the mandibular body, we statistically determined and analyzed the distances between the mandibular canal and the external mandibular surfaces, MC-BS and MC-LS distance.

The distance between the mandibular canal and the lateral (buccal) surface of the mandibular body (MC-BS distance), measured on dried mandibles and on CBCT images, varied between 2.2–7 mm in the premolar region, between 3.1–7.1 mm in the region of the first molar, and between 1.5–8.5 mm in the region of the second molar. This distance had the following statistically determined mean values: 4.44 mm in the premolar region, 5.32 mm in the region of the first molar, and 5.78 mm in the region of the second molar. These values prove that the distance

between the mandibular canal and the buccal surface of the mandibular body drops progressively from the second molar to the second premolar, which indicates that in its anterior trajectory, the mandibular canal nears the buccal cortical bone. The statistical analysis showed that MC-BS distance differs significantly between the premolar region, the first molar region, and the second molar region, on both the left and right sides ( $p < 0.05$ ).

The distance between the mandibular canal and the medial (lingual) surface of the mandibular body (MC-LS distance), measured on dried mandibles and on CBCT images, varied between 2.2–7.7 mm in the premolar region, between 1.2–6.8 mm in the first molar region, and 1.2–5.2 mm in the second molar region. The statistical analysis showed that this distance had the following mean values: 5.04 mm in the premolar region, 3.59 mm in the region of the first molar, and 3.45 mm in the region of the second molar. These findings indicate that the distance between the mandibular canal and the lingual surface of the mandibular body drops progressively from the premolar region to the second molar region, opposite behavior to that found when comparing the distance between the mandibular canal and the buccal surface of the mandible, aspect which proves that in its anterior trajectory, the mandibular canal distances itself from the lingual cortical bone. The statistical analysis showed that MC-LS distance differs significantly between the region of the second premolar, the region of the first molar, and the region of the second molar, both on the left and right sides ( $p < 0.05$ ).

An important aspect, unmentioned in the reviewed specialized literature, is the fact that in the premolar region, distal to the mental foramen, the mandibular canal is located halfway between the buccal surface and the lingual surface of the mandible. According to the data collected, the position of the mandibular canal with respect to the lateral and medial mandibular surfaces also depends on the buccal–lingual dimension of the posterior mandible.

According to the results of our study, we established the main pattern regarding the buccal–lingual trajectory of the mandibular canal in edentate human specimens: it has an anterior and lateral direction, from the level of the second molar region to the premolar region, where it is located in the middle of the mandibular trabecular bone. This main buccal–lingual topographic pattern of the mandibular canal was found in 27 (84.37%) of the analyzed cases. In five (15.63%) cases in the premolar region, the mandibular canal was closer to the buccal cortical plate.

Certain such similarities regarding the buccal–lingual trajectory of the mandibular canal were also mentioned in some of the analyzed bibliographic references, but the results of this study showed different values and different topography of the mandibular canal in the premolar region, distal to the mental foramen.

Our results contradict the findings of Kim *et al.* (2009) [3], who showed that at the level of the mandibular body, the mandibular canal presents three topographic patterns related to the buccal–lingual plane [4].

The mean distance of  $5.23 \pm 1.71$  mm between the mandibular canal and the buccal surface of the mandibular body, as presented by Al-Siweedi *et al.* (2014) is greater

than that reported by other authors [14]. According to Levine *et al.* (2007), this distance has an average of 4.9 mm [15], and according to Kilic *et al.* (2010), it is 4.58 mm [16]. While these findings are more general, our data are more precise and presented in relation to each missing lateral tooth area, which is an especially important aspect for the clinician.

Another general report regarding the horizontal trajectory of the mandibular canal belongs to Hwang *et al.* (2005), who presented the mandibular canal as being closer to the lingual surface in the posterior two thirds, but closer to the buccal surface in the anterior one third of the mandible [17].

Comparing the results regarding the horizontal trajectory of the mandibular canal in edentate patients to those found in dentate patients, from a previous study [18], we can state that there are no great differences in the target work regions, which proves the existence of a mandibular horizontal atrophy that mainly involves the buccal bone. In the case of such an advanced atrophy, placing endosseous implants towards the lingual is a surgical option with an unfavorable outcome, as osseointegration might be affected upon the implants load. A better surgical approach in cases of extensive mandibular horizontal atrophy is bone augmentation prior to implants placement.

So as to establish the vertical trajectory pattern of the mandibular canal in the mandibular body, we determined, on dried mandibles and on CBCT images, and statistically analyzed, the distance between the mandibular canal and the mandibular alveolar surface (top of the alveolar ridge), MC-AS distance. This distance varied between 3–20 mm in the premolar region, 3–16.8 mm in the first molar region, and between 2.1–15.5 mm in the second molar region. The statistical analysis proved that this distance had the following mean values: 8.73 mm in the premolar region, 7.47 mm in the first molar region, and 6.58 mm in the second molar region. It also proved that the MC-AS distance differs significantly in the three target work areas, both on the right and left sides, but only in the case of morphometric evaluation on dried mandibles ( $p < 0.05$ ).

These results evince the main pattern of the mandibular canal's vertical trajectory, characterized by the canal's location in the superior half of the mandibular body, descending from the second molar region to the premolar region. This main vertical topographic pattern of the mandibular canal was found in 28 (87.5%) of the analyzed cases. In four (12.5%) cases, the mandibular canal had a descending course in the posterior two thirds and a slightly ascending course in the anterior one third of the mandibular body.

Certain similarities regarding this type of vertical trajectory of the mandibular canal are to be found in the reviewed specialized literature, the data being partially comparable with the results of the present study.

According to Kieser *et al.* (2005), in 70–73% of the cases, in edentate subjects, the mandibular canal is located in the inferior half of the mandible, finding that is contradictory to our results [7].

Other authors show that in edentate patients, the mandibular canal was located in the superior half of the

mandibular body in 30.7% of the cases, and in 69.3% of the cases, it was located closer to the middle of the mandibular height or to the lower edge of the mandible [19].

According to Kubilius *et al.* (2004), the distance between the alveolar ridge and the mandibular canal is approximately 8–10 mm at the level of the third molar, 8–12 mm at the level of the second molar, 13.5–17 mm at the level of the second premolar, and 14–17 mm at the level of the first premolar, findings very different from the ones we presented [20].

Comparing the data, we established three classes of mandibular atrophy: class I, incipient atrophy, with available bone height over 9 mm (MC-AS distance); class II, advanced atrophy, with available bone height between 9 mm and 6 mm; class III, severe atrophy, with available bone height less than 6 mm. We did not take into account the width of the available bone because, in all analyzed cases, this parameter was dimensionally adequate for the implant.

At the level of the target work areas, the atrophy classes had the following representation, percentage-wise: in the premolar region, class I was present in 46.87% of cases, class II in 25.01% of cases, and class III in 28.12% of cases; in the region of the first molar, class I was present in 40.63% of the cases, class II in 12.5% of cases and class III in 46.87% of cases; in the region of the second molar, class I was present in 34.37% of cases, class II in 15.62% of cases, and class III in 50% of cases. Overall, severe atrophy was present in 41.33% of the cases. This anatomic condition makes placing dental implants in the posterior mandible difficult and complicated, due to the high risk of damaging the inferior alveolar neurovascular bundle.

Ulm *et al.* (1993) showed that in edentulous lower jaws the distance between the mandibular canal and the buccal and lingual surfaces of the mandible does not change in relation to atrophy stages and remains visibly constant, statement at odds with our findings. Also, these authors showed that the distance between the mandibular canal and the top of the alveolar ridge is much more affected by the atrophying process, observation we also noted [21].

Certain similarities regarding the types of mandibular atrophy were signaled in certain bibliographic references [22], but the data obtained in this study were very different.

The anatomical variations regarding the trajectory of the mandibular canal are important because they increase the risk of damaging the content of the mandibular canal. In such situations, the revising of morphological data, of therapeutic considerations and of the potential consequences of inadequate therapy, is required [23–26].

CBCT evaluation of the posterior region of the mandible in patients with a high risk of damaging the inferior alveolar neurovascular bundle is a necessity in oral surgical procedures (extraction of impacted teeth, implant surgery, orthognathic surgery, fracture surgery), because the mandibular canal, vital reference point, may complicate such treatments, due to the high risk of being injured.

## Conclusions

For a successful oral surgery procedure in the posterior mandible, the practitioner must have a clear and precise image of the area, which can be obtained by combining all the findings from the clinical examination with the data obtained through imaging procedures. For dental implants placement, a 1.5–2 mm safety distance to the mandibular canal is recommended, in order to avoid a potential damaging of its content. Failure to respect the safety distance is responsible for the most severe complications in the case of oral rehabilitation with dental implants in the posterior mandible.

## Conflict of interests

The authors declare that they have no conflict of interests.

## Acknowledgments

Part of the research for this paper was conducted within Valentin Daniel Sîrbu PhD Thesis “Management of the mandibular canal during the prosthetic treatment of severely atrophic edentulous mandible”.

## Author contribution

Author #1 (Victor Nimigean), author #2 (Valentin Daniel Sîrbu) and author #4 (Daniela Gabriela Bădiță) have equal contributions to this paper and thus are main authors.

## References

- [1] Nimigean VR, Nimigean V, Maru N, Andressakis D, Balatsouras D, Danielidis V. The maxillary sinus and its endodontic implications: clinical study and review. *B-ENT*, 2006, 2(4):167–175.
- [2] Nimigean V, Nimigean VR, Măru N, Sălăvăstru DI, Bădiță D, Tuculină MJ. The maxillary sinus floor in the oral implantology. *Rom J Morphol Embryol*, 2008, 49(4):485–489.
- [3] Kim ST, Hu KS, Song WC, Kang MK, Park HD, Kim HJ. Location of the mandibular canal and the topography of its neurovascular structures. *J Craniofac Surg*, 2009, 20(3): 936–939.
- [4] Nimigean VR, Nimigean V, Bencze MA, Dimcevi-Poesina N, Cergan R, Moraru S. Alveolar bone dehiscences and fenestration: an anatomical study and review. *Rom J Morphol Embryol*, 2009, 50(3):391–397.
- [5] Sălăvăstru DI. Clinical and experimental studies on dental implants osseointegration. PhD Thesis, “Carol Davila” University of Medicine and Pharmacy, Bucharest, Romania, 2014, 17–23.
- [6] Sîrbu VD. Management of the mandibular canal during the prosthetic treatment of severely atrophic edentulous mandible. PhD Thesis, “Carol Davila” University of Medicine and Pharmacy, Bucharest, Romania, 2015, 19–25, 41–70.
- [7] Kieser J, Kieser D, Hauman T. The course and distribution of the inferior alveolar nerve in the edentulous mandible. *J Craniofac Surg*, 2005, 16(1):6–9.
- [8] Kalpidis CD, Setayesh RM. Hemorrhaging associated with endosseous implant placement in the anterior mandible: a review of the literature. *J Periodontol*, 2004, 75(5):631–645.
- [9] Abarca M, van Steenberghe D, Malevez C, De Ridder J, Jacobs R. Neurosensory disturbances after immediate loading of implants in the anterior mandible: an initial questionnaire approach followed by a psychophysical assessment. *Clin Oral Investig*, 2006, 10(4):269–277.
- [10] Juodzbalys G, Wang HL. Identification of the mandibular vital structures: practical clinical applications of anatomy and radiological examination methods. *J Oral Maxillofac Res*, 2010, 1(2):e1.
- [11] Juodzbalys G, Wang HL, Sabalys G. Anatomy of mandibular vital structures. Part I: mandibular canal and inferior alveolar neurovascular bundle in relation with dental implantology. *J Oral Maxillofac Res*, 2010, 1(1):e2.

- [12] Rashid SA, Ali J. Morphometric analysis of mandibular canal course and position in relation to gender and age of Iraqi sample using digital panoramic imaging. *J Baghdad Coll Dentistry*, 2011, 23(Special issue):92–99.
- [13] Woelfel JB, Scheid RC. Dental anatomy – its relevance to dentistry. 5<sup>th</sup> edition, Williams & Wilkins, Baltimore, Maryland, USA, 1997, 178, 215.
- [14] Al-Siweedi SYA, Nambiar P, Shanmuhasuntharam P, Ngeow WC. Gaining surgical access for repositioning the inferior alveolar neurovascular bundle. *Scientific World Journal*, 2014, 2014: 719243.
- [15] Levine MH, Goddard AL, Dodson TB. Inferior alveolar nerve canal position: a clinical and radiographic study. *J Oral Maxillofac Surg*, 2007, 65(3):470–474.
- [16] Kilic C, Kamburoğlu K, Ozen T, Balcioglu HA, Kurt B, Kutoglu T, Ozan H. The position of the mandibular canal and histologic feature of the inferior alveolar nerve. *Clin Anat*, 2010, 23(1): 34–32.
- [17] Hwang K, Lee WJ, Song YB, Chung IH. Vulnerability of the inferior alveolar nerve and mental nerve during genioplasty: an anatomic study. *J Craniofac Surg*, 2005, 16(1):10–14; discussion 14.
- [18] Sîrbu VD, Perlea P, Nimigean VR, Bădiță DG, Șerban A, Nimigean V. Morphological assessment of the mandibular canal trajectory in dentate subjects. *Rom J Morphol Embryol*, 2017, 58(4):1401–1408.
- [19] Watanabe H, Mohammad Abdul M, Kurabayashi T, Aoki H. Mandible size and morphology determined with CT on a premise of dental implant operation. *Surg Radiol Anat*, 2010, 32(4):343–349.
- [20] Kubilius R, Sabalys G, Juodzbals G, Gedrimas V. Traumatic damage to the inferior alveolar nerve sustained in course of dental implantation. Possibility of prevention. *Stomatologija, Baltic Dental and Maxillofacial Journal*, 2004, 6(4):106–110.
- [21] Ulm CW, Solar P, Blahout R, Matejka M, Watzek G, Gruber H. Location of the mandibular canal within the atrophic mandible. *Br J Oral Maxillofac Surg*, 1993, 31(6):370–375.
- [22] Juodzbals G, Kubilius M. Clinical and radiological classification of the jawbone anatomy in endosseous dental implant treatment. *J Oral Maxillofac Res*, 2013, 4(2):e2.
- [23] Wadhvani P, Mathur RM, Kohli M, Sahu R. Mandibular canal variant: a case report. *J Oral Pathol Med*, 2008, 37(2):122–124.
- [24] Nemati S, Ashouri Moghadam A, Dalili Kajan Z, Mohtavipour ST, Amouzad H. An analysis of visibility and anatomic variations of mandibular canal in digital panoramic radiographs of dentulous and edentulous patients in northern Iran populations. *J Dent (Shiraz)*, 2016, 17(2):112–120.
- [25] Manikandhan R, Mathew PC, Naveenkumar J, Anantanarayanan P. A rare variation in the course of the inferior alveolar nerve. *Int J Oral Maxillofac Surg*, 2010, 39(2):185–187.
- [26] Eliades AN, Papadeli C, Tsirlis AT. Mandibular canal, foramina of the mandible and their variations: part II: the clinical relevance of the preoperative radiographic evaluation and report of five cases. *Oral Surg*, 2016, 9(2):85–93.

### **Corresponding author**

Vanda Roxana Nimigean, Associate Professor, DMD, PhD, Head of Oral Rehabilitation Department, Faculty of Dental Medicine, “Carol Davila” University of Medicine and Pharmacy, 17–23 Calea Plevnei Street, 060015 Bucharest, Romania; Phone +40721–561 848, e-mail: vandanimigean@yahoo.com

*Received: December 8, 2017*

*Accepted: May 27, 2018*