

Vestibular sensory functional status of cochlear implanted ears *versus* non-implanted ears in bilateral profound deaf adults

ROMICĂ SEBASTIAN COZMA¹⁾, LUCIA CORINA DIMA-COZMA²⁾, LUMINIȚA MIHAELA RĂDULESCU¹⁾, MARIA CRISTINA HERA¹⁾, CRISTIAN MĂRȚU¹⁾, RALUCA OLARIU¹⁾, BOGDAN MIHAIL COBZEANU³⁾, OANA ROXANA BITERE¹⁾, MIHAIL DAN COBZEANU¹⁾

¹⁾Department of Otorhinolaryngology, Faculty of Medicine, "Grigore T. Popa" University of Medicine and Pharmacy, Iași, Romania

²⁾Department of Internal Medicine, Faculty of Medicine, "Grigore T. Popa" University of Medicine and Pharmacy, Iași, Romania

³⁾ENT Clinic, Rehabilitation Clinical Hospital, Iași, Romania

Abstract

Patients with hearing loss who underwent cochlear implantation can present symptomatic or asymptomatic vestibular damages earlier or later after the surgery. The vestibular permanent lesions could be acute, produced by surgical trauma or could be progressive due to local morphological changes made by the presence of the portelectrode in the inner ear (fibrosis related, ossification, basilar membrane distortion, endolymphatic hydrops). Besides histopathological findings in inner ear of cochlear implanted patients, the vestibular permanent damages could be found by assessment of clinical vestibular status. This study reports the sensorial vestibular functional findings for adults in cochlear implanted ears related to the electrode insertion type (cochleostomy or round window approach) and comparing to non-implanted deaf ears. A total of 20 adult patients with 32 cochlear implanted ears (12 patients with binaural cochlear implant and eight with monoaural) were selected for postoperative vestibular examination by cervical and ocular vestibular myogenic potentials and vestibular caloric tests. The same tests were made for a control group of 22 non-implanted deaf ears. Functional testing results were reported related to the electrode insertion approach. For the cochleostomy group, we found different deficits: in 40% for saccular function, 44% for utricular function, and 12% horizontal canal dysfunction. In round window group, the deficit was present in 14.29% for saccular function, 28.57% for utricular function, and 28.58% for horizontal canal. In 46.88% of implanted ears, the vestibular function was completely preserved on all tested sensors. In conclusion, the vestibular functional status after inner ear surgery presents sensorial damages in 53.12% ears compare with the vestibular dysfunction existing in 50% of deaf non-operated ears. Round window insertion allows for better conservation of the vestibular function.

Keywords: vestibular function, cochlear implant, cochleostomy, round window.

Introduction

Cochlear implantation, a successful procedure to restore the hearing in deaf adults and children, is already widely used in the world. In the last years, the bilateral cochlear implantation became the standard especially in bilateral congenital profound deafness in children. Different pathological vestibular symptoms or damages were reported in cochlear implanted patients in post-operative period or later in time. The anatomical reports between cochlear and vestibular spaces could prone the vestibular dysfunction due to cochlear implantation. Despite the increased interest for this topic in the last years, still there is a limited number of studies about vestibular possible consequences after cochlear implant surgery.

The insertion of the electrode array may damage the vestibular peripheral receptor, as it is demonstrate by some histopathological studies [1]. Handzel *et al.* show that in 59% of the implanted bones the cochlea was hydropic and in the majority of study bones the saccula was collapsed [2]. The mechanism could be represented

by the portelectrode insertion process inducing a cochlear direct trauma, as well as: perilymphatic fistula, endolymphatic hydrops, intraoperative gusher, autoimmune reaction in inner ear caused by the presence of the electrode, local infectious contamination, vascular lesions (ischemic or hemorrhagic) or direct electric stimulation [3].

The vestibular aggression could be followed by a transitory balance disorder, but sometimes the vestibular damage could be permanent. For unilateral permanent vestibular impairment, medical treatment and vestibular rehabilitation are efficient for vestibular compensation in order to restore the patient's balance [4]. If the cochlear implantation is performed on both ears and the vestibular peripheral system is bilaterally affected, the consequences on patient's balance could be very serious, especially in children [5]. The vestibular status can be assessed nowadays by specific functional tests available for adults and children. In some rare particular cases of deaf patients with associate vestibular and additional injuries (genetic rare diseases), the vestibular assessment before the cochlear implant surgery could be very limited due to malformations of the ear or more complex, muscular deficits

(oculomotor, cervical and facial) making impossible to record ocular and cervical vestibular evoked myogenic potentials or to perform vestibular caloric tests [6].

As more and more patients are cochlear implanted every year, the number of patients exposed to vestibular damage risk increases. In order to limit the potential structural and functional inner ear damages, the medical and technical researchers are working on two directions: to create smaller and less traumatic devices and to establish the minimal invasive possible surgical technique [7]. In this regard in the last years, different authors present advantages and disadvantages of two possible inner ear approaches: cochleostomy (CO) and round window (RW) electrode insertion. The vestibular impairment prevalence due to cochlear implantation reported by different authors is highly variable, as well as its association with each insertion technique [8].

The aim of our study was to evaluate the status of vestibular peripheral sensors in cochlear implanted ears *versus* non-implanted deaf ears in adults and to analyze a possible correlation of postoperative vestibular sensory status with the type of electrode insertion approach: cochleostomy and round window.

☞ Patients, Materials and Methods

In this retrospective cohort study, we included 27 adult patients (age range 16 to 73 years, with a mean of

42.40 years) with bilateral profound acquired hearing loss, excepting meningitis, post-traumatic deafness or otospongiosis and without any known vestibular disease in history. Some of them underwent surgery for cochlear implant for both ears (12 patients), others for one ear (eight patients), and the rest were not implanted (seven patients). From this group of patients, we selected a subgroup of cochlear implanted patients (32 ears with a mean age of 41.71 years) and a second group of non-implanted patients (22 ears with a mean age of 42.95 years), without any otological surgery in the past. We included only patients that have complete cochlear insertion of the portelectrode and who underwent a complete vestibular sensorial battery assessment with interpretable results for all tests.

The cochlear implantations were done by the same surgeon and cochlear systems were provided by Cochlear (CI 24R and CI 522), MedEl (Concerto and Synchrony system) and Oticon/Neurelec (Digisonic SP and Digisonic SP Binaural). The surgical approach was classic, with retroauricular incision, mastoidectomy and posterior tympanotomy. The insertion type was the intraoperative surgeon's choice, depending of the local anatomy for the best placement of the electrode: through the round window in seven cases (sometimes was necessary to remove a part of the RW lip for a better view) or through cochleostomy in 25 cases (Figures 1 and 2).

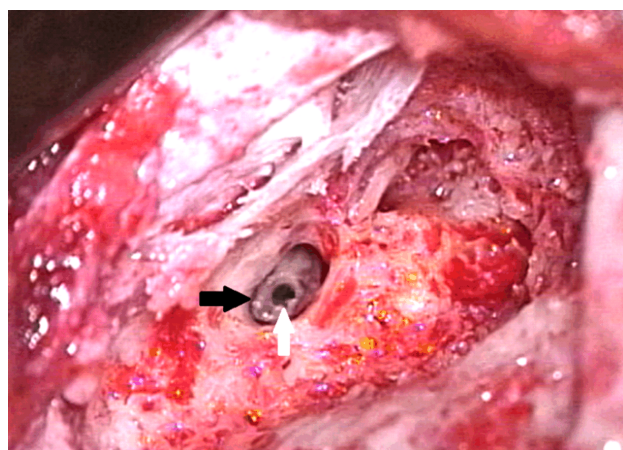


Figure 1 – Intraoperative image of cochleostomy for cochlear electrode insertion (pointed by white arrow), performed after mastoidectomy and posterior tympanotomy (pointed by black arrow).

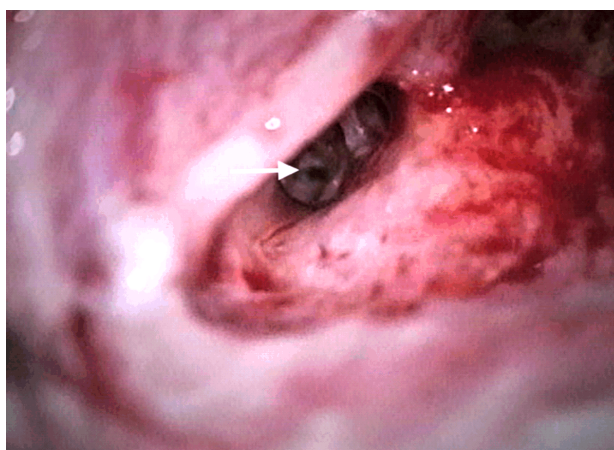


Figure 2 – Intraoperative image of round window approach for cochlear electrode insertion (pointed by white arrow), performed after mastoidectomy and posterior tympanotomy.

A plain temporal bone radiography (modified Stenvers view) was performed for each implanted ear to verify the correct placement of intracochlear electrodes and receiver-stimulator postoperative position.

The time between cochlear implant surgery and the vestibular examinations ranged from three to 22 months.

Each patient was assessed for vestibular status of peripheral sensors using the same examination protocol including the following tests: clinical examination of the ear, tympanometry, bithermal air caloric test for horizontal semicircular canal, cervical and ocular vestibular evoked myogenic potentials (cVEMP, oVEMP).

The horizontal semicircular canal function was measured by vestibular caloric test, after a cardiovascular examination, including determination of arterial blood

pressure, heart rate and electrocardiogram recording. This examination was made in order to exclude patients with cardiovascular diseases, preventing the risk of side neurovegetative reactions, which could happen along the vestibular caloric stimulation in adults. The caloric ear irrigation was performed by irrigating the external auditory canal with a flow of warm air at 50°C and cold air at 24°C by Air Fx Caloric stimulator, Interacoustics, Denmark, for 60 seconds on each ear. The tests were made sequentially, with at least seven minutes of pause between. During this test, the patient was lying down with the head elevated at 30° reported to horizontal plane. The nistagmus elicited by air caloric irrigation through the external auditory canal was observed with an infrared camera and its duration and direction were recorded for

each run test. The tests were performed according to *British Audiology Society* guidelines [9].

The saccular sensorial organ activity was measured by cVEMP, recorded on lying down patient by sound air conduction stimulation, tone burst at 500 Hz at 100 dB nHL (decibels above normal adult hearing level) through ear insert phones, 2 ms duration, 5.1 stim./s, between 150 and 200 sweeps per run. We used an Eclipse evoked potentials machine from Interacoustics, Denmark. To record ipsilateral myogenic evoked potentials, the active electrode was placed on the inferior third of the sternocleidomastoidian muscle (SCM), the ground electrode on forehead, and the other two electrodes on the retroauricular areas. Along the sound stimulation, the patient was asked to contract the SCM, with the head turned on 45° to the opposite side. For cochlear implanted patients during the cVEMP test, the sound processor was switched off.

For the utricular sensorial organ activity, the oVEMP were recorded also on lying down patient by sound air

conduction stimulation, tone burst at 500 Hz at 100 dB nHL through ear insert phones, 2 ms duration, 5 stim./s, between 120 and 150 sweeps per run. Ocular VEMP are contralaterally evoked potentials, the active electrode was placed on the infraorbital area, the ground electrode on forehead, and the other two electrodes also on the infraorbital areas. During the sound stimulation and response recording, the patient was asked to gaze upward at 20° or more. For cochlear implanted patients during the cVEMP and oVEMP tests, the sound processor was switched off. The parameters for P1–N1 complex on obtained waves were analyzed for both cVEMP and oVEMP.

Results

The analyze of the temporal bone radiography of each implanted ear confirmed the complete intracochlear insertion of the portelectrode for both approaches used by the surgeon: cochleostomy and round window for all types of implanted devices, as shown in Figures 3 and 4.

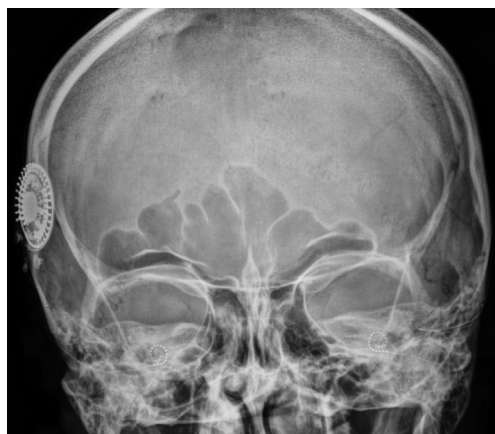


Figure 3 – Skull radiography showing the placement of receptor-stimulator of the cochlear implant (under musculo-cutaneous flap on the right temporal bone) and bilateral cochlear portelectrode insertion for a binaural cochlear implant.

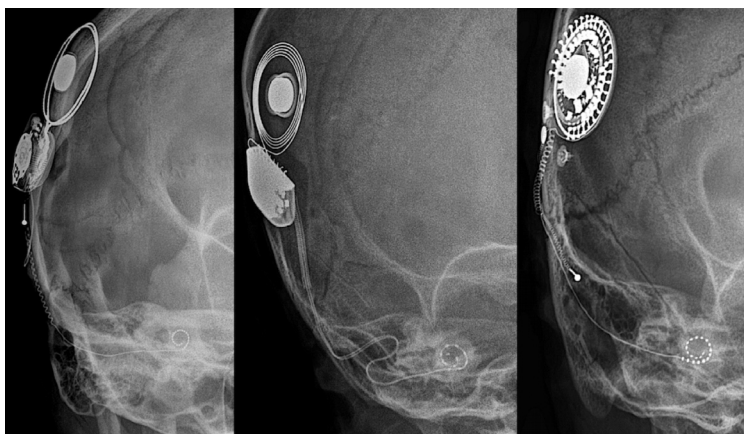


Figure 4 – Stenvers modified X-rays showing the placement of receptor-stimulator and cochlear portelectrode insertion for different monoaural cochlear implants (Cochlear, MedEl and Oticon).

We analyzed the vestibular sensorial status by objective quantitative tests: caloric vestibular test for horizontal semicircular canal, the cVEMP for saccular function and oVEMP for utricular function. All mentioned sensors were evaluated for all patients in study groups, non-implanted and cochlear implanted ears.

If we consider as vestibular damaged each ear with at least one sensor affected by hyporeflexia or areflexia, the tests for peripheral sensors show vestibular impairment in our non-implanted deaf group in 11 ears (50% of cases) and for cochlear implanted group in 17 (53.12%) ears. The patients with round window insertion present a bigger percentage of ears with at least one sensor affected (57.14%) comparing with the cochleostomy group (52%). Both subgroups present a bigger percentage of vestibular damaged sensors comparing with non-implanted ears (Figure 5).

The normal vestibular function was considered if all tested sensors of an ear present normal functional parameters: 50% of non-implanted ears and 46.88% of cochlear implanted ears. The normal vestibular function

was present in 48% for patients with electrode insertion by cochleostomy and 42.86% for those with round window insertion (Figure 5).

The functional evaluation of lateral semicircular canal measured by caloric vestibular test showed that this sensor is the less affected one in cochlear implanted ears, presenting normal function in 84.38% (27) ears. A hyporesponsiveness of the lateral canal has been found in 9.38% (three) ears and areflexia in 6.25% (two) ears. Ocular VEMP revealed that the utricle has been the most injured sensor in cochlear implanted ears (40.63%), as for the rest of 59.38% the utricular sensor has been found normal. In all implanted ears with utricular impairment, the oVEMP was not elicited, showing a total utricular lost in each case. In 65.63% of cochlear implanted cases (21 ears), we found a normal saccular function for cochlear implanted ears, elicited by cVEMP. The pathological saccular sensors have been found for 34.38% (11) ears, with hyporeflexia in 9.38% of cases (three ears) and saccular areflexia in 25% of implanted ears (eight ears). The most affected vestibular sensor in our cochlear

implanted group was the utricle (40.63%), in all cases presenting areflexia. Areflexia was overall the most present damage for vestibular sensors in cochlear implanted ears.

The results for lateral semicircular canal, saccular and utricular function are shown in Figure 6.

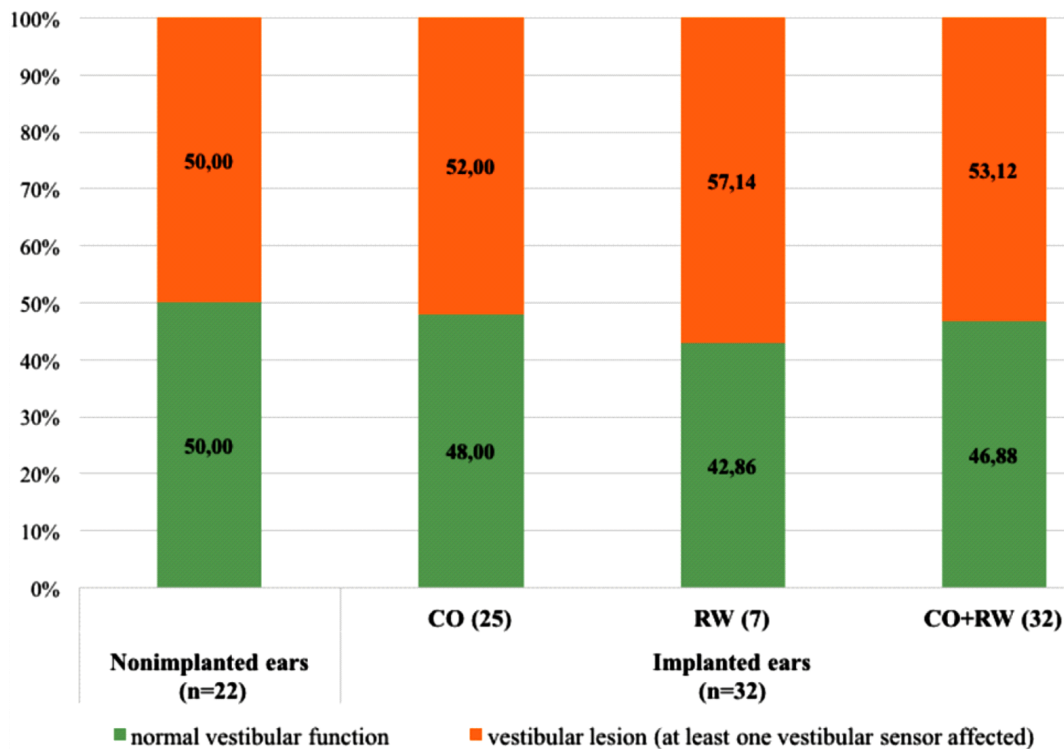


Figure 5 – Vestibular function in non-implanted ears and in cochlear implanted ears with different portelectrode insertion: cochleostomy and round window (vestibular lesion of at least one sensor per ear). CO: Cochleostomy; RW: Round window.

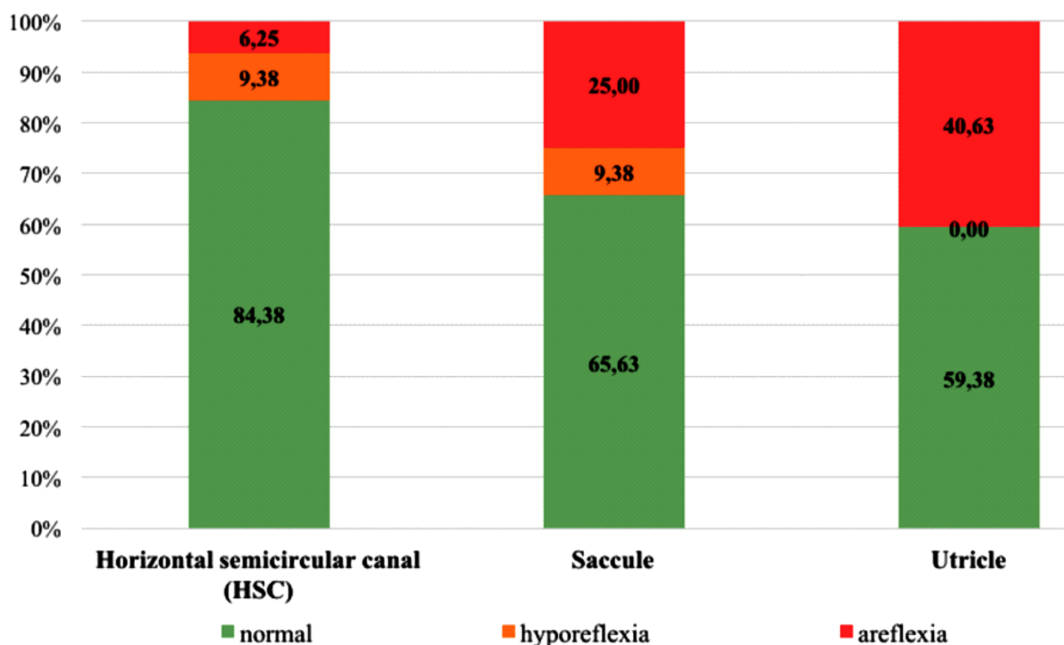


Figure 6 – Vestibular sensorial status in cochlear implanted ears: hyporeflexia and areflexia of horizontal semicircular canal, saccule and utricle compared to postoperatively sensorial functional preservation (n=32).

The vestibular sensors could be differently influenced by different approaches for the insertion of cochlear implant's portelectrode. We analyzed the vestibular assessment results depending of the insertion methods: cochleostomy and round window approach. For semicircular lateral canal, we found non-damaged cupular

sensors in 88% for cochleostomy and 71.43% for round window technique. Hyporeflexia was the dominant consequence of cochlear implantation for horizontal canal (8% in cochleostomy and 14.29% in round window insertion) and areflexia was less important for cochleostomy (4%) and similar with hyporeflexia (14.29%) for

round window approach. The normal saccular function was preserved significantly better in round window insertion (85.71%) than in cochleostomy cases (60%), which present 12% of hyporeflexia and 28% of areflexic saccular sensors. As mentioned above, the utricular sensors present only areflexia in cochlear implanted ears, for cochleostomy have been found a complete loss of the function in 44% of ears and for round window in 28.57% of ears. For our study subgroups of cochlear implanted ears, the round window approach preserved better the saccule and utricle and the cochleostomy was less traumatic only for horizontal semicircular canal (Figure 7).

Considering the globally vestibular injury reported to all tested peripheral sensors of cochlear implanted ears depending of portelectrode insertion strategy, we found a better vestibular sensorial conservation for round window insertion which presents 76.19% normal sensors postoperatively, 4.76% hyporeflexia and 19.04% areflexia. For cochleostomy approach, we found 68% of normal vestibular sensors, 6.66% hyporeflexia and 25.33% areflexic sensors. Both hyporeflexia and areflexia presents increased percentages comparing with round window insertion (Figure 8).

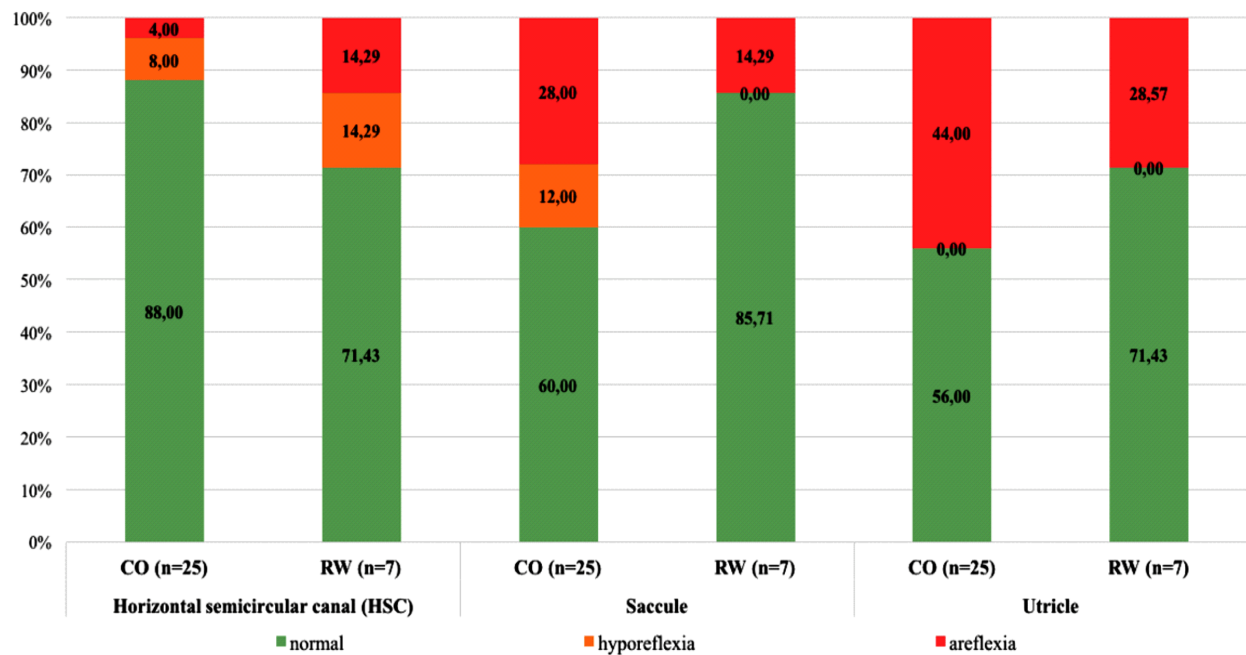


Figure 7 – Comparison of vestibular sensorial status (normal function, hyporeflexia and areflexia) for horizontal semicircular canal, saccule and utricle related to cochleostomy and round window insertion approaches. CO: Cochleostomy; RW: Round window.

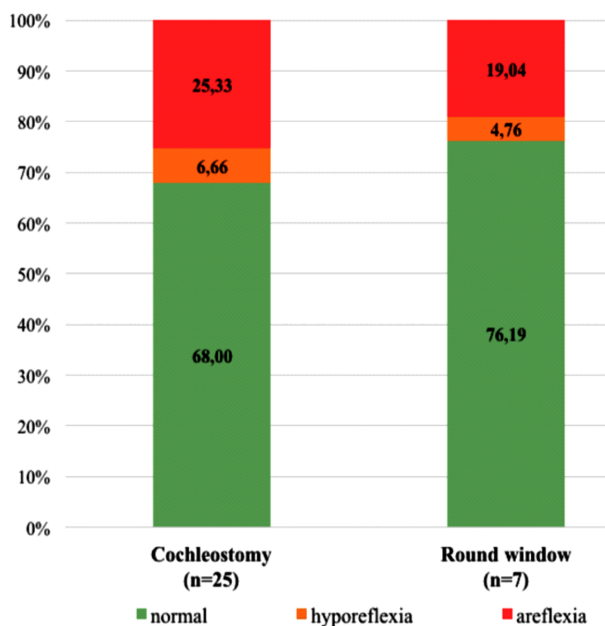


Figure 8 – Vestibular function in cochlear implanted ears with different portelectrode insertion: cochleostomy and round window (vestibular lesion of at least one sensor per ear).

Discussions

The vestibular assessment was made respecting a time delay for cochlear implanted ears of at least three months in order to avoid some transitory vestibular injuries after cochlear implantation. Many patients present immediately after the surgery symptoms like nausea, imbalance, dizziness or vertigo, but often there are present for a short time due to internal ear trauma produced by electrode insertion. González-Navarro *et al.* found no difference in symptoms for the two type of insertion, but round window insertion could induce more vertigo symptoms that appear earlier after the surgery, but with less vestibular permanent damage [10–12].

We considered that in the control group of deaf patients the prevalence of the vestibular dysfunction should be the same like in the selected study group, for many cases of hearing loss the etiology remaining unknown. As well, the groups were homogeneous from the mean age perspective (41.71 years *vs.* 42.95 years), so we should not consider that other risk factors or diseases could be responsible for vestibular sensor degenerations. Thus, the increased number of the injured vestibular sensors in cochlear implanted group was assumed to be a consequence of the surgery.

In our study, the vestibular sensors of cochlear implanted ears were globally more affected by the port-electrode insertion through the cochleostomy than through the round window. In the last years, many researchers published data showing the advantages of round window insertion which does not need to drill the basal turn of the cochlea reducing the surgical trauma [10, 13, 14]. Our results confirm the advantage of using round window insertion for a maximal conservation of the vestibular function. There are also studies showing that the results of vestibular tests were not significantly different before and after cochlear implant (CI) surgery between the cochleostomy and round window groups [15].

For the horizontal semicircular canal, we used the caloric vestibular test, but the results depend on the integrity of the middle ear, especially after the cochlear implant surgery. In our cases, it was no patient reported with postoperatively middle ear complications. The tympanometry performed before the caloric test showed normal parameters for each case included in the study. The lateral semicircular canal seems to be the most respected sensor by the cochlear implant surgery for our patients, in over 84% of implanted ears the function was found normal. Moreover, the same sensor presents the smaller number of ears with areflexia (two cases) – 6.25% and the hyporeflexia was identified in the same amount like in saccular deficit – 9.38% (three) implanted ears. For horizontal canal preservation, the cochleostomy could be more sure than the round window approach, but on the other hand the risk of globally vestibular damage could be increased. Batuecas-Caletrio *et al.* described by video head impulse test postoperative change in vestibular function in 30% of cochlear implanted ears and they suggest that round window approach should be recommended for less inner ear trauma [14]. In other study, Krause *et al.* showed a significant postoperative worsening of the caloric response in 32% of patients [16].

Saccular sensors evaluated by cVEMP testing revealed a less altered function compared with utricular sensors and more injured related to horizontal semicircular canal. For the cochlear implanted affected ears, the saccular areflexia was significantly much more present than saccular hyporeflexia (25% vs. 9.38%). This conclusion confirms other author's results [13, 17]. The round window insertion way should be more secured for saccular sensors than the cochleostomy method [14].

For the utricular damaged sensors in cochlear implanted ears, the oVEMP were not obtained at all, suggesting utricular areflexia; this sensor could be more sensitive to the trauma compared to the others. For some monoaural cochlear implanted patients with utricular areflexia on the implanted ear, we found a normal utricular function on the contralateral ear. Thus, we could presume that for these patients at least the utricular sensors could be considered to be damaged by the cochlear implantation surgery. From our data, the round window insertion would be better tolerated by utricular sensors, which present a less important damage (28.57%) comparing to the cochleostomy (44%).

The differences between functional vestibular status of implanted *versus* non-implanted ears described in our

study cannot be favored by other factors as presby-vestibulopathy or other damages produced by the age, both groups of patients having similar mean ages: 41.71 years for non-implanted group and 42.31 years for implanted group.

The vestibular symptoms and permanent damages induced by the cochlear implant surgery could be a consequence of different histopathological changes of the inner ear elements, but it was shown that there are not evidences of the vestibular nerve injury [2]. For vestibular injured patients by cochlear implantation the compensation process could evolve spontaneously or by vestibular rehabilitation [18, 19].

The cochleostomy and the round window approaches could influence, apart the vestibular function, the audiological outcomes of the patient. The scalar placement of intracochlear portelectrode is very important in relation with local histopathological damages, especially in cases with residual hearing and also with auditory performance. Brendan *et al.*, in a review study, emphasize the impact of surgical approach, electrode design, and insertion depth on auditory results: electrode insertions into the *scala tympani* are associated with superior speech perception and higher rates of hearing preservation. The round window and extended round window approaches appear to maximize the likelihood of a *scala tympani* insertion [1]. In the same time, the electrode placement into the cochlea reported to lateral wall and to modiolus influences the cochlear implant fitting parameters with impact on audiological results [20]. In this regard, the vestibular impact of this preferable approach through the round window should be very well studied.

Our study focused on the status of the vestibular sensors in non-implanted and implanted ears has a limit concerning the vestibular damages induced by cochlear implantation, because we compared groups of implanted and non-implanted ears (including contralateral non-implanted ears of unilaterally implanted patients). A following study will appreciate the vestibular impact of cochlear implant surgery using preoperative and post-operative vestibular evaluation exclusively on the implanted ears.

However, in our study we followed-up all quantitative measurable sensors (horizontal canal, the saccule and the utricle) and compared their status in the main actual strategies used for portelectrode insertion.

There are wide discrepancies in clinical results regarding the sensorial deficits found by different studies [8]. In Table 1, there are comparative levels of deficits in different studies [21–25]. For lateral semicircular canal, the deficit was reported between 19% to 93%, while for saccular deficit, very rarely reported, the deficit widely varies between 21% and 100% in different studies [26–33].

The vestibular sensorial status after cochlear implant is much more important for children than for adults, since they are nowadays implanted at a very early age, even before walking. Wiener-Vacher reports that the use of round window approach could induce a vestibular impairment in 10% of implanted children, close to results published by Todt *et al.* (13%) and significantly lower than 50% in children with cochleostomy. The round window insertion and the sequential bilateral implantation

would be recommended in order to prevent the bilateral vestibular loss [31].

Table 1 – Vestibular deficit findings in cochlear implanted patients reported by different studies for vestibular sensors (lateral semicircular canal and saccular deficit)

Study	No. of enrolled patients	Lateral semicircular canal deficit (ENG/VOG caloric test)	Saccular deficit (cervical VEMP)
Basta <i>et al.</i> , 2008	18	NA	100%
Brey <i>et al.</i> , 1995	17	40–43%	NA
Enticott <i>et al.</i> , 2006	86	32%	NA
Filipo <i>et al.</i> , 2006	14	93%	NA
Fina <i>et al.</i> , 2003	66	56%	NA
Huygen <i>et al.</i> , 1995	13	31%	NA
Ito, 1998	24	38%	NA
Jin <i>et al.</i> , 2006	6	NA	100%
Mangham, 1987	9	44%	NA
Szirmai <i>et al.</i> , 2001	60	23%	NA
Todt <i>et al.</i> , 2008	35/28	19%	21%
Krause <i>et al.</i> , 2010	30	50%	86%
Nair <i>et al.</i> , 2016	20	45%	95%
Krause <i>et al.</i> , 2009	47	55%	NA
Krause <i>et al.</i> , 2009	25	80%	83%
Abouzayd <i>et al.</i> , 2017	957	28–60%	38–63%

ENG: Electronystagmography; VOG: Video-oculography; VEMP: Vestibular evoked myogenic potentials; NA: Not available.

Conclusions

Cochlear implantation represents an important risk factor for injury of the peripheral vestibular receptors. Our study revealed significant vestibular changes on cochlear implanted ears *vs.* non-implanted deaf ears. We can affirm that in our implanted patients the global vestibular lesions were less important for round window approach compared with cochleostomy electrode insertion. Using minimally invasive surgical techniques, like round window insertion approach, and also less traumatic devices for inner ear, the conservation of vestibular sensory function will be improved in the advantage of cochlear implanted patient's balance. However, the potential of permanent damage of some vestibular structures with clinical vestibular impact should be discussed with patient before surgery.

Conflict of interests

The authors declare that they have no conflict of interests.

Author contribution

Romică Sebastian Cozma and Lucia Corina Dima-Cozma equally contributed to this study.

References

- O'Connell BP, Hunter JB, Wanna GB. The importance of electrode location in cochlear implantation. *Laryngoscope Investig Otolaryngol*, 2016, 1(6):169–174.
- Handzel O, Burgess BJ, Nadol JB Jr. Histopathology of the peripheral vestibular system after cochlear implantation in the human. *Otol Neurotol*, 2006, 27(1):57–64.
- Tien HC, Linthicum FH Jr. Histopathologic changes in the vestibule after cochlear implantation. *Otolaryngol Head Neck Surg*, 2002, 127(4):260–264.

- Georgescu M, Stoian S, Mogoantă CA, Ciubotaru GV. Vestibular rehabilitation – election treatment method for compensating vestibular impairment. *Rom J Morphol Embryol*, 2012, 53(3):651–656.
- Krause E, Louza JP, Wechtenbruch J, Gürkov R. Influence of cochlear implantation on peripheral vestibular receptor function. *Otolaryngol Head Neck Surg*, 2010, 142(6):809–813.
- Hinganu MV, Stan CI, Țăranu T, Hinganu D. Morphological changes in support mechanism of superficial face layers in Moebius syndrome. *Rom J Morphol Embryol*, 2017, 58(3): 851–855.
- Dhanasingh A, Jolly C. An overview of cochlear implant electrode array designs. *Hear Res*, 2017, 356:93–103.
- Ibrahim I, da Silva SD, Segal B, Zeitouni A. Effect of cochlear implant surgery on vestibular function: meta-analysis study. *J Otolaryngol Head Neck Surg*, 2017, 46(1):44.
- British Society of Audiology (BSA). Recommended procedure: the caloric test. BSA, Berkshire, UK, 2010, <https://www.thebsa.org.uk/wp-content/uploads/2014/04/Recommended-procedure-for-the-Caloric-test.pdf>.
- González-Navarro M, Manrique-Huarte R, Manrique-Rodríguez M, Huarte-Irujo A, Pérez-Fernández N. Long-term follow-up of late onset vestibular complaints in patients with cochlear implant. *Acta Otolaryngol*, 2015, 135(12):1245–1252.
- Hänsel T, Gauger U, Bernhard N, Behzadi N, Romo Ventura ME, Hofmann V, Olze H, Knopke S, Todt I, Coordes A. Meta-analysis of subjective complaints of vertigo and vestibular tests after cochlear implantation. *Laryngoscope*, 2018, Jan 4.
- Migliaccio AA, Della Santina CC, Carey JP, Niparko JK, Minor LB. The vestibulo-ocular reflex response to head impulses rarely decreases after cochlear implantation. *Otol Neurotol*, 2005, 26(4):655–660.
- Meli A, Aud BM, Aud ST, Aud RG, Cristofari E. Vestibular function after cochlear implant surgery. *Cochlear Implants Int*, 2016, 17(3):151–157.
- Batuecas-Caletrio A, Klumpp M, Santacruz-Ruiz S, Benito Gonzalez F, Gonzalez Sánchez E, Arriaga M. Vestibular function in cochlear implantation: correlating objectiveness and subjectiveness. *Laryngoscope*, 2015, 125(10):2371–2375.
- Kluenter HD, Lang-Roth R, Beutner D, Hüttenbrink KB, Guntinas-Lichius O. Postural control before and after cochlear implantation: standard cochleostomy *versus* round window approach. *Acta Otolaryngol*, 2010, 130(6):696–701.
- Krause E, Louza JP, Hempel JM, Wechtenbruch J, Rader T, Gürkov R. Effect of cochlear implantation on horizontal semicircular canal function. *Eur Arch Otorhinolaryngol*, 2009, 266(6):811–817.
- Krause E, Wechtenbruch J, Rader T, Gürkov R. Influence of cochlear implantation on sacculus function. *Otolaryngol Head Neck Surg*, 2009, 140(1):108–113.
- Abramides PA, Bittar RS, Tsuji RK, Bento RF. Caloric test as a predictor tool of postural control in CI users. *Acta Otolaryngol*, 2015, 135(7):685–691.
- Suh MW, Hyun J, Lyu AR, Kim DW, Park SJ, Choi JW, Hur GM, Park YH. Compensation of vestibular function and plasticity of vestibular nucleus after unilateral cochleostomy. *Neural Plast*, 2016, 2016:7287180.
- Vaerenberg B, Smits C, De Ceulaer G, Zir E, Harman S, Jaspers N, Tam Y, Dillon M, Wesarg T, Martin-Bonniot D, Gärtner L, Cozma S, Kosaner J, Prentiss S, Sasidharan P, Briare JJ, Bradley J, Debruyne J, Hollow R, Patadia R, Mens L, Veekmans K, Greisiger R, Harboun-Cohen E, Borel S, Tavora-Vieira D, Mancini P, Cullington H, Ng AH, Walkowiak A, Shapiro WH, Govaerts PJ. Cochlear implant programming: a global survey on the state of the art. *Scientific World Journal*, 2014, 2014:501738.
- Basta D, Todt I, Goepel F, Ernst A. Loss of saccular function after cochlear implantation: the diagnostic impact of intra-cochlear electrically elicited vestibular evoked myogenic potentials. *Audiol Neurotol*, 2008, 13(3):187–192.
- Brey RH, Facer GW, Trine MB, Lynn SG, Peterson AM, Suman VJ. Vestibular effects associated with implantation of a multiple channel cochlear prosthesis. *Am J Otol*, 1995, 16(4):424–430.
- Enticott JC, Tari S, Koh SM, Dowell RC, O'Leary SJ. Cochlear implant and vestibular function. *Otol Neurotol*, 2006, 27(6): 824–830.

- [24] Filipo R, Patrizi M, La Gamma R, D'Elia C, La Rosa G, Barbara M. Vestibular impairment and cochlear implantation. *Acta Otolaryngol*, 2006, 126(12):1266–1274.
- [25] Fina M, Skinner M, Goebel JA, Piccirillo JF, Neely JG, Black O. Vestibular dysfunction after cochlear implantation. *Otol Neurotol*, 2003, 24(2):234–242; discussion 242.
- [26] Huygen PL, Hinderink JB, van den Broek P, van den Borne S, Brokx JP, Mens LH, Admiraal RJ. The risk of vestibular function loss after intracochlear implantation. *Acta Otolaryngol Suppl*, 1995, 520(Pt 2):270–272.
- [27] Ito J. Influence of the multichannel cochlear implant on vestibular function. *Otolaryngol Head Neck Surg*, 1998, 118(6):900–902.
- [28] Jin Y, Nakamura M, Shinjo Y, Kaga K. Vestibular-evoked myogenic potentials in cochlear implant children. *Acta Otolaryngol*, 2006, 126(2):164–169.
- [29] Mangham CA. Effects of cochlear prostheses on vestibulo-ocular reflexes to rotation. *Ann Otol Rhinol Laryngol*, 1987, 96(1 Suppl):101–104.
- [30] Szirmai A, Ribári O, Répássy G. Air caloric computer system application in monitoring vestibular function changes after cochlear implantation. *Otolaryngol Head Neck Surg*, 2001, 125(6):631–634.
- [31] Todt I, Basta D, Ernst A. Does the surgical approach in cochlear implantation influence the occurrence of postoperative vertigo? *Otolaryngol Head Neck Surg*, 2008, 138(1):8–12.
- [32] Nair G, Indorewala A, Vijayakrishnan P, Raghunandhan S, Kameswaran M. A study of vestibular dysfunction in cochlear implantees. *SAS J Surg*, 2016, 2(5):228–232.
- [33] Abouzayd M, Smith PF, Moreau S, Hitier M. What vestibular tests to choose in symptomatic patients after a cochlear implant? A systematic review and meta-analysis. *Eur Arch Otorhinolaryngol*, 2017, 274(1):53–63.

Corresponding authors

Maria Cristina Hera, MD, PhD Student, Department of Otorhinolaryngology, Faculty of Medicine, “Grigore T. Popa” University of Medicine and Pharmacy, 16 University Street, 700115 Iași, Romania; Phone +40732–324 492, e-mail: cristinahera@yahoo.it

Luminița Mihaela Rădulescu, Associate Professor, MD, PhD, Department of Otorhinolaryngology, Faculty of Medicine, “Grigore T. Popa” University of Medicine and Pharmacy, 16 University Street, 700115 Iași, Romania; Phone +40724–955 956, e-mail: lmrdulescu@yahoo.com

Received: September 21, 2017

Accepted: May 19, 2018