CASE REPORT

RJME
Romanian Journal of Morphology & Embryology
http://www.rjme.ro/

Rare metastasis of renal carcinoma in the frontoethmoid-orbital region – case report and review of the literature

RĂZVAN HAINĂROŞIE[1,2], FLORIN ANGHELINA[3], IRINA GABRIELA IONIŢĂ[1], OLIMPIA IULIA ZOICAN[2], CĂTĂLINA PIETROŞANU[1], SILVIU MIREL PIŢURU[4], VIOREL ZAINEA[1,2]

[1] *Department of ENT, "Carol Davila" University of Medicine and Pharmacy, Bucharest, Romania*

[2] *"Prof. Dr. Dorin Hociotă" Institute of Phonoaudiology and Functional ENT Surgery, Bucharest, Romania*

[3] *Department of ENT, University of Medicine and Pharmacy of Craiova, Romania*

[4] *Department of Professional Organization and Medical Legislation–Malpraxis, "Carol Davila" University of Medicine and Pharmacy, Bucharest, Romania*

Abstract

A tumor located in the region of the paranasal sinuses and the orbit is not usually a metastasis, but a primary tumor. Even more, renal cell carcinoma (RCC) is very rarely the cause of metastasis in the paranasal sinuses or the orbit. Up to the present moment, few cases have been reported in the literature of such an association. The aim of the authors is to highlight the rare case of a male patient presented with ptosis, frontal swelling, minor headaches and epistaxis, as the only symptoms, but in which the mass located in the left frontoethmoidal region with extension to the orbit proved to be a RCC metastasis, thus leading to the diagnosis of the primary renal tumor. We must underline the need for clinical suspicion and the importance of accurate histopathological and immunohistochemical investigations, in such rare cases, where they are crucial in obtaining the right diagnosis.

Keywords: renal carcinoma, metastasis, paranasal sinuses, orbit, sinonasal metastasis.

Introduction

The cases of metastases in the head and neck region from primary tumors located below the clavicular region are quite rare [1]. According to the literature, lung and breast cancers are most frequently associated with metastasis in the head and neck, followed by renal carcinoma, but the latest most often causes metastatic determinations in the sinonasal area [2]. Other possible origins of the primary tumor with paranasal metastasis include the gastrointestinal tract, the testis or the prostate [3, 4]. There are few cases described so far, with non-specific symptoms, which is why the diagnosis in such patients is delayed, sometimes being set only by the histopathological findings. Up to this moment, we do not know of a pattern in presentation that should give rise to the suspicion of a sinonasal metastasis, which clearly indicates the importance of a thorough pathological diagnosis. Renal cell carcinoma (RCC) usually affects male patients, aged 30–60 years, and associates a variety of symptoms and a variable evolution [5]. Although cases in which the diagnosis was set due to symptoms caused by different metastasis were presented, it is extremely rare to have sinonasal metastasis as the only cause of complaints from the patients, as is the case the authors wish to present.

We aim to present the case of a patient that was diagnosed with a tumor located in the left frontal and ethmoidal sinuses, extended to the left orbit and maxillary sinus. Although the patient did not present any complaint related to the urinary system, the histopathological and immunohistochemical (IHC) examinations revealed the nasosinusal tumor to be a metastasis of clear cells renal carcinoma.

Case presentation

A 60-year-old man (TC) was referred to our Department ("Prof. Dr. Dorin Hociotă" Institute of Phonoaudiology and Functional ENT Surgery, Bucharest, Romania), in September 2015, for left ptosis and a swelling in the left frontal region, symptoms with an acute onset one month prior to presentation. The patient also reported minor headaches that responded to over-the-counter drugs, and a few episodes of non-severe epistaxis, that resolved spontaneously, without ever requiring medical treatment. The patient's personal history included a recently diagnosed sleep apnea syndrome, arterial hypertension and ventricular arrhythmia with frequent ventricular extrasystolic beats (more than 15/minute).

The clinical examination revealed a firm swelling in the left frontal region and the displacement of the left eyeball laterally and forward with eyelid ptosis. The patient also had an obstructive septal deviation, which did not permit the visualization of the middle and upper meatus on the left side. The visual acuity was within normal limits, as proved by the ophthalmologic examination. No other significant findings were reported.

A cranial computed tomography (CT) was immediately performed, revealing a partially cystic mass located at the level of the left frontal sinus (Figure 1) and left ethmoidal cells with extension to the left orbit (Figure 2) and maxillary sinus (Figure 3).

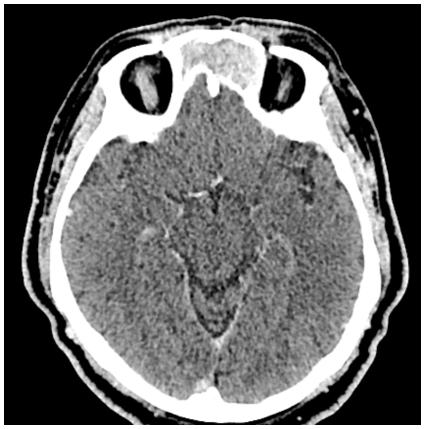

Figure 1 – ***Cranio-facial transverse CT image with tumor involving left frontal sinus.***

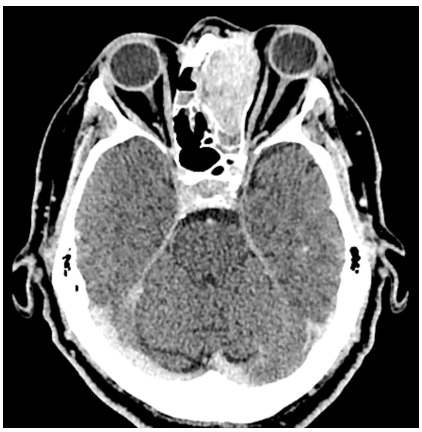

Figure 2 – ***Cranio-facial transverse CT image with tumor involving left ethmoidal sinus and orbit.***

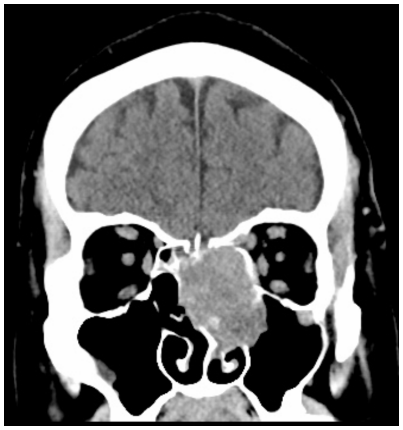

Figure 3 – ***Cranio-facial coronal CT image with tumor involving ethmoidal sinus, orbit and maxillary sinus.***

There was no apparent involvement of the eyeball. The paraclinical investigations revealed a slightly increased blood urea with sodium and potassium on the upper limit, increased thrombocytes, a minor anemia, a high value of leukocytes and increased inflammatory markers, but no other significant changes: alanine aminotransferase (ALT) 30 U/L; aspartate aminotransferase (AST) 23 U/L; calcium 8.7 mg/dL; chloride 10^6 mmoles/L; glycemia 157 mg/dL; potassium 5.1 mmoles/L; sodium 140 mmoles/L; urea 52 mg/dL; Quick time/international normalized ratio (INR) – prothrombin time (PT) 12.3 s, INR 1.09; leukocytes $20.4\times10^3/\mu L$, erythrocytes $3.88\times10^6/\mu L$, hemoglobin (Hb) 11.8 g/dL, hematocrit (Ht) 35.5%, blood platelets $470\times10^3/\mu L$, lymphocytes $2.7\times10^3/\mu L$, monocytes $0.5\times10^3/\mu L$, granulocytes $17\times10^3/\mu L$, mean corpuscular volume (MCV) 91.5 fL, mean corpuscular hemoglobin (MCH) 30.4 pg, mean corpuscular hemoglobin concentration (MCHC) 33.2 g/dL, erythrocyte sedimentation rate (ESR) 48 mm/h. The electrocardiogram was within normal range.

The patient underwent surgery under general anesthesia. The endoscopic approach was aiming to perform a complete evaluation of the area after the obstructive septal deviation was resolved, to perform multiple targeted biopsies and if possible to completely remove the tumor. However, due to the highly vascular nature of the tumor, that associated significant bleeding, only the biopsies were performed.

In order to establish the histopathological diagnosis, the biopsies were sent to the Department of Anatomical Pathology. The biological material was prepared using a 10% neutral formaldehyde solution and enclosed in paraffin, according to the classical protocol. Then, the biopsies were sectioned using a Microm HM350 rotary microtome, equipped with a sections transfer system in water bath (STS, microM). For the histological study, 4 μm sections were performed, that were stained using Hematoxylin–Eosin (HE).

In order to have a certain positive and differential diagnosis and to evaluate the tumor's aggressivity, we decided to complete the histopathological study with an immunohistochemistry study. From the paraffin samples, a series of sections were performed, that were collected on slides covered with poly-L-lysine and then dried using a thermostat, at 37^0C, for 24 hours. In order to assess the IHC markers, the paraffin was removed from the histological sections and these were rehydrated. Afterwards, in order to discover the antigens, they were boiled in a sodium citrate solution, pH 6, for 21 minutes (seven cycles of three minutes each) in a microwave oven. The blockage of the endogenous peroxidase was accomplished by incubating the sections in 3% hydrogen peroxide solution for 30 minutes, at room temperature, followed by washing in distilled water for 10 minutes. The blockage of the non-specific sites was accomplished by incubating the sections in 2% half skimmed milk for 30 minutes. Then, the sections were incubated with primary antibodies for 18 hours (overnight), at 4^0C. The next day, the secondary biotinylated antibody was applied for 30 minutes, at room temperature, then Streptavidin–Horseradish peroxidase (HRP) was applied for 30 minutes, at room temperature. The signal was detected using 3,3'-Diaminobenzidine (DAB) tetrahydrochloride (Dako) and the reaction was terminated using 1% phosphate-buffered saline (PBS), under microscopic control. The contrast was obtained using Mayer's Hematoxylin, the dehydration was performed with alcohol, the clarifying with xylene and the sections were mounted using a DPX (Fluka) medium.

In our study, we used the following antibodies: anti-alpha-1-fetoprotein (AFP) (polyclonal marker, 1/100 dilution, Dako); anti-cyclin D1 (clone dcs-6, 1/100 dilution, Life Technologies); anti-cancer antigen (CA) 19.9 (clone 1116-NS-19-9, 1/50 dilution, Dako); anti-E-cadherin (clone NCH-38, 1/100 dilution, Dako), anti-cytokeratin (CK) 7 (clone OV-TL 12/30, 1/50 dilution, Dako), anti-CK18 (clone DC 10, 1/25 dilution, Dako); anti-Ki67 (clone MIB-1, 1/50 dilution); anti-p53 (clone DO-7, 1/100 dilution, Dako); anti-CD34 (clone QBEnd 10, 1/100 dilution, Dako).

The classical histopathological study revealed tumor cells organized in trabecular or alveolar structures, separated by conjunctival septae of various thicknesses, intensely vascular. The tumor's surface was covered by a cylindrical pseudostratified epithelium, typical of the

airway (Figure 4). Most of the tumor cells had clear, vacuolary cytoplasm, slightly acidophilic due to the glycogen and lipids accumulation that do not become pigmented using the classical HE staining. The nuclei were small, round, ovalary, hyperchromic, located most often centrally. The nuclei presented frequent nuclear atypia, but rare mitoses were observed (Figure 5). In some areas of the tumor, an intense vascular congestion was observed, even with intratumoral microhemorrhage (Figure 6).

Besides the tumor areas with clear, typical cells that occupied most of the tumor's volume, other areas were identified, areas with small eosinophilic cells (Figure 7) and areas with cells with tubular architecture that mimic the embryonic nephrotic tubes (Figure 8).

The immunohistochemistry study revealed the fact that the tumor cells with clear cytoplasm and the ones with tubular architecture were positive and intense-positive for the anti-AFP antibody (Figures 9 and 10), while for anti-cyclin D1 antibody both types of tumor cells were slightly positive (Figures 11 and 12). The IHC reaction for the anti-CA 19.9 antibody was different: in the clear cells, it was negative (Figure 13), but it was intensely positive in the cells with tubular architecture (Figure 14). The IHC reaction for E-cadherin was similar to the one for CA 19.9 antibody, meaning that the clear cells were negative (Figure 15), while the cells with tubular architecture were intensely positive (Figure 16).

Regarding the reaction to cytokeratins, we noticed the fact that the clear cells were negative for CK7 and slightly positive for CK18 (Figure 17, a and b). The Ki67 proliferation index was low, with a number of approximately 10% of the tumor cells presenting a positive reaction for this antibody (Figure 18). Also, we could notice an intensely positive reaction of the vessels from the tumor's stroma to the anti-CD34 antibody (Figure 19), which explains the intense vascular supply of the tumor and the tendency towards bleeding.

The histopathological examination revealed that the tumor was a metastasis of a clear cell carcinoma, most likely with a renal point of origin. It also demonstrated the fact that the metastasis contained more clones of tumor cells, most of them being the clear cells.

We performed first an abdominal echography, followed by an abdominal CT, which revealed an 8 cm mass located in the inferior portion of the right kidney. Further investigations revealed a small mass of 8 mm in the right lung and a 4/3 cm osteolytic mass located at the level of the T2–T3 vertebrae.

The patient was referred to the Department of Urology, where he underwent right nephrectomy, then returned to our service for further evaluation and treatment. Due to the high risk of bleeding, the patient having presented minor episodes of epistaxis in this period, and to the high potential of orbital compression, we decided to perform surgery, with the purpose of completely removing the tumor.

We chose a combined approach, with a lateral rhinotomy for better exposure of the lesion and the endoscopic control, which allowed a better visualization of the hidden areas. In order to remove the entire tumor, an antero-posterior left ethmoidectomy and external trepanation of the frontal and maxillary sinuses were performed. The results were excellent, with complete removal of the lesion, as shown by a contrast enhanced CT that was performed seven days after surgery. Multiple biopsies were performed in the orbital area, and the results were negative.

Only seven days of broad-spectrum antibiotics were necessary. After surgery, the patient had nasal packing with No. 8 Merocel that was removed 48 hours later, with no bleeding. He was discharged nine days following surgery.

The follow-up of the patient from the ear, nose and throat (ENT) perspective required a control every three months with endoscopic examination and a positron emission tomography (PET)-CT every year. So far, the outcome was a positive one, with no signs of recurrence, but further regular check-ups are still necessary.

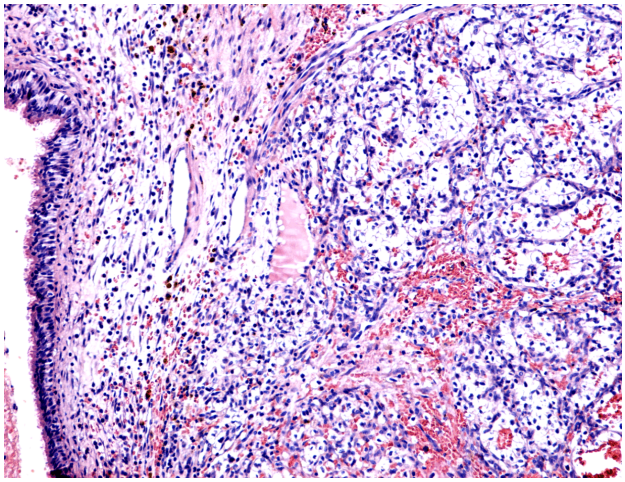

Figure 4 – ***Tumor cells with alveolar or trabecular architecture, covered on the surface by respiratory epithelium (HE staining, ×100).***

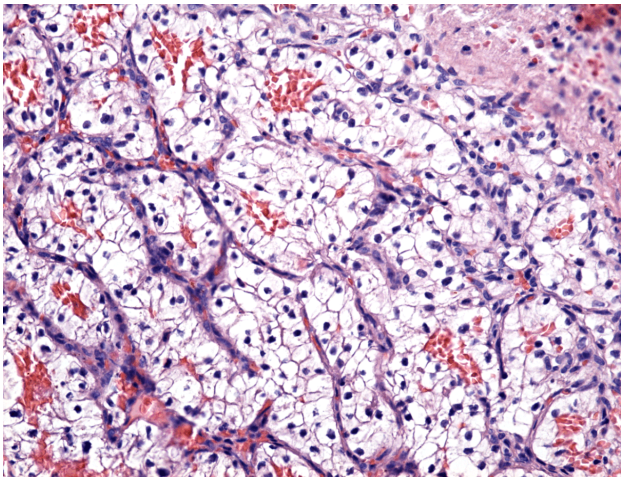

Figure 5 – ***Well delimitated tumor cells, with clear cytoplasm, organized in cords or alveolae, separated by conjunctival septae rich in blood capillaries (HE staining, ×200).***

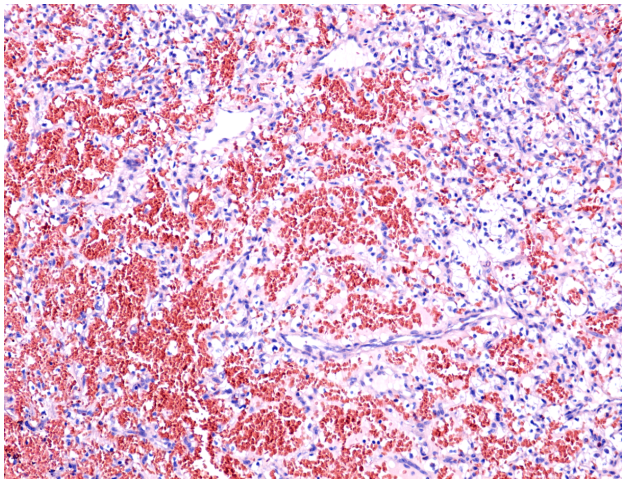

Figure 6 – ***Highly vascularized tumor area (HE staining, ×100).***

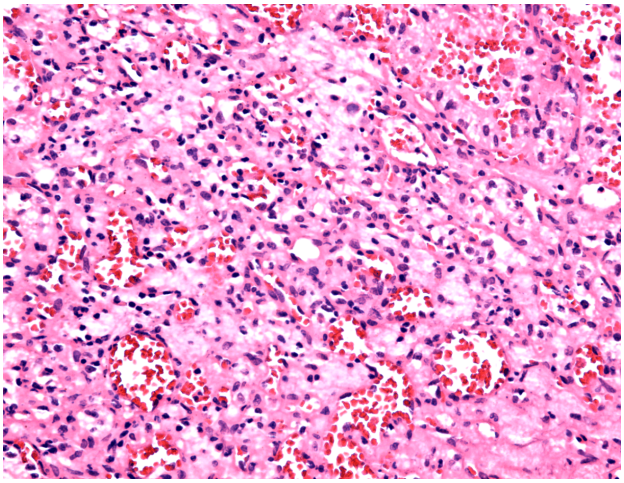

Figure 7 – ***Area of the tumor with eosinophilic cells (HE staining, ×200).***

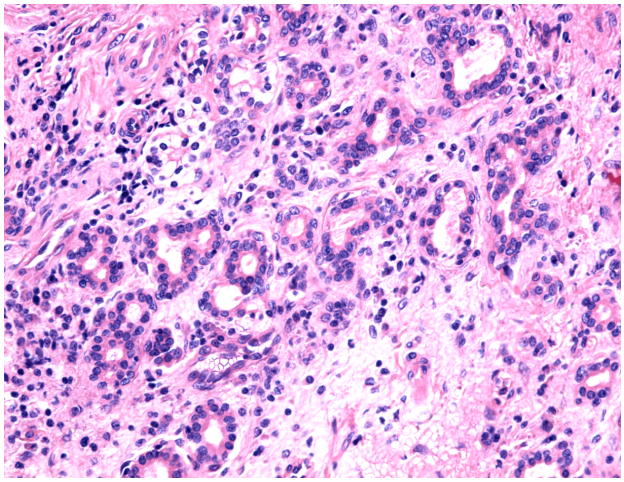

Figure 8 – ***Tumor cells with tubular architecture (HE staining, ×200).***

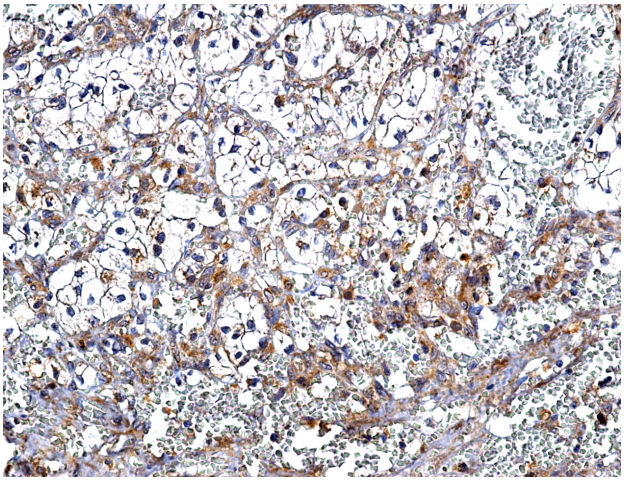

Figure 9 – ***Immunohistochemistry image of an area with clear cells, positive for the anti-AFP antibody (Immunomarking with anti-AFP antibody, ×200). AFP: Alpha-fetoprotein.***

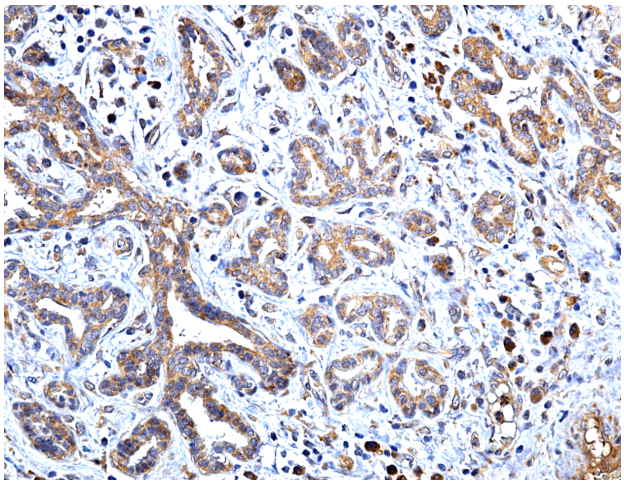

Figure 10 – ***Tumor cells with tubular architecture, intensely positive for the anti-AFP antibody (Immunomarking with anti-AFP antibody, ×200). AFP: Alpha-fetoprotein.***

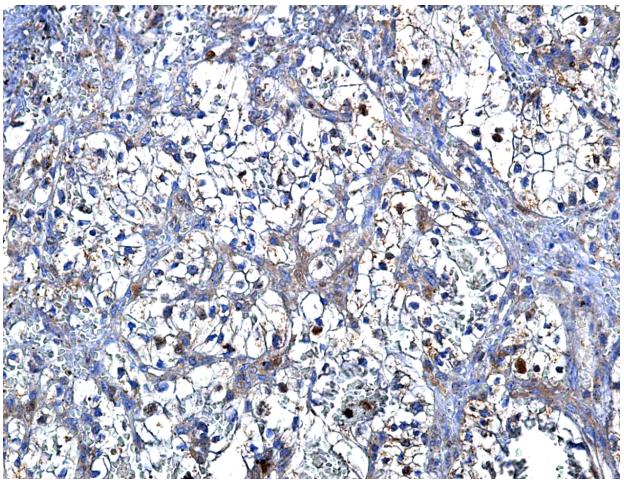

Figure 11 – ***Image of the clear cells tumor, slightly positive for anti-cyclin D1 antibody (Immunomarking with anti-cyclin D1 antibody, ×200).***

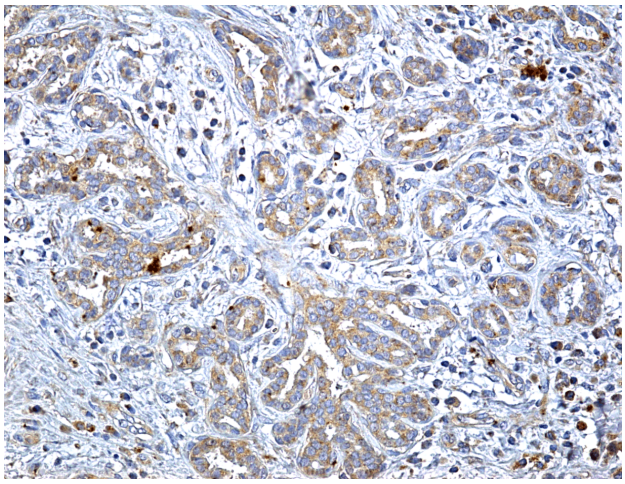

Figure 12 – ***Tumor cells with tubular architecture, with slightly positive reaction to the anti-cyclin D1 antibody (Immunomarking with anti-cyclin D1 antibody, ×200).***

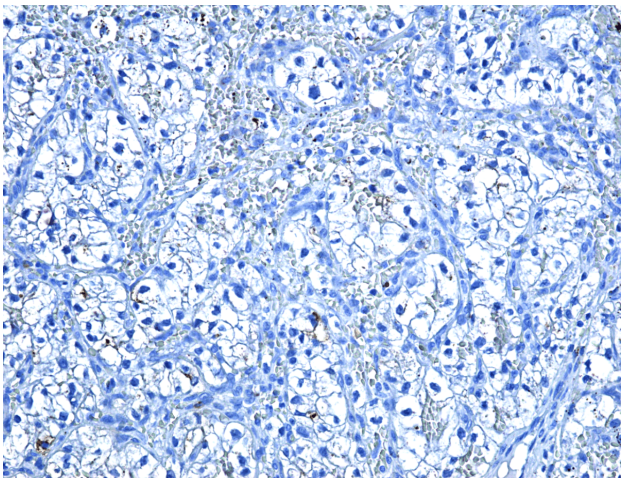

Figure 13 – ***Image of a tumor area with clear cells, with negative reaction to the anti-CA 19.9 antibody (Immunomarking with anti-CA 19.9 antibody, ×200). CA: Cancer antigen.***

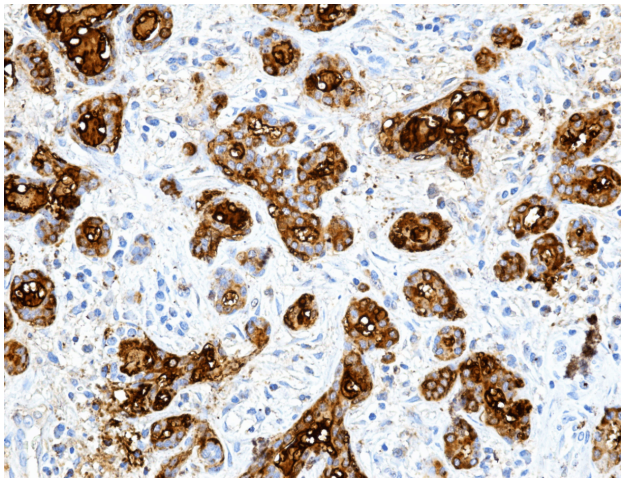

Figure 14 – ***Tumor cells with tubular architecture, with intense reaction to the anti-CA 19.9 antibody (Immunomarking with anti-CA 19.9 antibody, ×200). CA: Cancer antigen.***

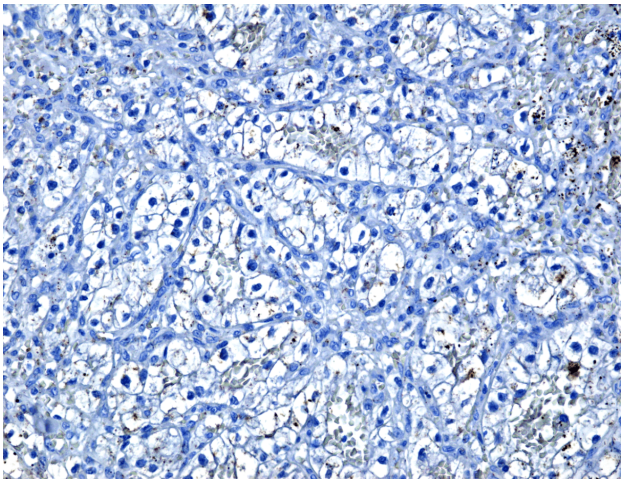

Figure 15 – ***Tumor cells with clear cytoplasm, with negative reaction to the anti-E-cadherin antibody (Immunomarking with anti-E-cadherin antibody, ×200).***

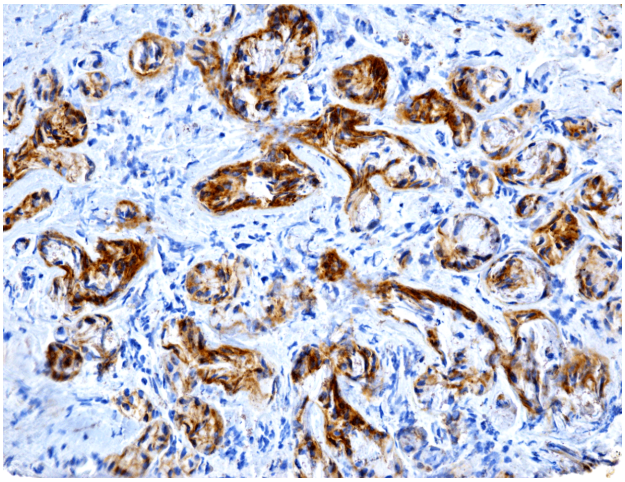

Figure 16 – ***Tumor cells with tubular architecture, intensely positive for the anti-E-cadherin antibody (Immunomarking with anti-E-cadherin antibody, ×200).***

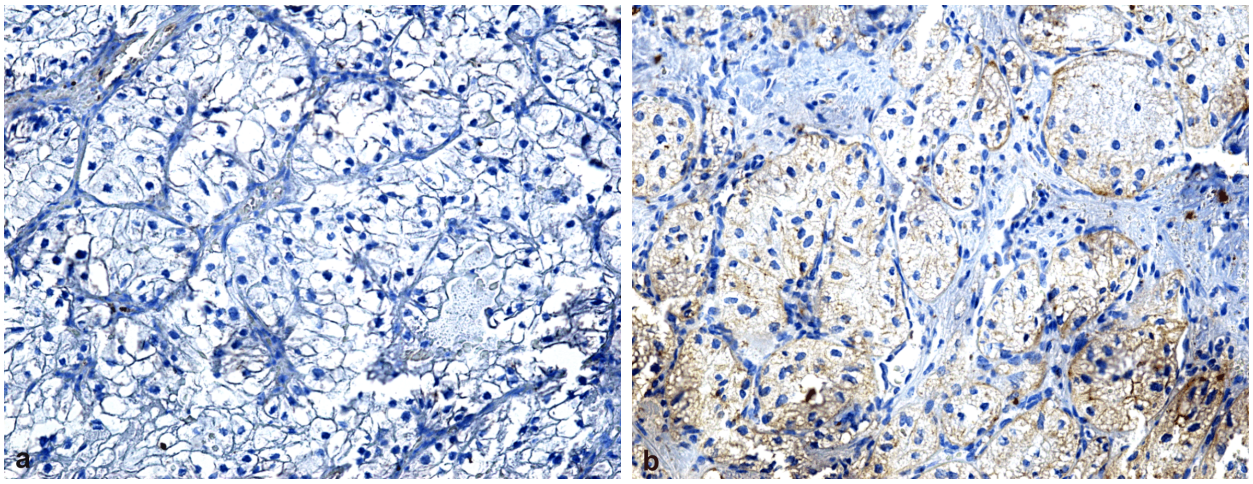

Figure 17 – ***(a) Tumor cells with clear cytoplasm, with negative reaction to the anti-CK7 antibody (Immunomarking with anti-CK7 antibody, ×200); (b) Tumor cells with slightly positive reaction to the anti-CK18 antibody (Immunomarking with anti-CK18 antibody, ×200). CK: Cytokeratin.***

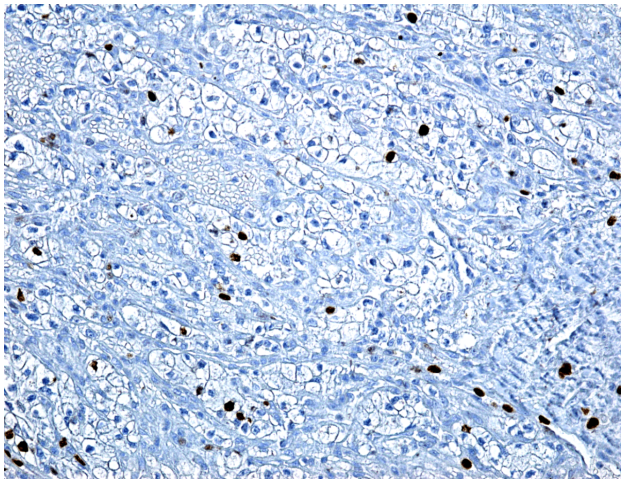

Figure 18 – ***Clear cells tumor area with a reduced number of cells positive for anti-Ki67 antibody (Immunomarking with anti-Ki67 antibody, ×200).***

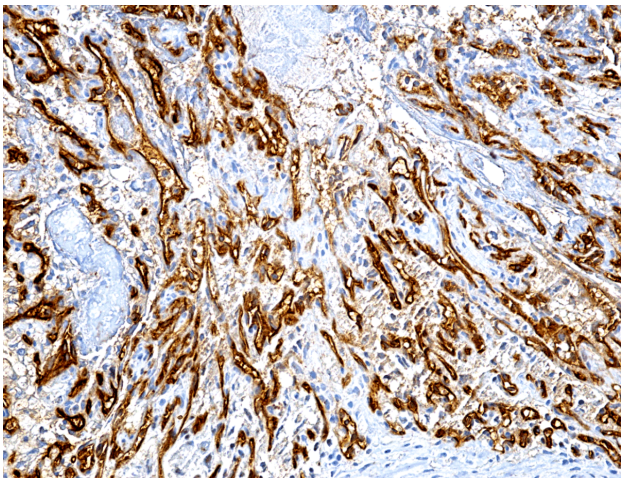

Figure 19 – ***Tumor with intense reaction for anti-CD34 antibody, while reveals the existence of a well represented vascular network (Immunomarking with anti-CD34 antibody, ×200).***

Discussion

When choosing the right approach for this patient, we had to bare in mind multiple aspects. First of all, the nature of the tumor – the histopathological result revealed it to be a metastasis of RCC, which imposed all the rules of oncological surgery, with clear limits of resection. On the other hand, we must emphasize the importance of accurate and thorough imagistic investigations, which showed the true extension of the lesion, and in this particular case, allowed us to evaluate the opportunity of complete resection.

In short term, we consider the results of the surgical intervention to be excellent, as the removal of the tumor was complete, with safety margins, with preservation of the eyeball and a normal visual acuity. Unfortunately, in this case we must not forget that the intervention was necessary due to the high risk of local complications through the growth and extension of the metastasis, but from an oncological point of view, the patient will have to undergo further investigations and treatment for the suspicion of lung and vertebral metastasis, which affect his overall chances of survival.

The diagnosis of sinonasal diseases is based on a combination of clinical symptoms and imagistic findings. The first and most important step is to differentiate between a chronic inflammatory process and a neoplastic lesion. Once this has been achieved, the final diagnosis can be set by biopsy only. A primary tumor of the sinonasal region has similar clinical features and imagistic findings, with a metastatic tumor of another primary, which is why a correct histopathological diagnosis is crucial for the appropriate management of the patient [6]. There are studies demonstrating the value of certain serum markers, such as the serum matrix metalloproteinase (MMP)-2, in determining the characteristics of head and neck tumors [7].

Although metastatic determinations in the head and neck region from primary tumors situated in the infraclavicular area are very rare, according to the literature, RCC is the most frequent type of tumor to associate metastasis of the sinonasal region, accounting for up to 49% of these types of tumors [8]. Other locations of the primary tumor that may cause metastasis in the head and neck region include breast or lung cancers more often,

or tumors of the bronchi, the urogenital tract or the gastrointestinal tract.

RCC is the most frequent malignant tumor of the kidneys, with a predominance for males. The typical presenting symptoms include hematuria, costovertebral pain and an abdominal mass, but it is rare to have all of these complaints present. The tumor has a low growth rate and is well encapsulated, but the evolution and metastatic potential are often unpredictable [9]. The most often treatment includes a surgical intervention with removal of the tumor, but the follow-up is mandatory. Even following a complete removal of the primary tumor, authors have reported metastatic determinations as late as 31 years following the nephrectomy, time in which the patient has been considered disease free [10]. The most frequent sites for metastasis are the lungs, regional lymph nodes, bones and the liver, in the order of frequency. Sinonasal metastases are an exceptional finding.

According to some studies [11, 12], the clear cell renal carcinoma, at the moment of diagnosis, already presents with metastasis in 25–30% of the cases. Another particular characteristic of this type of cancer is the tendency towards local and distant recurrences in approximately 20–40% of the cases following nephrectomy [13]. Usually, the classical histopathological examination can easily set the diagnosis of clear cell renal carcinoma metastasis, when the primary renal tumor has already been discovered. However, when the location of the primary tumor is unknown, the positive and differential diagnosis are more difficult, especially since the renal carcinoma has more histopathological variations [14].

In our study, the histopathological and IHC examinations played a key role in finding the positive diagnosis and in characterizing the tumor' cells. We could demonstrate the fact that, besides clear cells, the tumor also contained cells with acidophilic cytoplasm and cells with tubular architecture.

More studies revealed the fact that renal carcinoma presents not only metastasis with clear cells, but also cells with sarcomatoid or rhabdoid differentiation, cases in which the positive and differential diagnosis can be quite difficult [15, 16]. That is why we consider, as do other authors that the IHC studies are of great aid in the positive and differential diagnosis of some forms of cancer [17–20].

One of the most important aspects of the metastasis of RCCs is their vascular nature and potential for important bleeding. This feature may cause important problems for the surgeon, especially in cases where the diagnosis is yet unknown, as was our patient.

The primary renal tumor may be completely asymptomatic, in which case the only complaints are the ones caused by the metastatic determinations. However, if it is the case of a patient with a sinonasal metastasis, the clinical features are non-specific and do not suggest the real problem. On such patients, the diagnosis is set by the biopsy, but it requires further investigations necessary for locating and evaluating the primary tumor, such as a urine analysis, an abdominal CT or magnetic resonance imaging (MRI) and a pyelogram. The pattern in which a RCC may cause metastasis in the sinonasal region, especially in cases where it is an unique metastasis, has been the subject of multiple research [8], and up to now it appears that the paranasal sinuses are reached after passing the pulmonary filter, *via* the prevertebral venous plexus and the pterygoid plexus.

Due to the rarity of sinonasal metastasis of RCC, the ENT surgeon does not routinely consider this a differential diagnosis, especially if the patient has no complaints caused by the primary tumor, as was our case. However, the right histopathological result will guide the diagnostic steps and a complete and correct management of the patient. As far as the presented case is concerned, we would like to underline some important aspects. First of all, the advanced stage in which the disease has been diagnosed, the patient being free of symptoms caused by the primary tumor. Second, the decision to undergo surgery was influenced by two main aspects: the fact that the imagistic findings indicated that a complete removal was possible with minimum morbidity and by the possible complications that would have occurred in a short period of time. The risk of recurrent and possible massive epistaxis was present due the vascular nature of the tumor. Also, although the eyeball was not affected and the visual acuity was normal, due to the growth of the tumor, the sight would have been affected, either by direct extension or by increased pressure in the orbit, with secondary blindness and a negative impact on the quality of life of the patient. Taking into account all of these aspects, the surgical intervention was considered to be the best option for the patient, followed by oncological treatment, including radiotherapy, chemotherapy and immunotherapy. Local cancer treatments for this type of tumors could have been an option in less advanced cases with low bleeding risk [21–23].

Conclusions

Although it is a very rare finding, the surgeon should consider the metastasis of an unknown primary as a differential diagnosis for sinonasal tumors, especially since the clinical and imagistic features are similar. A correct histopathological diagnosis will guide the management of the patient, where as a complete imagistic evaluation will show if a curative surgical intervention is possible. However, as shown by this case, we must always adapt our strategy to each case, aiming to provide the best chances and quality of life for out patients. Although the overall prognosis of patients that associate multiple metastasis is poor, the correct diagnosis set as soon as possible may increase their overall survival. Such difficult cases, with increased risk of bleeding, may require a complex external approach combined with endoscopy techniques. Only this combination can allow the surgeon to thoroughly assess the limits of the tumor and dissect within safety margins. In our case, this approach allowed us to save the orbit and its content, with negative resection margins, as proved by the biopsy samples.

Conflict of interests

The authors declare that they have no conflict of interests.

References

[1] Batsakis JG, McBurney TA. Metastatic neoplasms to the head and neck. Surg Gynecol Ostet, 1971, 133(4):673–677.

[2] Boles R, Cerny J. Head and neck metastases from renal carcinomas. Mich Med, 1971, 70(16):616–618.
[3] Maschka DA, McCulloch TM, Nerad JA. Prostate cancer metastatic to the orbit. Ann Otol Rhinol Laryngol, 1996, 105(1):70–71.
[4] Har-El G, Avidor I, Weisbord A, Sidi J. Carcinoma of the prostate metastatic to the maxillary antrum. Head Neck Surg, 1987, 10(1):55–58.
[5] Lang EE, Patil N, Walsh RM, Leader M, Walsh MA. A case of renal cell carcinoma metastatic to the nose and tongue. Ear Nose Throat J, 2003, 82(5):382–383.
[6] Bernstein JM, Montgomery WW, Balogh K Jr. Metastatic tumors to the maxilla, nose, and paranasal sinuses. Laryngoscope, 1966, 76(4):621–650.
[7] Stanciu AE, Zamfir Chiru Anton A, Stanciu MM, Popescu CR, Gheorghe DC, Nitipir C. Serum matrix metalloproteinase-2 in head and neck squamous cell carcinoma is associated with tumor differentiation. Rom Biotechnol Lett, 2017, 22(2): 12419–12426.
[8] Evgeniou E, Menon KR, Jones GL, Whittet H, Williams W. Renal cell carcinoma metastasis to the paranasal sinuses and orbit. BMJ Case Rep, 2012, 2012:bcr0120125492.
[9] Nahum AM, Bailey BJ. Malignant tumors metastatic to the paranasal sinuses: case report and review of the literature. Laryngoscope, 1963, 73(7):942–953.
[10] McNichols DW, Segura JW, DeWeerd JH. Renal cell carcinoma: long-term survival and late recurrence. J Urol, 1981, 126(1): 17–23.
[11] Ljungberg B, Alamdari FI, Stenling R, Roos G. Prognostic significance of the Heidelberg classification of renal cell carcinoma. Eur Urol, 1999, 36(6):565–569.
[12] Lee C, Park JW, Suh JH, Nam KH, Moon KC. Histologic variations and immunohistochemical features of metastatic clear cell renal cell carcinoma. Korean J Pathol, 2013, 47(5): 426–432.
[13] Lam JS, Leppert JT, Figlin RA, Belldegrun AS. Surveillance following radical or partial nephrectomy for renal cell carcinoma. Curr Urol Rep, 2005, 6(1):7–18.
[14] Eble JN, Sauter G, Epstein JI, Sesterhenn IA (eds). Pathology and genetics of tumours of the urinary system and male genital organs. World Health Organization (WHO) Classification of Tumors, International Agency for Research on Cancer (IARC) Press, Lyon, 2004, 12–39.
[15] Shuch B, Bratslavsky G, Shih J, Vourganti S, Finley D, Castor B, Treat E, Linehan WM, Pantuck AJ, Said JW, Belldegrun AS. Impact of pathological tumour characteristics in patients with sarcomatoid renal cell carcinoma. BJU Int, 2012, 109(11):1600–1606.
[16] Chapman-Fredricks JR, Herrera L, Bracho J, Gomez-Fernandez C, Leveillee R, Rey L, Jorda M. Adult renal cell carcinoma with rhabdoid morphology represents a neoplastic dedifferentiation analogous to sarcomatoid carcinoma. Ann Diagn Pathol, 2011, 15(3):333–337.
[17] Sangoi AR, Karamchandani J, Kim J, Pai RK, McKenney JK. The use of immunohistochemistry in the diagnosis of metastatic clear cell renal cell carcinoma: a review of PAX-8, PAX-2, hKIM-1, RCCma, and CD10. Adv Anat Pathol, 2010, 17(6): 377–393.
[18] Truong LD, Shen SS. Immunohistochemical diagnosis of renal neoplasms. Arch Pathol Lab Med, 2011, 135(1):92–109.
[19] Poiană C, Carşote M, Ardeleanu C, Terzea D, Avramescu ET, Neamţu MC, Miulescu RD. The value of the immunohistochemistry in a case of gastric neuroendocrine tumor and thyroid metastasis. Rom J Morphol Embryol, 2011, 52(1):187–192.
[20] Barbu CG, Florin A, Neamţu MC, Avramescu ET, Terzea D, Miron A, Dănciulescu Miulescu R, Poiană C, Fica S. Papillary thyroid carcinoma with anaplastic dedifferentiation in the lymph node metastasis – a rare form of presentation even for a tall cell variant. Rom J Morphol Embryol, 2015, 56(2):527–531.
[21] Yipel M, Ghica MV, Albu Kaya MG, Spoiala A, Radulescu M, Ficai D, Ficai A, Bleotu C, Nitipir C. Multifunctional materials for cancer therapy: from antitumoral agents to innovative administration. Curr Org Chem, 2016, 20(28):2934–2948.
[22] Nitipir C, Albu MG, Voicu G, Ficai A, Barbu MA, Popa LG, Mirea D, Lazar S, Levai C, Ghica MV. Collagen–vinblastine delivery systems as a new treatment for Kaposi's sarcoma. Rev Chim (Bucharest), 2015, 66(8):1169–1172.
[23] Ghica MV, Albu MG, Kaya DA, Popa L, Öztürk Ş, Rusu LC, Dinu-Pîrvu C, Chelaru C, Albu L, Meghea A, Nitipir C. The effect of lavandula essential oils on release of niflumic acid from collagen hydrolysates. Korean J Chem Eng, 2016, 33(4): 1325–1330.

Corresponding author
Florin Anghelina, Associate Professor, MD, PhD, Department of ENT, University of Medicine and Pharmacy of Craiova, 2 Petru Rareş Street, 200349 Craiova, Romania; Phone +40742–031 003, e-mail: anghelina.florin@gmail.com

Received: December 15, 2016

Accepted: February 28, 2018