

## CASE REPORT

# Is thyrogastric disease a potential setting for oncogenesis? Gastric adenoneuroendocrine carcinoma arising from *Helicobacter pylori*-associated atrophic gastritis in a patient with autoimmune thyroiditis

KAVITA GAUR<sup>1)</sup>, RAVINDRA KUMAR SARAN<sup>1)</sup>, VINEETA VIJAY BATRA<sup>1)</sup>, PUJA SAKHUJA<sup>1)</sup>,  
PRAMOD KUMAR MISHRA<sup>2)</sup>

<sup>1)</sup>Department of Pathology, Govind Ballabh Pant Institute of Postgraduate Medical Education and Research, New Delhi, India

<sup>2)</sup>Department of Gastrointestinal Surgery, Govind Ballabh Pant Institute of Postgraduate Medical Education and Research, New Delhi, India

## Abstract

Gastric mixed adenoneuroendocrine carcinoma arising from *Helicobacter pylori*-associated multifocal atrophic gastritis is exceedingly rare. An added association with autoimmune thyroiditis in this case highlighted a complex interplay between *Helicobacter*, autoimmunity and gastric atrophy. A 55-year-old hypothyroid female presented with hematemesis and a large polypoidal mass in the gastric fundus, suggestive of gastrointestinal stromal tumor on imaging and endoscopy. Histopathology revealed a tumor comprised of nests of monomorphic cells immunopositive for synaptophysin and chromogranin A admixed with malignant glands. Follow-up imaging revealed a heterogeneously enhancing residual gastric body wall. A completion total gastrectomy was performed. Histopathology displayed multifocal atrophic gastritis, occasional *Helicobacter* and nests of neuroendocrine cells. The patient also had markedly elevated levels of anti-thyroid peroxidase and anti-thyroglobulin. To the best of our knowledge, this is the first case of gastric adenoneuroendocrine carcinoma arising from *H. pylori*-associated atrophic gastritis, in a patient with autoimmune thyroiditis.

**Keywords:** carcinoma, neuroendocrine, *Helicobacter pylori*, gastritis, atrophic.

## Introduction

The “thyrogastric syndrome” is a peculiar autoimmune association in which affected patients develop antibodies to gastric parietal cells, thyroid peroxidase and thyroglobulin resulting in subsequent disease. In 1998, de Luis *et al.* [1] described an increased incidence of *Helicobacter pylori* (HP) infection in patients of autoimmune thyroiditis. The link between HP and gastric carcinoma is well established. However, its potential to cause neuroendocrine tumors in humans has rarely been reported in literature [2].

We report here a unique case of autoimmune thyroiditis in which the patient subsequently developed gastric mixed adenoneuroendocrine carcinoma (GMANEC) in a background of HP-associated multifocal gastritis. The patient was negative for gastric autoantibodies. To the best of our knowledge, this is the first such case to be reported. This report highlights the complex dynamics between gastric atrophy, HP, autoimmunity and potential oncogenesis.

## Case presentation

A 55-year-old female presented in the casualty with a history of two episodes of hematemesis without associated melena, fever, jaundice or altered bowel habits. The patient also had complaints of fatigue for the last six months. There was no history of loss of appetite/weight, altered

sensorium or drug abuse. The patient was postmenopausal and was diagnosed with hypothyroidism three years back for which she was taking 75 mg of thyroxine. No other significant past history was elicited apart from occasional episodes of indigestion over the last five to six years for which no medical assistance was taken.

Emergency upper gastrointestinal (UGI) endoscopy showed a large polypoidal mass with superficial ulceration seen in the fundus and proximal gastric body, suggestive of a gastrointestinal stromal tumor (GIST). Clinical examination showed pallor and laboratory parameters showed reduced hemoglobin (64 g/L), with mild thrombocytopenia ( $110 \times 10^9/L$ ) and a normocytic normochromic blood picture. Her thyroid function tests at the time of admission showed an elevated thyroid stimulating hormone (TSH) 8.6 mU/L, decreased free T3 and T4 (2 pmol/L and 8.6 pmol/L, respectively). All other routine investigations were normal.

Contrast-enhanced computed tomography (CECT) showed a 5×4 cm heterogeneously enhancing mass in the greater curvature (Figure 1a). The patient was transfused two units of packed red blood cells and a wide local excision was performed for the suspected GIST.

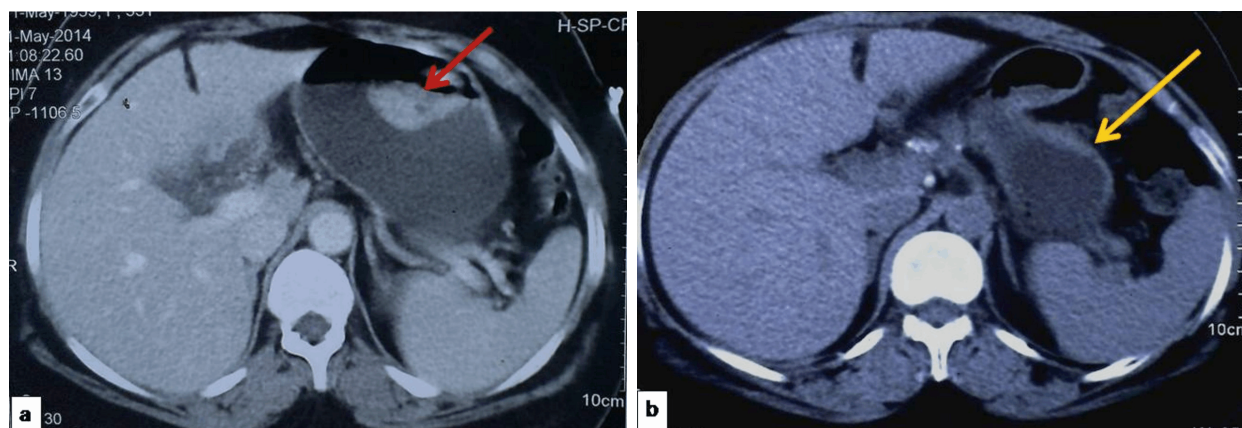
Preoperatively, a 4×5 cm intraluminal polypoidal lesion with an ulcer crater 3×3 cm in size was seen. Histopathological examination showed a tumor with two components (Figure 2, a–c). The first component showed

epithelial glandular formations positive for cytokeratin (CK) 7, epithelial membrane antigen (EMA) (Figure 2, d and f) and negative for CK20. The second comprised of monomorphic sheets and nests of cells showing stippled nuclear chromatin strongly immunopositive for synaptophysin and chromogranin A (Figure 2e). The neuroendocrine component was largely well differentiated, with foci of moderate differentiation. Each component roughly comprised 50% of the tumor and was admixed with each other. MIB-1 labeling index ascertained by an eyeballed estimate was 40% in the glandular areas and 25% in the neuroendocrine nests (Figure 2g), conferring a diagnosis of mixed adenoneuroendocrine carcinoma. Margin status of the resected specimen was negative.

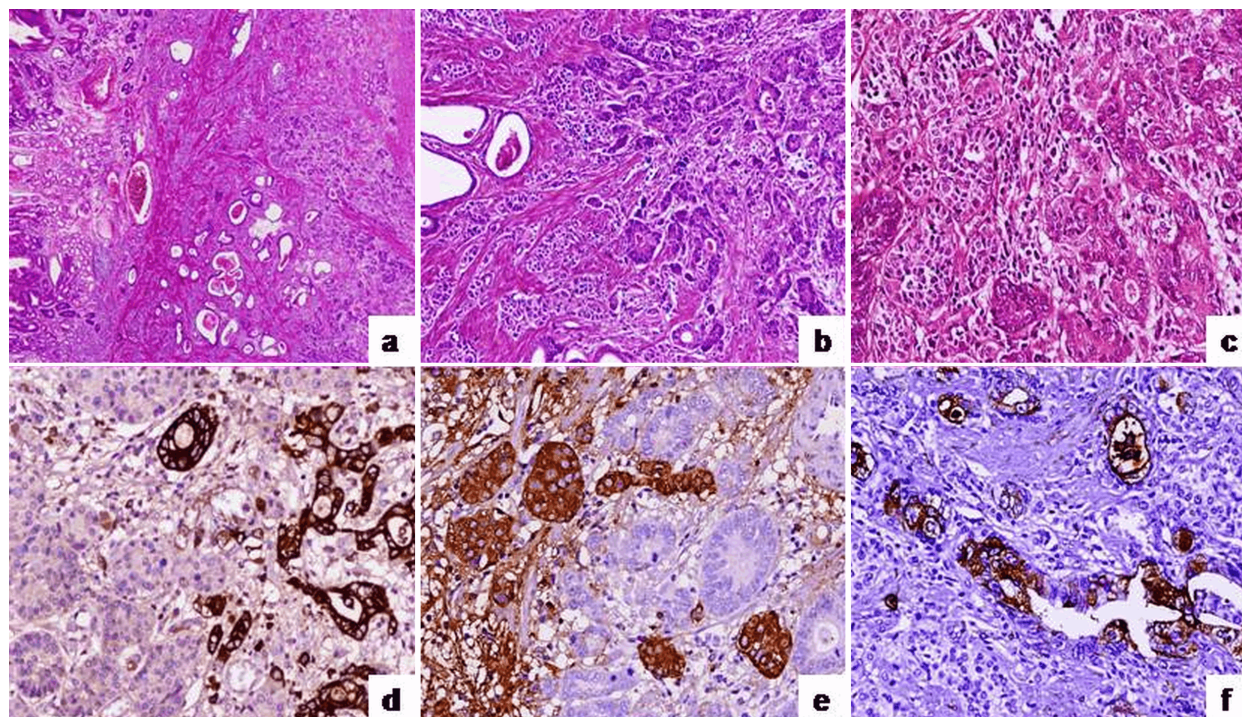
Two months later, the patient was taken up for a completion gastrectomy. CECT showed an asymmetrical

heterogeneously enhancing wall thickening of the residual gastric body (Figure 1b) with an hourglass appearance and minimal perigastric stranding. UGI endoscopy showed hyperemic mucosa at the distal part of the suture line.

Histopathology of the excised suture line tissue showed occasional clusters of neuroendocrine cells positive for synaptophysin (Figure 3). The residual stomach showed multifocal atrophic gastritis (Figure 4, a, b and d) afflicting both the corpus and antrum in a patchy fashion. Occasional, HP was seen in the antral area (Figure 4e). This was accompanied by intestinal metaplasia (Figure 4c), low-grade dysplasia and neuroendocrine tumorlets in the lamina of the corpus (Figure 2, h and i). Gastrin (G) immunostaining showed no evidence of G-cell hyperplasia (Figure 4f). Twelve lymph nodes ranging from 0.1 to 1 cm were resected all of which were free of tumor.

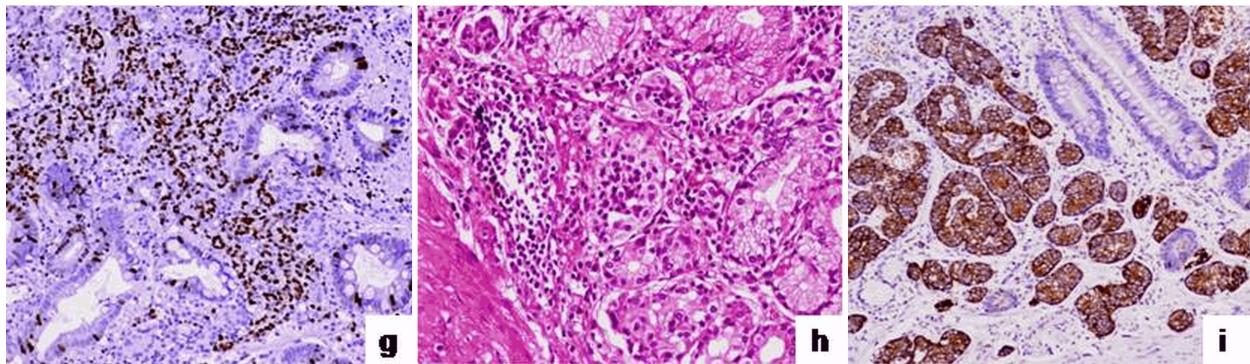


**Figure 1 – Imaging findings:** (a) CECT scan showing a heterogeneously enhancing gastric mass (red arrow); (b) Post-operative CECT showing heterogeneous wall thickening of the greater curvature (yellow arrow).

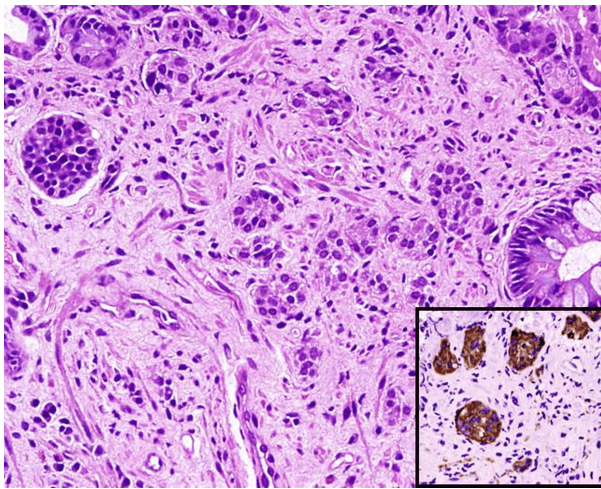


**Figure 2 – Tumor showing both glandular and neuroendocrine components:** (a) In low power [Hematoxylin–Eosin (HE) staining,  $\times 40$ ]; (b and c) At higher magnifications (HE staining,  $\times 100$  and  $\times 200$ , respectively); (d) Glandular component positive for CK7 (Anti-CK7 antibody immunostaining,  $\times 200$ ); (e) Neuroendocrine component immunopositive for chromogranin A (Anti-chromogranin A antibody immunostaining,  $\times 200$ ); (f) EMA immunopositivity in the glandular areas (Anti-EMA antibody immunostaining,  $\times 200$ ).





**Figure 2 (continued)** – Tumor showing both glandular and neuroendocrine components: (g) MIB-1 labeling index of 25% in the neuroendocrine nests (Anti-Ki67 antibody immunostaining,  $\times 100$ ); (h) Residual stomach showing neuroendocrine nests (HE staining,  $\times 400$ ), highlighted by synaptophysin in (i) (Anti-synaptophysin antibody immunostaining,  $\times 40$ ).



**Figure 3** – Tissue at suture line shows nests of neuroendocrine cells (HE staining,  $\times 400$ ). Inset: Tumor cells positive for synaptophysin (Anti-synaptophysin antibody immunostaining,  $\times 400$ ).

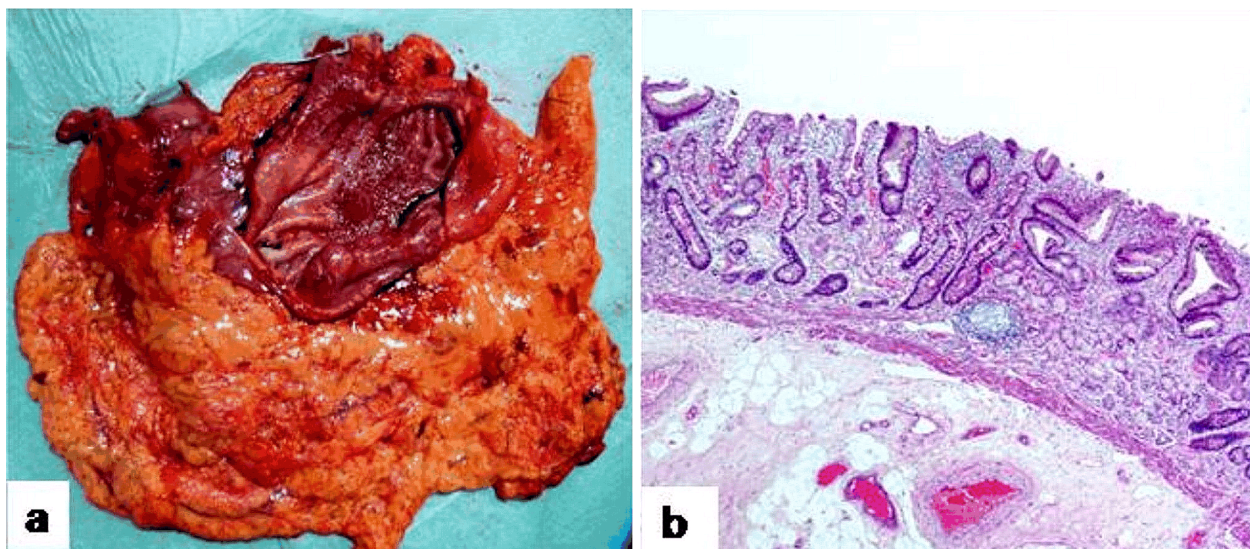
A detailed workup to rule out pernicious anemia was done in light of the marked gastric atrophy. Serum B12 and folate levels were normal. Antibodies to gastric parietal cell (Euroimmun, Indirect Immunofluorescence) and intrinsic factor (serum IgG 1.1 U/mL) were both

negative. Tests for antinuclear antigen (ANA) and double-stranded deoxyribonucleic acid (dsDNA) were negative. Nuclear line antigen assay showed no specific autoantibodies. Serum levels of anti-thyroglobulin ( $>2500$  U/mL) and anti-thyroid peroxidase (470.1 U/mL) measured by chemiluminescence assay however, were markedly elevated. The patient's dose of thyroxine was subsequently increased to 100 mg by the treating physician.

After one year of follow-up, the patient is currently doing well and is free of complaints.

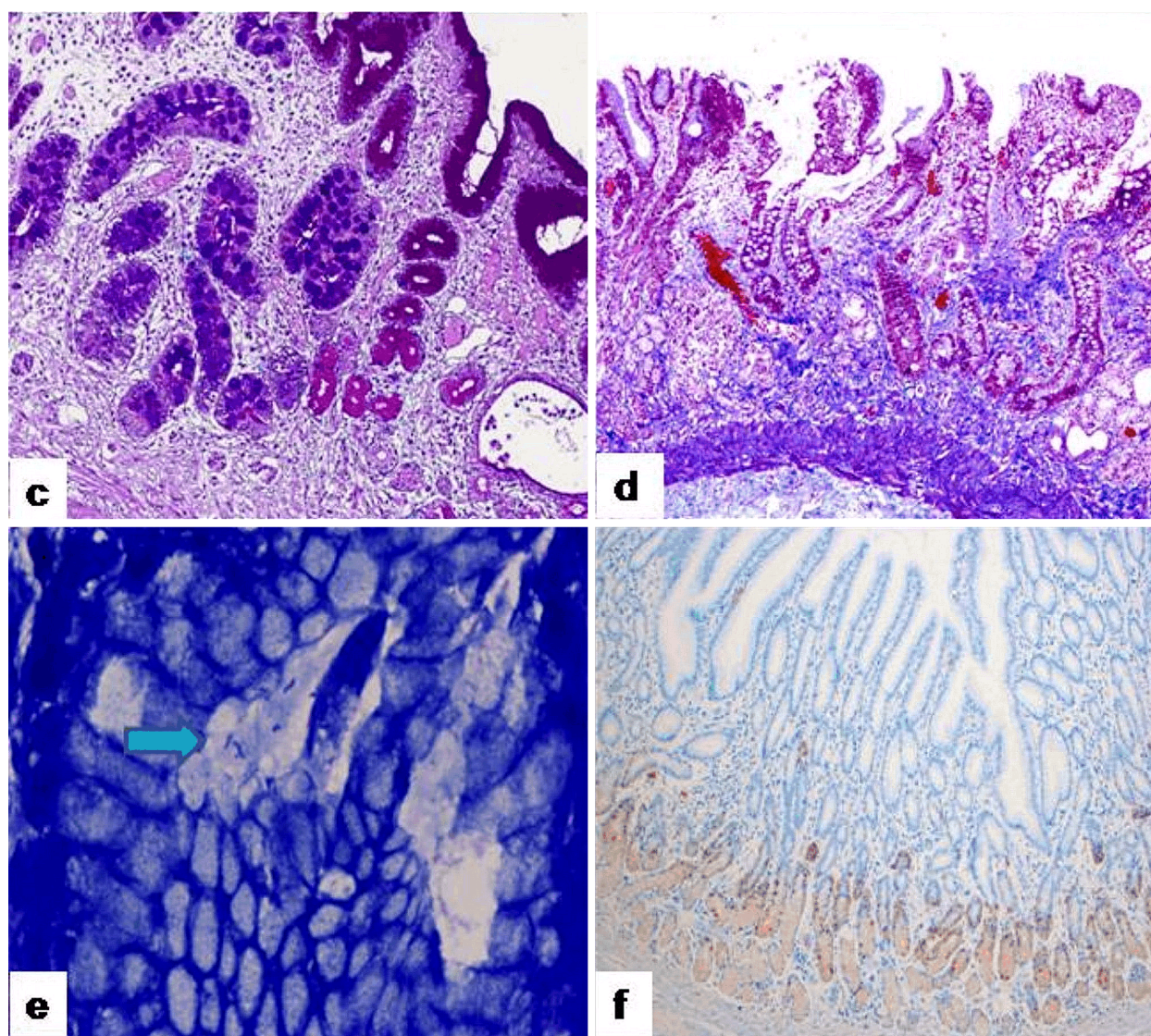
## Discussion

Mixed adenoneuroendocrine carcinomas (MANECs), earlier known as mixed exocrine–endocrine tumors are a rare type of gastroenteropancreatic neuroendocrine neoplasms. The latest *World Health Organization* (WHO) guidelines define these neoplasms as having at least 30% each of gland forming epithelial and neuroendocrine components [3]. MANECs have been described in sites like the appendix, small and large bowel, esophagus, gallbladder and rarely the stomach [4].



**Figure 4** – (a) Operative specimen of the residual stomach showing focal loss of rugae and atrophic mucosa in the corpus; (b) Low power view of antrum showing reduced mucosal thickness (HE staining,  $\times 40$ ).





**Figure 4 (continued) – (c) Intestinal metaplasia highlighted by Alcian blue [Periodic acid Schiff with Diastase (PAS-D)–Alcian blue staining,  $\times 100$ ]; (d) Atrophic changes also seen in the corpus mucosa (Masson's trichrome staining,  $\times 40$ ); (e) Occasional *H. pylori* (arrow) seen in an antral crypt (Modified Giemsa staining,  $\times 1000$ ); (f) Gastrin (G) immunostaining showing normal G-cell density (Anti-gastrin antibody immunostaining,  $\times 100$ ).**

Few cases of gastric MANECs (GMANECs) have been described as arising from a background of corpus-restricted atrophy [5–9]. To the best of our knowledge, this is the first such case arising from a background of multifocal atrophic gastritis (MFAG). Gastric atrophy may have an autoimmune etiology, described more commonly in Western literature. It may also be the end result of long-standing *Helicobacter* infection more prevalent in Asia, as seen in this case. The GMANEC is believed to arise from bidirectional differentiation of a common precursor cell or coincidental neoplasia in separate precursors [9]. An extension of the second theory is that the glandular component follows the metaplasia–dysplasia sequence, while the neuroendocrine component is sequelae of enterochromaffin cell (ECL) hyperplasia secondary to hypergastrinemia [7]. Autoimmune-mediated destruction of the parietal cells described in previous cases [5–9] leads to reduced acidity and achlorhydria, which removes the inhibition on gastrin.

In our case, the patient had not taken prior proton-pump inhibitor (PPI) therapy. Absence of gastric parietal

cell and intrinsic factor antibodies along with normal serum B12 and folate levels made autoimmune gastritis unlikely. Hypergastrinemia due to long-term PPI intake or autoimmune mediated gastric atrophy could therefore not explain the development of tumor. Serum gastrin levels were not done prior to surgery, as the endoscopic findings were more suggestive of a polypoidal tumor. Gastrin (G) immunostaining also did not reveal G-cell hyperplasia, though some authors have referred to the lack of correlation between G-cell density and gastrin levels [10]. In the absence of definite evidence of hypergastrinemia, the exact cause for the neuroendocrine hyperplasia and subsequent tumorigenesis may seem elusive. However, recent studies suggest that HP may act through mechanisms independent of gastrin in triggering ECL hyperplasia including inflammation-associated apoptosis [2].

The present case showed tissue evidence of HP infection. MFAG, sequelae of HP infection involves both the corpus and antrum in a patchy fashion. Vannella *et al.* [11] observed that corpus-restricted atrophy associated



with pernicious anemia is a less likely setting for gastric oncogenesis. Chronic HP infection on the other hand is associated with a more extensive pangastritis and subsequent atrophy. HP infection is rarely associated with the development of neuroendocrine tumors in humans as seen in this case. Lipopolysaccharides associated with the bacterium are believed to stimulate ECL cell proliferation [12].

An interesting facet to this case was the presence of thyroid autoantibodies. HP infection is associated with extragastrointestinal manifestations including organ-specific autoimmune disease [1]. The link between HP and autoimmune thyroopathy is believed to be through the same lipopolysaccharide (LPS) implicated in ECL proliferation. Molecular mimicry between LPS and Lewis blood group antigens are believed to cause the autoimmune activation in sites away from the stomach [13]. The association between HP and autoimmune thyroid disease has been examined in a number of studies [1, 14–24] with most recording a definite association. A large Czech study [14] on the relationship between HP and anti-gastric and anti-thyroid antibodies observed that the antibodies were more common in HP-infected patients suggesting that the bacterium may have a role in the thyrogastric syndrome. However, a recent meta-analysis and few prior studies [17, 19, 24, 25] have refuted this hypothesis. In the context of the present case that may imply that association of the GMANEC, HP atrophic gastritis and thyroid antibodies may be incidental and not causal. We do acknowledge this limitation; however, this report may provide further research direction on elucidating a possible oncogenetic link between HP, thyroid antibodies and gastric cancer.

In our case, antibodies to gastric parietal cells were absent. The gastric atrophy brought on by HP mimicked autoimmune gastritis and even its possible remote effects like autoimmune thyroiditis. The patient underwent a complete gastric resection. Histologically, though the neuroendocrine component appeared more well differentiated, a high Ki67 index was noted. As previously suggested by some authors, differentiation and grade may not synchronize in all cases [15]. The patient is hence being kept on a vigilant follow-up and is currently doing well.

## Conclusions

The present case highlighted that HP alone may “multitask” and trigger bidirectional neoplastic cell proliferation, while promoting autoimmune destruction of a distant site, the thyroid in this case. Though there is currently no evidence that HP screening is necessary in autoimmune disease, this report may direct further studies on larger cohorts to validate such a strategy and clearly elucidate all pathways behind such a multi-pronged pathology.

## Conflict of interests

The authors have no conflict of interests to declare.

## Acknowledgments

The authors would like to thank Dr Dhanpat Jain, Professor of Pathology and Internal Medicine, Yale University, Connecticut, USA, for helping us with the

gastrin immunostaining performed at Yale, while studying this case.

## Presentation

This case was presented at “Symposium on Gastrointestinal Pathology” – 2015, SRL Fortis Faridabad, Delhi – National Capital Region (NCR), India.

## References

- [1] de Luis DA, Varela C, de La Calle H, Cantón R, de Argila CM, San Roman AL, Boixeda D. *Helicobacter pylori* infection is markedly increased in patients with autoimmune atrophic thyroiditis. *J Clin Gastroenterol*, 1998, 26(4):259–263.
- [2] Antonodimitrak P, Tsolakis A, Welin S, Kozlovacki G, Oberg K, Granberg D. Gastric carcinoid in a patient infected with *Helicobacter pylori*: a new entity? *World J Gastroenterol*, 2011, 17(25):3066–3068.
- [3] Rindi G, Arnold R, Bosman FT, Capella C, Kilmstra DS, Kloppel G, Komminoth P, Solcia E. Nomenclature and classification of neuroendocrine neoplasms of the digestive system. In: Bosman FT, Carneiro F, Hruban RH, Theise ND (eds). *World Health Organization (WHO) Classification of Tumours of the Digestive System*. 4<sup>th</sup> edition, International Agency for Research on Cancer (IARC) Press, Lyon, France, 2010, 13–14.
- [4] Pericleous M, Toumpanakis C, Lumgair H, Caplin ME, Morgan-Rowe L, Clark I, Luong TV. Gastric mixed adenoneuroendocrine carcinoma with a trilineage cell differentiation: case report and review of the literature. *Case Rep Oncol*, 2012, 5(2):313–319.
- [5] Caruso ML, Pilato FP, D’Adda T, Baggi MT, Fucci L, Valentini AM, Lacatena M, Bordi C. Composite carcinoid-adenocarcinoma of the stomach associated with multiple gastric carcinoids and nonantral gastric atrophy. *Cancer*, 1989, 64(7):1534–1539.
- [6] Pasquinelli G, Santini D, Preda P, Cariani G, Bonora G, Martinelli GN. Composite gastric carcinoma and precursor lesions with amphicrine features in chronic atrophic gastritis. *Ultrastruct Pathol*, 1993, 17(1):9–24.
- [7] Adhikari D, Conte C, Eskreis D, Urmacher C, Ellen K. Combined adenocarcinoma and carcinoid tumor in atrophic gastritis. *Ann Clin Lab Sci*, 2002, 32(4):422–427.
- [8] Ronellenfitsch U, Ströbel P, Schwarzbach MHM, Staiger WI, Grager D, Kähler G. Composite adenoendocrine carcinoma of the stomach arising from a neuroendocrine tumor. *J Gastrointest Surg*, 2007, 11(11):1573–1575.
- [9] Nugent SL, Cunningham SC, Alexiev BA, Bellavance E, Papadimitriou JC, Hanna N. Composite signet-ring cell/neuroendocrine carcinoma of the stomach with a metastatic neuroendocrine carcinoma component: a better prognosis entity. *Diagn Pathol*, 2007, 2:43.
- [10] Petersson F, Borch K, Rehfeld JF, Franzén LE. A morphometric study of antral G-cell density in a sample of adult general population: comparison of three different methods and correlation with patient demography, *Helicobacter pylori* infection, histomorphology and circulating gastrin levels. *Int J Clin Exp Pathol*, 2009, 2(3):239–248.
- [11] Vannella L, Lahner E, Annibale B. Risk for gastric neoplasias in patients with chronic atrophic gastritis: a critical reappraisal. *World J Gastroenterol*, 2012, 18(12):1279–1285.
- [12] Kidd M, Tang LH, Schmid S, Lauffer J, Louw JA, Modlin IM. *Helicobacter pylori* lipopolysaccharide alters ECL cell DNA synthesis via a CD14 receptor and polyamine pathway in mastomys. *Digestion*, 2000, 62(4):217–224.
- [13] Appelmek BJ, Simoons-Smit I, Negrini R, Moran AP, Aspinall GO, Forte JG, De Vries T, Quan H, Verboom T, Maaskant JJ, Ghiara P, Kuipers EJ, Bloemena E, Tadema TM, Townsend RR, Tyagarajan K, Crothers JM Jr, Monteiro MA, Savio A, De Graaff J. Potential role of molecular mimicry between *Helicobacter pylori* lipopolysaccharide and host Lewis blood group antigens in autoimmunity. *Infect Immun*, 1996, 64(6):2031–2040.
- [14] Sterzl I, Hrdá P, Matucha P, Cerovská J, Zamrazil V. Anti-*Helicobacter pylori*, anti-thyroid peroxidase, anti-thyroglobulin and anti-gastric parietal cells antibodies in Czech population. *Physiol Res*, 2008, 57(Suppl 1):S135–S141.



- [15] Venturi S, Venturi M. Iodide, thyroid and stomach carcinogenesis: evolutionary story of a primitive antioxidant? *Eur J Endocrinol*, 1999, 140(4):371–372.
- [16] Figura N, Di Cairano G, Lorè F, Guarino E, Gragnoli A, Cataldo D, Giannace R, Vaira D, Bianciardi L, Kristodhullu S, Lenzi C, Torricelli V, Orlandini G, Gennari C. The infection by *Helicobacter pylori* strains expressing CagA is highly prevalent in women with autoimmune thyroid disorders. *J Physiol Pharmacol*, 1999, 50(5):817–826.
- [17] Franceschi F, Satta MA, Mentella MC, Penland R, Candelli M, Grillo RL, Leo D, Fini L, Nista EC, Cazzato IA, Lupascu A, Pola P, Pontecorvi A, Gasbarrini G, Genta RM, Gasbarrini A. *Helicobacter pylori* infection in patients with Hashimoto's thyroiditis. *Helicobacter*, 2004, 9(4):369.
- [18] Bertalot G, Montresor G, Tampieri M, Spasiano A, Pedroni M, Milanesi B, Favret M, Manca N, Negrini R. Decrease in thyroid autoantibodies after eradication of *Helicobacter pylori* infection. *Clin Endocrinol (Oxf)*, 2004, 61(5):650–652.
- [19] Tomasi PA, Dore MP, Fanciulli G, Sanciu F, Realdi G, Delitala G. Is there anything to the reported association between *Helicobacter pylori* infection and autoimmune thyroiditis? *Dig Dis Sci*, 2005, 50(2):385–388.
- [20] Sterzl I, Hrdá P, Potuznikova B, Matucha P, Hana V, Zamrazil V. Autoimmune thyroiditis and *Helicobacter pylori* – is there a connection? *Neuro Endocrinol Lett*, 2006, 27(Suppl 1):41–45.
- [21] Larizza D, Calcaterra V, Martinetti M, Negrini R, De Silvestri A, Cisternino M, Iannone AM, Solcia E. *Helicobacter pylori* infection and autoimmune thyroid disease in young patients: the disadvantage of carrying the human leukocyte antigen-DRB1\*0301 allele. *J Clin Endocrinol Metab*, 2006, 91(1):176–179.
- [22] Aghili R, Jafarzadeh F, Ghorbani R, Khamseh ME, Salami MA, Malek M. The association of *Helicobacter pylori* infection with Hashimoto's thyroiditis. *Acta Med Iran*, 2013, 51(5):293–296.
- [23] Shi WJ, Liu W, Zhou XY, Ye F, Zhang GX. Associations of *Helicobacter pylori* infection and cytotoxin-associated gene A status with autoimmune thyroid diseases: a meta-analysis. *Thyroid*, 2013, 23(10):1294–1300.
- [24] Shmueli H, Shimon I, Gitter LA. *Helicobacter pylori* infection in women with Hashimoto thyroiditis: a case-control study. *Medicine (Baltimore)*, 2016, 95(29):e4074.
- [25] Tang LH, Shia J, Vakiani E, Dhall D, Klimstra DS. High grade transformation of differentiated neuroendocrine neoplasms (NENs) of the enteropancreatic system – a unique entity distinct from *de novo* high grade neuroendocrine carcinoma (HGNECa) in pathogenesis and clinical behavior. 97<sup>th</sup> Annual Meeting of the United States and Canadian Academy of Pathology (USCAP), March 1–7, 2008, Denver, Colorado, USA, Lab Invest, 2008, 88(Suppl 1):137A (Meeting Abstract: 622).

### Corresponding author

Ravindra Kumar Saran, MD, D.N.B, Director Professor, Department of Pathology, Govind Ballabh Pant Institute of Postgraduate Medical Education and Research, 1 Jawaharlal Nehru Marg, Academic Block, Room No. 333, 110002 New Delhi, India; Phone 91–11–9718599074, Fax 01123221835, e-mail: ravindraksaran@hotmail.com

Received: February 7, 2017

Accepted: February 3, 2018