

Keratinocyte growth factor and its receptor expression in chronic otitis media with and without cholesteatoma

OANA ELENA HARABAGIU¹⁾, MARCEL COSGAREA¹⁾, CARMEN AURELIA MOGOANTĂ²⁾, DANIEL CORNELIU LEUCUȚA³⁾, ALMA AURELIA MANIU¹⁾

¹⁾Department of Otorhinolaryngology, "Iuliu Hațieganu" University of Medicine and Pharmacy, Cluj-Napoca, Romania

²⁾Department of Otorhinolaryngology, University of Medicine and Pharmacy of Craiova, Romania

³⁾Department of Medical Informatics and Biostatistics, "Iuliu Hațieganu" University of Medicine and Pharmacy, Cluj-Napoca, Romania

Abstract

Introduction: Chronic suppurative otitis media (CSOM) with and without cholesteatoma is regarded as chronic inflammation of the middle ear and mastoid mucosa that can be associated with the presence of granulation tissue and infection, which can lead to ossicular damage and hearing loss, but it is commonly known that cholesteatoma behaves aggressively. Both lesions appear to contain a predominant population of inflammatory cells, among which proinflammatory cytokines secreting keratinocyte growth factor (KGF) and its receptor (KGFR). No clear difference was demonstrated between these entities. The purpose of this study was to investigate the potential influence of KGF and KGFR in increased epithelial-cell proliferation of chronic otitis media (COM) with cholesteatoma in contrast to COM without cholesteatoma (CSOM), particularly in the granulative form, and to compare the rate of proliferation activity of epithelial cells using the Ki-67 epithelial proliferation marker expression. **Patients, Materials and Methods:** We analyzed 105 ears with cholesteatoma vs. 53 ears with CSOM without cholesteatoma using our KGF and KGFR variables, and the ratio of proliferating epithelial cells using Ki-67. The percentage of the specimens expressing KGF and KGFR was compared between the two groups for statistical significance using the Pearson's *chi-square* test. Immunohistochemical staining was conducted and the proportion of the cells staining positive for the nuclear antigen Ki-67 was evaluated in a quantitative and visual way, using light microscopes. **Results:** KGF was positive in 88.57% of cholesteatoma and was positive in 41.51% CSOM without cholesteatoma specimens (cholesteatoma vs. CSOM, $p=0.001$). The positive rate of KGFR in the CSOM group was 33.96% compared to those in cholesteatoma, which was 60.95%. Compared to the cholesteatoma specimens, a significantly smaller number of Ki-67 labeling index was detected in CSOM specimens. **Conclusions:** Our results indicated that the abnormal behavior of the cholesteatoma epithelium seems to be induced by the paracrine interaction between KGF and KGFR. Furthermore, we found that cholesteatoma expressing both KGF and KGFR had high Ki-67 index, which correlated with its aggressiveness. These findings suggest that excessive KGF and KGFR synthesis may contribute to the hyperproliferative state in cholesteatoma and could explain the pathological difference between cholesteatoma and CSOM.

Keywords: cholesteatoma, middle ear, keratinocyte growth factor, chronic otitis media, Ki-67.

Introduction

Chronic suppurative otitis media (CSOM) with or without cholesteatoma represents a chronic inflammation of the middle ear and mastoid mucosa, in which the tympanic membrane (TM) is not intact and discharge is present [1]. Usually, both types of lesions are associated with the presence of granulation tissue and infection, which can lead to ossicular damage and hearing loss, but it is commonly known that cholesteatoma behaves more aggressively, being able to cause fatal intracranial complications [2].

Several theories have tried to explain the migration and invasion properties pertaining to the disease [3]. Currently, according to recent advances in biomolecular research, cholesteatoma could be considered a disorder in cell growth control [4]. One of the suppositions is that the growth of cholesteatoma cultures can be explained by a higher growth factor activity, such as keratinocyte growth factor (KGF) and its receptor (KGFR) [5]. These are secreted cytokines by the cholesteatoma perimatrix fibroblasts. Their production is initiated by the pro-

inflammatory cytokines released by the keratinocytes from the matrix [6]. Werner *et al.* showed that KGF was expressed in normal skin and was induced upon injury [7]. KGF was predominantly expressed in stromal cells below and at edge of the wound, and that KGFR was detected in the epidermis. They concluded that a KGF-mediated paracrine interaction may be important for the migration and proliferation of epidermal keratinocytes seen during wound healing. Staiano-Coico *et al.* also indicated that KGF had marked effects on the epithelialization and healing of wounds [8]. Cholesteatoma is a disorder of uncoordinated proliferation, migration and invasion of the involved keratinocytes. Researchers have stated that there are some cytokines of epithelial origin that can be considered markers of keratinocytes proliferation [9].

Ki-67 is a nuclear protein associated with cellular proliferation and was originally identified by Gerdes *et al.* [10] in the early 1980's, using a mouse monoclonal antibody directed against a nuclear antigen from a Hodgkin's lymphoma-descended cell line. The most prevalent analysis method of Ki-67 antigen is the immunohistochemical (IHC) evaluation [11]. The expression of the human Ki-67 protein

is strictly associated with cell proliferation. During interphase, the antigen can be exclusively detected within the nucleus, whereas in mitosis most of the protein is relocated to the surface of the chromosomes [12]. Ki-67 expression was shown to be higher in cholesteatoma tissues compared to controls [13]. Lately, many surveys have reported the higher KGFR expression in cases of middle ear cholesteatoma samples compared to the normal skin but very few of them referred to chronic otitis media (COM) without cholesteatoma.

The purpose of the study was to investigate the potential influence of KGF and KGFR in increased epithelial-cell proliferation of COM with cholesteatoma in contrast to COM without cholesteatoma (CSOM), particularly in the granulative form, and to compare the rate of proliferation activity of epithelial cells using the Ki-67 epithelial proliferation marker expression.

☞ Patients, Materials and Methods

We performed a prospective study between January 2011 and December 2013. The number of studied subjects was 158 patients (158 ears) who underwent ear surgery at the Department of Otorhinolaryngology, Head and Neck Surgery, “Iuliu Hațieganu” University of Medicine and Pharmacy, Cluj-Napoca, Romania. All patients were informed regarding the participation to this study and their written informed consent had been obtained before the study was initiated. The study had the approval of the Ethics Committee of the “Iuliu Hațieganu” University of Medicine and Pharmacy, Cluj-Napoca and had been conducted according to the principles of the Helsinki Declaration. We first chose patients with cholesteatoma (COM), then selected cases who presented CSOM without cholesteatoma, the granulative form. In the cholesteatoma group, specimens were harvested from the site that contained both, epithelium and connective tissues that were in a matrix of the cholesteatoma. In the CSOM group, specimens consisted of granulation tissue from the middle ear. The cases with complications (facial canal dehiscence, lateral semicircular canal dehiscence, dura mater dehiscence) were considered aggressive cases.

IHC staining was conducted and the proportion of the cells staining positive for the Ki-67 nuclear antigen:

DIA-670-M-Anti-Ki-67/MIB-1 (Hu) from mouse (clone Ki-67P; unconj.-100 µL; 1:100–1:200 dilution histo-/cytochemistry; manufacturer/brand DIANOVA) was evaluated in a quantitative and visual way, using light microscopes. Ki-67 is strongly expressed in proliferating cells and has been reported as a prognostic marker in various tumors. Ki-67 protein plays an essential role in ribosomal RNA transcription and cell proliferation. Expression of Ki-67 occurs during G1, S, G2, and M phases, while in G0 phase, the Ki-67 protein is not detectable [12].

The specimen with KGF-positive cells was KGF positive case and the specimen without KGF-positive cells was KGF-negative case. The specimen with KGFR-positive cells was KGFR-positive case and the specimen without KGFR-positive cells was KGFR-negative case. Quantitative data were summarized using percentages and associated 95% CI (confidence interval). Quantitative variables were expressed as the mean \pm standard deviation (SD), range, and 95% CI, when data were normally distributed, and the median and quartiles, when data were not normally distributed. All analyses were performed with R statistical software packages ver. 3.2.1 (2015-06-18). The percentage of the specimens expressing KGF and KGFR was compared between the two groups for statistical significance, using the Pearson's *chi-square* test. A *p*-value less than 0.01 denoted the presence of a statistically significant difference.

☞ Results

Study subjects consisted of 105 patients (52 females and 53 males) with cholesteatoma and 53 patients (30 females and 23 males) with CSOM without cholesteatoma. The age of the patients ranged from 7 to 78 years (average: 38.44 years) and from 11 to 77 years (average: 40.02 years) in the cholesteatoma and CSOM without cholesteatoma groups, respectively. The final diagnosis was established by pathologist, based on the presence of keratinizing stratified squamous epithelium with four layers identical to the normal skin, Langerhans cells and keratin debris (cholesteatoma matrix). In the periphery, the connective tissue containing collagen fibers, fibrocytes and inflammatory cells (perimatrix) were present (Figures 1–3).

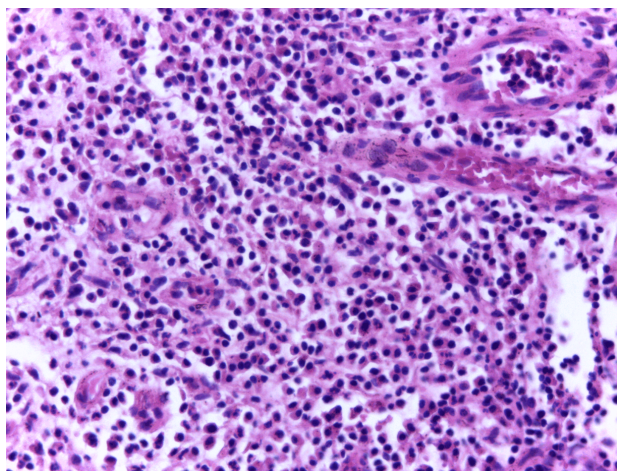


Figure 1 – Pathological specimen of acquired cholesteatoma: granulation tissue with inflammatory infiltrate of mixed type [Hematoxylin–Eosin (HE) staining, $\times 200$].

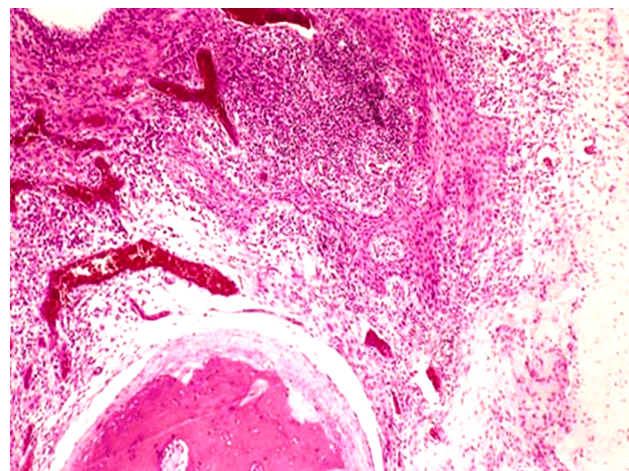


Figure 2 – Pathological specimen of acquired cholesteatoma: acquired cholesteatoma showing downgrowths from the deeper layer of cholesteatoma epithelium (HE staining, $\times 40$).

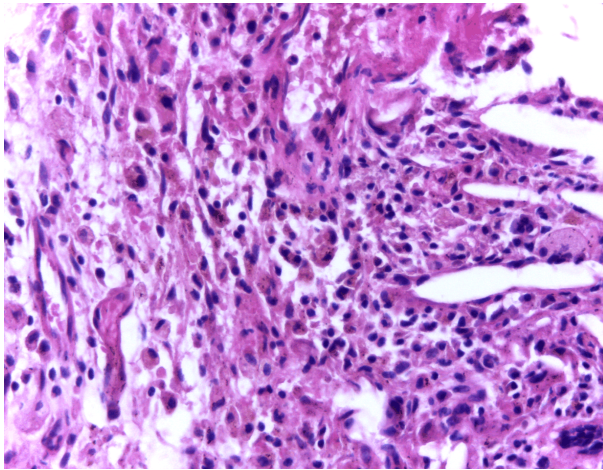


Figure 3 – Pathological specimen of acquired cholesteatoma: macrophages with hemosiderin, giant cells and cholesterol crystals (HE staining, ×200).

A comparison was made between groups in terms of KGF-positive specimens.

In the cholesteatoma group, 93 of 105 (88.57%) specimens were KGF-positive. In 22 out of 53 (41.51%) CSOM specimens, positive staining for KGF was detected in stromal cells (KGF-positive specimens), while KGF staining was not detected anywhere in any slice of the remaining 31 (58.49%) cases (KGF-negative specimens) (Figure 4).

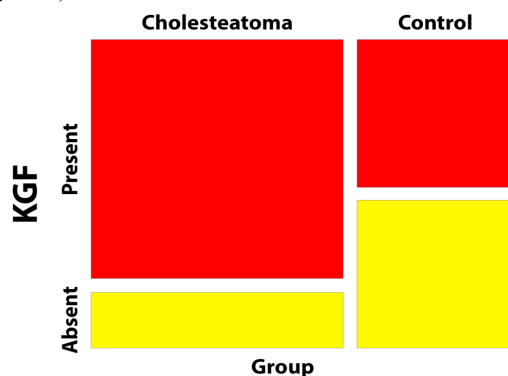


Figure 4 – KGF according to the group. KGF: Keratinocyte growth factor.

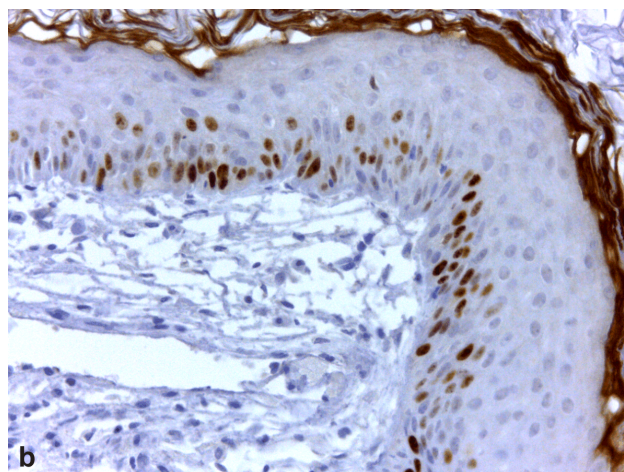
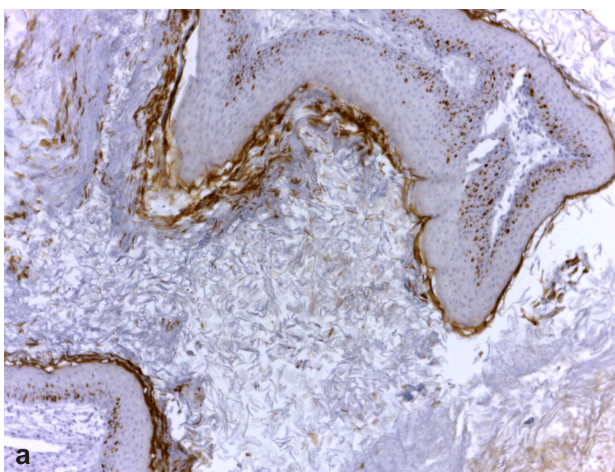


Figure 6 – (a and b) Pathological specimen of acquired cholesteatoma. Cholesteatoma epithelium shows the Ki-67 epithelial proliferation marker. Microscopic examination revealed a high Ki-67 proliferation index in the basal and parabasal layers of the squamous epithelium. At higher magnification, numerous mitoses could be identified. Anti-Ki-67 antibody immunostaining: (a) ×40; (b) ×200.

Chronic otitis media with cholesteatoma represents the cholesteatoma group and chronic otitis media without cholesteatoma is the control group. It was obvious that the percentage of KGF-positive specimens was significantly higher in the cholesteatoma group than in other cases (88.57%, $p < 0.001$, *chi-square* test).

Regarding the KGFR presence, this was detected in 64 out of 105 (60.95%) cases (KGFR-positive specimens) with cholesteatoma, and was predominantly found in consisting cells of the spinous layer and also in basal and granular cells in cholesteatoma epithelium (Figure 5).

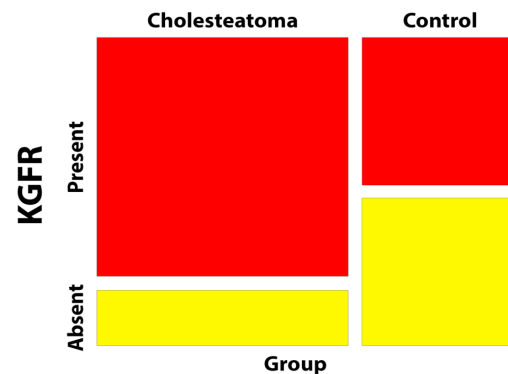


Figure 5 – KGFR according to the group. KGFR: Keratinocyte growth factor receptor.

KGFR was detected in a small number of epithelial cells in 18 of 53 (33.96%) specimens with CSOM (KGFR-positive case). The incidence of KGFR-positive specimens was lower in the CSOM group (control group) than in the cholesteatoma group (33.96% vs. 60.95%, $p < 0.001$, *chi-square* test).

In specimens with CSOM, some Ki-67-positive cells were found in the basal layer of the epithelium. In specimens from the cholesteatoma group, Ki-67-positive cells were found mainly in the suprabasal and upper layers of the epithelium (Figure 6, a and b), which almost corresponded to KGFR-positive layers (Table 1). The Ki-67 was significantly lower in the CSOM group than in the cholesteatoma group, but statistically insignificant ($p = 0.069$, *chi-square* test). Co-expression of stromal KGF and epithelial KGFR were observed in several cholesteatoma cases (54 specimens – 51.43%) (Table 2).

Table 1 – Ki-67 (%) according to the group

Ki-67 / Group	0–19: No. (%)	20–49: No. (%)	50–79: No. (%)	80–100: No. (%)	Total (%)
Cholesteatoma	10 (9.52)	31 (29.52)	31 (29.52)	33 (31.43)	105 (100)
Control	7 (13.21)	25 (47.17)	8 (15.09)	13 (24.53)	53 (100)

Table 2 – Co-expression KGF–KGFR according to the group

Co-expression KGF–KGFR / Group	Coexpression: No. (%)	One: No. (%)	None: No. (%)	Total (%)
Cholesteatoma	54 (51.43)	49 (46.67)	2 (1.9)	105 (100)
Control	13 (24.53)	14 (26.42)	26 (49.06)	53 (100)

KGF: Keratinocyte growth factor; KGFR: Keratinocyte growth factor receptor.

Co-expression of stromal KGF and epithelial KGFR was observed in fewer specimens of CSOM (13 specimens – 24.53%). The association between the group and co-expression of KGF and KGFR was tested and $p < 0.001$ was obtained (*chi-square* test). Further on, we suppose that the KGF–KGFR co-expression and the Ki-67 presence are higher in aggressive cases of cholesteatoma, that means in the cases presenting complications (facial canal dehiscence, lateral semicircular canal dehiscence, dura mater dehiscence).

The association between complications and KGF-positive specimens for cholesteatoma group was evaluated and $p = 0.003$ Fisher's exact test (Table 3) was reached.

Table 3 – Complications according to KGF for cholesteatoma group

KGF	Present (n=93)	Absent (n=12)	P-value
Facial canal dehiscence (yes), No. (%)	26 (27.96)	0 (0)	0.035
Semicircular canal dehiscence (yes), No. (%)	30 (32.26)	0 (0)	0.018
Dura mater dehiscence (yes), No. (%)	5 (5.38)	0 (0)	1
Complications (yes), No. (%)	41 (44.09)	0 (0)	0.003

KGF: Keratinocyte growth factor.

Discussion

Two main forms of the chronic otitis media are distinct: chronic suppurative otitis media with and without cholesteatoma. Usually, not only do these two classic types differ in their clinical course and prognosis, but they also require different therapeutic strategies [14]. Even though chronic otitis media without cholesteatoma is known as a benign disease with chronic irritating otorrhea, that can often be managed conservatively, in its granulative form the erosion of the bony labyrinth may occur [15]. Both forms of the chronic otitis media can be associated with granulation tissue and infection, with a number of interlinking mechanisms at the molecular level being responsive for bone resorption. In previous studies, both cholesteatoma and CSOM appeared to contain a predominant population of inflammatory cells including lymphocyte monocyte and plasma cells. KGF and KGFR

A result of attributable risk was attained – the risk that variable “complications” to be “yes” is 40.3% (95% CI 25.81–54.8) higher in the group KGF present vs. the group KGF absent. When tested, the association between complications and KGFR-positive specimens for cholesteatoma group $p < 0.001$ (*chi-square* test) was collected (Table 4). A result of attributable risk was gained – the risk that variable “complications” to be “yes” is 52.06% (95% CI 37.62–66.49) higher in the group KGFR present vs. the group KGFR absent. The association between complications and Ki-67-positive specimens in cholesteatoma group was analyzed and $p < 0.001$ (*chi-square* test) was confirmed (Table 5).

Table 4 – Complications according to KGFR for cholesteatoma group

KGFR	Present (n=64)	Absent (n=41)	P-value
Facial canal dehiscence (yes), No. (%)	23 (35.94)	3 (7.32)	<0.001
Semicircular canal dehiscence (yes), No. (%)	29 (45.31)	1 (2.44)	<0.001
Dura mater dehiscence (yes), No. (%)	5 (7.81)	0 (0)	0.154
Complications (yes), No. (%)	38 (59.38)	3 (7.32)	<0.001

KGFR: Keratinocyte growth factor receptor.

Table 5 – Complications according to Ki-67 (%) for cholesteatoma group

Ki-67 (%)	0–19 (n=10)	20–49 (n=31)	50–79 (n=31)	80–100 (n=33)	P-value
Facial canal dehiscence (yes), No. (%)	1 (10)	2 (6.45)	6 (19.35)	17 (51.52)	<0.001
Semicircular canal dehiscence (yes), No. (%)	0 (0)	3 (9.68)	9 (29.03)	18 (54.55)	<0.001
Dura mater dehiscence (yes), No. (%)	0 (0)	0 (0)	1 (3.23)	4 (12.12)	0.14
Complications (yes), No. (%)	1 (10)	6 (19.35)	13 (41.94)	21 (63.64)	<0.001

were detected also in CSOM [16, 17]. No clear difference was demonstrated between these entities. However, the intracranial complications are most frequently attributed to cholesteatoma.

Discerning the differential molecular pathology of proliferative middle ear lesions, our study revealed that higher expression of KGF and KGFR is responsible for higher aggressiveness and power of erosion in chronic otitis media with cholesteatoma vs. chronic otitis media without cholesteatoma. Therefore, in the present study, the percentage of KGF and KGFR positive specimens was significantly higher in the cholesteatoma group than in CSOM cases (88.57% / 41.51%; 88.57% / 60.95%). In cholesteatoma KGF was mainly localized in stromal cells whereas KGFR was in epithelial cells indicating their paracrine actions. These results confirm the hyper-proliferative capacity of the keratinocytes in cholesteatoma. A significantly higher expression of KGF mRNA

in cholesteatoma compared to normal skin was found in a study of Ishibashi *et al.* [18].

Other researcher reported the same results, but they only investigated the cholesteatoma tissue samples compared to the skin. In this present study, we chose to compare the expression and the population of KGF between cholesteatoma and the granulative form of COM because both lesions are associated with proliferative activity, bone erosion and extracranial and intracranial complications. To the best of our knowledge, this has not been studied yet.

As regard to the Ki-67-positive cells, these were significantly lower in the CSOM group than in the cholesteatoma group. Even though they exhibited an up-regulation that was not statistically significant ($p=0.069$, *chi-square* test), in specimens from the cholesteatoma group, Ki-67-positive cells were found mainly in the suprabasal and upper layers of the epithelium (which almost corresponded to KGFR-positive layers) and in specimens with CSOM, some Ki-67-positive cells were found in the basal layer of the epithelium, this indicates that the proliferative activity is lower in the CSOM group than in the cholesteatoma group.

In the study focused on KGF, Yamamoto-Fukuda *et al.* demonstrated that co-expression of KGF and KGFR seemed to induce the proliferation of epithelial cells in the primary cholesteatomatous COM, as well as in its recurrence [17]. They suggested the possibility that co-expression of KGF and KGFR plays an important role in the transitional stage from non-cholesteatomatous COM to cholesteatoma. Here, the co-expression KGF–KGFR appeared to be higher for cholesteatoma specimens compared CSOM specimens (51.43% vs. 24.53%; $p<0.001$, *chi-square* test). A statistically significant ($p=0.011$) relationship was found, between the presence of KGF expression in the subepithelial tissue and the presence of KGFR expression in the epithelium. Concerning the presence of complications our study revealed the association between the positive KGFR specimens and the presence of complications in cholesteatoma group ($p=0.003$).

The positive Ki-67 specimens presented with a higher aggressiveness compared to the negative Ki-67, bearing the question if the Ki-67 can really be a cause for greater power of osseous resorption. Using the logistic regression, we concluded that the cholesteatoma presence increases by 8.39 the chance of developing further complications, compared to the CSOM group. Using the same logistic regression, we have proved that the KGF–KGFR co-expression increases by 14.35 the chance of developing further complications, compared to those without the previous mentioned co-expression. Assessment of the proliferative activity of cholesteatoma using the labeling index for Ki-67 showed a significantly higher Ki-67 labeling index in KGF + KGFR cases than other cases. There was a significant correlation between KGF–KGFR co-expression and aggressiveness ($p<0.001$). This present study confirmed that the interactions between matrix keratinocytes and perimatrix inflammatory cells play an important role in the process of tissue proliferation within cholesteatoma. Differentiation, proliferation and migration of the matrix keratinocytes require paracrine and autocrine signaling.

Our results indicate the possible involvement of both KGF and KGFR in enhanced epithelial cell proliferative activity of cholesteatoma.

Conclusions

Our results indicate that the abnormal behavior of the cholesteatoma epithelium seems to be induced by the paracrine interaction between KGF and KGFR. Furthermore, we found that cholesteatoma expressing both KGF and KGFR had high Ki-67, which correlated with its aggressiveness. These findings suggest that excessive KGF and KGFR synthesis may contribute to the hyper-proliferative state in cholesteatoma and could explain the pathological difference between cholesteatoma and CSOM.

Conflict of interests

The authors declare that they have no conflict of interests.

References

- [1] Verhoeff M, van der Veen EL, Rovers MM, Sanders EA, Schilder AG. Chronic suppurative otitis media: a review. *Int J Pediatr Otorhinolaryngol*, 2006, 70(1):1–12.
- [2] Tall A, Ba MC, Essalki I, Diallo BK, Ndiaye M, Loum B, Ndiaye IC, Diouf R, Diop EM. [Cranioencephalic complications of middle ear cholesteatoma: report of 4 cases]. *Dakar Med*, 2006, 51(1):5–9.
- [3] Kuo CL. Etiopathogenesis of acquired cholesteatoma: prominent theories and recent advances in biomolecular research. *Laryngoscope*, 2015, 125(1):234–240.
- [4] Jackler RK, Santa Maria PL, Varsak YK, Nguyen A, Blevins NH. A new theory on the pathogenesis of acquired cholesteatoma: mucosal traction. *Laryngoscope*, 2015, 125(Suppl 4):S1–S14.
- [5] Alves AL, Pereira CS, Carvalho Mde F, Fregnani JH, Ribeiro FQ. EGFR expression in acquired middle ear cholesteatoma in children and adults. *Eur J Pediatr*, 2012, 171(2):307–310.
- [6] Kuo CL, Shiao AS, Yung M, Sakagami M, Sudhoff H, Wang CH, Hsu CH, Lien CF. Updates and knowledge gaps in cholesteatoma research. *Biomed Res Int*, 2015, 2015:854024.
- [7] Werner S, Peters KG, Longaker MT, Fuller-Pace F, Banda MJ, Williams LT. Large induction of keratinocyte growth factor expression in the dermis during wound healing. *Proc Natl Acad Sci U S A*, 1992, 89(15):6896–6900.
- [8] Staiano-Coico L, Krueger JG, Rubin JS, D'limi S, Vallat VP, Valentino L, Fahey T 3rd, Hawes A, Kingston G, Madden MR. Human keratinocyte growth factor effects in a porcine model of epidermal wound healing. *J Exp Med*, 1993, 178(3):865–878.
- [9] Maniu A, Harabagiu O, Perde Schrepler M, Cătană A, Fănuță B, Mogoantă CA. Molecular biology of cholesteatoma. *Rom J Morphol Embryol*, 2014, 55(1):7–13.
- [10] Gerdes J, Schwab U, Lemke H, Stein H. Production of a mouse monoclonal antibody reactive with a human nuclear antigen associated with cell proliferation. *Int J Cancer*, 1983, 31(1):13–20.
- [11] Brown DC, Gatter KC. Monoclonal antibody Ki-67: its use in histopathology. *Histopathology*, 1990, 17(6):489–503.
- [12] Scholzen T, Gerdes J. The Ki-67 protein: from the know and the unknown. *J Cell Physiol*, 2000, 182(3):311–322.
- [13] Sikka K, Sharma SC, Thakar A, Dattagupta S. Evaluation of epithelial proliferation in paediatric and adult cholesteatomas using the Ki-67 proliferation marker. *J Laryngol Otol*, 2012, 126(5):460–463.
- [14] Hüttenbrink KB. [Surgical treatment of chronic otitis media. I: Indications, preoperative care and surgical principles]. *HNO*, 1994, 42(9):582–593.
- [15] Smith JA, Danner CJ. Complications of chronic otitis media and cholesteatoma. *Otolaryngol Clin North Am*, 2006, 39(6):1237–1255.

- [16] Wight CG, Meyerhoff WL. Pathology of otitis media. *Ann Otol Rhinol Laryngol Suppl*, 1994, 163:24–26.
- [17] Yamamoto-Fukuda T, Aoki D, Hishikawa Y, Kobayashi T, Takahashi H, Koji T. Possible involvement of keratinocyte growth factor and its receptor in enhanced epithelial-cell proliferation and acquired recurrence of middle-ear cholesteatoma. *Lab Invest*, 2003, 83(1):123–136.
- [18] Ishibashi T, Shinogami M, Kaga K, Fukaya T. Keratinocyte growth factor and receptor mRNA expression in cholesteatoma of the middle ear. *Acta Otolaryngol*, 1997, 117(5):714–718.

Corresponding author

Carmen Aurelia Mogoantă, MD, PhD, Department of Otorhinolaryngology, University of Medicine and Pharmacy of Craiova, 2 Petru Rareș Street, 200349 Craiova, Dolj County, Romania; Phone +40728-020 623, e-mail: carmen_mogoanta@yahoo.com

Received: April 10, 2017

Accepted: February 12, 2018