ORIGINAL PAPER

RJME
Romanian Journal of Morphology & Embryology
http://www.rjme.ro/

Acupuncture causes serotonin release by mast cells

NIKOLAY DIMITROV[1)], DIMITRINKA ATANASOVA[1–3)], NIKOLA TOMOV[1)], DIMITAR SIVREV[1)], NIKOLAI LAZAROV[2,4)]

[1)]*Department of Anatomy, Faculty of Medicine, Trakia University, Stara Zagora, Bulgaria*

[2)]*Institute of Neurobiology, Bulgarian Academy of Sciences, Sofia, Bulgaria*

[3)]*Department of Genes and Behavior, Max Planck Institute of Biophysical Chemistry, Göttingen, Germany*

[4)]*Department of Anatomy and Histology, Medical University of Sofia, Sofia, Bulgaria*

Abstract

Mast cells (MCs) are important object in experimental acupuncture due to their putative involvement in local reactions to needling. In the rat, they are shown to contain in their granules, among other tissue mediators, serotonin, also called 5-hydroxytryptamine (5-HT). The aim of this study is to examine the normal distribution of 5-HT-containing MCs in soft tissues of Zusanli (ST_{36}) acupuncture point (acupoint) and their morphological changes caused by experimental acupuncture. We observed 5-HT-immunopositive MCs in the tissues and in the vicinity of the needle tract formed after acupuncture. As a result of acupuncture needling, the tissue integrity is disrupted and certain folds are formed in the direction of the needle tract. Connective tissue in the vicinity of the needle tract gets compressed and displaced, together with the 5-HT-immunoreactive MCs seen there. Some of those 5-HT-immunopositive MCs showed signs of degranulation with numerous discharged granules, some of them found at a considerable distance form the cell. Furthermore, 5-HT-immunopositive MCs are unevenly distributed in soft tissues of ST_{36} acupoint. Larger numbers of 5-HT-containing MCs were visualized in subcutis and dermis, compared to the observed in striated muscles. Placing the acupuncture needle into the rat skin caused a formation of an apparent needle tract, tissue displacement and degranulation of 5-HT-immunopositive MCs. The demonstrated serotonin release by means of MC degranulation might be involved in the local tissue response to acupuncture.

Keywords: ST_{36}, mast cells, rat, 5-HT, needle tract, acupoint.

Introduction

Mast cells (MCs) are associated mainly with their involvement in innate immunity and the mechanisms of defense against parasite infections, immunomodulation of the immune system and tissue repair [1]. MCs are derived from hematopoietic stem cells and distributed throughout tissues, particularly near surfaces exposed to the environment [2]. MCs have a crucial role in innate and adaptive immunity, including immune tolerance [3]. Studies have shown that the MCs, which are located beneath the basal layer of the epidermis in the normal skin in rats, are involved in wound healing of the skin [4]. Their tight involvement with the skin makes them an important subject for research in acupuncture points and acupuncture meridian lines [5–9]. MCs are important object in experimental acupuncture in rats [5, 9–12]. They are found to be involved in reactions not only to classical acupuncture using a steel needle, but also in laser acupuncture [13]. Serotonin, also known as 5-hydroxytryptamine (5-HT), is one of the most extensively examined neurotransmitters in the central nervous system, and also present in a variety of peripheral tissues in constituents of the immune system. Functions of 5-HT include T-cell and natural killer (NK)-cell activation, delayed-type hypersensitivity responses, production of chemotactic factors, and natural immunity delivered by macrophages [14]. 5-HT has been demonstrated in the granules of rat MCs [15–17]. Its expression in the tissues of acupuncture points (acupoints) is generally limited to 5-HT-positive MCs [18]. In acupoints, they are predominantly located in the dermis, which is comprised of an integrated system of fibrous and amorphous connective tissue that accommodates MCs, among nerve and vascular networks, epidermal derived appendages, fibroblasts, and macrophages [19]. In our previous research, we determined the normal histology of Zusanli (ST_{36}) acupoint, *i.e.*, the epidermis, dermis, subcutis, fascia, epimysium, muscle, blood vessels and nerves. We found clusters of MCs in certain areas of the dermis, subcutis, fascia and striated muscle [20].

Materials and Methods

The aim of this study is to examine the normal distribution of 5-HT-immunopositive MCs in soft tissues of ST_{36} acupoint and their morphological changes caused by experimental acupuncture in rats. The method we developed enables the investigator to demonstrate the tissues in a circumstance, maximally close to the condition during the needling process, without additional staining and/or processing. The moment of intervention remains "frozen in time" [21]. Changes in epithelium, blood vessels, nerves, elastic and collagen fibers, fascia, and muscle can be followed. Furthermore, it allows the visualization of degranulated 5-HT-containing MCs in the vicinity of the needle tract. The experiments were carried out on 10 adult male Wistar rats weighing between

220 and 350 g, which were subjected to acupuncture needling with a standard metallic acupuncture needle. The reference group consisted of adult male Wistar rats (n=10; 220–350 g body weight), which were not treated (intact). The experimental design was approved by the Research Ethics Committee at the Faculty of Medicine, Trakia University, Bulgaria. All efforts were made to minimize the number of animals used and their suffering.

For the present study, we used ST_{36} acupuncture point (acupoint) due to its widespread use in Traditional Chinese Medicine (TCM). The acupuncture point could be detected with the method of standard proportion of anatomical structures [22] under the control of the apparatus KWD-808 measuring skin resistance [23]. ST_{36} acupoint is also commonly used in experimental acupuncture in rats [12, 20]. In rats, ST_{36} is located between the tibia and fibula, laterally to the distal end of the cranial tuberosity of the tibia, lateral to the anterior tubercle of the tibia, in the tibialis anterior muscle. It is 5 mm below the head of the fibula under the knee joint, and 2 mm lateral to the anterior tubercle of the tibia [24]. The area around the acupoint was epilated, defined and marked. For the histological preparations, the rats were anaesthetized with ether to the point at which respiration was suppressed, and perfused first with 0.05 M phosphate-buffered saline (PBS) followed by 4% paraformaldehyde (PFA) in 0.1 M PBS, pH 7.36. Material from ST_{36} acupoint with 5×5×5 mm size was taken and postfixed in the same fixative, overnight, at 4^0C. Samples were embedded in paraffin and sectioned on a conventional paraffin microtome at 5 μm-thick sections. For the histological observation of changes caused by experimental acupuncture and visualization of acupuncture needles tract, the rats were anaesthetized with ether and the acupuncture needle was placed in the tissues of the acupoint. We used steel acupuncture needles with 0.25× 13 mm size. Acupuncture needles were inserted 5 mm deep into ST_{36} acupoint. The acupuncture needle was not retained for a long time in the tissues of the ether-narcotized rats and the perfusion followed almost immediately. A tissue sample with 5×5×5 mm size was excised together with the acupuncture needle.

In this method, the acupuncture needle was a constant companion of the tissue sample during further processing. It was removed just before sectioning of the paraffin-embedded tissue. This did not allow for tissue retraction following removal of the needle. In this way, the needle tract remained clearly visible as it penetrated trough the tissues. In this fashion, we were able to determine the influence of the needle on the tissues surrounding the needle tract. Introducing a needle prior to tissue processing also allowed the precise localization not only of the needle impact, but also of the acupoint used. We used light microscopic immunohistochemistry with antibodies against serotonin for the demonstration of 5-HT-containing MCs. We also applied antibodies against tryptase, a general immunohistochemically marker for MCs, present in their granules. For the immunohistochemical reactions, 5 μm-thick paraffin sections were dewaxed in two changes of xylene and were rehydrated in ethanol. Afterwards, sections were washed in 0.1 M PBS, pH 7.4, incubated in 1.2% hydrogen peroxide in absolute methanol for 30 minutes, followed by antigen retrieval in 10 mM citrate buffer (pH 9) for up to 10 minutes in pressure cooker. Between the separate steps, the sections were rinsed with cold PBS/Triton X-100. Subsequently, they were incubated in a humid chamber, overnight, at 4^0C, with the primary antibody and monoclonal mouse anti-human serotonin (clone 5HT-H209, DAKO, Denmark) and monoclonal mast cell tryptase (clone 10D11, Leica Biosystems, Newcastle, UK) in 1:100 dilution. Following washing three times with PBS, the slides were incubated with DAKO-REAL™ En-Vision™ detection system (DAKO) for 60 minutes, then visualized with 3,3'-diaminobenzidine (DAB) and counterstained with Mayer's Hematoxylin. PBS replacing the primary antibody was used as a negative control.

Bismarck brown staining is a reliable method for demonstration of skin MCs, as demonstrated by previous studies [25]. Therefore, we used it interchangeably with Toluidine blue to demonstrate MCs, as previously described [26]. In particular, initially we stained consecutive serial sections with Toluidine blue, followed by immunostaining for tryptase and 5-HT, respectively. The second approach involved a histochemical demonstration of MCs on immunolabeled slides. For this purpose, after coverslipping, the slides with 5-HT-immunostained MCs were photographed. The coverslips were thereafter removed by immersing the slides in xylene, the sections were rehydrated and stained with 0.5% aqueous solution of Toluidine blue (pH 3) for 3 minutes. Following brief rinsing and dehydration, the slides were cleared and coverslipped once again for repeated observation.

The slides were viewed using a light microscope (Eclipse 80i, Nikon, Japan), and photographed with a digital camera (Nikon DMX 1200). We quantitatively evaluated the distribution of 5-HT-positive MCs in the dermis, subcutis and striated muscle.

Statistical analysis was performed using SigmaStat® 11.0 software package (Systat Software Inc.). Experimental data were evaluated using one-way analysis of variance (ANOVA) with Tukey–Kramer's *post-hoc* test. Differences were considered statistically significant if p-values were <0.05.

Results

We observed 5-HT-immunopositive MCs in the soft tissues of ST_{36} acupoint. They were either individually positioned or, more commonly, arranged in small clusters. We were able to demonstrate the uneven distribution of 5-HT-immunoreactive MCs in soft tissues ST_{36} acupoint. In our study, we did not ascertain the presence of 5-HT-immunopositive MCs in the epidermis. Larger numbers of 5-HT-immunopositive MCs were visualized in subcutis [28±1.155, mean ± standard error of the mean (SEM)] and dermis (13.25±1.065), compared to striated muscles (1.333± 0.667). There were statistically significant differences in the distribution of MCs in dermis, subcutis and striated muscles [one-way ANOVA ($F_{1, 13}$ = 79.611, $p<0.001$)]

(Figure 1A). The 5-HT-immunopositive MCs were more numerous in the papillary layer (8.7±1.219), than in the reticular layer (4.55±0.667) of the dermis (Figure 1B). We established statistical significant differences in the distribution of 5-HT-immunopositive MCs in the papillary layer when compared to the reticular layer by using Student's *t*-test ($p<0.05$). More 5-HT-reactive MCs were visualized in the border zones epidermis–dermis, dermis–subcutis, subcutis–fascia and epimysium (Figure 2, B and E). Small numbers of scattered 5-HT-positive MCs are present in the dermis, more in dermo-epidermal junction and in the subcutis fat, close to the fascia and blood vessels. In the dermis, 5-HT-immunopositive MCs were located mainly around blood vessels and close to the hair follicles. In the subcutis, 5-HT-immunoreactive MCs are in the vicinity of the fascia, blood vessels and lipocytes. We found larger number of 5-HT-immunopositive MCs in the vicinity of fascia (Figure 2, B and E). Some of the observed 5-HT-immunopositive MCs in the dermis and subcutis showed signs of degranulation (Figure 2E). Furthermore, we found 5-HT-immunoreactive MCs in the vicinity of the epimysium that surrounds the striated muscles. We observed smaller numbers of 5-HT-immunopositive MCs more deeply in the striated muscles (Figure 1A). Some 5-HT-immunopositive MCs were also seen in the connective tissue of striated muscle in the vicinity of blood vessels, a few of the immunostained cells forming clusters close to the blood vessels and in the vicinity of muscle spindles (Figure 3, A–C).

In order to demonstrate that the visualized 5-HT-positive cells are indeed MCs, we used serial sections which were processed for Toluidine blue staining (Figure 2, C and F), immunohistochemistry for tryptase (Figure 3B), and immunolabeled sections with visualized 5-HT-positive MCs stained with Toluidine blue (Figure 2, A and D). Furthermore, the MCs were demonstrated on some control sections using Bismarck brown staining.

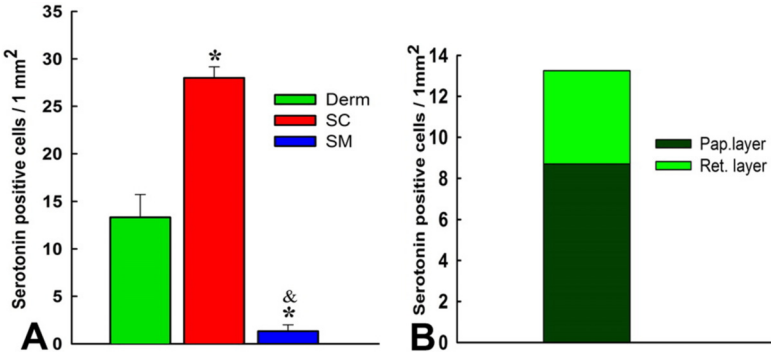

Figure 1 – ***(A) Graphical representation of distribution of 5-HT-immunopositive MCs in the tissues of ST_{36} acupoint in rats. 5-HT-containing MCs are distributed in the dermis (Derm), subcutis (SC) and striated muscle (SM). Analysis of the data by one-way analysis of variance (ANOVA) shows the differences in the distribution of 5-HT-immunopositive MCs among the groups [$F_{1, 13} = 79.611$, $p<0.001$]. The data represent the average of the distribution of 5-HT-immunopositive MCs in an area of 1 mm^2 + standard error of the mean (SEM). (*$p<0.05$ vs. Derm; $^{\&}p<0.05$ vs. SC). (B) Stacked column chart represents the estimated proportion of distribution of 5-HT-positive MCs in papillary (Pap.) and reticular (Ret.) layers of the dermis in the tissues of ST_{36} acupoint in rats.***

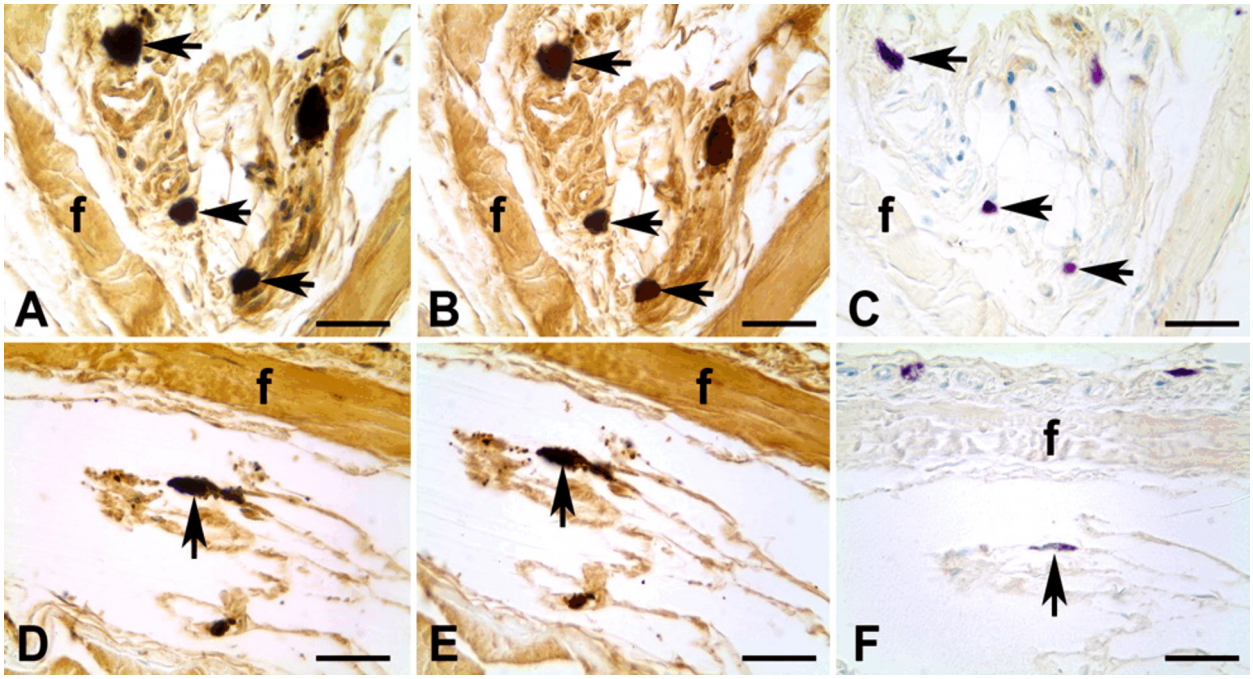

Figure 2 – ***(A–F) MCs from the area of acupuncture point ST_{36} in rats: (A and D) 5-HT-immunolabeled slides showing MCs double-stained with Toluidine blue in the connective tissue of subcutis close to fascia (f); (B and E) Localization of 5-HT-immunopositive MCs (arrows) in the connective tissue of subcutis close to fascia (f); (C and F) Toluidine blue-stained MCs (arrows) close to fascia (f). Scale bars: 20 µm.***

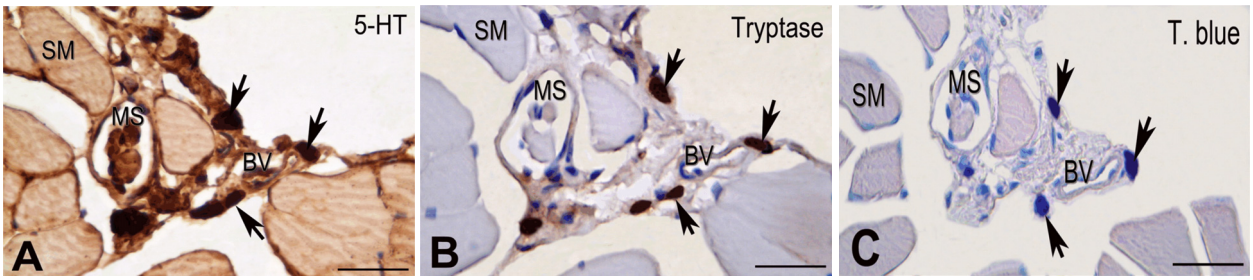

Figure 3 – *(A–C) MCs from the area of ST_{36} acupuncture point in rats: (A) 5-HT-positive MCs (arrow) in the connective tissue of striated muscle (SM) in the vicinity of blood vessels (BV) and muscle spindles (MS); (B) Tryptase-positive MCs (arrow) in the connective tissue of striated muscle (SM) in the vicinity of blood vessels (BV) and muscle spindles (MS); (C) Toluidine blue-stained MCs (arrow) in the connective tissue of striated muscle (SM) in the vicinity of blood vessels (BV) and muscle spindles (MS). Scale bars: 50 µm.*

Following acupuncture, a needle tract is formed in the tissues, affected by the needle. We observed 5-HT-immunopositive MCs in the vicinity of this tract (Figure 4, A–D). Some peculiarities of their appearance and distribution could be attributed to the effect of the needle. As a result of acupuncture needling, the integrity of tissues is disrupted and folds were formed in the direction of the needle. We observed compression and displacement of the connective tissue in the vicinity of the needle tract, together with the 5-HT-positive MCs contained in it (Figure 4, C and D; Figure 5, B and D). As a result, the 5-HT-immunoreactive MCs migrated passively from the more superficial towards the deeper layers of the skin and skeletal muscle. The integrity of the epithelium was disrupted and it folds in the direction of the needle tract (Figure 4A). The integrity of derma, subcutis, deep fascia, epimysium and striated muscle was disrupted by the acupuncture needle (Figure 4, A–D). We observed the uneven distribution 5-HT-positive MCs in soft tissue in the vicinity of the needle tract. Larger numbers of 5-HT-immunopositive MCs were visualized in subcutis and dermis in the vicinity of the needle tract, compared to striated muscles. Some of those 5-HT-immunopositive MCs showed signs of degranulation with released granules found a considerable distance form the cell (Figure 5, B, D and F). The immunolabeled slides with 5-HT-immunopositive mast cells stained with Toluidine blue undisputedly confirmed the mastocytic nature of the 5-HT immunoreactivity observed (Figure 5, A, C and E). A few of those 5-HT-positive MCs were mechanically destroyed by the acupuncture needle. They were found inside the needle tract, with their granules discharged (Figure 6, A–C). A number of 5-HT-containing granules were seen along the needle tract itself, but some of them were also scattered in the disrupted tissue around (Figure 5, B, D and F; Figure 6B). We consider them to be released by the destroyed MCs and dispersed by the moving needle.

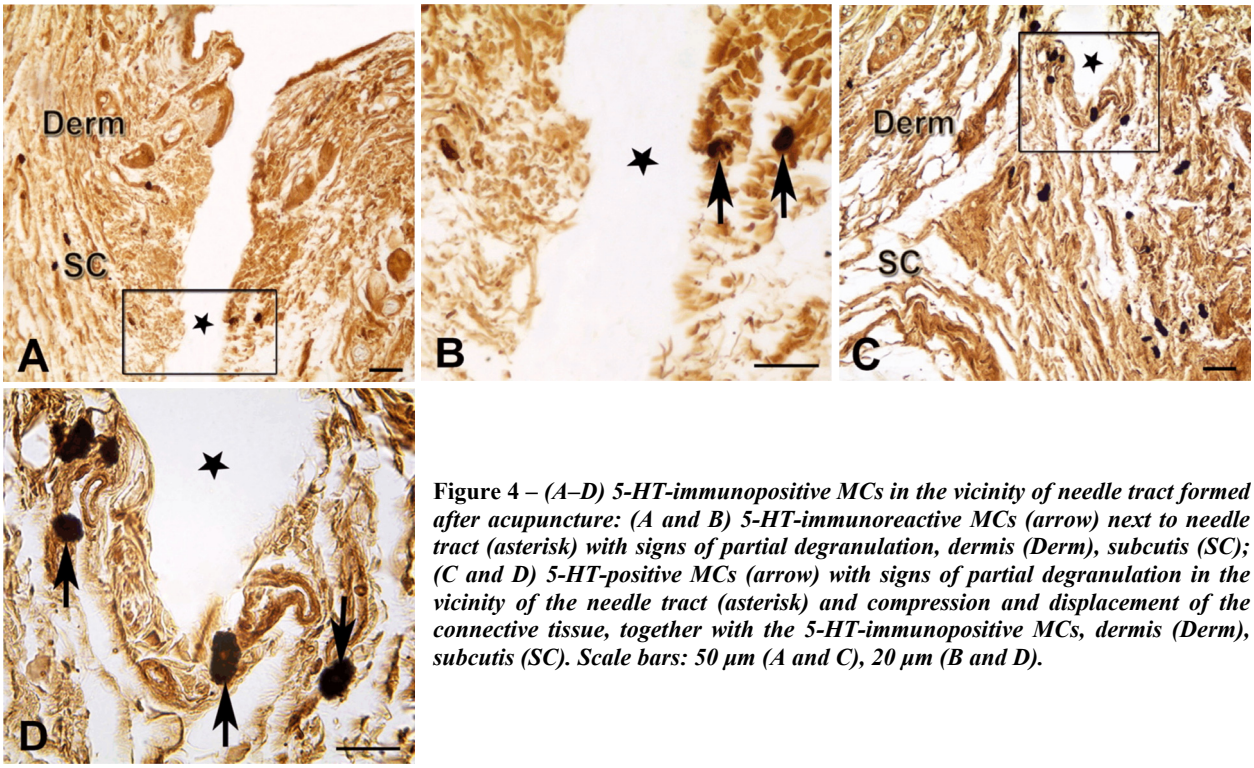

Figure 4 – *(A–D) 5-HT-immunopositive MCs in the vicinity of needle tract formed after acupuncture: (A and B) 5-HT-immunoreactive MCs (arrow) next to needle tract (asterisk) with signs of partial degranulation, dermis (Derm), subcutis (SC); (C and D) 5-HT-positive MCs (arrow) with signs of partial degranulation in the vicinity of the needle tract (asterisk) and compression and displacement of the connective tissue, together with the 5-HT-immunopositive MCs, dermis (Derm), subcutis (SC). Scale bars: 50 µm (A and C), 20 µm (B and D).*

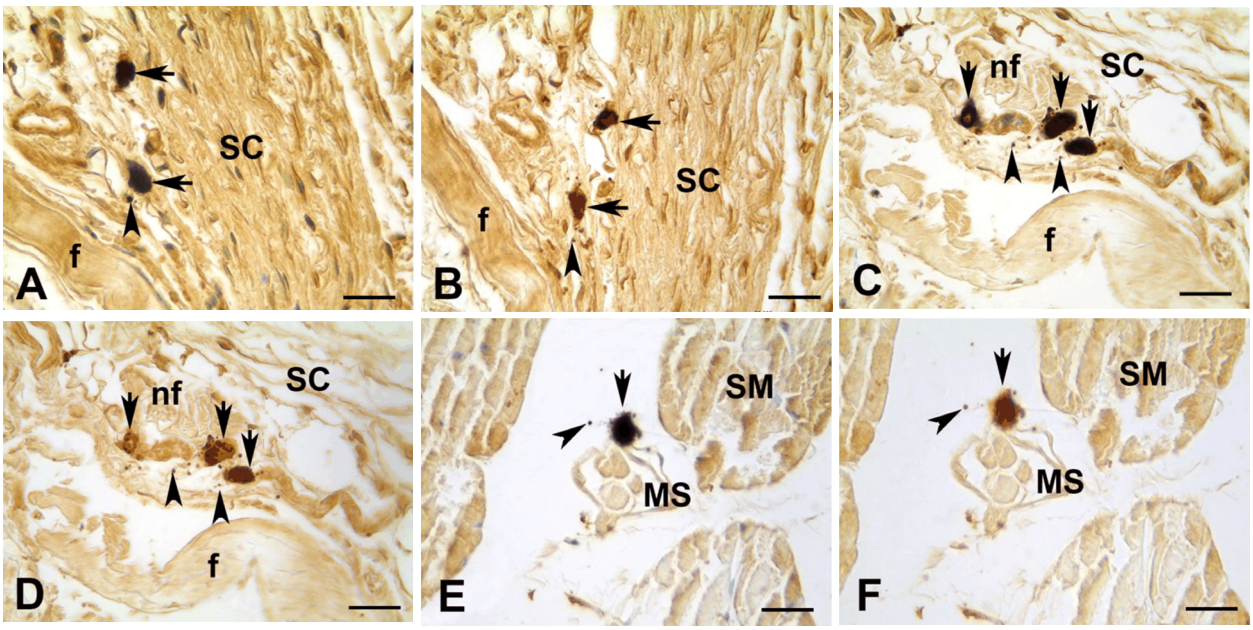

Figure 5 – ***(A, C and E) 5-HT-immunoreactive MCs (arrows) stained with Toluidine blue with signs of degranulation and discharged granules (arrowhead) found at a considerable distance from the cell in the vicinity of the needle tract, fascia (f), subcutis (SC), striated muscle (SM), muscle spindles (MS). (B, D and F) 5-HT-immunoreactive MCs (arrow) with signs of degranulation and discharged granules (arrowhead) found at a considerable distance from the cell in the vicinity of the needle tract, fascia (f), subcutis (SC), striated muscle (SM), muscle spindles (MS). Scale bars: 20 µm.***

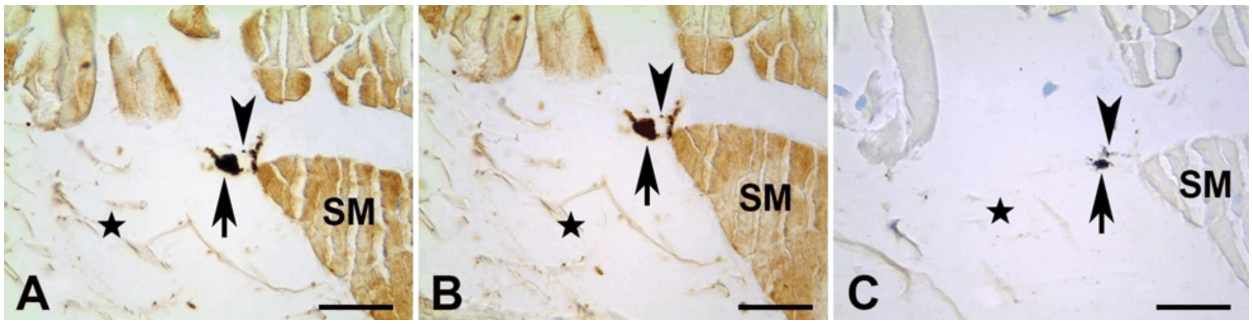

Figure 6 – ***(A) 5-HT-immunopositive MCs (arrows) stained with Toluidine blue, mechanically destroyed by the acupuncture needle with discharged granules (arrowhead) in the needle tract (asterisk) between striated muscle (SM); (B) 5-HT-immunopositive MCs (arrow) mechanically destroyed by the acupuncture needle with discharged granules (arrowhead) in the needle tract (asterisk) between striated muscle (SM); (C) Toluidine blue-stained MCs (arrow) mechanically destroyed by the acupuncture needle with discharged granules (arrowhead) in the needle tract (asterisk) between striated muscle (SM). Scale bars: 20 µm.***

Discussion

5-HT is a well-known mediator, which has its effects both as a neurotransmitter, as well as a local agent. The release of such an active chemical compound in the peripheral tissues triggers a number of cascades and leads to multiple reactions [14]. It is established, that MCs degranulation is one of the mechanisms of the normal reaction to acupuncture needling [9]. Since 5-HT is contained in the mastocytic granules [15–17], based on our data we can assume that its release following acupuncture is an important mechanism of the tissue reactivity to acupuncture.

We cannot exclude that, at least partially, the 5-HT-immunoreactivity close to the needle tract is of thrombocytic origin, due to its significant presence in their granules. However, our experimental setting involving placing the needles immediately before perfusion and obtaining the tissue specimen without removing the needle makes extravasation of blood cells in the needle tract highly unlikely. Moreover, no large blood vessels are affected by the needle, and the smaller ones, which may be damaged by it, are compressed by the needle shaft and are not prone to leaking. Therefore, we may conclude that the content of thrombocytic 5-HT is negligible compared to that of mastocytic origin. The combined method of MCs demonstration with immunohistochemistry for 5-HT and Toluidine blue staining unequivocally proves that the observed large cells in immediate vicinity of the needle tract are indeed mast cells. The observed serotonin-containing granules are most likely of mastocytic origin, either from degranulated MCs, or from mechanically destroyed ones. This was additionally demonstrated on serial sections processed for tryptase and 5-HT immunohistochemistry. According to our experimental data, Toluidine blue histochemistry is comparable with tryptase immunohistochemistry for the demonstration of MCs in the skin [27]. Therefore, we consider the present results

employing 5-HT immunohistochemistry with additional confirmation by Toluidine blue histochemistry to be of a comparable value.

In this study, we tried to demonstrate changes in the tissues and tissue mast cells caused by the acupuncture needle. This is a one-time event, with a quite short duration. We suggest that the mechanical impact of the needle causes degranulation and/or mechanical disintegration of mast cells. The 5-HT-immunoreactive granules found some distance from the mast cells, in the needle tract, are of mastocytic origin, but were displaced by the needle either together with the tissues, or simply along the needle shaft in the needle tract. This displacement of tissues could be the reason behind the differences of MCs numbers in the needled animals, compared with the reference group, as shown on Figures (Figure 4, C and D; Figure 5, A–D).

It should be noted, however, that degranulation of MCs is not triggered solely by the acupuncture needle, but also by multiple biochemical factors. Moreover, the presence of partially degranulated MCs is a normal finding in the tissues of the reference group animals, which were not needled. However, our observation of destroyed MCs in the needle tract, together with the displacement of their serotonin-containing granules, proves the notion that acupuncture directly releases the contents of mastocytic granules. We consider the finding that serotonin-containing granules are displaced along the needle tract to be of great significance considering the effect of acupuncture.

Additionally, in the present study we observed an uneven distribution of 5-HT-immunopositive MCs in the tissues of ST_{36} acupuncture point. Studies concerning the subcutaneous connective tissue (fascia) in albino rats and humans reported that a greater number of MCs was more concentrated in the acupoints and/or meridian lines in comparison with their control areas and these differences are statistically significant [5, 6]. Authors also suggest the presence of longitudinal chemotactic migration of MCs along the course of the acupuncture meridians [28]. Our data cannot confirm such findings. Some researchers suggested that the density of MCs in the area of ST_{36} acupuncture point rats is higher than that of the nearest sham points [6–9]. In our study, we were unable to demonstrate morphological differences in the number and distribution of MCs between the centre of ST_{36} acupoint and neighboring tissues, and therefore we conclude that no significant differences in the distribution of MCs between the acupoint area and the non-acupoint areas exist [29]. We also confirm the presence of a large amount of MCs concentrated in the connective tissue around blood vessels.

Our previous results show the presence of a thicker layer of loose connective tissue in some areas of the skin, indentations and differences in the thickness of the epidermis and folding of the deep fascia. Clusters of large blood vessels were located in the depth of the underlying striated muscle tissue [20]. There is a possibility that dislocation and folding of tissues can contribute to the received results. Clusters of MCs were found in certain areas of the dermis, subcutis, fascia and striated muscle. We have detected degranulation of many MCs after acupuncture in ST_{36} acupoint [21]. Degranulation of MCs was also observed in the absence of needling, but only in a minor fraction of cells. Results of other researches revealed that the number of the MCs in human skin was maximal immediately below the dermo-epidermal junction, and the base of the dermis [30]. They were found in greatest numbers in the vicinity of blood vessels and around hair follicles [31]. Indeed, there is convincing evidence that the MCs lay under the basal layer (germinative layer) of the epidermis in normal skin in rats [4]. This is in concordance with our results in rats in which we observed more 5-HT-positive MCs underneath the basal layer (germinative layer). In our previous research, we found MCs in the zones, located in the border dermis and subcutis, close to the hair follicles, fascia and the perimysium and close to nerve endings and blood vessels [20]. In the present research, we observed more 5-HT-positive MCs in the same zones, located on the border between dermis and subcutis, fascia, and the epimysium that surrounds the striated muscles. Regarding the normal histology structures in ST_{36} acupoint: epidermis, dermis, subcutis, fascia, epimysium, muscles, the results were confirmatory to our previous data [20].

Normally, 5-HT in the skin of the rat is expressed by MCs [15–17, 32]. Previous research has revealed expression of 5-HT by MCs and their granules in the acupoint area in rats skin using double immunohistochemical staining of tryptase together with 5-HT. The available data indicated that local cutaneous nerve terminals and MCs responded to manual acupuncture with higher expression of substance P (SP) and calcitonin gene-related peptide (CGRP) in nerve fibers, as well as with aggregation and degranulation of MCs with histamine and 5-HT granules at acupoint in rat [18]. Immunohistochemically, almost all of the skin connective tissue MCs (CTMCs) in rats showed serotonin immunoreactivity [33]. Therefore, we could conclude, that the observed 5-HT-positive cells were, indeed, MCs. Moreover, due to the almost ubiquitous expression of 5-HT by rat MCs we consider the observed 5-HT-positive MCs to be a representative population for all MCs in the acupoint. We, therefore, consider that 5-HT is a reliable marker for skin MCs in rats.

MCs are found at varying levels of association with the nervous system in close apposition to peripheral nerve endings in a variety of tissues [34]. We were also able to visualize MCs in the vicinity of nerve fibers and muscle spindles. Some researchers speculate about the existence of a neuromastocytic junction, which is considered to be involved in acupuncture effects [35]. In this stage, we cannot confirm such a junction due to the lack of clear morphological evidence for it. Another discussed mechanism of acupuncture effects is the reaction of the connective tissue in the vicinity of the needle tract [36, 37]. We also demonstrated thickening and displacement of the connective tissue following acupuncture. Other investigators have also observed the needle tract in the tissue of acupoints. In its vicinity, they observed nerve fibers, small vessels and muscle spindles [38]. They, however, did not demonstrate directly degranulation of MCs along the needle tract, despite this notion is widely supported [28, 39, 40]. The present findings show for the first time that mediators are released and scattered in

tissues as a result of acupuncture. The functional implications of this phenomenon are yet to be elucidated.

Our previous research in rats reveals that acupuncture causes degranulation of MCs [21, 41]. Ultrastructural analysis of ST_{36} area following acupuncture also demonstrates the same phenomenon [41]. Even though the influence of acupuncture on degranulation of MCs is considered by some to be unremarkable [29], our morphological data points that we cannot dismiss it. In our research, we observed 5-HT-positive MCs in the vicinity of the needle tract showing clear marks of degranulation. Moreover, we also observed destruction of 5-HT-positive MCs and serotonin liberation in form of scattered mastocytic granules. The direct liberation of mastocytic granules, caused by mechanical disruption of the cellular integrity, rather by degranulaton, has not been discussed previously.

A relationship between MCs degranulation and some acupuncture effects, such as acupuncture analgesia, has been proposed. Electroacupuncture and manual stimulation of the acupuncture needle (known methods for eliciting a more intense therapeutic response) in ST_{36} acupoint can increase the degranulation ratio of MCs in the stimulated ST_{36} area, and consecutively, the magnitude of the therapeutic effect [42]. Since the notion that acupuncture leads to degranulation of MCs is widely supported [43, 44], we consider MC degranulation to be an important mechanism involved in the normal reaction to acupuncture. Furthermore, our data suggests, that MC granules can be released directly due to destruction of MCs by the acupuncture needle. The wide palette of mediators released thereafter can elicit local effects *via* multiple mechanisms. The present study provides clear morphological evidence for the release of one mediator following acupuncture. The *in vivo* effects of the release of this and other mediators are yet to be explained.

Conclusions

In the present study, we establish by an original method that placing the acupuncture needle into the rat skin caused a formation of an observable needle tract, tissue displacement, and degranulation of 5-HT-positive MCs. The serotonin release by means of MCs degranulation is highly likely to be involved in the local tissue response to acupuncture. Additionally, we establish the uneven distribution 5-HT-positive MCs in soft tissues of ST_{36} acupoint.

Conflict of interests

The authors have no conflict of interests to declare.

References

[1] Metcalfe DD, Baram D, Mekori YA. Mast cells. Physiol Rev, 1997, 77(4):1033–1079.

[2] Galli SJ, Borregaard N, Wynn TA. Phenotypic and functional plasticity of cells of innate immunity: macrophages, mast cells and neutrophils. Nat Immunol, 2011, 12(11):1035–1044.

[3] da Silva EZ, Jamur MC, Oliver C. Mast cell function: a new vision of an old cell. J Histochem Cytochem, 2014, 62(10): 698–738.

[4] Miller L, Whitting HW. Mast cells and wound healing of the skin in the rat. Z Zellforsch Mikrosk Anat, 1965, 65(4):597–606.

[5] Wu J, Chai X, Cai D, Zong A. Observation on mast cells in subcutaneous connective tissue at points in albino rats. Acta Anat Sinica, 1980, 11(3):308–312.

[6] Zhu Z, Xu R. [Morphometric observation on the mast cells under the acupuncture meridian lines]. Zhen Ci Yan Jiu (Acupunct Res), 1990, 15(2):157–158.

[7] Zhong AM, Wu JL, Hu YL, Feng Y, Deng XG. Study on correlation between the mast cell and the acupoint. World J Acupunct Mox, 1994, 4(4):53–58.

[8] Zhang D, Ding GH, Shen XY, Yao W, Lin J. Study on the correlation between meridian acupoints and mast cells. Acupunct Res, 2005, 30(2):115–118.

[9] Zhang D, Ding G, Shen X, Yao W, Zhang Z, Zhang Y, Lin J, Gu Q. Role of mast cells in acupuncture effect: a pilot study. Explore (NY), 2008, 4(3):170–177.

[10] Shi Y, Qi L, Wang J, Xu MS, Zhang D, Wu LY, Wu HG. Moxibustion activates mast cell degranulation at the ST_{25} in rats with colitis. World J Gastroenterol, 2011, 17(32):3733–3738.

[11] Ming C, Cai S, Cai Y, Ma T. Observation of MC in the deep aponeurosis under the fluorescent microscope by electric needling in "Zusanli". Zhen Ci Yan Jiu (Acupunct Res), 2000, 25(1):51–53.

[12] Zhang D, Ding GH, Shen XY, Yao W, Zhang ZY, Zhang YQ, Lin JY. [Influence of mast cell function on the analgesic effect of acupuncture of "Zusanli" (ST_{36}) in rats]. Zhen Ci Yan Jiu (Acupunct Res), 2007, 32(3):147–152.

[13] Cheng K, Shen XY, Ding GH, Wu F. [Relationship between laser acupuncture analgesia and the function of mast cells]. Zhongguo Zhen Jiu (Chin Acupunct Mox), 2009, 29(6):478–483.

[14] Mössner R, Lesch KP. Role of serotonin in the immune system and in neuroimmune interactions. Brain Behav Immun, 1998, 12(4):249–271.

[15] Crabb ED. Serotonin as a mast cell product. University of Colorado Studies – Series in Biology: Ecology & Evolutionary Biology, 1958, 13(1):36–158.

[16] Benditt EP, Wong RL, Arase M, Roeper E. 5-Hydroxytryptamine in mast cells. Proc Soc Exp Biol Med, 1955, 90(1): 303–304.

[17] Dvorak AM. Basophil and mast cell degranulation and recovery. Vol. 4 – Series "Blood Cell Biochemistry" (Series Editor: Harris JR), Plenum Press, New York, 1991, 1–415.

[18] Wu ML, Xu DS, Bai WZ, Cui JJ, Shu HM, He W, Wang XY, Shi H, Su YS, Hu L, Zhu B, Jing XH. Local cutaneous nerve terminal and mast cell responses to manual acupuncture in acupoint LI4 area of the rats. J Chem Neuroanat, 2015, 68: 14–21.

[19] Zaki SM. Characteristics of the skin of the female albino rats in different ages: histological, morphometric and electron microscopic study. J Cytol Histol, 2015, 3(4):1–11.

[20] Dimitrov ND. Normal morphology of biologically active point /BAP/ ST_{36} rat. Acta Morphol Anthropol, 2012, 19:34–37.

[21] Dimitrov ND. Morphological changes in biologically active point /BAP/ ST_{36} after acupuncture in rat. Acta Morphol Anthropol, 2012, 19(1):30–33.

[22] Morley K. How to locate acupuncture points. In: White A, Cummings M, Filshie J (eds). An introduction to Western medical acupuncture. 1st edition, Churchill Livingstone–Elsevier, Edinburgh, 2008, 185–189.

[23] Dimitrov ND, Sivrev DP, Pirovski NL, Georgieva AI. Methods for localization of BAP of the human body. XIXth Congress of Bulgarian Society of Anatomists with International Participation, May 29–31, Pleven, Bulgaria, 2009, J Biomed Clin Res, 2009, 2(1 Suppl 1):19–21.

[24] Lee CH, Kim DK, Yook TH, Sasaki M, Kitamura N. Effectiveness of electroacupuncture at Zusanli (ST_{36}) on the immunohistochemical density of enteroendocrine cells related to gastrointestinal function. J Acupunct Meridian Stud, 2012, 5(2):63–71.

[25] Spatz M. Bismarck brown as a selective stain for mast cells. Tech Bull Regist Med Technol, 1960, 30:141–143.

[26] Dimitrov N, Sivrev D, Atanasova D. Histological structure of the human biologically active point (BAP) ST_{36}. Trakia J Sci, 2015, 13(Suppl 2):67–69.

[27] Atiakshin D, Samoilova V, Buchwalow I, Boecker W, Tiemann M. Characterization of mast cell populations using different methods for their identification. Histochem Cell Biol, 2017, 147(6):683–694.

[28] Yang YM, Wang PP. [Morphological observation on the effect of acupuncture on mast cells at the Zusanli point]. Zhen Ci Yan Jiu (Acupunct Res), 1986, 11(4):298–302.
[29] Zong A, Shi X, Zhang F. [Effects of electro-acupuncture on fascia mast cells in "Zusanli" acupoint area of rabbits]. J Zhengzhou Univ (Sci Med), 1992, 27(3):226–229.
[30] Cowen T, Trigg P, Eady RA. Distribution of mast cells in human dermis: development of a mapping technique. Br J Dermatol, 1979, 100(6):635–640.
[31] Mikhail GR, Miller-Milinska A. Mast cell population in human skin. J Invest Dermatol, 1964, 43:249–254.
[32] Schwartz LB, Austen KF. Enzymes of the mast cell granule. J Invest Dermatol, 1980, 74(5):349–353.
[33] Feng Y, Wu J. [Histochemical and immunohistochemical observations on heterogeneity in mast cells of rat]. Acta Anat Sinica, 1989, 1(1):90–94.
[34] Johnson D, Krenger W. Interactions of mast cells with the nervous system – recent advances. Neurochem Res, 1992, 17(9):939–951.
[35] Chen LW, Zhang BZ. [Discovery of the neuromastocytic junction on the modelled meridian line in mouse skin – a study by light and electron microscopical immunohistochemistry]. Shenjing Jiepouxue Zazhi (Chinese J Neuroanat), 1987, 3(2): 253–258.
[36] Langevin HM, Churchill DL, Cipolla MJ. Mechanical signaling through connective tissue: a mechanism for the therapeutic effect of acupuncture. FASEB J, 2001, 15(12):2275–2282.
[37] Langevin HM, Bouffard NA, Churchill DL, Badger GJ. Connective tissue fibroblast response to acupuncture: dose-dependent effect of bidirectional needle rotation. J Altern Complement Med, 2007, 13(3):355–360.
[38] Kim M, Nam T, Kim M, Kim J, Kim D, Lee K, Song C. Histological observation of canine acupoints. J Vet Clin, 2006, 23(2):102–104.
[39] Deng Y, Fu Z, Dong H, Wu Q, Guan X. [Effects of electro-acupuncture on the subcutaneous mast cells of Zusanli acupoint in rat with unilateral sciatic nerve transaction]. Zhen Ci Yan Jiu (Acupunct Res), 1996, 21(3):46–49.
[40] Luo MF, He JN, Guo Y, Li CH, Zhang JL. [Effect of electro-acupuncture and moxibustion of "Dazhui" (GV_{14}) on the number and distribution of degranulated mast cells in GV_{14} region]. Zhen Ci Yan Jiu (Acupunct Res), 2007, 32(5):327–329.
[41] Dimitrov N, Atanasova D, Tomov N, Ivanova I, Staykova Y, Dinkova K, Ganeva I, Sivrev D. Distribution of histamine-positive mast cells in the vicinity of the needle tract following acupuncture in "Zusanli" (ST_{36}) acupoint in rats. Acta Morphol Anthropol, 2016, 23:26–31.
[42] Lin J, Huang H, Ding GH, Zhang D. [Relationship between the function of mast cells and acupuncture analgesia in adjuvant arthritis rats]. Zhen Ci Yan Jiu (Acupunct Res), 2007, 32(1):16–19.
[43] Gao S, Ming CR, Wu YW. [The effect of electro-acupuncture on the ultrastructure of mast cells in acupoints]. Liaoning J Tradit Chin Med, 1981, 5:40–42.
[44] Shen DK. [A study on the morphological structure for inducing needling sensations in acupoint]. Zhonghua Zhongyiyao Zazhi (China J Trad Chin Med Pharm), 1989, 4:57–64.

Corresponding author
Dimitrinka Atanasova-Dimitrova, Senior Scientist, PhD
Laboratory of Functional Neuroanatomy, Department of Synaptic Signaling and Communication, Institute of Neurobiology, Bulgarian Academy of Sciences, Acad. G. Bonchev Street, Block 23, 1113 Sofia, Bulgaria; E-mail: didiatan@bio.bas.bg
Department of Anatomy, Faculty of Medicine, Trakia University, Armeyska 11, 6000 Stara Zagora, Bulgaria; E-mail: didi.atanasova@mf.uni-sz.bg
Department of Genes and Behavior, Max Planck Institute of Biophysical Chemistry, Am Fassberg 11, 37077 Göttingen, Germany; E-mail: datanasova@mpibpc.mpg.de

Received: April 3, 2017

Accepted: December 12, 2017