

Morphological changes in support mechanism of superficial face layers in Moebius syndrome

MARIUS VALERIU HÎNGANU, CRISTINEL IONEL STAN, TRAIAN ȚĂRANU, DELIA HÎNGANU

Department of Anatomy and Embryology, "Grigore T. Popa" University of Medicine and Pharmacy, Iași, Romania

Abstract

Moebius syndrome, also called congenital facial paralysis is a rare neurological disease, whose etiology is not fully elucidated. It affects especially facial and oculomotor cranial nerves and its clinical feature is peripheral facial paralysis. The objective of the study is to highlight the anatomical and functional changes in the Moebius syndrome and establish certain criteria that should be the basis for reparative surgery in this disease. For this purpose, we used a group of six patients diagnosed with this pathology, in whom we pursued functional anatomical and histological changes of the superficial layers of the face that we have grouped in terms of their clinical impact. All the data obtained were centralized in order to assess anatomical functional changes occurring after evolution in time of lesions caused by Moebius syndrome. The results of the study led us to conclude that the face is made up of three main regions – median, medial and lateral –, which behave differently both in atresia of the facial nerve and in healthy individuals. This has an important echo on the way we emphasized the functional anatomy of superficial layers of the face and in surgery.

Keywords: superficial musculo-aponeurotic system, Moebius syndrome, facial regions, cranial nerves.

Introduction

Moebius syndrome, also called congenital facial paralysis, congenital ocular-facial paralysis or nuclear aplasia is a rare neurological disorder, whose cause is not yet elucidated. It affects especially facial and oculomotor cranial nerves and its clinical feature is peripheral facial paralysis [1].

Clinically, it is highlighted from birth, most often by: (a) face lack of expressions, impossibility of making facial mimics and the various types of speech disorders; (b) paralysis of the oculomotor nerve, eyelid ptosis, strabismus; (c) if it affects the glossopharyngeal nerve, it may give disturbance in swallowing and chewing, tongue muscle atrophy.

These symptoms may occur by themselves or in various combinations, according to the nerves that are affected, the age and the associated pathology [2–4].

The treatment is symptomatic and its aim is to improve the patient's quality of life. Thus, it can be applied logopedic treatment, physiotherapy, home care services. Surgical cure has specific indications and can provide a part of face mobility, on different levels [5–7].

Facial paralysis is a major health problem, a devastating one, not allowing patients to communicate and express their emotions and feelings properly, by adversely affecting the patient's quality of life [8].

The aim of the study is to highlight the anatomical and functional changes in the Moebius syndrome and clinical changes that occur in the face statics and dynamics. We also tried to establish some criteria that should be the basis for reparative surgery in this disease. We centralized all the data to develop a map encompassing anatomic and functional changes occurring after evolution over time of lesions caused by this pathology.

Patients, Materials and Methods

The study was conducted on a total of six patients with Moebius syndrome lesions that presented or were admitted in "St. Mary" Emergency Hospital for Children, Iași, Romania.

The information was obtained from observation charts of each patient and intraoperatively (for patients who have had such treatment recommendation), where tissue specimens were taken. Based on these, we analyzed changes that occur in these cases, from the clinical, anatomical and histological point of view. We pursued, on the studied cases, changes in functional anatomy, of superficial layers of the face, which we grouped in terms of clinical manifestations, correlated with individual pathophysiological substrate.

The clinical observation and palpation was done through specific maneuvers, which highlighted contraction and action of each individual muscle groups and by blocking others. In the cases where surgical intervention was performed, we collected tissue fragments that have been assessed qualitatively by common staining techniques.

Results

The clinical examination and functional exploration of the first patient showed the following aspects related to atresia/paralysis of the facial nerve: asymmetric facies, lagophthalmos, impossibility of closing the eyes and mouth, decreased lacrimation, loss of taste. Besides these aspects, the patient experienced symptoms related to damage of other cranial nerves, such as: abducens nerve – unable lateral gaze, convergent strabismus, photophobia, myopic astigmatism; hypoglossal nerve – difficulty in chewing, preferring soft food, tongue protrusion, difficulty

in swallowing. Cranial nerve injuries are associated with other congenital malformations: microcephaly, tear duct changes, hypoplasia of the wing nose, hooked nose, short filter.

In another patient, we observed clinical signs given by facial nerve damage, with craniofacial dysmorphism, slits eyelid upward and laterally. The lesions of oculomotor nerve determined the appearance of convergent strabismus, disorders in eyeballs motility, with the absence of abduction and convergence of eye, obliquity of palpebral fissure, divergent deviation. All of these were correlated with congenital atrophy of the optic nerve (blindness), impossibility of closing the mouth, micrognathism, posterior rotated ears, triangular facies, psychomotor retardation.

The third patient also presented facial dysmorphism with myopathic facies, ptosis of the eyelid, like major symptomatology given by the damage of the facial nerve but also by injuries associated with lesions of other cranial nerves – paresis of oculomotor nerve, and bilateral paralysis of the abducens nerve with strabismus and bilateral palpebral ptosis; hypoglossal nerve injuries – swallowing disorders. All these were associated with circular facies, hypertelorism, mongoloid eyelid slits, facial hypoplasia, broad bridge of the nose, low-set ears, pectus excavatum, prominent nose base, ears dysplasia, weak voice, intellectual disability, cognitive and psychomotor delay.

Another patient had clinical signs of facial nerve injury at face level: facial dysmorphism, inexpressive facies, narrow slits eyelid, associated with small nose, small mouth, lowered commissures, micrognathism, ears dysplasia, which were small and round, discrete right hemiparesis and moderate delay in psychomotor development.

The fifth patient had the following changes of the face: inexpressive facies, short eyelid slots – given by bilateral facial nerve injury. He had specific clinical signs given by oculomotor nerve damage: limited movements of the eyeballs associated with prominent upper lip, evident micrognathism.

The last patient had the following symptoms: bilateral facial paresis (inexpressive facies), cranial nerve paresis (eye mobility problems) associated with small, asymmetrical tongue, significantly disorders in phonation, dental malposition. Neurologically, this patient had medium/severe delay in mental development and in language development against the background of brain organization (intelligence quotient – IQ = 35–40).

After the study on these patients, we found that clinical symptoms were directly correlated with the level of cranial nerve injuries. Unilateral lesion of the facial nerve causes facial dysmorphism by ptosis of the superficial tissues on the same side and by flattening wrinkles expression. In cases where the damage occurs bilaterally, patient's face is like an inert mask. In both cases, the evolution in time of symptoms leads to dysfunction of the facial muscles, especially the muscles of the jaw, controlled by the trigeminal nerve.

We found that the most exposed areas of the face to present dysmorphism are the central ones: oral, nasal, orbital. On the lateral regions of the face, where superficial fascial has insertions on the bone, there occur two forces that act on these attachments: those caused by facial

muscle contraction (engaged in a whole as SMAS – superficial musculo-aponeurotic system) and by masticatory muscles. Clinical signs of the damage in this lateral region appear in time after a mean duration of five years from the occurrence of central facial dysmorphism.

The affecting of infraorbital, zygomatic and jugal regions is a consequence of the appearance of laxity in fixation structures of SMAS, combined with changing of force vectors acting in these regions, by the installation of central facial dysmorphism and “fatigue of masticatory muscle”. The main defect that occurs in this medial region is quantitative loss of adipose tissue (the reduction of Bichat's fat pad).

Moebius syndrome affects both sequentiality and as a clinical manifestation of these three regions. Initially, malfunctions occur in the medial regions, especially in those with occlusive functional characters. The next step is the damage of transition medial regions and it is due in particular by secondary functional lesions of the medial regions. Finally, clinical changes in the lateral, fixing regions are late, due to sufferings manifested for long time.

The pathophysiological mechanism of production of these clinical manifestations is quite similar to the phenomenon of “aging face” and consists in loss of the quality of various mechanisms of anti-gravity fixation of superficial cervical and facial structures. These phenomena have resulted in facial soft tissue ptosis that affects further functionality of other facial regions. The emergence of these clinical manifestations determines resorting to surgical treatment, the only able to recover mechanical and anti-gravitational support of the structures of the SMAS, by cutting original, incompetent means of fixing (rejuvenation) and transfer the temporal muscle function to the mimic muscles (orbicularis oris).

Common stainings revealed the muscle fibers atrophy correlated with the appearance of excess fibrous connective tissue, especially in the medial, relational region of the face (Figure 1). At the level of lateral regions of the face (Figure 2), there can be noticed the laxity of fixing elements by the proximity periosteum through the collagen fibers elongation.

In the medial passage region (Figure 3), the changes appear probably late. It is the last region of the face that suffered degenerative changes following the loss of tone and contractility of the mimic muscles. Nasolabial groove, in particular, remains last redoubt; at its level, we have not detected any significant changes of morphology in the advanced stages of the disease in the patients studied.

Discussion

The facial dermis is fixed to the bones through a fibrous support, which contains ligaments and superficial fascia but, at the same time, they allow the movements and facial gestures involved. This attachment must resist also at external forces such as gravity and traction.

The ligaments, which fix the superficial fascia to the skeleton, can divide face into several distinct regions. Three of them are in the mental and infrazygomatic regions: chin, lateral side of the chin.

Besides these, we can include the regions of lower eyelids, upper eyelids, infratemporal and frontal.

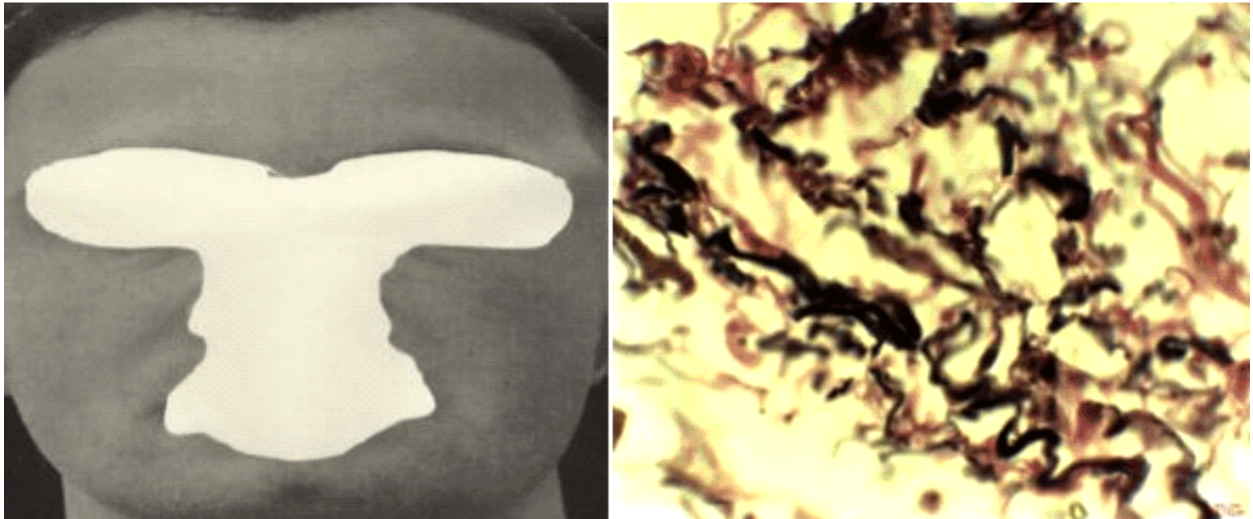


Figure 1 – Medial region of the face; numerous elastic and collagen fibers, medium size and muscular fibers underrepresented in the structure of SMAS from the jugal region. Verhoeff staining, $\times 600$.

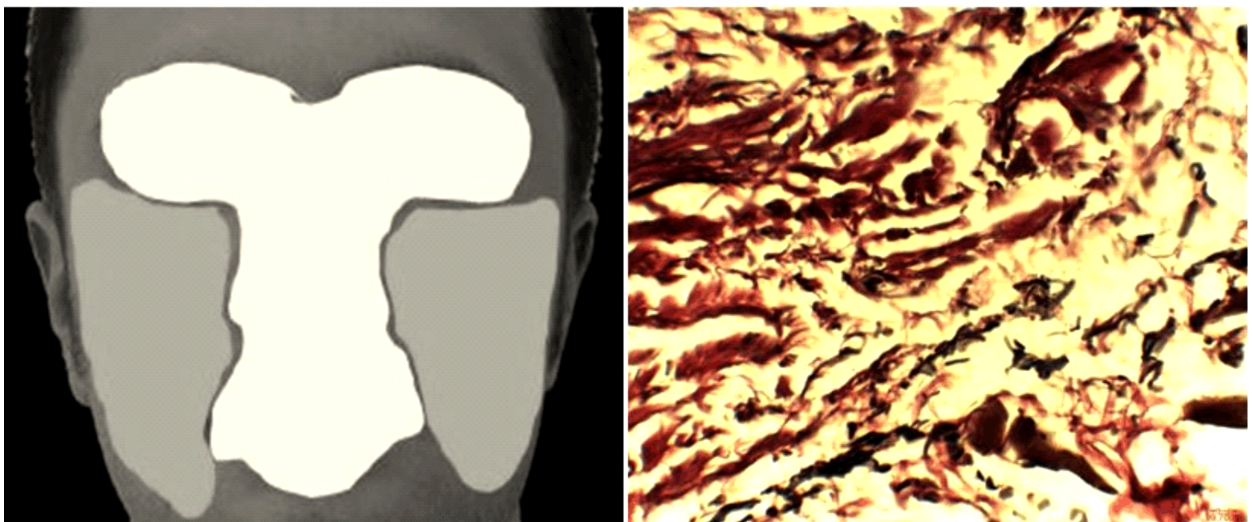


Figure 2 – Medial regions of the face; collagen and elastic fibers from SMAS in lateral part of nasolabial groove. Verhoeff staining, $\times 400$.

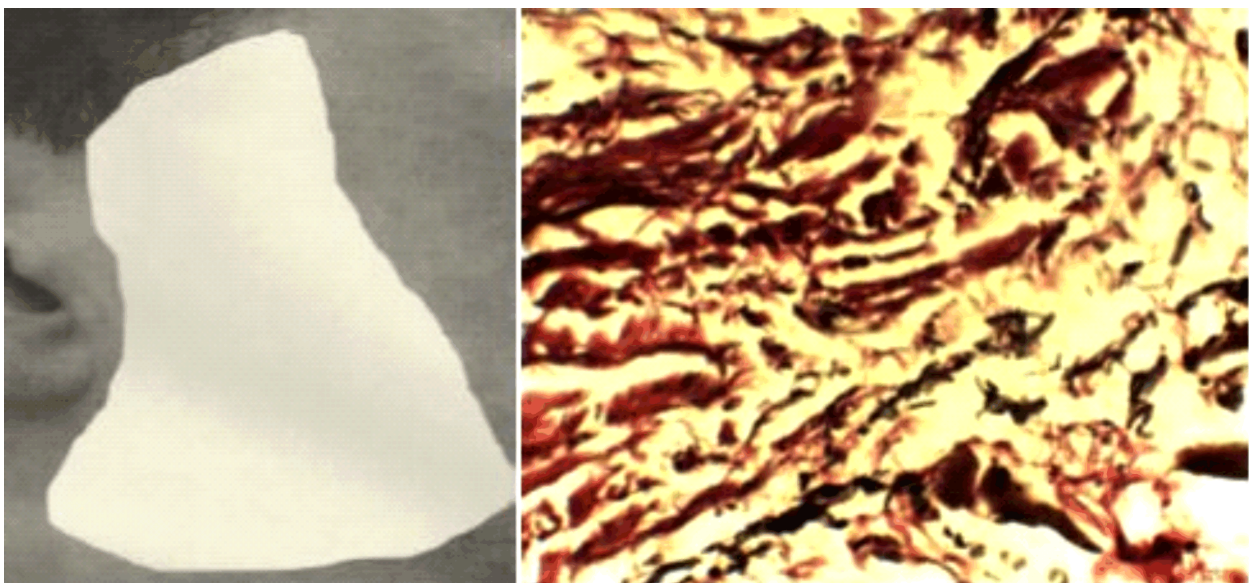


Figure 3 – Lateral region of the face; periorbital SMAS, with dense collagen fibers, medium and abnormally long, arranged longitudinally. Van Gieson staining, $\times 600$.

In these regions, the ligaments between posterior aspect of superficial fascia and facial skeleton “put in quarantine movements caused by muscle contraction, at least in young people so that will not transmit the movements of superficial fascia to neighboring regions” [9].

Outside the classical division of face in three zones – superior, middle and inferior – one can be added based on aesthetic, anatomical and functional considerations. Anatomical pattern of ligamentous attachment of the superficial fascia to the facial skeleton defines the limits that divide face in several regions. Three of these are parts of what is seen on the outside such as: the cheek, lateral cheek, pre- and infrazygomatic sides medial cheek, in addition to the other regions: lower eyelid, forehead and upper eyelid. Congenital atresia of the facial nerve has a different impact on these parts of the face, both in terms of morphology and of the time of appearance of clinical signs. In severe cases of bilateral congenital atresia, the clinically echo of it is more severe and earlier.

The weakening of connecting tissue through muscular shortening and stretching determines the displacement on different direction depending on the configuration of each muscle, separately.

There are multiple vectors of movement in facial aging because each muscles of facial expression has its own connection direction of the lax tissue, and the correction of each vector displacement requires a proper fixing vector. The presence of Moebius syndrome associated pathologies speeds up appearance of connection tissue degeneration, leading to more early clinical manifestations [10]. Fortunately, the use of SMAS concept provides increased opportunities for controlling the direction of lifting. In this direction, we can say that the face is made up of three distinct functional morphological regions: median, medial, lateral-posterior.

Medial region of the face includes superficial and deep layers around the face openings. Its shape is a butterfly with raised wings. The main feature of this region is the fixity of superficial structures to the deep ones. This is caused by powerful, flared muscular insertions on the deep part of the dermis. It can be said that it is the visceral segment of the face. Most muscles play the role of sphincter of the openings that surround them and the others are basically their functional extensions. The medial part of the face is predominant in individualizing the facies and hence, the relational life of each individual. Therefore, we call it the “relational” part of the face, and we can divide it into four subregions: orbital, nasal and oral. Although muscles are different at each of them, there are some common considerations, in terms of stratigraphy, quantity and quality: (a) the skin gradually thins as we move towards the mediosagittal area; (b) the same behavior highlights at subcutaneous adipose tissue, except that the layer beneath the superficial fascia is almost nonexistent; (c) superficial and deep fascia lose their elasticity, being made up of dense connective tissue.

In some situations, both fascia are reflected with one another and even adheres to the periosteum region. This happens periorbitally (ligamental adhesion where it is impossible to perform a deep dissection) at the lower edge of nasal cartilage and at the midline union of the two nasal wings [11].

The medial region (intermediate) of the face is a pair region, mainly characterized by a high degree of mobility of the superficial tissue compared to deep layers. It is bounded superiorly by the zygomatic arch [12] and inferiorly by mandible arch. Laterally, it spreads to the parotid gland capsule and medially to a line, which joins the angle of the mouth with lateral edge of nasogenian groove.

The exacerbated mobility of these regions, compared to the other two, is due to the fact that it contains two fat pads (malar and jugal), of a considerable size. There is a strong adhesion, made by connective fibers [13] of the superficial fascia of these fat pads to the deep layer of the dermis. In depth, they are “anchored” only by the cutaneous insertions of zygomatic muscles.

This region is also one of “passage”, SMAS [14] realizing connective tunnels through which branches of the facial nerve, Stenon’s duct and branches from facial vessels cross it from the lateral part to the medial part or vice versa. Duplication of SMAS with the formation of tunnels for nerves and vessels is done through a transversely oriented connective tissue [15], while the superficial layer, whose origin is orientated from superior to inferior, in the direction of the traction vectors of zygomatic and infraorbital insertions.

Another important role of these regions is to inter-connect the medial with the lateral region of the face [16], providing an additional support to actions that occur at this level. Thus, it actively intervenes in the facial expressions, far-reaching, such as making a wide smile. This stands out when this region is developing an inflammatory or tumoral process, which disrupts its functionality. In this case, it can cause active facial dysmorphism (in an attempt to express facial gestures) or passive dysmorphism through retraction of tissue and loss of anti gravity support.

The role of the most powerful masticatory muscles (temporal, masseter, buccinator) is amplified, through a leverage mechanism, by the connections of their insertion regions with the perioral one [17]. Mimics in this area can occur only on its boundary where the muscles of facial expression take insertion.

Posterior lateral region of the face is a pair region, fixing the face to exoskeleton. Herein lie strong ligaments and ligamentary adhesions that, on the one hand anchors the soft tissues of the face and, on the other hand delimit it by the neighboring regions: frontal, temporal, lateral-cervical and cervical.

Being particularly visible from profile, this region intervenes indirectly in creating facial expressions [18, 19]. At this level, in deep plan masticatory muscle inserts on mandibular ramus. The region extends superiorly to the zygomatic arch, practically covering the infratemporal fossa. Laterally and posteriorly, it is added the parotid region and the deep fascial layer is made by parotidian masseteric fascia.

✦ Conclusions

The clinical and morphological changes that occur Moebius syndrome are strongly correlated with a particular structure located on the face and called SMAS. In the central regions of the face, the sphincter role of mimic

muscles has a significantly decrease in Moebius syndrome. The fixity of fat pad from medial regions, through fibrous extensions that sends it to this level is determined by the SMAS. This provides the contour of the cheek, SMAS having an active role in raising the soft tissues of the cheek, feature which alleviates a pace much higher in Moebius syndrome. The anterior capsule of the parotid gland is formed by SMAS. From this level, it is continued posteriorly and laterally with the fascia of sternocleidomastoid muscle and anteriorly and medially with fibrous tunnels for facial nerve branches. At the supraorbital level, there are strong adhesions between the ligaments of superciliary arches and the dermal insertions of the superior fascicle of orbicularis oculi muscle, which are becoming increasingly lax. Continuities of this fascia with the surrounding fascia – frontal, cervical, temporal – are due to determining pathological changes associated with Moebius syndrome.

Conflict of interests

The authors declare that they have no conflict of interests.

References

- [1] Kumar D. Moebius syndrome. *J Med Genet*, 1990, 27(2): 122–126.
- [2] Carta A, Mora P, Neri A, Favilla S, Sadun AA. Ophthalmologic and systemic features in Möbius syndrome: an Italian case series. *Ophthalmology*, 2011, 118(8):1518–1523.
- [3] Magnifico M, Cassi D, Kasa I, Di Blasio M, Di Blasio A, Gandolfini M. Pre- and postsurgical orthodontics in patients with Moebius syndrome. *Case Rep Dent*, 2017, 2017: 1484065.
- [4] Kuhn MJ, Clark HB, Morales A, Shekar PC. Group III Möbius syndrome: CT and MR findings. *AJNR Am J Neuroradiol*, 1990, 11(5):903–904.
- [5] Terzis JK, Anesti K. Developmental facial paralysis: a review. *J Plast Reconstr Aesthet Surg*, 2011, 64(10):1318–1333.
- [6] Terzis JK, Noah EM. Möbius and Möbius-like patients: etiology, diagnosis, and treatment options. *Clin Plast Surg*, 2002, 29(4):497–514.
- [7] Di Blasio A, Cassi D, Di Blasio C, Gandolfini M. Temporomandibular joint dysfunction in Moebius syndrome. *Eur J Paediatr Dent*, 2014, 14(4):295–298.
- [8] Mendelson BC. SMAS fixation to the facial skeleton: rationale and results. *Plast Reconstr Surg*, 1997, 100(7):1834–1842.
- [9] Costea CF, Anghel K, Dimitriu G, Dumitrescu GF, Faiyad Z, Dumitrescu AM, Sava A. Anatomoclinical aspects of conjunctival malignant metastatic melanoma. *Rom J Morphol Embryol*, 2014, 55(3):933–937.
- [10] Berkovitz BKB, Holland GR, Moxham BJ. Oral anatomy, histology and embryology. 3rd edition, Mosby, UK, 2002, 81–92.
- [11] Bosse JP, Papillon J. Surgical anatomy of the SMAS at the malar region. In: ***. Transactions of the 9th International Congress of Plastic and Reconstructive Surgery, McGraw-Hill, New York, 1987, 348–349.
- [12] Delmar H. Anatomie des plans superficiels de la face et de cou [Anatomy of the superficial parts of the face and neck]. *Ann Chir Plast Esthet*, 1994, 39(5):527–555.
- [13] Gardetto A, Dabernig J, Rainer C, Piegger J, Piza-Katzer H, Fritsch H. Does a superficial musculoaponeurotic system exist in the face and neck? An anatomical study by the tissue plastination technique. *Plast Reconstr Surg*, 2003, 111(2): 664–672; discussion 673–675.
- [14] Gola R. Chirurgie esthétique et fonctionnelle de la face. Springer-Verlag, Paris, 2005.
- [15] Gosain AK, Klein MH, Madiedo G, Larson DL, Matloub HS, Sanger JR. Surgical anatomy of the SMAS: a reinvestigation. *Plast Reconstr Surg*, 1993, 92(7):1254–1263; discussion 1264–1265.
- [16] Hughes SM, Salinas PC. Control of muscle fibre and motoneuron diversification. *Curr Opin Neurobiol*, 1999, 9(1):54–64.
- [17] Picciolini O, Porro M, Cattaneo E, Castelletti S, Masera G, Mosca F, Bedeschi MF. Moebius syndrome: clinical features, diagnosis, management and early intervention. *Ital J Pediatr*, 2016, 42(1):56.
- [18] Scutariu MM, Surdu A, Macovei G. Contributions to recognition of some particularities of the lingual mucosa conditions. *Rev Med Chir Soc Med Nat Iasi*, 2015, 119(4):1147–1152.
- [19] Scutariu MM, Ciurcanu OE, Agop Forna D, Forna NC. Importance of dental maxillofacial aesthetics in dental therapy. *Rev Med Chir Soc Med Nat Iasi*, 2016, 120(4):926–931.

Corresponding author

Cristinel Ionel Stan, Assistant Professor, MD, PhD, Department of Anatomy and Embryology, “Grigore T. Popa” University of Medicine and Pharmacy, 16 Universității Street, 700115 Iași, Romania; Phone +40728–122 015, e-mail: cristi_stan00@yahoo.com

Received: September 27, 2016

Accepted: November 18, 2017