

## CASE REPORT

# Replaced common hepatic artery originating from the superior mesenteric artery and prepancreatic, anterior course in a patient with cephalic pancreaticoduodenectomy – case report

OCTAVIAN MARIUS CREȚU<sup>1)</sup>, EMIL FLORIN HUT<sup>1)</sup>, RADU GHEORGHE DAN<sup>1)</sup>, MIHNEA MUNTEANU<sup>1)</sup>, BOGDAN DAN TOTOLICI<sup>2)</sup>, OCTAVIAN AUREL ANDERCOU<sup>3)</sup>

<sup>1)</sup>Department of Surgery 1, "Victor Babeș" University of Medicine and Pharmacy, Timișoara, Romania

<sup>2)</sup>Department of General Medicine, Faculty of Medicine, "Vasile Goldiș" Western University, Arad, Romania

<sup>3)</sup>II<sup>nd</sup> Surgical Department, "Iuliu Hațieganu" University of Medicine and Pharmacy, Cluj-Napoca, Romania;  
 Clinic of Surgery II, Emergency County Hospital, Cluj-Napoca, Romania

## Abstract

The presence of hepatic arterial variations is particularly important for patients undergoing cephalic pancreaticoduodenectomy, because it can lead to unnecessary incidents or postoperative complications. We present the case of a patient with pancreatic head neoplasm in which the cephalic pancreaticoduodenectomy was performed and the origin of common hepatic artery from superior mesenteric artery, with an anterior, prepancreatic course.

**Keywords:** common hepatic artery, pancreaticoduodenectomy, anatomical variant.

## Introduction

Celiaco-mesenteric arterial aberrations are common, with frequency ranging from 22% to 48% [1], according to existing studies. In patients proposed for cephalic pancreaticoduodenectomy, their knowledge is extremely important, avoiding unnecessary surgical complications and thus perioperative morbidity [2].

Recognition of vascular anatomical variations is possible in preoperative explorations, multidetector computed tomography (CT) angiography, which allows for three-dimensional reconstructions, being an extremely efficient method with an accuracy approaching 100%. However, this ultra-modern exploration is not always available, the presence of these vascular abnormalities being often intraoperative surprises.

In this study, we present the case of a patient with pancreatic head neoplasm in which the cephalic pancreaticoduodenectomy was performed and the origin of common hepatic artery from superior mesenteric artery, with an anterior, prepancreatic course was intraoperatively discovered. This vascular aberration was not seen by the contrast enhanced CT scan preoperatively performed.

## Case presentation

A 60-year-old male patient was admitted to General Surgery Clinic of Timișoara City Hospital (Romania) for evaluation of jaundice. Contrast-enhanced CT scan revealed a tumor in the pancreatic head, with compressive effect on the biliary tract and the pancreatic duct, without invasion of superior mesenteric artery or celiac trunk. The patient was proposed for cephalic pancreaticodu-

denectomy. Intraoperatively, we discovered an arterial trunk posterior to the first portion of the duodenum, having a course similar to the gastroduodenal artery and the absence of a common hepatic artery originating from the celiac trunk. We preserved this artery and following its proximal and distal course, we discovered its origin in the superior mesenteric artery, having a prepancreatic course, describing a loop over the cephalic-isthmus portion of pancreas and ascending toward the hepatic hilum behind the first duodenal segment, where it divided into the two liver arteries, right and left respectively (Figure 1). No accessory liver arteries have been identified, the arterial blood supply of the liver being provided only by the aberrant artery. The section of the pancreas was made to the left of the portal vein (Figure 2), and resection of the mesopancreas, routinely performed during pancreaticoduodenectomy in our Clinic, has not encountered any particular difficulty, due to the anterior course of the aberrant artery (Figure 3).

After tactical cholecystectomy, the pancreatic head was excised together with the duodenum and antropyloric region of the stomach, according to the technique used in our Clinic. The pancreatico-jejunal anastomosis with invagination on intestinal loop past by mesocolon was performed in front of aberrant hepatic artery. The biliary and gastric anastomoses were performed on the same jejunal limb, in continuity.

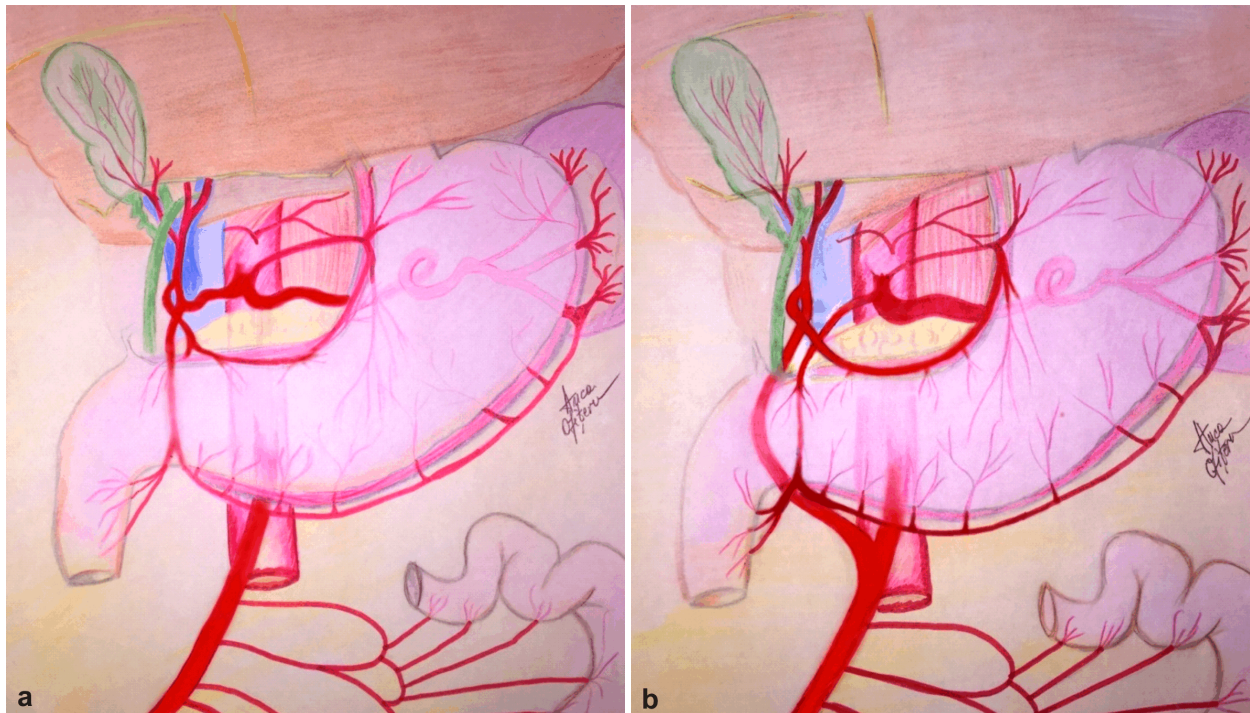
On the first postoperative day, the patient became hemodynamically unstable, with blood outflowing on the drainage tube. Abdominal ultrasound showed large intraperitoneal effusion. Under these conditions, surgical intervention was decided. Intraoperatively, we discovered

an active source of bleeding in the mesentery of the first jejunal loop, requiring hemostasis.

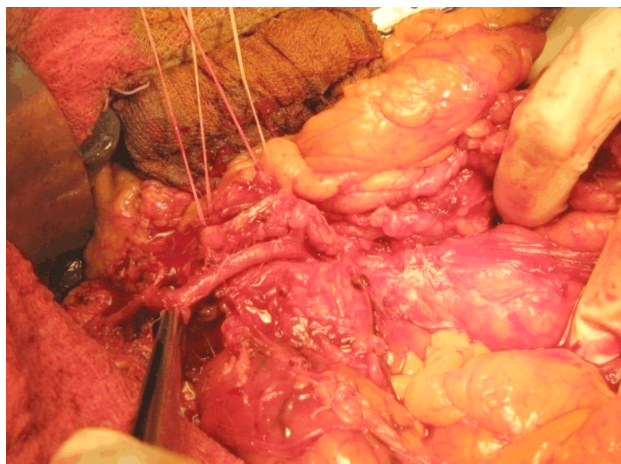
The patient's postoperative outcome was marked by the occurrence of an acute myocardial infarction, with cardiopulmonary arrest that responded to resuscitation maneuvers. Subsequently, the patient had a favorable

evolution, without noticeable events, being discharged 13 days after the second operation.

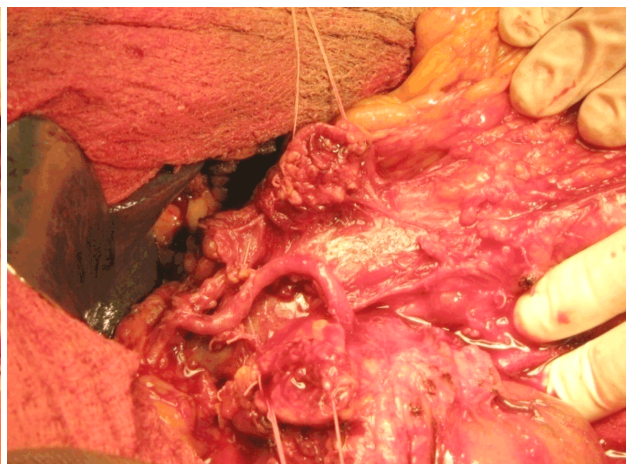
The histopathological examination revealed a moderately differentiated ductal adenocarcinoma of the pancreas (G2) that invades the duodenum to the level of lamina propria and an R0 type resection.



**Figure 1** – (a) *The normal hepatic artery (outline);* (b) *The aberrant hepatic artery in our case (outline).*



**Figure 2** – *Common hepatic artery originating from the superior mesenteric artery and prepancreatic anterior course. Pancreatic section to the left of the common hepatic artery (intraoperative aspect).*



**Figure 3** – *Appearance of the common hepatic artery originating from the superior mesenteric artery and prepancreatic, anterior course, after its dissection and separation from the pancreatic head (intraoperative aspect).*

## Discussion

The presence of hepatic arterial variations was first described by Haller, in 1756 [3, 4]. Two centuries later, in 1955, based on the results obtained from examination of 200 cadavers, Michels proposes a classification with the 10 most common types of arterial blood supply to the liver [5]. In 1994, Hiatt *et al.* simplified this classification to six types, following a study of 1000 cases [5, 6].

The anatomical variant with the origin of the common

liver artery in the superior mesenteric artery, also encountered in this case, is a rare possibility, found in 1–5% of cases [5, 7–10]. Studying 607 patients examined by CT multi-detector, Farghadani *et al.* found variations of the common liver artery origin in 16 patients (2.6%), eight patients having its origin in the superior mesenteric artery [8], while Thangarajah & Parthasarathy, using the same method, identified this anomaly in four of the 200 (2%) examined subjects [9]. In a mega-analysis performed on

5002 patients undergoing CT and digital subtraction angiography (DSA), Song *et al.* described the mesenteric origin of the common liver artery in 148 (3%) cases [10].

Although the course of this aberrant artery in relation to the pancreas has not been described in most of the studies [5], the prepancreatic one, encountered in our study, is a rare condition. Studying the arterial anatomy in 486 patients, Huang *et al.* discovered that only 3.2% of the common hepatic arteries originating in the superior mesenteric artery have a prepancreatic course [5, 11]. In our case, from over 50 cephalic pancreaticoduodenectomy performed in the Clinic in recent years, this was the only patient in which we found a common liver artery originating in the superior mesenteric artery and having an anterior, prepancreatic course.

Preoperative evidence of celiaco-mesenteric vascular abnormalities is particularly important for patients undergoing cephalic pancreaticoduodenectomy, where the direct view of the operator field may be limited, especially in the case of obese patients or with a history of supramesocolic surgery [4]. Preoperative knowledge of local vasculature allows the development of some surgical strategies, thus avoiding some unnecessary incidents or postoperative complications, some of which can put patient's life in danger.

Preoperative diagnosis of vascular abnormalities is possible using modern imaging techniques such as CT multi-detector angiography, spiral CT or DSA. The accuracy of these explorations is extremely high, reaching up to 100%, according to a study performed by Egorov *et al.* [1], who compared the results of multidetector CT angiography with intraoperative photographs in 59 patients with pancreaticoduodenectomy or extended distal pancreatectomy [1].

Often, however, these explorations are not available or do not reveal the presence of vascular abnormalities, these being real intraoperative surprises. In a paper published in 2014, Müller *et al.* [5] describing a case similar to that presented in our study, points out that vascular abnormalities were preoperatively observed by the surgical team who examined the images and were not mentioned in the radiological interpretation [5]. Similarly, Rubio-Manzanares-Dorado *et al.* states that 73% of the vascular abnormalities present in patients following cephalic pancreaticoduodenectomy were intraoperatively diagnosed [12].

The importance of a trained surgical team, emphasized by Müller *et al.* [5] in his study, can also be deduced from this case presentation, in which the vascular abnormality was intraoperatively found, the common hepatic artery originating from the superior mesenteric artery having a similar course with gastroduodenal artery, routinely ligated during cephalic pancreaticoduodenectomies. Not knowing the possibilities of anatomical variants and not exploring the arterial tract could have led to the ligation of this artery, the single arterial affluent of the liver in the described case.

In this case, the presence of arterial abnormalities did not increase operative time and did not require modification of the operative technique. Also, ablation of meso-

pancreas, routinely performed in the case of cephalic pancreaticoduodenectomies in our Clinic, has not raised any particular problems. The postoperative complications occurring in this case were not related to the presence of vascular abnormality.

The presence of vascular variant did not compromise oncological radicality for this case and a type R0 resection was performed. The possibility of oncological radicality in patients with cephalic pancreaticoduodenectomies and vascular abnormalities is supported by other studies in the literature, which conclude that pancreatic head oncological interventions are reliable, even in the presence of an aberrant liver artery [12, 13].

## Conclusions

The common hepatic artery originating from the superior mesenteric artery and prepancreatic course is a rare but possible occurrence in patients undergoing a cephalic pancreaticoduodenectomy. The discovery of arterial anomalies can be an intraoperative surprise, with no influence on patient's outcome, in case of a well-trained surgical team.

## Conflict of interests

The authors declare that they have no conflict of interests.

## References

- [1] Egorov VI, Yashina NI, Fedorov AV, Karmazanovsky GG, Vishnevsky VA, Shevchenko TV. Celiaco-mesenterial arterial aberrations in patients undergoing extended pancreatic resections: correlation of CT angiography with findings at surgery. *JOP*, 2010, 11(4):348–357.
- [2] Wood M, Lazo C, Hassid V, Awad ZT. Replaced common hepatic artery from superior mesenteric artery during pancreaticoduodenectomy. *Gulf J Oncolog*, 2012, (11):60–62.
- [3] Ramanadham S, Toomay SM, Yopp AC, Balch GC, Sharma R, Schwarz RE, Mansour JC. Rare hepatic arterial anatomic variants in patients requiring pancreatoduodenectomy and review of the literature. *Case Rep Surg*, 2012, 2012:953195.
- [4] Sureka B, Mittal MK, Mittal A, Sinha M, Bhambri NK, Thukral BB. Variations of celiac axis, common hepatic artery and its branches in 600 patients. *Indian J Radiol Imaging*, 2013, 23(3):223–233.
- [5] Müller P, Randhawa K, Roberts KJ. Preoperative identification of anomalous arterial anatomy at pancreaticoduodenectomy. *Ann R Coll Surg Engl*, 2014, 96(5):e34–e36.
- [6] Hiatt JR, Gabbay J, Busuttil RW. Surgical anatomy of the hepatic arteries in 1000 cases. *Ann Surg*, 1994, 220(1):50–52.
- [7] Michels NA. Newer anatomy of the liver and its variant blood supply and collateral circulation. *Am J Surg*, 1966, 112(3):337–347.
- [8] Farghadani M, Momeni M, Hekmatnia A, Momeni F, Baradaran Mahdavi MM. Anatomical variation of celiac axis, superior mesenteric artery, and hepatic artery: evaluation with multi-detector computed tomography angiography. *J Res Med Sci*, 2016, 21:129.
- [9] Thangarajah A, Parthasarathy R. Celiac axis, common hepatic and hepatic artery variants as evidenced on MDCT angiography in South Indian population. *J Clin Diagn Res*, 2016, 10(1):TC01–TC05.
- [10] Song SY, Chung JW, Yin YH, Jae HJ, Kim HC, Jeon UB, Cho BH, So YH, Park JH. Celiac axis and common hepatic artery variations in 5002 patients: systematic analysis with spiral CT and DSA. *Radiology*, 2010, 255(1):278–288.
- [11] Huang Y, Liu C, Lin JL. Clinical significance of hepatic artery variations originating from the superior mesenteric artery in abdominal tumor surgery. *Chin Med J (Engl)*, 2013, 126(5):899–902.

- [12] Rubio-Manzanares-Dorado M, Marín-Gómez LM, Aparicio-Sánchez D, Suárez-Artacho G, Bellido C, Álamo JM, Serrano-Díaz-Canedo J, Padillo-Ruiz FJ, Gómez-Bravo MÁ. Implication of the presence of a variant hepatic artery during the Whipple procedure. *Rev Esp Enferm Dig*, 2015, 107(7):417–422.
- [13] Jah A, Jamieson N, Huguet E, Praseedom R. The implications of the presence of an aberrant right hepatic artery in patients undergoing a pancreaticoduodenectomy. *Surg Today*, 2009, 39(8):669–674.

**Corresponding author**

Radu Gheorghe Dan, Assistant Professor, MD, PhD, Department of Surgery 1, “Victor Babeș” University of Medicine and Pharmacy, 2 Eftimie Murgu Square, 300041 Timișoara, Timiș County, Romania; Phone +40744–561 930, e-mail: radudan12@yahoo.com

*Received: May 3, 2016*

*Accepted: June 16, 2017*