

# Root fractures: epidemiological, clinical and radiographic aspects

SANDA MIHAELA POPESCU<sup>1)</sup>, OANA ANDREEA DIACONU<sup>2)</sup>, MONICA SCRIECIU<sup>1)</sup>, IULIA ROXANA MARINESCU<sup>1)</sup>, EMMA CRISTINA DRĂGHICI<sup>1)</sup>, ANCA GABRIELA TRUȘCĂ<sup>1)</sup>, ALEXANDRA CARINA BĂNICĂ<sup>1)</sup>, MIHAELA VĂTU<sup>1)</sup>, VERONICA MERCUT<sup>1)</sup>

<sup>1)</sup>Department of Prosthetics and Oral Rehabilitation, Faculty of Dental Medicine, University of Medicine and Pharmacy of Craiova, Romania

<sup>2)</sup>Department of Endodontics, Faculty of Dental Medicine, University of Medicine and Pharmacy of Craiova, Romania

## Abstract

Chronic root fractures are a relative frequent dental condition, occurring both in vital teeth and in teeth with root canal treatment, with a difficult and frustrating diagnosis. Two clinical forms are described: crown–root fractures with crown origin and vertical root fractures with root origin. The aim of the study was to determine the prevalence of the root fractured extracted teeth in two dental clinics with different profile [oral rehabilitation (OR) and endodontics (E)] and to present some particular aspects of the root fractures. A retrospective study over a period of five years was performed to determine the number of extracted teeth and the motives for extraction. For root fractured extracted teeth were noted: fracture type, tooth vitality, restoration type. Although the number of the patients with tooth extractions in the five years period was significantly higher in OR clinic than in E clinic, the number of tooth extractions was almost similar. Most of the teeth (70.6%) were extracted for caries complications. The prevalence of the root fractured extracted teeth was 17.93%. In OR clinic, women had more root fractured extracted teeth compared with E clinic, where the number of root fractured extracted teeth was higher in men. Most extracted teeth for root fracture were teeth with prosthetic restorations followed by teeth with root canal treatment and dental fillings. The most extracted teeth for root fracture were maxillary premolars, almost similar for both sexes, followed by mandibular molars. The teeth with least extractions for root fractures were mandibular incisors and mandibular canine.

**Keywords:** prevalence, clinical aspects, vertical root fractures.

## Introduction

Root fractures are discontinuities of the anatomical structure of the tooth root [1]. They are classified in acute and chronic fractures. The acute fractures could appear after an acute tooth trauma and the chronic fractures could appear after the summing of the action over a long period of many factors like: fatigue stress, root treatment consequences, incorrect tooth restoration [2].

Chronic root fractures represent a relative frequent disease, with a poor prognosis, often guiding the dentist towards tooth extraction. Prevalence of the extractions generated by the root fractures is controversial, varying between 4.4% [3] and 67% [4]. Root treated teeth fractures are the most frequent [5], teeth with large restorations being the most root fracture susceptible [6].

The classification of the root fractures takes into consideration the origin, localization and the direction of propagation of the fracture line [2]. According to their origin, chronic root fractures could be:

- Crown originating fractures – root fractures with the origin in the tooth crown, which are spontaneous fractures with the origin in the tooth crown, progressing towards apical direction to the tooth root;
- Root originating fractures – root fractures with the origin anywhere in the root, being characteristic for root treated teeth; most of them are vertical root fractures (VRFs).

Chronic root fractures are an entity very difficult to

diagnose, with many management issues that bring frustrations for the dentist and also the patient [7]. Chronic root fractures have a silent clinical stage, with evolution toward the infection of the fractured tooth that brings the clinical signs and symptoms [2]. Root fractured tooth signs and symptoms are uncertain, but pain, swollen, sinus tract and periodontal pocket could be seen [8].

The radiographic aspect in horizontal root fractures is evident [9]. In vertical root fractures, fracture line is very difficult to be determined. Cone beam computed tomography (CBCT) using for diagnosing vertical root fractures could be a solution [10, 11], but only if the root fracture has a certain dimension [12]. Otherwise, because of the radiopaque root canal materials and metallic posts, artifacts could appear making the diagnostic impossible. Sometimes, the dentist could reflect a surgical flap to observe the fracture line and to put a certain diagnosis [13]. Most root fractures cases are treated by extraction of the fractured tooth. There are also alternatives to this, as the extraction of the fractured tooth, the cementation of the fractured parts and tooth replantation [14–16].

The aim of the study was to determine the prevalence of the tooth extractions motivated by root fractures and to present some particular aspects of the root fractures.

## Patients, Materials and Methods

The retrospective study was performed in two dental clinics of the Faculty of Dental Medicine, University of

Medicine and Pharmacy of Craiova (Romania) – Oral Rehabilitation Clinic and Endodontics Clinic, over a period of five years, between 2012–2016, in order to determine the number of extracted teeth and the motives for extraction. Institutional Ethical Committee of University of Medicine and Pharmacy of Craiova approved the study. The variables took into consideration were: patient's age and gender and reason for extraction (dental caries, periodontal disease, root fracture). For teeth extracted as a consequence of root fracture, the following variables were noted: fracture type, tooth vitality, restoration type (dental filling, root cast post, root prefabricated post, cast post with bridge, vital tooth with bridge, non-vital tooth with bridge). A few special cases were selected from the archives to be presented. Collected data were analyzed using chi-square ( $\chi^2$ ) test.

**Table 1 – Prevalence of the teeth extractions according to reason for extraction**

Dental clinic profile	Patients (n)	Mean age [years]	Extracted teeth (n)	Caries extracted teeth		Periodontal extracted teeth		Root fractured extracted teeth	
				n	%	n	%	n	%
Oral rehabilitation	253	43.13±14.98 [15–81]	357 1.41 extracted teeth/patient	287	80.4	36	10.1	34	9.5
Endodontics	93	52.86±14.28 [22–88]	379 4.75 extracted teeth/patient*	233	61.5	48	12.7	98*	25.8

\* $p < 0.05$ .

In the case of root fractured extracted teeth, the prevalence was significantly higher in Endodontics Clinic compared with Oral Rehabilitation Clinic (Table 2). In Oral Rehabilitation Clinic, women had more root fractured extracted teeth compared with men (Table 2). In Endodontics Clinic, the number of root fractured extracted teeth was higher in men (Table 2).

**Table 2 – Root fractured extracted teeth distribution according to gender**

Dental clinic profile	Patients		Root fractured extracted teeth	
	n	%	n	%
Oral rehabilitation	253*		34*	
Men	99	39.4	7	20.6
Women	154	60.6	27	79.4
Endodontics	93		98	
Men	43	46.2	52	53.1
Women	50	53.8	46	46.9

\* $p < 0.05$ .

For both dental clinics, most extracted teeth for root fracture were non-vital teeth with root canal treatment and dental fillings, mainly from composite (Table 3, Figures 1 and 2). A higher number of teeth with dental cast post and dental cast post and bridge (Table 3, Figures 3 and 4), and also non-vital teeth with bridge were fractured and extracted, compared to vital teeth (Table 3, Figure 5) and vital teeth with bridge (Table 3, Figure 6). Overall, most teeth extracted for root fracture had a prosthetic rehabilitation, like cast post and crown, cast post and bridge or bridge on non-vital teeth (Table 3).

The most extracted teeth for root fracture were maxillary premolar (Table 4, Figure 5), almost similar for both genders, followed by mandibular molars (Table 4, Figures 1 and 2). The next most extracted teeth for root fracture were maxillary incisors, mainly in men and maxillary molars, mainly in women (Table 4). The teeth with least extractions

## Results

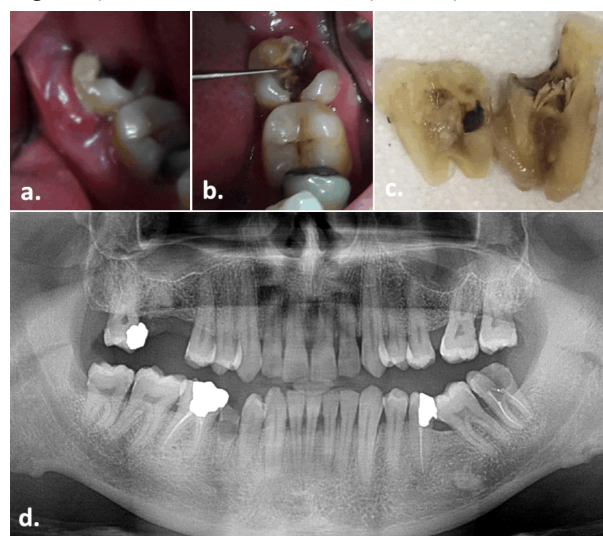
The number of the patients with tooth extractions in the five years period was significantly higher in Oral Rehabilitation Clinic then in Endodontics Clinic (Table 1).

Mean age of the patients was 43.1 years in the Oral Rehabilitation Clinic and 52.8 years in the Endodontics Clinic (Table 1).

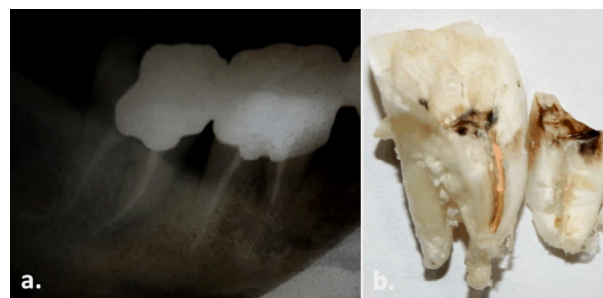
The number of tooth extractions in the five years period was almost similar in the two dental clinics, with a medium number of extracted teeth per patient significantly higher in Endodontics Clinic (Table 1).

In general, the teeth were extracted for caries complications: 80.39% in Oral Rehabilitation Clinic and 61.48% in Endodontics Clinic (Table 1). Overall, the prevalence of the root fractured extracted teeth was 17.93%.

for root fractures were mandibular incisors (Table 4, Figure 6) and mandibular canine (Table 4).



**Figure 1 – (a–d) Endodontically treated tooth (mandibular third molar – 38) with amalgam filling, which has been fractured mesial–distal four months after the root canal treatment – 46-year-old male patient.**



**Figure 2 – (a and b) Endodontically treated tooth (mandibular third molar – 48) with amalgam filling, which after 10 years of service presented with fracture of mesial root – 46-year-old male patient.**

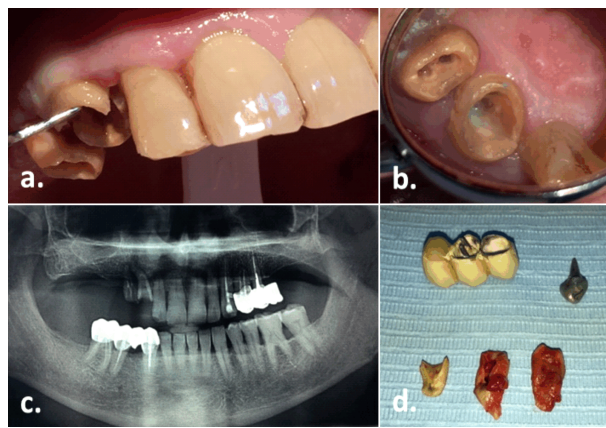


Figure 3 – (a–d) Right maxillary canine (13) with cast post included in an incorrect bridge – 72-year-old male patient.

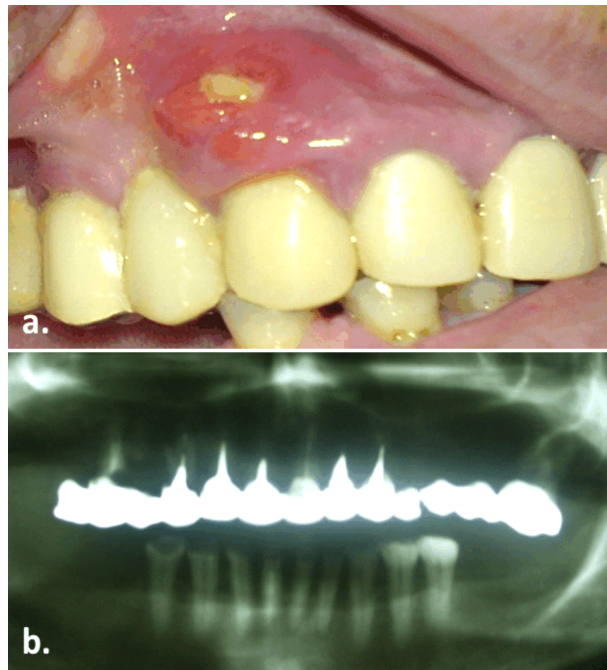


Figure 4 – (a and b) Right maxillary canine (13), with cast post in a total metallic–acrylic maxillary bridge – 57-year-old female patient.

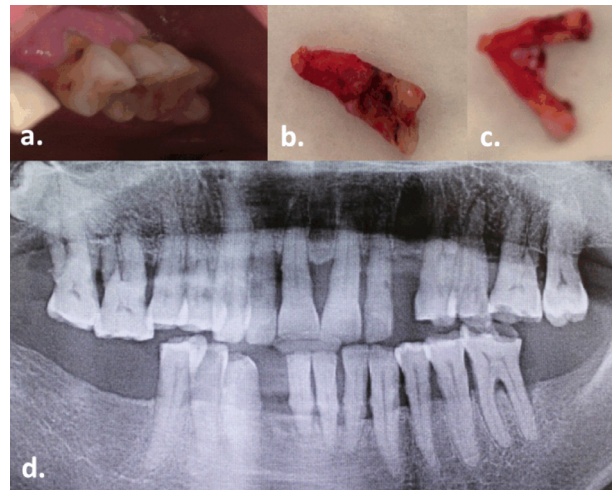


Figure 5 – (a–d) Vital maxillary premolar (25) with occlusal wear (attrition), with vertical crown–root fracture – 65-year-old female patient.

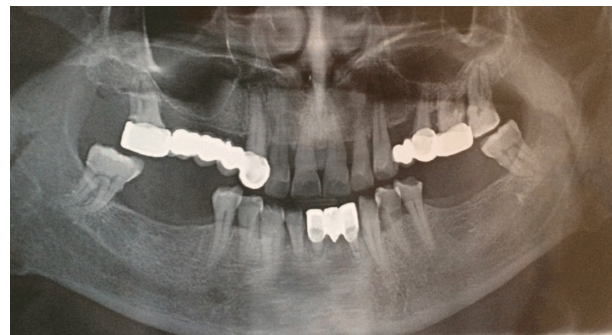

Figure 6 – Lateral incisor teeth (32), a bridge pillar, a horizontal fracture in the apical third, vital tooth – 58-year-old male patient.

A few special cases were retrieved from the archives and presented: two vital teeth with root fracture, a superior premolar with tooth wear and vertical root fracture crown originated (Figure 5) and an inferior incisor with horizontal root fracture (Figure 6); a superior canine with cast post in a total bridge with vertical root fracture, root fragments displaced and a perforation of the buccal bone plate and buccal oral mucosa (Figure 4).

Table 3 – Root fractured extracted teeth according vitality and prosthetic treatments

Dental clinic profile	RF non-vital tooth		RF vital tooth		RF cast post		RF cast post and bridge		RF vital tooth and bridge		RF non-vital tooth and bridge		RF prefabricated post		Total
	n	%	n	%	n	%	n	%	n	%	n	%	n	%	
Oral rehabilitation	12	35.4	3	8.9	8	23.5	8	23.5	1	2.9	2	5.8	0	0	34
Endodontics	33	33.7	3	3.1	16*	16.3	21	21.4	0	0	23*	23.4	2	2.1	98
Total	45		6		24		29		1		25		2		132

RF: Root fracture; \* $p < 0.05$ .

Table 4 – Root fractured extracted teeth distribution according to type of tooth

Gender	Max. incisor		Max. canine		Max. premolar		Max. molar		Mand. incisor		Mand. canine		Mand. premolar		Mand. molar		Total
	n	%	n	%	n	%	n	%	n	%	n	%	n	%	n	%	
Males	14*	23.7	4	6.8	16	27.1	5	8.5	2	3.4	0	0	3	5.1	15	25.4	59
Females	8	10.9	7	9.6	14	19.2	14*	19.2	3	4.1	1	1.4	14*	19.2	12	16.4	73
Total	22		11		30		19		5		1		17		27		132

Max.: Maxillary; Mand.: Mandibular; \* $p < 0.05$ .

## Discussion

The prevalence of extractions for reasons of dental caries was highest in this study (70.7%), significantly higher than root fracture (17.9%) and periodontal disease (11.4%). The result is motivated by a high decayed, missing, and filled teeth (DMFT) index in our country [17], maintaining higher caries prevalence than in other countries, where the number of teeth extracted for dental caries is closer to number of teeth extracted for periodontal disease [3, 18]. The mean age of patients with root fractures was higher in endodontics clinic (52.8 years), then in oral rehabilitation clinic, where the mean age was 43.3 years.

As for root fractured extracted teeth, the overall rate is higher than in other studies [3, 5, 18, 19]. The prevalence of root fractured extracted teeth was higher in endodontics clinic than in oral rehabilitation clinic (25.8% *versus* 9.5%). Many dental clinics are doing root canal treatments (all dentists have this ability) but for root canal treatment complications, patients are referred to endodontics clinics. Accordingly, the number of teeth with poor prognosis is significantly higher in endodontics clinic than in oral rehabilitation clinic, where root canal treatment is performed first time (4.7 extractions per patient *versus* 1.41 extractions per patient). As such, the higher number of root fractured extracted teeth is explained through excessive reshaping of the root canals in retreatments and the lowering of root walls resistance that is favoring root fracture.

In oral rehabilitation clinic, root fracture prevalence is higher in women (79.4%), mandibular molars being the most affected by root fracture. Root fracture prevalence higher in women was found also by other authors [19, 20]. In endodontics clinic, the prevalence of root fractured extracted teeth is a little higher in men (53.06%), maxillary premolars being the most affected teeth by root fracture. Overall, the most affected teeth by root fracture were maxillary premolars and mandibular molars. A higher prevalence of root fracture in maxillary premolars and mandibular molars was found also by other authors [20–22]. The highest prevalence for root fractured extracted maxillary premolars is justified by the fact that patients choose almost every time the cheapest treatment solution (*e.g.*, dental composite filling instead of crown for non-vital teeth), and they hardly accept a denture. Many times, patients request treatment solutions that represent a compromise both for patient and dentist. The higher prevalence of root fractured extracted teeth in mandibular molars can be explained by a higher occlusal force distribution in molars (first mandibular molar takes 55% from maximum occlusal force) [23, 24].

Apart from the type of tooth affected by root fracture, the number of fractured teeth with root canal treatment and prosthetic treatment was higher than the number of non-vital teeth with fillings, and the number of vital teeth affected by root fracture. The strong association of root fracture with prosthetic treatment was shown also by Matsuda *et al.* [19] and Liao *et al.* [20].

American Association of Endodontics [9] described five types of root fractures, and among them, three types referred to root fractures (cracked tooth, split tooth and

vertical root fracture). In fact, cracked tooth and split tooth are two stages of the vertical root fractures originated in the crown of the tooth. Crown originating root fractures are not correlated with endodontic treatment, and they appear in the tooth crown progressing towards the root, and getting to the vertical fracture of the tooth [2]. Crown–root fractures with medial–distal direction observed in vital teeth (maxillary premolars and maxillary and mandibular molars) with/without fillings, were named cracked teeth [2, 9, 25]. If the root fracture is diagnosed in the first stage of evolution (so-called cracked tooth) the fracture would be incomplete, with minimal clinical signs and reserved prognostic. Subsequent, even if treatment is done, the stage is exceeded, since the fracture would become complete with the two fragments separation (split tooth).

Fractures with root origin are usually characteristic for endodontic treated teeth but they could be encountered also in vital teeth. They could have the origin in each level of the root, even if they frequent originate in the apical part of the root [8, 13]. Although these fractures are usually vertical, they do not follow always the axis of the tooth root, their direction being influenced by the shape of the tooth root and the occlusal forces [13]. If these fracture lines originate in the medium part of the root, they could propagate anyway, in any direction. VRFs have an oral–buccal pattern, rarely being medial–distal [13].

The factors implicated in the etiology of radicular fractures encountered in this study were: the endodontic preparation of root canal, the type of root canal filling, the type of the crown filling, the type of post, the type of bridge, occlusal factors and parafunctional habits. Several authors consider that the etiology of root fractures may be due to trauma [26], non-physiological chewing [27] and iatrogenic dental treatments [28]. Over time, many studies related the factors associated with endodontic treatment to root fractures. It has been found that classic endodontic preparation of the teeth with absent marginal ridges is more likely to fracture than those with the minimally invasive endodontic preparation and intact marginal ridges [6, 29]. Chai & Tamse [30] have considered ovoid and irregular channels more susceptible to fracture. Factors related to instrumentation and taper may affect fracture risk only indirectly.

According to Pitts & Natkin [26], there is a correlation between the force applied to the teeth that generates fracture and root size, width of canal walls after preparation, and the endodontic taper. However, subsequent studies have shown that as the root dentin layer thins, increases the risk of root fracture [31, 32]. The materials used for root canal does not alter the root fracture resistance [33].

The high frequency of root fracture in the post restored teeth, whether included or not in a bridge, is explained by the failure to follow the indications and tooth preparing techniques for these prosthetic restorations. For right maxillary canine with post included in a full bridge, the life of this formula was seven years. The metallic–acrylic total bridge, which included right superior canine as an abutment, increased the occlusal vertical dimension and subsequently caused wear of the antagonistic dental arch. In the left side of the bridge, the pontic was fractured.

The opposite dental arch was shortened, with severely worn teeth. Fractured maxillary right canine was opposed with the last tooth on the antagonist shortened arcade (second premolar), and also the fractured pontic is also opposed to the last tooth on the opposing arch. We consider that in this situation a continuous overestimation of occlusal forces determined by the occlusal vertical dimension (OVD) increase produced fatigue stress and subsequently the VRF of the canine, with the vestibular wall displacement and perforation of the maxillary alveolar process, accompanied by the discontinuity of the oral mucosa.

We consider that horizontal fracture in the apical third of the lateral incisor in the mandibular bridge could be due to differences of mobility between the two abutment teeth with bad distribution of the occlusal forces. Vertical complete crown-root fracture in the vital upper premolar (split tooth) could be explained by the morphology of the premolar, which favored the appearance of the fracture line between the two cusps and the presence of excessive force that after Larson could reach 1000 N and which produced fatigue wear at this level [23]. Fatigue fractures occur in endodontic root treated teeth but also in vital teeth. The incidence of dental fractures was associated with large restorations and large carious cavities. Teeth restored with adhesive restorations presented a more favorable distribution of stress, similar to that of intact teeth, and better resistance to fracture.

## ✉ Conclusions

Although the number of the patients with tooth extractions in the five years period was significantly higher in oral rehabilitation clinic than in endodontics clinic, the number of tooth extractions was almost similar. Most of the teeth were extracted for caries complications. The prevalence of the root fractured extracted teeth was second position, after caries. The factors implicated in root fractures were root canal treatment and retreatment, occlusal forces, incorrect prosthetic treatment and para-functional habits.

## Conflict of interests

The authors declare that they have no conflict of interests.

## References

- [1] Andreasen FM, Andreasen JO. Crown fractures. In: Andreasen JO, Andreasen FM, Andersson L (eds). Textbook and color atlas of traumatic injuries to the teeth. 4<sup>th</sup> edition, Wiley-Blackwell, Oxford, 2007, 280–313.
- [2] Bakland LK, Tamse A. Categorization of dental fractures. In: Tamse A, Tsesis I, Rosen E (eds). Vertical root fractures in dentistry. Springer International Publishing, Switzerland, 2015, 7–28.
- [3] Chrysanthakopoulos NA. Reasons for extraction of permanent teeth in Greece: a five-year follow-up study. *Int Dent J*, 2011, 61(1):19–24.
- [4] Axelsson P, Nyström B, Lindhe J. The long-term effect of a plaque control program on tooth mortality, caries and periodontal disease in adults. Results after 30 years of maintenance. *J Clin Periodontol*, 2004, 31(9):749–757.
- [5] Fuss Z, Lustig J, Tamse A. Prevalence of vertical root fractures in extracted endodontically treated teeth. *Int Endod J*, 1999, 32(4):283–286.
- [6] Taha NA, Palamara JE, Messer HH. Fracture strength and fracture patterns of root filled teeth restored with direct resin restorations. *J Dent*, 2011, 39(8):527–535.
- [7] Tsesis I, Rosen E, Tamse A, Taschieri S, Kfir A. Diagnosis of vertical root fractures in endodontically treated teeth based on clinical and radiographic indices: a systematic review. *J Endod*, 2010, 36(9):1455–1458.
- [8] Corbella S, Tamse A, Nemcovsky C, Taschieri S. [Diagnostic issues dealing with the management of teeth with vertical root fractures: a narrative review]. *G Ital Endod*, 2014, 28(2):91–96.
- [9] Endodontics: Colleagues for Excellence. Cracking the cracked tooth code: detection and treatment of various longitudinal tooth fractures. American Association of Endodontists, Chicago, 2008, 2–7, [https://www.aae.org/uploadedfiles/publications\\_and\\_research/endodontics\\_colleagues\\_for\\_excellence\\_new\\_sletter/ecfesum08.pdf](https://www.aae.org/uploadedfiles/publications_and_research/endodontics_colleagues_for_excellence_new_sletter/ecfesum08.pdf).
- [10] Endodontics: Colleagues for Excellence. Cone beam-computed tomography in endodontics. American Association of Endodontists, Chicago, 2011, 2–7, [https://www.aae.org/uploadedfiles/publications\\_and\\_research/endodontics\\_colleagues\\_for\\_excellence\\_newsletter/ecfe%20summer%2011%20final.pdf](https://www.aae.org/uploadedfiles/publications_and_research/endodontics_colleagues_for_excellence_newsletter/ecfe%20summer%2011%20final.pdf).
- [11] Corbella S, Del Fabbro M, Tamse A, Rosen E, Tsesis I, Taschieri S. Cone beam computed tomography for the diagnosis of vertical root fractures: a systematic review of the literature and meta-analysis. *Oral Surg Oral Med Oral Pathol Oral Radiol*, 2014, 118(5):593–602.
- [12] Chang E, Lam E, Shah P, Azarpazhooh A. Cone-beam computed tomography for detecting vertical root fractures in endodontically treated teeth: a systematic review. *J Endod*, 2016, 42(2):177–185.
- [13] Walton RE, Tamse A. Diagnosis of vertical root fractures. In: Tamse A, Tsesis I, Rosen E (eds). Vertical root fractures in dentistry. Springer International Publishing, Switzerland, 2015, 49–66.
- [14] Iqbal MK, Kim S. A review of factors influencing treatment planning decisions of single-tooth implants *versus* preserving natural teeth with nonsurgical endodontic therapy. *J Endod*, 2008, 34(5):519–529.
- [15] Avila G, Galindo-Moreno P, Soehren S, Misch CE, Morelli T, Wang HL. A novel decision-making process for tooth retention or extraction. *J Periodontol*, 2009, 80(3):476–491.
- [16] Tsesis I, Beitlitum I, Rosen E. Treatment alternatives for the preservation of vertically root fractured teeth. In: Tamse A, Tsesis I, Rosen E (eds). Vertical root fractures in dentistry. Springer International Publishing, Switzerland, 2015, 97–108.
- [17] Baci D, Danila I, Balcos C, Gallagher JE, Bernabé E. Caries experience among Romanian schoolchildren: prevalence and trends 1992–2011. *Community Dent Health*, 2015, 32(2):93–97.
- [18] Aida J, Ando Y, Akhter R, Aoyama H, Masui M, Morita M. Reasons for permanent tooth extractions in Japan. *J Epidemiol*, 2006, 16(5):214–219.
- [19] Matsuda K, Ikebe K, Enoki K, Tada S, Fujiwara K, Maeda Y. Incidence and association of root fractures after prosthetic treatment. *J Prosthodont Res*, 2011, 55(3):137–140.
- [20] Liao WC, Tsai YL, Wang CY, Chang MC, Huang WL, Lin HJ, Liu HC, Chan CP, Chang SH, Jeng JH. Clinical and radiographic characteristics of vertical root fractures in endodontically and nonendodontically treated teeth. *J Endod*, 2017, 43(5):687–693.
- [21] PradeepKumar AR, Shemesh H, Jothilatha S, Vijayabharathi R, Jayalakshmi S, Kishen A. Diagnosis of vertical root fractures in restored endodontically treated teeth: a time-dependent retrospective cohort study. *J Endod*, 2016, 42(8):1175–1180.
- [22] Llana-Puy MC, Forner-Navarro L, Barbero-Navarro I. Vertical root fracture in endodontically treated teeth: a review of 25 cases. *Oral Surg Oral Med Oral Pathol Oral Radiol Endod*, 2001, 92(5):553–555.
- [23] Larson TD. The effect of occlusal forces on restorations. *J Mich Dent Assoc*, 2014, 96(9):38–47.
- [24] Petcu CM, Nițoi D, Mercuț V, Țuculină MJ, Iliescu AA, Croitoru CI, Diaconu OA, Iliescu MG, Gheorghită LM, Iliescu A. Masticatory tensile developed in upper anterior teeth with chronic apical periodontitis. A finite-element analysis study. *Rom J Morphol Embryol*, 2013, 54(3):587–592.
- [25] Lubisich EB, Hilton TJ, Ferracane J; Northwest Precedent. Cracked teeth: a review of the literature. *J Esthet Restor Dent*, 2010, 22(3):158–167.
- [26] Pitts DL, Natkin E. Diagnosis and treatment of vertical root fractures. *J Endod*, 1983, 9(8):338–346.

- [27] Goga R, Purton DG. The use of endodontically treated teeth as abutments for crowns, fixed partial dentures, or removable partial dentures: a literature review. *Quintessence Int*, 2007, 38():e106–e111.
- [28] Jameson MW, Hood JA, Tidmarsh BG. The effects of dehydration and rehydration on some mechanical properties of human dentine. *J Biomech*, 1993, 26(9):1055–1065.
- [29] Chlup Z, Žižka R, Kania J, Přibyl M. Fracture behaviour of teeth with conventional and mini-invasive access cavity designs. *J Eur Ceram Soc*, 2017, March 27.
- [30] Chai H, Tamse A. Fracture mechanics analysis of vertical root fracture from condensation of gutta-percha. *J Biomech*, 2012, 1673–1678.
- [31] Lertchirakarn V, Palamara JE, Messer HH. Load and strain during lateral condensation and vertical root fracture. *J Endod*, 1999, 25(2):99–104.
- [32] Lertchirakarn V, Palamara JE, Messer HH. Patterns of vertical root fracture: factors affecting stress distribution in the root canal. *J Endod*, 2003, 29(8):523–528.
- [33] Ribeiro FC, Souza-Gabriel AE, Marchesan MA, Alfredo E, Silva-Sousa YT, Sousa-Neto MD. Influence of different endodontic filling materials on root fracture susceptibility. *J Dent*, 2008, 36(1):69–73.

**Corresponding author**

Oana Andreea Diaconu, Lecturer, DMD, PhD, Department of Endodontics, Faculty of Dental Medicine, University of Medicine and Pharmacy of Craiova, 2 Petru Rareș Street, 200349 Craiova, Romania; Phone +40722–248 030, e-mail: oanamihailescu76@yahoo.com

*Received: May 3, 2016*

*Accepted: June 12, 2017*