

## CASE REPORT

# Cribriform-morular variant of papillary thyroid carcinoma at pediatric age – case report and review of the literature

ANDREEA CRISTIANA BREHAR<sup>1)</sup>, DANA CRISTINA TERZEA<sup>2,3)</sup>, DUMITRU LUCIAN IOACHIM<sup>3)</sup>,  
 CAMELIA PROCOPIUC<sup>1)</sup>, FELIX MIRCEA BREHAR<sup>4)</sup>, ALEXANDRA CĂTĂLINA BULGĂR<sup>5)</sup>,  
 MIRCEA VASILE GHEMIGIAN<sup>6)</sup>, CONSTANTIN DUMITRACHE<sup>5,7)</sup>

<sup>1)</sup>Department of Pediatric Endocrinology, "C. I. Parhon" National Institute of Endocrinology, Bucharest, Romania

<sup>2)</sup>Department of Morphopathology, "Carol Davila" University of Medicine and Pharmacy, Bucharest, Romania

<sup>3)</sup>Department of Pathology and Cytopathology, "C. I. Parhon" National Institute of Endocrinology, Bucharest, Romania

<sup>4)</sup>Department of Neurosurgery, "Carol Davila" University of Medicine and Pharmacy, Bucharest, Romania

<sup>5)</sup>Department of Endocrinology, "C. I. Parhon" National Institute of Endocrinology, Bucharest, Romania

<sup>6)</sup>Department of Surgery, "C. I. Parhon" National Institute of Endocrinology, Bucharest, Romania

<sup>7)</sup>Department of Endocrinology, "Carol Davila" University of Medicine and Pharmacy, Bucharest, Romania

## Abstract

Cribriform-morular variant of papillary thyroid carcinoma (CMV-PTC) is a rare tumor, which exceptionally occurs at pediatric age. CMV-PTC may develop in patients with familial adenomatous polyposis (FAP) or may be a sporadic tumor. The authors present a case of CMV-PTC in a 10-year-old girl patient without FAP history, who presented with a left neck mass. The patient underwent total thyroidectomy with central compartment neck dissection. Histopathological diagnosis was compatible with cribriform-morular variant of papillary thyroid carcinoma and Hashimoto's thyroiditis. Immunostaining was positive for thyroglobulin,  $\beta$ -catenin, CD10 and p53. Molecular test showed the absence of BRAF, K-RAS mutations, deletions or duplications of APC (adenomatosis polyposis coli) gene and showed the presence of RET/PTC (rearranged during transfection/papillary thyroid carcinoma) rearrangements. At 32 months follow-up, the patient was without signs of recurrence. This particular form of thyroid carcinoma should raise suspicion of a possible familial cancer syndrome, therefore early diagnosis and thoroughly evaluation, which includes colonoscopy and genetic screening are mandatory.

**Keywords:** cribriform-morular carcinoma, papillary thyroid carcinoma, Hashimoto's thyroiditis, thyroglobulin.

## Introduction

Thyroid carcinoma (TC) is the most common malignancy of endocrine organs and it may develop from thyroid follicular epithelial cells and from para-follicular C cells. There are several sub-types of follicular cell-derived TC: well-differentiated papillary carcinoma (PTC) (80% of all thyroid carcinoma), follicular carcinoma (FTC) (approximately 15% of cases), poorly differentiated carcinoma and anaplastic (undifferentiated) carcinoma (2% of all thyroid cancer) [1].

The cribriform-morular variant (CMV) of PTC is a very rare subtype of PTC that was first described by Harach *et al.*, in 1994, in patients with familial adenomatous polyposis (FAP) and in 1999 by Cameselle-Teijeiro & Chan as the sporadic counterpart of FAP-associated thyroid carcinoma. The sporadic form is often solitary and in FAP-associated thyroid carcinoma is often multicentric [2, 3]. This rare form of thyroid carcinoma presents a particular morphology: areas showing cribriform architecture with follicular, papillary, trabecular, solid and spindle cell growth patterns with morular areas [2–4].

The molecular mechanisms involved are mutation of the APC (adenomatosis polyposis coli) gene and/or  $\beta$ -catenin gene that activate the Wnt pathway (derived from Wingless, the *Drosophila melanogaster* segment-polarity

gene, and Integrase-1, the vertebrate homologue) with cytoplasmic and nuclear storage of  $\beta$ -catenin [5–7].

RET/PTC translocations [rearrangements of the rearranged during transfection (RET) proto-oncogene, called RET/PTC rearrangements] were also described in this type of thyroid carcinoma [8, 9].

The aim of this paper was to evaluate a case of a rare form of thyroid cancer, the cribriform-morular variant of papillary thyroid carcinoma (CMV-PTC), which exceptionally occurs in pediatric patients and to review the current data available in the literature. To our knowledge, in the literature it was described only a case of CMV at pediatric age. Moreover, this is also the first report of CMV-PTC associated with Hashimoto's thyroiditis at pediatric age.

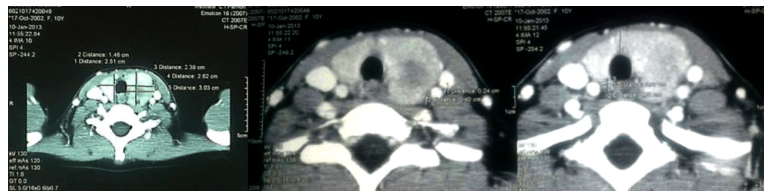## Case presentation

### Study case

We report the case of a 10-year-old girl without history of FAP or thyroid pathology who presented a left neck mass with relative rapid development. Physical examinations revealed a 3/3 cm nodule in the left lobe of thyroid with multiple hard swellings in the left supraclavicular and upper cervical regions. Thyroid ultrasound demonstrated a 2.81/2.9 cm mass in the left thyroid lobe with ultra-

sound signs suggestive for malignancy with regional lymphadenopathy (Figure 1). Thyroid scan with  $^{131}\text{I}$  revealed a "cold" left thyroid nodule. Laboratory findings of thyroid function tests revealed subclinical hypothyroidism. Anti-thyroid-peroxidase antibodies (anti-TPO) were positive and calcitonin levels were normal. Cervical, mediastinal and thoracic computed tomography (CT) scan described a 2.39/2.62/3.03 cm mass in the left lobe with inner calcifications with numerous regional lymph nodes metastases (Figure 2). The fine-needle aspiration (FNA) biopsy specimen demonstrated cells suspicious for papillary neoplasia.

The patient underwent a total thyroidectomy with central compartment neck dissection. After surgery, the patient underwent therapeutic radioactive iodine ablation and received T4 suppression treatment. Given the histopathological diagnosis, which was C-MV of papillary thyroid carcinoma (C-MV of PTC), the patient was advised for periodically follow-up visits, which should include colorectal examination and genetic screening for APC and  $\beta$ -catenin mutation, when they will be available.



**Figure 2 – Cervical CT scan describes a 2.39/2.62/3.03 cm mass in the left lobe with microcalcifications and numerous regional lymph nodes metastases.**

### Histopathological evaluation

The surgical specimen was fixed in formalin and then paraffin-embedded. Serial 3- $\mu\text{m}$  sections had been cut from paraffin blocks and stained with Hematoxylin and Eosin (HE).

The pathology report on gross examination revealed a 5.8/3.9 cm thyroid carcinoma of the entire left thyroid lobe (pT3N1). The isthmus and the right lobe of the thyroid parenchyma exhibited an aspect of chronic thyroiditis. Thirty-two lymphatic nodes were examined, of which 10 lymphatic nodes presented metastatic deposits of thyroid carcinoma.

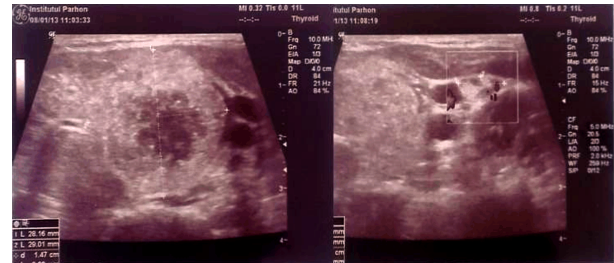
HE-stained cross-sections showed follicular (Figure 3, d and f), papillary (Figure 3f), solid (Figure 3, e and f), cribriform (Figure 4, b–d) and morular (Figure 4, a and c) architecture with capsular, vascular and lymphatic invasion and extrathyroidal extension (ETE). The remainder of the thyroid parenchyma revealed Hashimoto's thyroiditis. Histological examination of 10 regional lymph nodes revealed metastatic deposits of thyroid carcinoma.

### Immunohistochemistry evaluation

The immunohistochemistry (IHC) was performed on 3- $\mu\text{m}$  sections from 10% formalin-fixed paraffin-embedded tissues according to the IHC method of indirect bistradial technique performed with a polymer based detection system (EnVision™ Dual Link System-HRP, DAKO, Carpinteria, CA, USA). Tissue sections were spread on poly-L-lysine-coated slides immersed in three changes of xylene and rehydrated using a graded series of alcohol. Antigen retrieval was performed in microwave oven. In each section, endogenous peroxidase was blocked by 20 minutes incubation in 3% hydrogen peroxide. The

Colonoscopy revealed a normal colon without polyposis. Because in FAP there are described extracolonic manifestations that include brain tumors, a cerebral CT scan was performed and it was normal. Screening for APC mutation was performed 22 months after thyroidectomy.

At 32 months follow-up, the patient was without signs of local recurrence or distant metastasis and the patient received T4 suppression treatment.



**Figure 1 – Thyroid ultrasound demonstrates a 2.81/2.9 cm mass in the left thyroid lobe with ultrasound signs suggestive for malignancy (left) with regional lymphadenopathy (right).**

sections were incubated with primary antibody: thyroglobulin (DAKO, 1:500, polyclonal),  $\beta$ -catenin (DAKO, 1:200,  $\beta$ -catenin 1), p53 (DAKO, 1:50, D07), CD10 (Leica, 1:100, 56C6) and Ki67 (DAKO, 1:100, Mib-1), at room temperature for 1 hour. The DAKO EnVision Detection System-HRP was then applied for 30 minutes. Finally, the sections were incubated in 3,3'-diaminobenzidine for 5 minutes, counterstained with Mayer's Hematoxylin and mounted. The slides were examined and photographed on Leica DM750 microscope. Negative controls were obtained by replacing the primary antibody with non-immune serum. As a positive control, a thyroid tissue section was used.

On immunohistochemical examination, the tumor cells presented a diffuse strong expression for thyroglobulin (Figure 4a) with focal positive immunoreactivity for  $\beta$ -catenin (Figure 4b). CD10 was expressed diffuse in tumor cells (Figure 4c), p53 was positive in 35% on the tumor cells and Ki67 was positive in about 15% on the tumor cells (Figure 4d).

### Molecular genetic analysis

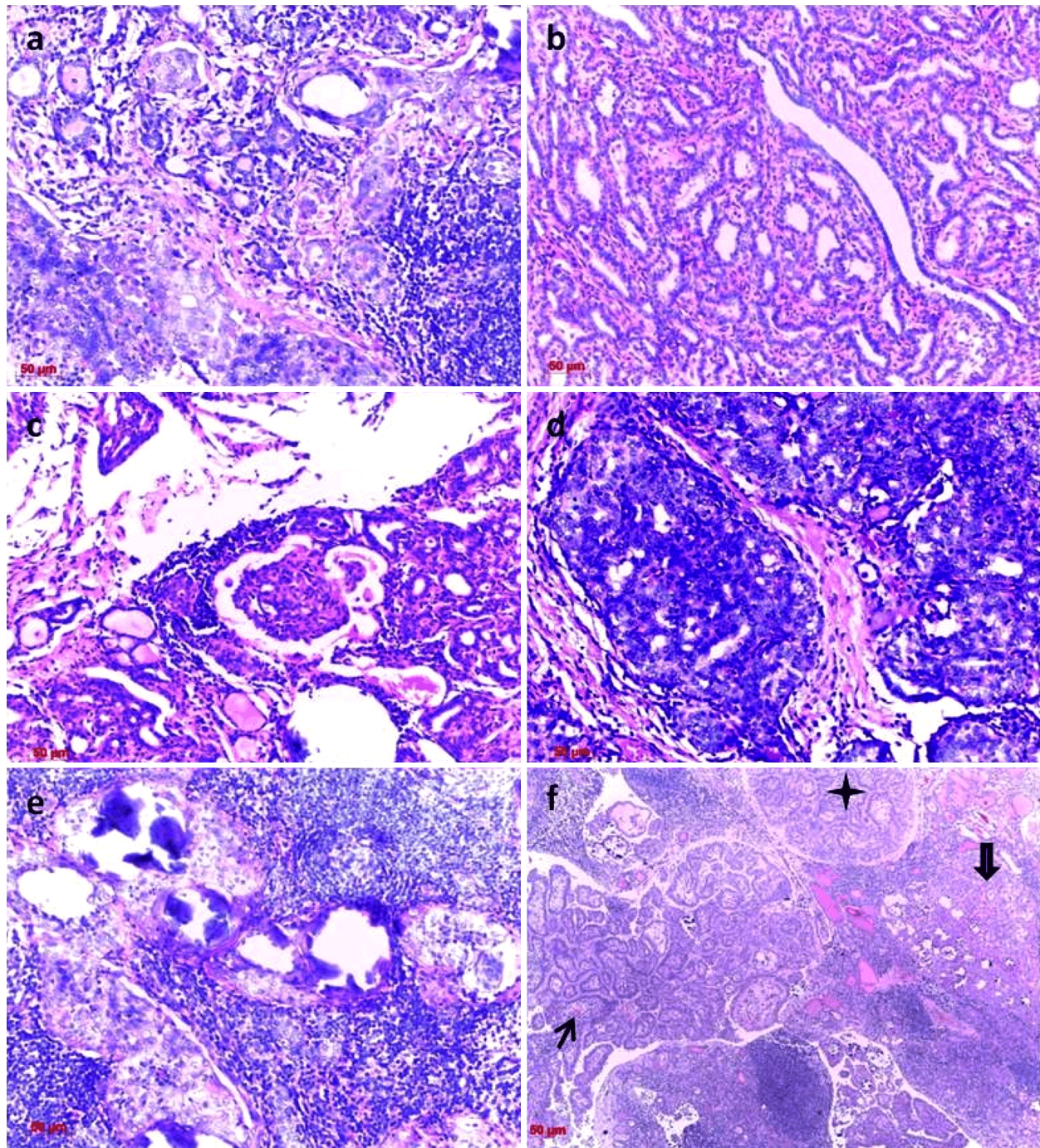
The APC gene was analyzed from blood by PCR (polymerase chain reaction) and sequencing of both DNA strands of the entire coding region and the highly conserved exon intron splice junctions. The reference sequences of the APC gene are: NM\_001127510.2, NM\_001127511.2. MLPA (multiplex ligation-dependent probe amplification) analyses were performed using SALSA MLPA probemix P043 provided by MRC-Holland to test for deletions or duplications within or including the APC gene. For BRAF and RAS genes, analysis the unstained sections were prepared from the paraffin block and tumor area was marked from which DNA was extracted with the WaxFree



DNA kit (BioMedomics, Inc., Research Triangle Park, NC, USA) following the manufacturer's protocol. By a specific PCR reaction, the 15 exon of the BRAF gene was amplified and then applied the sequencing technique. We analyzed K-RAS mutations by PCR-single-strand conformational polymorphism followed by DNA sequencing. Detection of RET/PTC rearrangements was performed from genomic DNA isolated from tumor tissue with High Pure PCR DNA Template-Roche kit according with manufacturer's instructions. The quality of isolated DNA was checked by spectrophotometry (NanoDrop, Thermo Scientific, USA). Detection of RET/PTC was performed

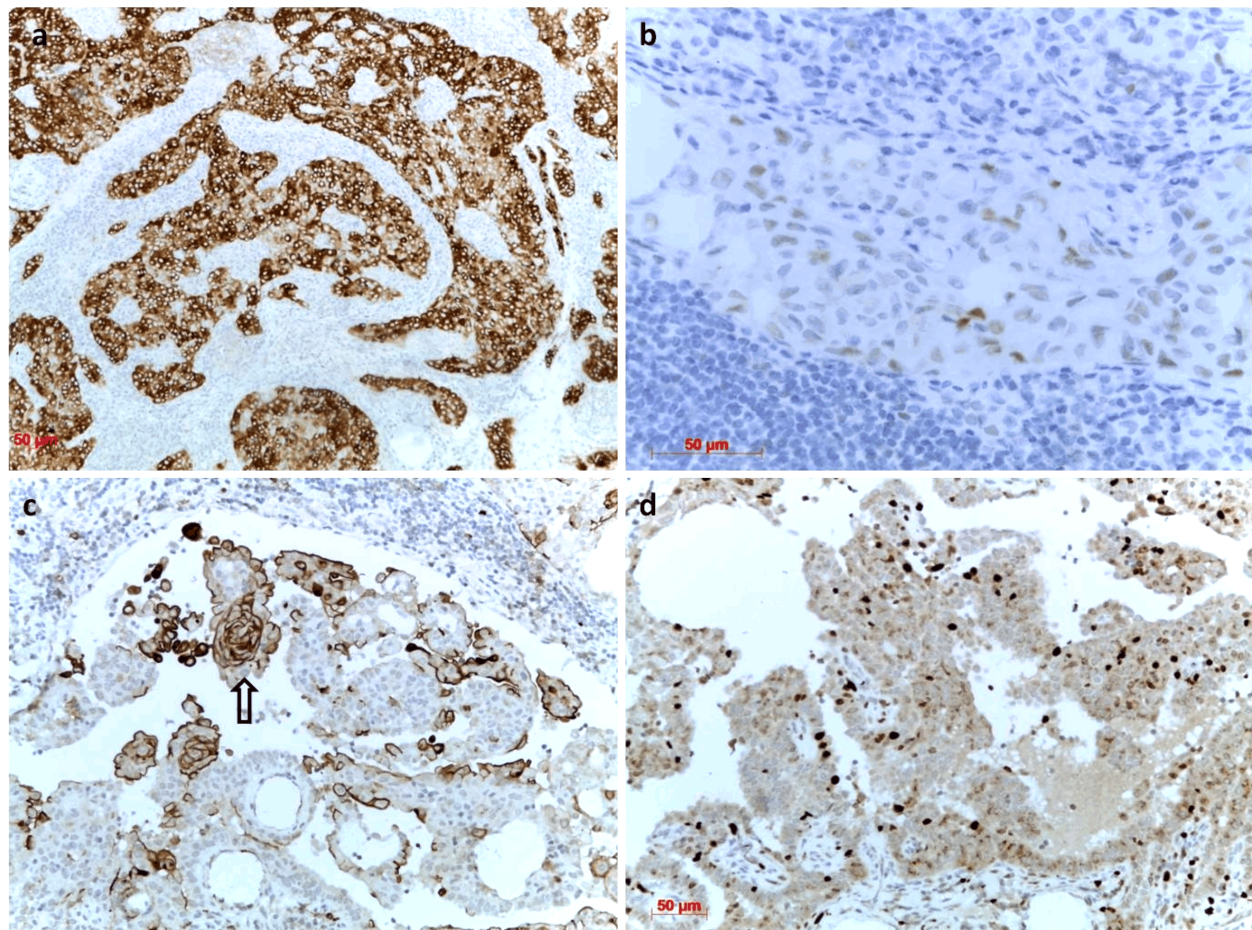
by *in situ* hybridization (FISH) using the procedure on isolated nuclei (Zytovision GmbH, Germany). The molecular tests for detecting beta-catenin mutation were not available.

We detected no pathogenic mutation in the APC gene by sequencing. No large deletions or duplications within or including the APC gene were detected by MLPA analysis. The T1799A BRAF mutation was not found. By sequencing DNA, no mutation at codons 12 and 13 of the KRAS gene was detected. Regarding the detection of RET/PTC rearrangements, we observed the presence of a split FISH signal (rearranged) in 92% of the nuclei analyzed.



**Figure 3 – (a) Microscopic appearance of CMV of PTC with morular (squamoid) areas (HE staining,  $\times 200$ ); (b) Microscopic area of tumor with cribriform pattern (HE staining,  $\times 200$ ); (c) Mixed cribriform and morular patterns of the tumor (HE staining,  $\times 200$ ); (d) Follicular and cribriform aspect of the tumor (HE staining,  $\times 200$ ); (e) Solid areas and calcospherites (HE staining,  $\times 200$ ); (f) Microscopic appearance of CMV of PTC with papillary (narrow arrow), follicular (star) and solid (wide arrow) patterns on the same section (HE staining,  $\times 50$ ).**





**Figure 4** – (a) Immunohistochemical staining for thyroglobulin in tumor cells: the tumor cells presented a diffuse strong expression for thyroglobulin (CMV-PTC) ( $\times 50$ ); (b) Immunohistochemical staining for  $\beta$ -catenin in PTC with cribriform patterns: the tumor cells presented focal positive immunoreactivity for  $\beta$ -catenin ( $\times 400$ ); (c) Immunohistochemical staining for CD10 in tumor cells, morular (squamous) areas (arrow) (CMV-PTC): CD10 was diffuse expressed in tumor cells ( $\times 100$ ); (d) Immunohistochemical staining for Ki67 in 15% of tumor cells (CMV-PTC) ( $\times 200$ ).

## Discussion

TC is rare in children and adolescents: 0.4–5.4 per 1 000 000 [10–15] and usually it is a well-differentiated papillary subtype or a papillary-follicular subtype [16]. Ahn & Park noticed that the histological types found in children and adolescents are papillary (89%) and follicular (7.8%) carcinoma and other types (3.2%) [17]. Koo *et al.* observed that the histological types in young patients are the diffuse sclerosing variant (41.2%), conventional PTC (38.2%), follicular variant (2.9%), and cribriform-morular variants (1.5%) [18].

CMV-PTC is a rare neoplasm described by Harach *et al.*, in 1994, as a particular thyroid carcinoma observed in patients with FAP sometimes preceding the diagnosis of FAP with 4–12 years before colon manifestations [2]. The prevalence of TC in FAP varies from 1 to 2% [19, 20] up to 12% [21, 22]. FAP, an autosomal dominant disorder caused by a germline mutation in the APC gene, is characterized by several hundred or thousands of adenomatous colorectal polyps that could progress to adenocarcinoma and numerous extracolonic manifestations: gastric and upper intestinal adenomas and carcinomas, hepatoblastomas, congenital hypertrophy of the retinal pigment epithelium (CHRPE), osseous tumors, epidermoid cysts in the skin, dental abnormalities, desmoid tumors in the abdominal wall and brain tumors [23–25].

In 1999, Cameselle-Teijeiro & Chan described the cribriform-morular variant (C-MV) of PTC as the sporadic counterpart of FAP-associated thyroid carcinoma representing approximately 0.1–0.2% of all PTC [3, 8]. FAP-associated thyroid tumors have a female predominance (female-to-male ratio of 17:1) and a mean age of 27.65 years [6, 26]. CMV-PTC tumors are encapsulated nodules or well circumscribed and may present capsular and/or vascular invasion [3]. Sporadic cases usually appear as isolated tumors and the forms associated with FAP are often multifocal [2, 27]. This rare variant of thyroid carcinoma is characterized histologically by a combination of cribriform, follicular, papillary, trabecular, solid and spindle cell growth patterns with morular areas [2–5]. Follicular, papillary and trabecular patterns may be observed within the same nodule. The colloid is absent in the lumina of the cribriform areas and psammoma bodies and necrosis are not observed [2, 3]. Squamous morula is different from squamous metaplasia. According to Hirokawa *et al.* morular cells are positive for Bcl-2 and negative or weakly positive for cytokeratin and  $\beta$ -catenin is located either in nucleus or intracytoplasmic [3, 5]. Squamous metaplastic cells are positive for  $\beta$ -catenin and S-100 protein-positive dendritic cells are observed [28]. The differential diagnoses of CMV-PTC are represented by tall cell variant of PTC, columnar cell carcinoma and poorly differentiated carcinoma [29].

According with literature data, on immunohistochemical analysis most tumor cells are positive for the following markers: thyroid transcription factor-1 (TTF1), cytokeratins 7 and 19, vimentin, estrogen and progesterone receptors, Bcl-2, E-cadherin and galectin-3. Also, tumor cells may be focally positive or totally negative for thyroglobulin and negative for calcitonin or cytokeratin 20 [2–5, 30]. CD10 immunostaining is a marker for recognition morules in tumors in which APC/ $\beta$ -catenin pathway is also involved [31]. In our case, the tumor stained positively for thyroglobulin (diffusely positive), CD10,  $\beta$ -catenin, p53 (positive 35% in tumor cells) and Ki67 (positive 15% in tumor cells) (Figure 4).

The molecular mechanisms involved in this variant of PTC are represented by germline or somatic mutation of APC gene and/or somatic mutation of  $\beta$ -catenin (CTNNB1) gene with activation of the Wnt pathway with nuclear and cytoplasmic accumulation of  $\beta$ -catenin [5, 8, 30]. APC gene, a tumor suppressor gene, is located on the long arm of chromosome 5 (5q21–22) and contains 15 exons. There are a various expression patterns depending on the location of the APC mutation. The study of Cetta *et al.* reported that in patients with FAP and CMV of PTC more than 85% of germline mutations of the APC gene were in exon 15. The majority of these germline mutations were before codon 1220 and outside the mutation cluster region (MCR) (codons 1286 to 1513), currently considered the hot spot mutation area [32–37].

Genetic studies revealed that RET/PTC rearrangements were also involved in CMV-PTC [38, 39]. In children and adolescents with PTC it was also observed RET/PTC rearrangements, namely RET/PTC1 [inv(10)(q11.2;q21)] and RET/PTC3 [inv(10)(q11.2;q10)] [40, 41]. In young adults with PTC, the presence of RET/PTC rearrangements was associated with poor prognosis but in children and adolescence with PTC, the relationship between the presence of these rearrangements and clinical outcome require further studies [42]. No BRAF mutations have been described to date through genetic alterations involved in CMV-PTC [8, 23, 30, 43]. BRAF mutations are rare in children and adolescence PTC, unlike the adult PTC where is frequently observed (36–83% of cases) and was associated with an aggressive behavior of PTC [44, 45].

In our case, genetic test showed the absence of BRAF mutation, K-RAS mutation, deletions or duplications within or including the APC gene. However, we observed the presence of RET/PTC rearrangements, showed by a split FISH signal (rearranged) in 92% of the nuclei analyzed.

The long-term prognosis for patients with CMV-PTC is good [34, 46] and the 5- and 20-year survival rates of FAP-associated PTCs have been reported to be 90% and 77%, respectively [34], except an aggressive subtype of CMV-PTC with neuroendocrine differentiation and areas of poorly differentiated carcinoma [8]. Cameselle-Teijeiro *et al.* described a case with neuroendocrine differentiation that was partially positive for chromogranin and synaptophysin and negative for thyroglobulin and calcitonin [8] and Nakazawa *et al.* presented a case of CMV-PTC with transformation into poorly differentiated thyroid carcinoma [47]. From a total of 126 cases reported till now in literature six patients died of neoplasia [2–7, 21, 22, 26, 28, 33–35, 37, 46, 48–53].

The authors of this report present a case of a very rare form of thyroid cancer, the CMV-PTC, which exceptionally occurs at pediatric age. To our knowledge, in the literature it was described only a case of CMV at pediatric age in an 8-year-old girl [54]. The absence of mutations/deletions of the APC gene and the absence of polyps at colonoscopy leads to the conclusion that the patient presents a sporadic counterpart of FAP-associated thyroid carcinoma.

The most common immunohistochemical markers expressed in PTC are p53, E-cadherin and Bcl-2 [55]. Recent evidences show a correlation of vimentin and E-cadherin with metastases and clinical aggressive behavior of PTC [56]. The aggressive behavior of PTC (extra-thyroidal invasion, lymph node metastases and advanced tumor stage at diagnosis) is also associated with BRAF mutation. In our case, the V600E BRAF mutation was negative and overexpression of p53 protein and Ki-67 may explain this behavior. According to Kim *et al.*, overexpression of p53 protein and Ki-67 in PTC is associated with tumor progression. Overexpression of p53 protein was positively associated with extrathyroidal extension, and Ki-67 immunoreactivity was positively correlated with tumor size [57]. On the other hand, at pediatric age at the time of diagnosis, the thyroid carcinoma usually presents in an advanced stage: primary tumor is large, lymph nodes metastases are frequently observed (70% of pediatric patients) and distant metastases are detected 3–4 times more frequently than in adults (10–20% of children) [58]. Thyroid carcinoma at pediatric age has a good prognosis and age is an important factor as regard the recurrence, and studies demonstrate that mortality rate is less than 10% [58, 59].

We report a rare case of papillary thyroid carcinoma occurred at a 10-year-old girl, which due to possible association with FAP should be mentioned. Currently, assessment, treatment and follow-up of children and adolescents with differentiated thyroid carcinoma are performed by protocols developed for adults. However, the differentiated thyroid carcinoma in children and adolescents should be considered as a distinct subtype and a diagnosis protocol for evaluation of thyroid nodules in children and adolescents is necessary to be developed in order to establish a correct diagnosis and an optimal therapy.

## Conclusions

Cribiform-morular variant of papillary thyroid carcinoma is a rare form of PTC, which could be associated with FAP. The diagnosis is assessed on histopathological and immunohistochemical examination. In conclusion, it should be emphasized that this particular form of thyroid carcinoma could raise the suspicion of a possible familial cancer syndrome (FAP). Moreover, CMV-PTC could precede the colonic manifestation, therefore early diagnosis and thoroughly evaluation, which includes colonoscopy and genetic screening are mandatory.

## Conflict of interests

The authors declare that they have no conflict of interests.

### Acknowledgments

We thank Dr. Oana Popa for FISH analysis and Dr. Anda Dumitraşcu for CT scan images.

FISH analysis was funded by the project GENITIR, PCCA2 No. 135/2012.

### References

- [1] DeLellis RA, Lloyd RV, Heitz PU, Eng C (eds). Pathology and genetics of tumours of endocrine organs. World Health Organization (WHO) International Classification of Tumors, International Agency for Research on Cancer (IARC) Press, Lyon, France, 2004.
- [2] Harach HR, Williams GT, Williams ED. Familial adenomatous polyposis associated thyroid carcinoma: a distinct type of follicular cell neoplasm. *Histopathology*, 1994, 25(6):549–561.
- [3] Cameselle-Teijeiro J, Chan JK. Cribriform-morular variant of papillary carcinoma: a distinctive variant representing the sporadic counterpart of familial adenomatous polyposis-associated thyroid carcinoma? *Mod Pathol*, 1999, 12(4):400–411.
- [4] Cameselle-Teijeiro J, Ruiz-Ponte C, Loidi L, Suarez-Peñaranda J, Baltar J, Sobrinho-Simoes M. Somatic but not germline mutation of the APC gene in a case of cribriform-morular variant of papillary thyroid carcinoma. *Am J Clin Pathol*, 2001, 115(4):486–493.
- [5] Xu B, Yoshimoto K, Miyauchi A, Kuma S, Mizusawa N, Hirokawa M, Sano T. Cribriform-morular variant of papillary thyroid carcinoma: a pathological and molecular genetic study with evidence of frequent somatic mutations in exon 3 of the beta-catenin gene. *J Pathol*, 2003, 199(1):58–67.
- [6] Cetta F, Pelizzo MR, Curia MC, Barbarisi A. Genetics and clinicopathological findings in thyroid carcinomas associated with familial adenomatous polyposis. *Am J Pathol*, 1999, 155(1):7–9.
- [7] Soravia C, Sugg SL, Berk T, Mitri A, Cheng H, Gallinger S, Cohen Z, Asa SL, Bapat BV. Familial adenomatous polyposis-associated thyroid cancer: a clinical, pathological, and molecular genetics study. *Am J Pathol*, 1999, 154(1):127–135.
- [8] Cameselle-Teijeiro J, Menasce LP, Yap BK, Colaco RJ, Castro P, Celestino R, Ruiz-Ponte C, Soares P, Sobrinho-Simões M. Cribriform-morular variant of papillary thyroid carcinoma: molecular characterization of a case with neuroendocrine differentiation and aggressive behavior. *Am J Clin Pathol*, 2009, 131(1):134–142.
- [9] Sugg SL, Zheng L, Rosen IB, Freeman JL, Ezzat S, Asa SL. *ret/PTC-1, -2, and -3* oncogene rearrangements in human thyroid carcinomas: implications for metastatic potential? *J Clin Endocrinol Metab*, 1996, 81(9):3360–3365.
- [10] Fridman MV, Savva NN, Krasko OV, Zborovskaya AA, Mankovskaya SV, Kurt Werner S, Demidchik YE. Clinical and pathologic features of “sporadic” papillary thyroid carcinoma registered in the years 2005 to 2008 in children and adolescents of Belarus. *Thyroid*, 2012, 22(10):1016–1024.
- [11] Cho EY, Lee SY, Shin CH, Yang SW. Clinical characteristics of papillary thyroid carcinoma in children and adolescent. *J Korean Soc Pediatr Endocrinol*, 2008, 13(1):65–72.
- [12] Hogan AR, Zhuge Y, Perez EA, Koniaris LG, Lew JI, Sola JE. Pediatric thyroid carcinoma: incidence and outcomes in 1753 patients. *J Surg Res*, 2009, 156(1):167–172.
- [13] Machens A, Lorenz K, Nguyen Thanh P, Brauckhoff M, Dralle H. Papillary thyroid cancer in children and adolescents does not differ in growth pattern and metastatic behavior. *J Pediatr*, 2010, 157(4):648–652.
- [14] Romanchishen AF, Thompson DB, Gostimskii AV. Surgical and postoperative treatment of patients with carcinomas of the thyroid gland in childhood and adolescence. *Vestn Khir Im I I Grek*, 2008, 167(5):55–58.
- [15] Tronko MD, Bogdanova TI, Komissarenko IV, Epstein OV, Oliynyk V, Kovalenko A, Likhtarev IA, Kairo I, Peters SB, LiVolsi VA. Thyroid carcinoma in children and adolescents in Ukraine after the Chernobyl nuclear accident: statistical data and clinicomorphologic characteristics. *Cancer*, 1999, 86(1):149–156.
- [16] Yip FW, Reeve TS, Poole AG, Delbridge L. Thyroid nodules in childhood and adolescence. *Aust N Z J Surg*, 1994, 64(10):676–678.
- [17] Ahn HY, Park YJ. Incidence and clinical characteristics of thyroid cancer in Korea. *Korean J Med*, 2009, 77(5):537–542.
- [18] Koo JS, Hong S, Park CS. Diffuse sclerosing variant is a major subtype of papillary thyroid carcinoma in the young. *Thyroid*, 2009, 19(11):1225–1231.
- [19] Bülow C, Bülow S. Is screening for thyroid carcinoma indicated in familial adenomatous polyposis? The Leeds Castle Polyposis Group. *Int J Colorectal Dis*, 1997, 12(4):240–242.
- [20] Truta B, Allen BA, Conrad PG, Kim YS, Berk T, Gallinger S, Bapat B, Terdiman JP, Sleisenger MH. Genotype and phenotype of patients with both familial adenomatous polyposis and thyroid carcinoma. *Fam Cancer*, 2003, 2(2):95–99.
- [21] Hizawa K, Iida M, Yao T, Aoyagi K, Oohata Y, Mibu R, Yamasaki K, Hirata T, Fujishima M. Association between thyroid cancer of cribriform variant and familial adenomatous polyposis. *J Clin Pathol*, 1996, 49(7):611–613.
- [22] Herraiz M, Barbesino G, Faquin W, Chan-Smutko G, Patel D, Shannon KM, Daniels GH, Chung DC. Prevalence of thyroid cancer in familial adenomatous polyposis syndrome and the role of screening ultrasound examinations. *Clin Gastroenterol Hepatol*, 2007, 5(3):367–373.
- [23] Talbot IC, Burt R, Järvinen H. Familial adenomatous polyposis. In: Hamilton SR, Aaltonen LA (eds). Pathology and genetics of tumours of the digestive system. WHO International Classification of Tumours, IARC Press, Lyon, France, 2000, 120–125.
- [24] Groden J, Thliveris A, Samowitz W, Carlson M, Gelbert L, Albertsen H, Joslyn G, Stevens J, Spirio L, Robertson M, Sargeant L, Krapcho K, Wolff E, Burt R, Hughes JP, Warrington J, McPherson J, Wasmuth J, Le Paslier D, Abderrahim H, Cohen D, Leppert M, White R. Identification and characterization of the familial adenomatous polyposis coli gene. *Cell*, 1991, 66(3):589–600.
- [25] Kinzler KW, Nilbert MC, Vogelstein B, Bryan TM, Levy DB, Smith KJ, Preisinger AC, Hamilton SR, Hedge P, Markham A, Carlson M, Joslyn G, Groden J, White R, Miki Y, Miyoshi Y, Nishishio I, Nakamura Y. Identification of a gene located at chromosome 5q21 that is mutated in colorectal cancers. *Science*, 1991, 251(4999):1366–1370.
- [26] Lee S, Hong SW, Shin SJ, Kim YM, Rhee Y, Jean BI, Moon WC, Oh MR, Lim SK. Papillary thyroid carcinoma associated with familial adenomatous polyposis: molecular analysis of pathogenesis in a family and review of the literature. *Endocr J*, 2004, 51(3):317–323.
- [27] Miyaki M, Iijima T, Ishii R, Hishima T, Mori T, Yoshinaga K, Takami H, Kuroki T, Iwama T. Molecular evidence for multicentric development of thyroid carcinomas in patients with familial adenomatous polyposis. *Am J Pathol*, 2000, 157(6):1825–1827.
- [28] Hirokawa M, Kuma S, Miyauchi A, Qian ZR, Nakasono M, Sano T, Kakudo K. Morules in cribriform-morular variant of papillary thyroid carcinoma: immunohistochemical characteristics and distinction from squamous metaplasia. *APMIS*, 2004, 112(4–5):275–282.
- [29] Volante M, Collini P, Nikiforov YE, Sakamoto A, Kakudo K, Katoh R, Lloyd RV, LiVolsi VA, Papotti M, Sobrinho-Simoes M, Bussolati G, Rosai J. Poorly differentiated thyroid carcinoma: the Turin proposal for the use of uniform diagnostic criteria and an algorithmic diagnostic approach. *Am J Surg Pathol*, 2007, 31(8):1256–1264.
- [30] Jung CK, Choi YJ, Lee KY, Bae JS, Kim HJ, Yoon SK, Son YI, Chung JH, Oh YL. The cytological, clinical, and pathological features of the cribriform-morular variant of papillary thyroid carcinoma and mutation analysis of CTNNB1 and BRAF genes. *Thyroid*, 2009, 19(8):905–913.
- [31] Cameselle-Teijeiro J, Albarte-Lista L, Chiarelli S, Buriticá C, Gonçalves L, González-Cámpora R, Nogales FF. CD10 is a characteristic marker of tumors forming morules with biotin-rich, optically clear nuclei that occur in different organs. *Histopathology*, 2008, 52(3):389–392.
- [32] Cetta F, Montalto G, Gori M, Curia MC, Cama A, Olschwang S. Germline mutations of the APC gene in patients with familial adenomatous polyposis-associated thyroid carcinoma: results from a European cooperative study. *J Clin Endocrinol Metab*, 2000, 85(1):286–292.
- [33] Uchino S, Noguchi S, Yamashita H, Yamashita H, Watanabe S, Ogawa T, Tsuno A, Murakami A, Miyauchi A. Mutational analysis of the APC gene in cribriform-morular variant of papillary thyroid carcinoma. *World J Surg*, 2006, 30(5):775–779.

- [34] Perrier ND, van Heerden JA, Goellner JR, Williams ED, Gharib H, Marchesa P, Church JM, Fazio VW, Larson DR. Thyroid cancer in patients with familial adenomatous polyposis. *World J Surg*, 1998, 22(7):738–742; discussion 743.
- [35] Fenton PA, Clarke SE, Owen W, Hibbert J, Hodgson SV. Cribiform variant papillary thyroid cancer: a characteristic of familial adenomatous polyposis. *Thyroid*, 2001, 11(2):193–197.
- [36] Kameyama K, Mukai M, Takami H, Ito K. Cribiform-morular variant of papillary thyroid carcinoma: ultrastructural study and somatic/germline mutation analysis of the APC gene. *Ultrastruct Pathol*, 2004, 28(2):97–102.
- [37] Subramaniam MM, Putti TC, Anuar D, Chong PY, Shah N, Salto-Tellez M, Soong R. Clonal characterization of sporadic cribiform-morular variant of papillary thyroid carcinoma by laser microdissection-based APC mutation analysis. *Am J Clin Pathol*, 2007, 128(6):994–1001.
- [38] Cetta F, Toti P, Petracci M, Montalto G, Disanto A, Lorè F, Fusco A. Thyroid carcinoma associated with familial adenomatous polyposis. *Histopathology*, 1997, 31(3):231–236.
- [39] Cetta F, Chiappetta G, Melillo RM, Petracci M, Montalto G, Santoro M, Fusco A. The *ret/ptc1* oncogene is activated in familial adenomatous polyposis-associated thyroid papillary carcinomas. *J Clin Endocrinol Metab*, 1998, 83(3):1003–1006.
- [40] Demidchik YE, Saenko VA, Yamashita S. Childhood thyroid cancer in Belarus, Russia, and Ukraine after Chernobyl and at present. *Arq Bras Endocrinol Metabol*, 2007, 51(5):748–762.
- [41] Waguespack SG, Francis GL. Current understanding and treatment of differentiated thyroid cancer in children – a review. *US Endocrinology*, 2010, 6(1):84–91.
- [42] Sassolas G, Hafdi-Nejjari Z, Ferraro A, Decaussin-Petrucci M, Rousset B, Borson-Chazot F, Borbone E, Berger N, Fusco A. Oncogenic alterations in papillary thyroid cancers of young patients. *Thyroid*, 2012, 22(1):17–26.
- [43] Schuetz D, Hoschar AP, Seethala RR, Assaad A, Zhang X, Hunt JL. The T1799A BRAF mutation is absent in cribiform-morular variant of papillary carcinoma. *Arch Pathol Lab Med*, 2009, 133(5):803–805.
- [44] Sobrinho-Simões M, Máximo V, Rocha AS, Trovisco V, Castro P, Preto A, Lima J, Soares P. Intragenic mutations in thyroid cancer. *Endocrinol Metab Clin North Am*, 2008, 37(2):333–362.
- [45] Xing M, Westra WH, Tufano RP, Cohen Y, Rosenbaum E, Rhoden KJ, Carson KA, Vasko V, Larin A, Tallini G, Tolaney S, Holt EH, Hui P, Umbricht CB, Basaria S, Ewertz M, Tufano AP, Califano JA, Ringel MD, Zeiger MA, Sidransky D, Ladenson PW. BRAF mutation predicts a poorer clinical prognosis for papillary thyroid cancer. *J Clin Endocrinol Metab*, 2005, 90(12):6373–6379.
- [46] Tomoda C, Miyauchi A, Uruno T, Takamura Y, Ito Y, Miya A, Kobayashi K, Matsuzuka F, Kuma S, Kuma K, Kakudo K. Cribiform-morular variant of papillary thyroid carcinoma: clue to early detection of familial adenomatous polyposis-associated colon cancer. *World J Surg*, 2004, 28(9):886–889.
- [47] Nakazawa T, Celestino R, Machado JC, Cameselle-Teijeiro JM, Vinagre J, Eloy C, Benserai F, Lameche S, Soares P, Sobrinho-Simões M. Cribiform-morular variant of papillary thyroid carcinoma displaying poorly differentiated features. *Int J Surg Pathol*, 2013, 21(4):379–389.
- [48] Kuma S, Hirokawa M, Xu B, Miyauchi A, Kukudo K, Sano T. Cribiform-morular variant of papillary thyroid carcinoma. Report of a case showing morules with peculiar nuclear clearing. *Acta Cytol*, 2004, 48(3):431–436.
- [49] Chikkamuniyappa S, Jagridar J. Cribiform-morular variant of papillary carcinoma: association with familial adenomatous polyposis – report of three cases and review of literature. *Int J Med Sci*, 2004, 1(1):43–49.
- [50] Dalal KM, Moraitis D, Iwamoto C, Shaha AR, Patel SG, Ghossein RA. Clinical curiosity: cribiform-morular variant of papillary thyroid carcinoma. *Head Neck*, 2006, 28(5):471–476.
- [51] Chung DC, Maher MM, Faquin WC. Case records of the Massachusetts General Hospital. Case 37-2006. A 19-year-old woman with thyroid cancer and lower gastrointestinal bleeding. *N Engl J Med*, 2006, 355(22):2349–2357.
- [52] Rosen EJ, Newlands SD, Rampy BA. Pathology quiz case: cribiform-morular variant of papillary thyroid carcinoma. *Arch Otolaryngol Head Neck Surg*, 2003, 129(6):679–681.
- [53] Chuah KL, Hwang JS, Ng SB, Tan PH, Poh WT, Au VS. Cytologic features of cribiform-morular variant of papillary carcinoma of the thyroid: a case report. *Acta Cytol*, 2005, 49(1):75–80.
- [54] Rossi ED, Revelli L, Martini M, Taddei A, Pintus C, Panunzi C, Fadda G. Cribiform-morular variant of papillary thyroid carcinoma in an 8-year-old girl; a case report with immunohistochemical and molecular testing. *Int J Surg Pathol*, 2012, 20(6):629–632.
- [55] Radu TG, Mogoantă L, Busuioc CJ, Stănescu C, Grosu F. Histological and immunohistochemical aspects of papillary thyroid cancer. *Rom J Morphol Embryol*, 2015, 56(2 Suppl):789–795.
- [56] Calangiu CM, Simionescu CE, Stepan AE, Cernea D, Zăvoi RE, Mărgăritescu C. The expression of CK19, vimentin and E-cadherin in differentiated thyroid carcinomas. *Rom J Morphol Embryol*, 2014, 55(3):919–925.
- [57] Kim BS, Kang KH, Lim YA, Kim LS. Clinical significance of p53, Ki-67 and galectin-3 expressions in papillary thyroid carcinoma. *J Korean Surg Soc*, 2009, 77(1):29–36.
- [58] Alessandri AJ, Goddard KJ, Blair GK, Fryer CJ, Schultz KR. Age is the major determinant of recurrence in pediatric differentiated thyroid carcinoma. *Med Pediatr Oncol*, 2000, 35(1):41–46.
- [59] Jarzab B, Handkiewicz-Junak D. Differentiated thyroid cancer in children and adults: same or distinct disease? *Hormones (Athens)*, 2007, 6(3):200–209.

### Corresponding author

Felix Mircea Brehar, Assistant Professor, MD, PhD, Department of Neurosurgery, “Carol Davila” University of Medicine and Pharmacy, 37 Dionisie Lupu Street, 020022 Bucharest, Romania; Phone +40724–257 549, Fax +4021–334 73 50, e-mail: felixbrehar@yahoo.com

Received: May 10, 2014

Accepted: July 8, 2016