

# Experimental study in order to assess the effects of limited periosteum stripping on the fracture healing and to compare osteosynthesis using plates and screws with intramedullary Kirschner wire fixation

TIBERIU PAUL NEAGU<sup>1,2)</sup>, VALENTIN ENACHE<sup>3)</sup>, ION COCOLOȘ<sup>4)</sup>, MIRELA ȚIGLIȘ<sup>5,6)</sup>,  
 CRISTIAN COBILINSCHI<sup>5,6)</sup>, RADU ȚINCU<sup>5,6)</sup>

<sup>1)</sup>Department of Plastic Surgery and Reconstructive Microsurgery, Emergency Clinical Hospital of Bucharest, Romania

<sup>2)</sup>Clinical Department No. 11, "Carol Davila" University of Medicine and Pharmacy, Bucharest, Romania

<sup>3)</sup>Department of Pathology, Emergency Clinical Hospital of Bucharest, Romania

<sup>4)</sup>Department of Orthopedic Surgery, Emergency Clinical Hospital of Bucharest, Romania

<sup>5)</sup>Department of Anesthesiology and Intensive Care, Emergency Clinical Hospital of Bucharest, Romania

<sup>6)</sup>Clinical Department No. 14, "Carol Davila" University of Medicine and Pharmacy, Bucharest, Romania

## Abstract

There are many studies that investigate indirect and direct fracture healing but few mention the effect of periosteum stripping on consolidation of fractures. Most of these studies use only one method of osteosynthesis for each group. Therefore, we reported a new developed murine model in order to assess if limited periosteum stripping influence significantly the quality of the fracture healing process by comparing two different osteosynthesis methods to reduce simultaneously bilateral femur fractures. We applied the experimental protocol for a number of 12 rats. We used plates and screws to reduce femoral osteotomy for the right hind limb and intramedullary Kirschner wire for the left hind limb. Clinical, radiological and histological assessments were made for a period of eight weeks. The absence of a healthy hind limb led to a slower healing process based on the histological findings and to implant failure based on radiological findings. In summary, complete fracture healing was not achieved during this experimental study. Therefore, we consider that future studies are needed for a better understanding of the effects of periosteum removal on the fracture healing process.

**Keywords:** fracture healing, model, bone plates, femoral fracture, rat.

## Introduction

Current models of fracture repair in rodents have investigated only one method of osteosynthesis for each subject, but none of them have used two different methods on the same subject in order to assess which one leads to better results using the same resources to heal. Many of these studies investigate indirect and direct healing, but few mention the effect of periosteum stripping on fracture healing.

The periosteum plays an important role in bone elongation and modeling during growth and skeletal development, and when the bone is injured it contributes to its recovery with the exception of intra-articular ends and sesamoid bone [1].

Periosteally derived cells are not the only one responsible for bone repair according to recent data [1, 2]. There are a couple of stages during the process of bone healing. First, if there is micromotion or macromotion at the fracture site where the bone fragments are covered with periosteum, endochondral bone repair will take place with a major contribution of the periosteum [1, 3]. Then, a process of proliferation and differentiation of the inner layer periosteal cells will begin. There are two mechanisms of fracture repair when the fracture site is

rigidly reduced or little motion is permitted. The first one occurs when there is no defect between the fragments of the fractured bone and it is named primary bone repair (direct fracture healing). In this case, osteoprogenitor cells come from the Haversian system of the cortex and lamellar bone is produced correctly oriented in a physiological manner. If there is a small defect between the bone heads, lamellar bone will fill the empty space perpendicularly to the bone and afterwards it will remodel to the anatomical position. If the defect is bigger but there are still some parts of the cortical bone in contact, woven bone will fill the gap and become lamellar bone. In this type of repair, there is no cartilage stage as it happens when macromotion is allowed [1].

Therefore, in this paper we reported a new developed murine model in order to assess if limited periosteum stripping influence significantly the quality of the fracture healing process by comparing two different osteosynthesis methods to reduce simultaneously bilateral femur fractures.

## Materials and Methods

The experimental protocol was applied according with the European Council Directive No. 86/609/24 November 1986, the European Convention on the Protection

of Vertebrate Animals (2005) and the Romanian Government Ordinance No. 37/2 February 2002 and with the agreement of the Ethics Committee of “Carol Davila” University of Medicine and Pharmacy, Bucharest, Romania.

### Animals

A total of 12 mature male Brown Norway rats (“Cantacuzino” Institute) were used in order to perform the experimental protocol. Their ages were between nine and 12 months and had a mean weight of 378 g. Animals were fed standard rat food and provided with water. Animals were accommodated in individual cages at constant temperature, using a 12-hour light/dark cycle.

### Anesthesia protocol

Isoflurane (3.5%) inhalation was used for anesthesia induction. In order to maintain the anesthesia we injected intramuscular a cocktail of 0.15 mL Xylazine with 0.4 mL of Ketamine for a 350 g subject and after that we injected 0.1 mL/100 g of Ketamine every 30 to 45 minutes. The eyes were permanently lubricated, we prevented hypothermia, and we monitored the breathing and the skin color during surgery. Preoperative antibiotic prophylaxis (0.1 mL/100 g Synulox) and fluids (1 mL/100 g 0.9% saline) were administered subcutaneously.

### Surgical procedures

After anesthesia, the anterolateral approach of the thigh to the femur was used, dissecting the space between the anterior and the posterior thigh muscles. An oblique shaft osteotomy was performed using a 0.15 mm thick Sabo Sagittal Saw powered by the Stryker Cordless Driver 3 handle.

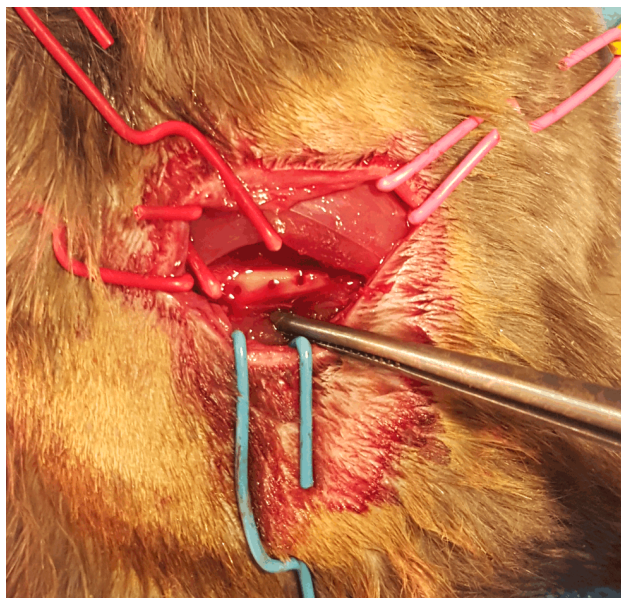
### Osteosynthesis using plate and screws

On the right posterior limb before the fracture was created, four holes were drilled with the aid of the plate using 0.8 mm drill bit powered by a hand-held Stryker Cordless Driver 3 (Figure 1). The spacing between the

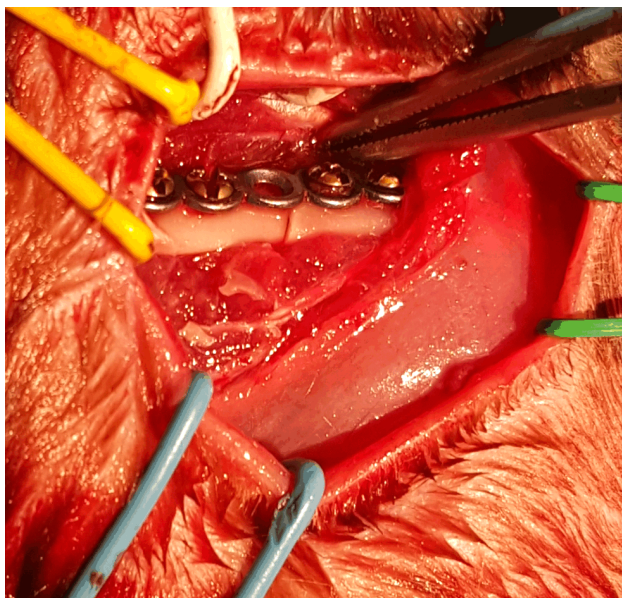
first and the second also the third and the fourth holes were equal, except the spacing between the second and the third which was 0.15 mm greater. We chose this spacing in order to compensate the bone defect that resulted after osteotomy. The periosteum was stripped circumferentially from the femur at the level of osteotomy for the length of 1.5 mm and on the side corresponding to the plate fixation for the length of 15 mm. The osteotomy was performed then aligned manually. Small needles were placed through the five-hole condensed malleable titanium plate measuring 18×1.2×0.5 mm for the first four rats (Figure 2) and through the four-hole standard titanium plate measuring 13×1.2×0.6 mm for the other eight rats (Figure 3). Four 1.2×6 mm to 8 mm self-tapping screws were used. The screws near the fracture site were inserted first and tightened earlier than the other, leaving the third hole free for the five-hole plate. Then the other two holes were filled. The femur was tested manually to assess if there is any movement at the fracture site. There was no mobility observed at surgery in any of the animals. 5-0 Vicryl (ETHICON; Johnson & Johnson Medical Ltd.) was used for wound closure. A spray with patent blue V and Oxytetracycline was used at the surgical site to prevent the rat from self-injuring.

### Osteosynthesis using intramedullary Kirschner wire (K-wire)

On the left posterior limb of the same subject, the periosteum was stripped circumferentially from the femur at the level of osteotomy for the length of 1 mm. The osteotomy was performed. A 25×1.6 mm stainless steel K-wire was inserted in the medullary cavity (Figure 4). After movement at the fracture site, there was insignificant small transverse mobility. 5-0 Vicryl was used for wound closure. A spray with patent blue V and Oxytetracycline was used at the surgical site to prevent the rat from self-injuring.

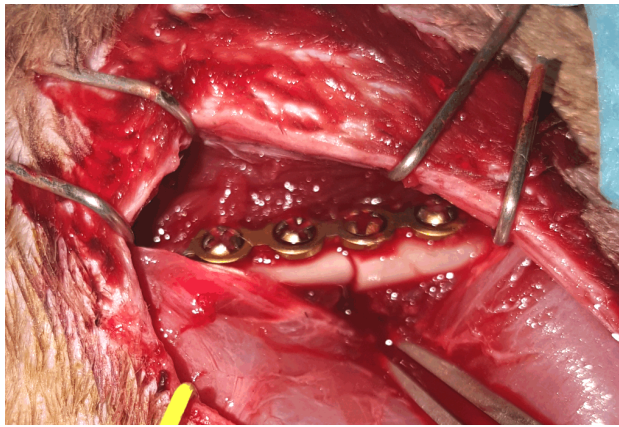


**Figure 1** – Dissection down to the femur, periosteum removal and screw holes drilled.



**Figure 2** – Osteosynthesis using five-hole condensed plate.





**Figure 3 – Osteosynthesis using four-hole plate and screws.**

### Clinical assessment

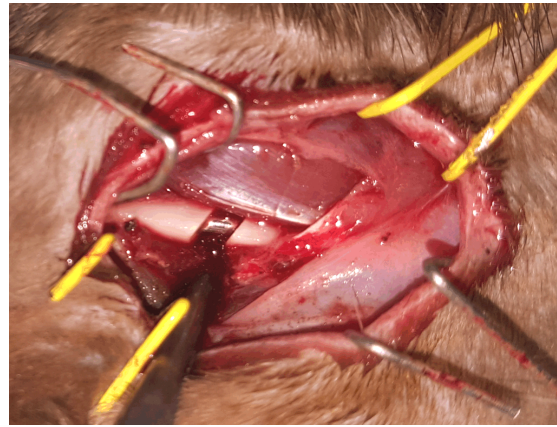
The lab rats were on daily basis monitored for eight weeks. Photos were taken using a digital camera. It was noted which limb was used for support and which was spared or less used, if there were any postoperative complications and movement disabilities. After four and eight weeks, a video recording was made capturing the activities of the rat, the motion of the hind limbs, the ability to climb an oblique grid with a 60° angle. Additionally, the rats were placed in a transparent uncovered water tank to capture the movement of the hind limbs underwater before harvesting the femurs.

### Radiological assessment

Plain anteroposterior radiographs of the healing fractures were obtained immediately after surgery, at two weeks and before harvesting. They were taken using a fixed radiography (RAD) system with an output of 60 kV, 4 mAs and exposure time of 0.1 ms (The Optima™ XR646 GE Healthcare autoRAD system). The radiological aspect of the fracture site was classified as being totally visible – no contact between the fragments, partially visible – when one or two sides of the cortical bone were in contact and absent – when the two segments were welded [4, 5].

### Histological assessment

Both femurs were harvested at four weeks for four rats and only the femur with K-wire for the last four at eight weeks. First four rats with five-hole plate were excluded from the study. Under general anesthesia, a large incision was made and the femur was harvested. The plate and the screws were removed but the K-wire was left inside the medullary cavity to prevent breaking the bone. The femurs were immersed in 10% buffered neutral formalin for 48 hours, at room temperature and then decalcified in 15% nitric acid for 24 hours. Three sets of three longitudinal 4 µm sections at 100 µm distance from each other were obtained using Accu-Cut™ SRM 200 Rotary Microtome, from each specimen and labeled anterior, middle and posterior. After Hematoxylin–Eosin (HE) classical staining was used, the slides were evaluated and photographed using a Compound Microscope Leica DM750 equipped with a Leica ICC 50 W high-definition video camera. It was noted the presence of callus, the type



**Figure 4 – Intramedullary Kirschner wire fixation and periosteum stripping of the fracture site.**

of callus, granulation, inflammatory tissue, necrosis and periosteal cells reaction. The fracture healing stage was noted and classified as hematoma stage (stage 1), inflammatory stage (stage 2), granulation tissue (stage 3), soft callus (stage 4), hard callus (stage 5) and remodeling (stage 6) [6]. With the aid of a grid, the area of inflammatory tissue was measured. Micrographs were captured, stored and analyzed using Adobe Photoshop CC.

## Results

### Plates and screws versus intramedullary K-wire: clinical assessment

All rats survived. There were no post-operative wound complications. The right hind limb with plates and screws was fully functional within 12 hours. The range of motion was normal. The left limb was used for support after 48–72 hours but it was not fully weight bearing. The main support for the rat was given by the right posterior limb. After seven weeks, the right limb was retracted and was no longer used. Most of the weight was supported by the left limb. It was noticed that the range of motion for the right limb in the first four rats where the fracture was reduced using a five-hole condensed plate decreased every day until the limb was no longer used. After the radiological assessment at two weeks, the four rats were excluded from subsequent analysis. At four weeks, the rats were able to climb the oblique grid using both hind limbs but with greater support on the right one (Figure 5). At eight weeks, the anterior limbs were mainly used to climb the grid also with the support of the left hind limb. In the water tank test, the right posterior limb had an average of four complete movements (flexion of the thigh – extension of the calf – flexion of the calf – extension of the thigh) per second and the other limb had an average of two complete movements per second at four weeks. At eight weeks, the left limb had an average of three complete movements per second while the right one had one or two followed by a short pause (Figure 6).

### Plates and screws versus intramedullary K-wire: radiological assessment


The first series of radiographs at two weeks revealed torsion of the plate and lack of contact between the

proximal and distal site of the fracture for the first four rats where we used malleable five-hole plates (Figure 7). These rats were excluded from the study. For the rest of the rats, the fracture site was totally visible for all eight remaining in the study. At four weeks before harvesting, the fracture site was partially visible for both femurs with the presence of external callus where intramedullary fixation was used (Figure 8). No external callus was observed where plating was used. At eight weeks, the proximal screws were loosen and pulled out, therefore there was no contact left between the proximal and distal parts of the femur shaft. The fracture site of the left femur was partially visible with small area of external callus. The osteotomy site was also partially visible for the left femur with K-wire (Figure 9).

### **Plates and screws versus intramedullary K-wire: histological assessment**

We harvested eight femurs with intramedullary fixation at four and eight weeks and four with plates and screws at four weeks (Figure 10). In all animals, the HE classical

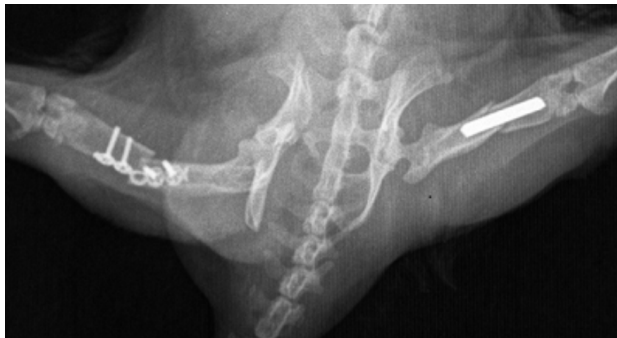staining from all three levels confirmed the radiological findings of lack of hard callus. At four weeks, the area of inflammatory and granulation tissue measured a mean of  $0.01 \text{ cm}^2$  at the healing site of the femurs with plate and screws (Figure 11A), much smaller than the area (Figure 11B) of the femurs with K-wire (a mean of  $0.3 \text{ cm}^2$ ). The group of femurs with K-wire was in the stage of inflammatory tissue (stage 2), which was extensive in the tissue around the fracture site and small areas of granulation tissue (stage 3). Small areas of necrosis inside the medullar cavity were observed. In the group of femurs with plates and screws, small areas of “soft callus” (stage 4), granulation tissue (stage 3) and very few inflammatory reactions were seen using magnification (Figure 12). At eight weeks, only four femurs with K-wire were histologically assessed. A small component of inflammatory tissue in the medullar cavity was observed in all samples (Figure 13) with very few extensions in the surrounding tissue (for only two samples). All of them presented granulation tissue (Figure 14) and only one of them presented “soft callus” (Figure 15).



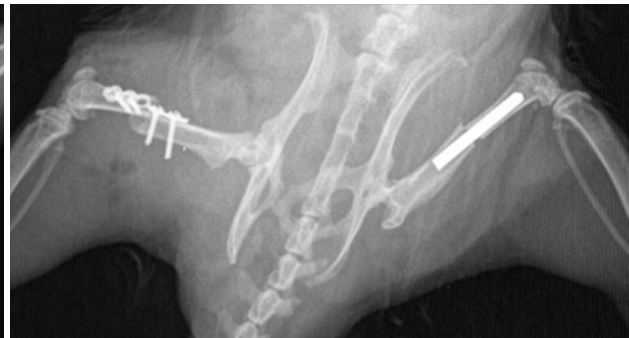**Figure 5** – *The grid test at four weeks after surgery.*



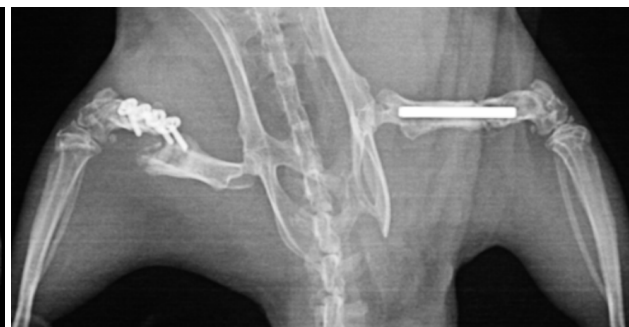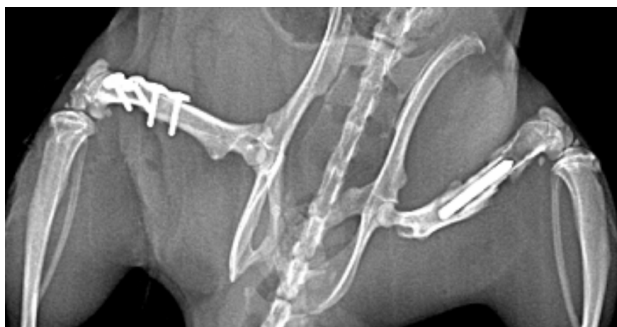**Figure 6** – *Open water tank test after eight weeks.*



**Figure 7** – *Plain radiographs at two weeks revealing torsion of the condensed five-hole plate.*

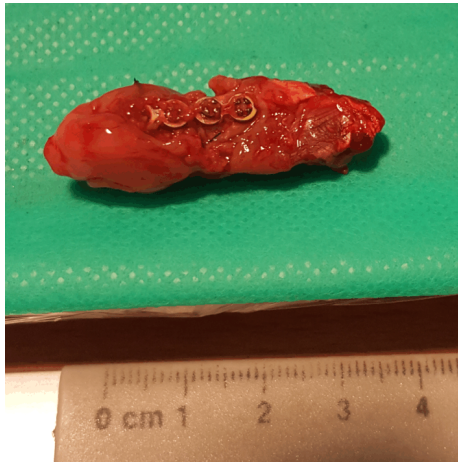


**Figure 8** – *Plain radiographs at four weeks revealing external callus formation where K-wire was used and partially visible fracture site.*

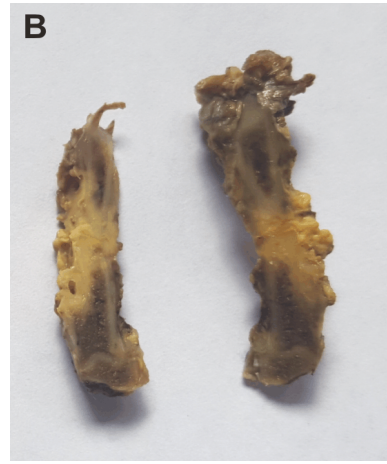
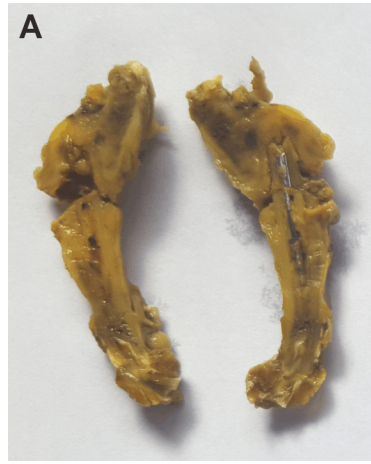
**Figure 9** – *Plain radiographs at eight weeks revealing plate and screws implant failure and callus formation where intramedullary fixation was used.*

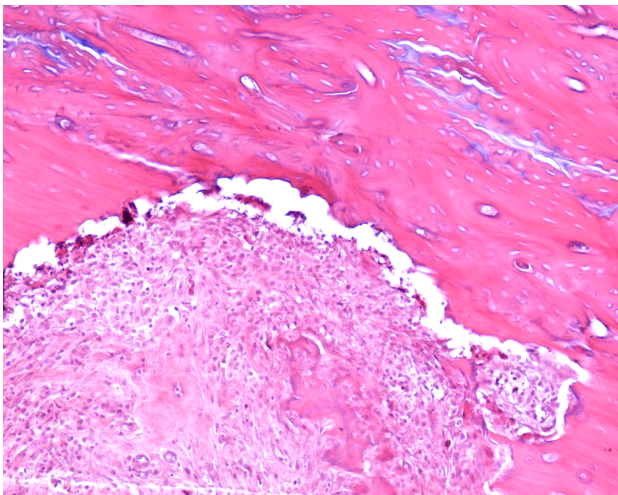




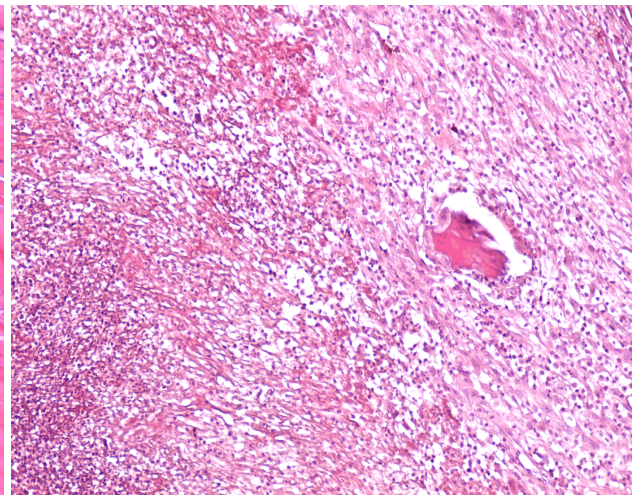
**Figure 10** – Harvested fractured femur reduced by plating after four weeks.



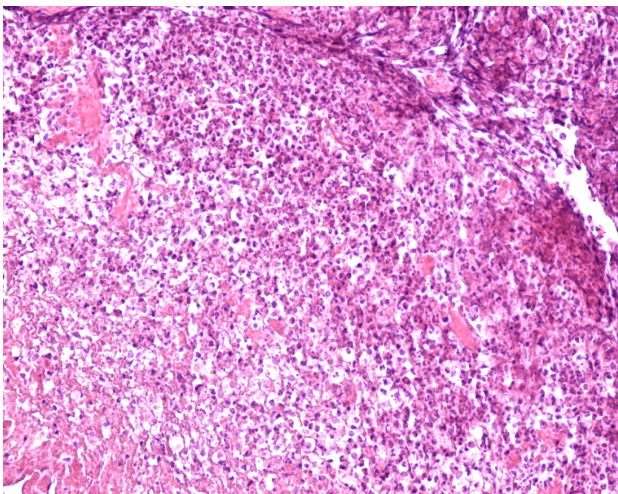
**Figure 11** – The macroscopic aspect of the harvested femurs after demineralization process: (A) K-wire; (B) Plate and screws.



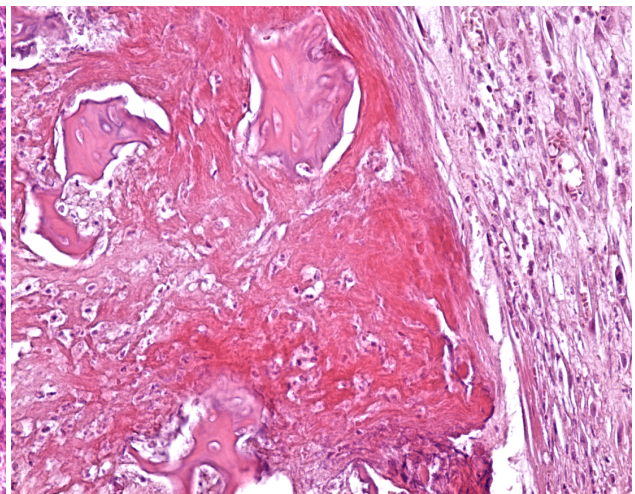
**Figure 12** – Micrograph of longitudinal section through the rat right fractured femur reduced with plate and screws after four weeks (HE staining,  $\times 200$ ). Fracture site with necrotic cortical ends. Areas of soft callus on the internal and external side of cortices.



**Figure 13** – Micrograph of longitudinal section through the rat left fractured femur reduced with intramedullary K-wire at eight weeks (HE staining,  $\times 100$ ). Polymorphous inflammatory tissue inside the medullary cavity, fibrosis and microabscess.



**Figure 14** – Micrograph of longitudinal section through the rat left fractured femur reduced with intramedullary K-wire at eight weeks (HE staining,  $\times 100$ ). Important areas of inflammatory tissue, the end fragments of the cortical bone are in a remodeling process. No hard callus is observed.



**Figure 15** – Micrographs of longitudinal section through the rat left femur reduce with intramedullary K-wire after eight weeks (HE staining,  $\times 100$ ). Presence of soft callus around the fracture site; the white part is a fixation artifact.

## Discussion

The skeletal system astonishes through its complexity and structure, being an architectural wonder. It can be defined in two simple terms, cortical and cancellous bone. The cortical bone offers structural strength and in order to do that, besides its intense mineralization process, it is covered on the inside by the endosteum and on the outside by the periosteum. Regarding the cellular level, the periosteum is thick in children with large cell population and through time, it becomes thinner. It has two layers, one close to the bone rich in young mesenchymal progenitor cells capable of becoming osteoblasts or chondrocytes [7], and one far from the bone rich in collagen fibers that offer additional strength. After the bone is broken, signals are sent in order to start a repairing process by means of endochondral or intramembranous ossification, similar to the ones during histogenesis; these processes are usually altered in patients associating improper mineral-bone metabolism conditions (*e.g.*, chronic kidney disease) [8–13].

The periosteum plays an important role in fracture healing, especially in children. Removing a limited surface of the periosteum may lead to complex regional pain syndrome. It is important to understand the healing process of the bone and associated conditions in order to choose the best therapeutic (surgical procedure) option when you have to deal with a fracture [9–13]. This experimental study was designed in order to compare two osteosynthesis methods, one that involves limited periosteum stripping and one that spares the periosteum, in order to see if periosteum removal influences significantly the quality of the healing.

Using plates and screws offers a good fixation of the fracture in order to regain mobility of the limb. There are experimental studies regarding indirect healing of the fractures, but most of them involve only method of osteosynthesis for each group. In this new developed experimental study, both methods were used on the same rat in order to benefit from the same resources for the healing process, to eliminate individual factors that may influence more or less, such as daily activity, rest and food intake.

This was a study pilot in order to assess if is feasible to apply the experimental protocol to a larger group of rats in order to gain statistical significance. The purpose of the study was to obtain histological proof of which of this two osteosynthesis methods is better, taking into consideration that this techniques are the most often used in order to reduce fractures of the small bones of the hand [14–18]. Therefore, this experimental study was designed for better understanding of the fracture healing and to mimic clinical practice.

We observed that the right hind limb with plate and screws regain its function within 12 hours after surgery, was fully weight bearing and was maintained until the dislocation of the implants, after an average time of seven weeks. The left limb with intramedullary fixation was spared for a couple of days (a mean of three days) and did not regain its full mobility. Plates and screws offered a rigidly fixation allowing the fracture site reduced with K-wire to heal properly with limited usage of the left limb where this technique was performed. Therefore,

the healing of the fractured plated femur was delayed due to the micromotion and macromotion of the bone fragments, as being the only support for the posterior part of the body during movement. The main reasons why the implant was pulled out after seven weeks were the absence of a resting limb and the occurrence of osteolysis around the screws that had loosened, leading to the end of the experimental study.

According to the literature, it takes about twelve weeks in order for the direct fracture healing and callus formation to be completed in the long bone of an adult rat. After that, the biomechanics of the long bone should be similar to the healthy part [2, 19, 20]. The strength proprieties of an injured bone are restored after the remodeling is complete. In order to do that, the injured bone must be aided using osteosynthesis methods that offer rigidity to the fracture site, like plates and screws or locked nails. In plating, the stress and the load is supported by the implant initially and the fracture site is therefore, protected in order to heal properly. Considering this, at six weeks the fracture site will not be healed completely and restored to its original state, even if the clinical aspects say otherwise [2]. Therefore, the implant will be left in place until complete healing occurs.

After radiological assessment, we observed that the osteotomy was partially visible for both methods at four weeks and only for K-wire at eight weeks, because the plate and screws were dislocated and the osteotomy was totally visible and un-reduced. The only difference was that external callus was observed for the femur with intramedullary fixation. Also, implant failure was noted for the first four rats where malleable condensed five-hole plates were used. Torsion and distraction were noted according to the radiological findings at two weeks after surgery. The rats were excluded from the study.

The histological findings proved that the healing process was more advanced and small areas of soft callus were present where the fracture site was reduced using plates and screws. Cartilaginous callus was seen after eight weeks where the K-wire were used, but there was no presence of hard callus.

Plates and screws were used before in other experimental studies in order to reduce femoral fractures in rats [21] and mice. In this experimental models a gap between the two ends of the fractured femur was intentionally created in order to see if atrophic non-union will occur. Even so, the fractured healed with less external callus using this rigidly osteosynthesis method compared to other less rigid fixation techniques [21]. According to Histings *et al.*, during radiological assessment they achieved earlier healing and greater fracture stiffness during a bending test, compared with the control group where an intramedullary K-wire was used. The plate fixation was without compression, therefore small areas of callus were present and no osteonal remodeling units were observed according to the histological findings [19]. The rate of the implant survival was around 80% [5].

In order to obtain osteonal-remodeling units, a new experimental protocol on lab rats was reported, where compression plates were used in order to stimulate direct fracture healing. In this protocol, the periosteum near the fracture site was stripped on each side for one diameter



to preserve the blood supply of the bone provided by the periosteal network [5], despite the findings of Rahn *et al.* and Ashhurst *et al.* who obtained direct healing in rabbits after removing the periosteum on an area twice the diameter of the bone on each side [22].

No matter what osteosynthesis method it will be used, there will always be a minimal iatrogenic traumatic factor that will delay fracture healing, even if its periosteum stripping while using plating or injury of the marrow cavity during intramedullary fixation with K-wire [1].

According to our experimental study, based on the histological proofs we assumed that limited periosteum stripping did not influence significantly callus formation and the quality of the healing process, but on the other hand, hard callus was not achieved through any of the methods because of implant failure after seven weeks.

## ✉ Conclusions

Complete fracture healing was not achieved during this experimental study. In fact, the absence of a healthy hind limb for support led to implant failure and dislocation. Therefore, we consider that this murine model is not the most suitable and reliable protocol in order to assess the effects of periosteum stripping or to compare two osteosynthesis methods on the same rat at the same time. Future studies are needed for a better understanding of the effects of periosteum removal on the fracture healing process.

## Conflict of interests

The authors declare no conflict of interests.

## References

- [1] Dwek JR. The periosteum: what is it, where is it, and what mimics it in its absence? *Skeletal Radiol*, 2010, 39(4):319–323.
- [2] Shapiro F. Bone development and its relation to fracture repair. The role of mesenchymal osteoblasts and surface osteoblasts. *Eur Cell Mater*, 2008, 15:53–76.
- [3] Ferguson C, Alpern E, Miclau T, Helms JA. Does adult fracture repair recapitulate embryonic skeletal formation? *Mech Dev*, 1999, 87(1–2):57–66.
- [4] Blokhuis TJ, de Bruijn JH, Bramer JA, den Boer FC, Bakker FC, Patka P, Haarman HJ, Manoliu RA. The reliability of plain radiography in experimental fracture healing. *Skeletal Radiol*, 2001, 30(3):151–156.
- [5] Savaridas T, Wallace RJ, Muir AY, Salter DM, Simpson AH. The development of a novel model of direct fracture healing in the rat. *Bone Joint Res*, 2012, 1(11):289–296.
- [6] Vigorita VJ. Fracture healing/callus. In: Vigorita VJ (ed). *Orthopaedic pathology*. 2<sup>nd</sup> edition, Lippincott Williams & Wilkins, Philadelphia, 2008, 90–94.
- [7] Murao H, Yamamoto K, Matsuda S, Akiyama H. Periosteal cells are a major source of soft callus in bone fracture. *J Bone Miner Metab*, 2013, 31(4):390–398.
- [8] Squier CA, Ghoneim S, Kremenak CR. Ultrastructure of the periosteum from membrane bone. *J Anat*, 1990, 171:233–239.
- [9] Peride I, Checheriță IA, Smarandache DR, Rădulescu D, Sinescu RD, Niculae A, Pricop C. Vascular calcification in continuous ambulatory peritoneal dialysis patients. *Rom J Morphol Embryol*, 2015, 56(2 Suppl):777–780.
- [10] Checheriță IA, Smarandache D, Rădulescu D, Peride I, Bratu O, Ciocâlțeu A, Sebe I, Lascăr I. Calcific uremic arteriopathy in hemodialyzed patients. *Chirurgia (Bucur)*, 2013, 108(5):736–740.
- [11] Checheriță IA, Smarandache D, David C, Ciocâlțeu A, Ion DA, Lascăr I. Vascular calcifications in chronic kidney disease – clinical management. *Rom J Morphol Embryol*, 2012, 53(1):7–13.
- [12] Checheriță IA, David C, Ciocâlțeu A, Lascăr I, Budală L. Oral treatment of metabolic acidosis in hemodialyzed patients and the implications on the hemodynamic status. *Rom J Morphol Embryol*, 2013, 54(3):539–543.
- [13] Checheriță IA, David C, Diaconu V, Ciocâlțeu A, Lascăr I. Potassium level changes – arrhythmia contributing factor in chronic kidney disease patients. *Rom J Morphol Embryol*, 2011, 52(3 Suppl):1047–1050.
- [14] Houghton D, Jordan D, Malahias M, Hindocha S, Khan W. Principles of hand fracture management. *Open Orthop J*, 2012, 6:43–53.
- [15] Diaz-Garcia R, Waljee JF. Current management of metacarpal fractures. *Hand Clin*, 2013, 29(4):507–518.
- [16] Al-Qattan MM. K-wire fixation for extraarticular transverse/short oblique fractures of the shaft of the middle phalanx associated with extensor tendon injury. *J Hand Surg Eur Vol*, 2008, 33(5):561–565.
- [17] Ozer K, Gillani S, Williams A, Peterson SL, Morgan S. Comparison of intramedullary nailing *versus* plate-screw fixation of extra-articular metacarpal fractures. *J Hand Surg Am*, 2008, 33(10):1724–1731.
- [18] Ouellette EA, Freeland AE. Use of the minicondylar plate in metacarpal and phalangeal fractures. *Clin Orthop Relat Res*, 1996, (327):38–46.
- [19] Histing T, Garcia P, Matthys R, Leidinger M, Holstein JH, Kristen A, Pohlemann T, Menger MD. An internal locking plate to study intramembranous bone healing in a mouse femur fracture model. *J Orthop Res*, 2010, 28(3):397–402.
- [20] McKibbin B. The biology of fracture healing in long bones. *J Bone Joint Surg Br*, 1978, 60-B(2):150–162.
- [21] Mehta M, Schell H, Schwarz C, Peters A, Schmidt-Bleek K, Ellinghaus A, Bail HJ, Duda GN, Lienau J. A 5-mm femoral defect in female but not in male rats leads to a reproducible atrophic non-union. *Arch Orthop Trauma Surg*, 2011, 131(1):121–129.
- [22] Ashhurst DE, Hogg J, Perren SM. A method for making reproducible experimental fractures of the rabbit tibia. *Injury*, 1982, 14(3):236–242.

## Corresponding author

Tiberiu Paul Neagu, Assistant Professor, MD, Department of Plastic Surgery and Reconstructive Microsurgery, Emergency Clinical Hospital of Bucharest, 8 Floreasca Avenue, Sector 1, 01446 Bucharest, Romania; Phone +4021–599 23 00, e-mail: dr.neagupaul@gmail.com

Received: October 10, 2015

Accepted: June 22, 2016