

Diagnostic and therapeutic aspects in malignant sinonasal lymphoma

MIHAIL TUȘALIU^{1,2)}, VIOREL ZAINEA^{1,2)}, CARMEN AURELIA MOGOANȚĂ^{3,4)}, ANA ALEXANDRA DRAGU¹⁾, CRISTINA MARIA GOANȚĂ⁵⁾, MARIA NIȚESCU⁶⁾, MARINA-RUXANDRA OȚELEA⁷⁾, VLAD ANDREI BUDU^{1,2)}

¹⁾“Prof. Dr. Dorin Hociotă” Institute of Phonoaudiology and Functional ENT Surgery, Bucharest, Romania

²⁾Department of Otorhinolaryngology and Ophthalmology, “Carol Davila” University of Medicine and Pharmacy, Bucharest, Romania

³⁾Department of Otorhinolaryngology, Emergency County Hospital, Craiova, Romania

⁴⁾Department of ENT, University of Medicine and Pharmacy of Craiova, Romania

⁵⁾Department of ENT, “Sf. Pantelimon” Clinical Emergency Hospital, Bucharest, Romania

⁶⁾Department of Hygiene and Environmental Health, “Carol Davila” University of Medicine and Pharmacy, Bucharest, Romania

⁷⁾Department of Physiopathology, “Carol Davila” University of Medicine and Pharmacy, Bucharest, Romania

Abstract

Among head and neck malignancies, lymphoma is the second most frequent cause. They can develop in the head and neck lymph nodes or as extranodal determinations. The onset of malignant lymphoma outside of lymph node registers increasingly frequent, currently over 30% of malignant lymphoma are diagnosed as taking place outside the lymph nodes. The aim of this paper is bringing in discussion and the presentation of current elements on the diagnosis and treatment in case of malignant sinonasal lymphoma, a pathological entity with a growing incidence. This study is a retrospective one, from January 2008 through December 2013, and included 31 patients admitted to “Prof. Dr. Dorin Hociotă” Institute of Phonoaudiology and Functional ENT (Ear, Nose & Throat) Surgery, Bucharest, Romania, and diagnosed with malignant sinonasal lymphoma. Despite progress in terms of immunological techniques, cytogenetic and molecular histological outlining of malignant lymphomas, correct diagnosis and appropriate therapy of malignant sinonasal lymphoma is still a problem for the clinician and pathologist, as multidisciplinary collaboration of ENT–Hematology–Pathology–Radiotherapy being essential in this regard.

Keywords: sinonasal malignant lymphoma, interdisciplinary treatment.

Introduction

Malignant lymphomas, defined as neoplasms of lymphoid B- or T-cells, are one of the topical problems of modern medicine. Although Hodgkin’s lymphoma records a stagnation or even a decrease in incidence in recent years, non-Hodgkin’s malignant lymphoma is lately growing by at least 5% per year ranking the 3rd place in terms of growth rate after lung cancer and malignant melanoma [1].

Improving biology and molecular genetics techniques, the contribution of immunohistochemistry and immunophenotyping and the development of new high performance imaging methods have enabled special clarifications regarding the diagnostic accuracy of this pathological entity, allowing the use of the most appropriate course of treatment [2].

Among head and neck malignancies, lymphoma is the second most frequent cause. Although most malignant lymphoma arises in the lymph nodes, the onset of malignant lymphoma outside of lymph nodes is registered increasingly frequent, currently a significant proportion of over 30% of cases having extranodal origin and presenting special pathogenic features, both clinical and therapeutical. This has led this group of lymphoproliferative transformations to be given increased attention in recent years [3, 4].

In literature, malignant lymphoma of the head and neck frequently include ENT (ear, nose & throat) lymphomas. Otorhinolaryngology lymphomas represent an important group of lymphomas with extranodal onset, being 2nd in frequency after digestive lymphomas. Their percentage is 5–10% of non-Hodgkin’s malignant lymphomas, including lymphoproliferation that arise in the Waldeyer’s lymphatic ring, in the nose and paranasal sinuses and in the larynx, the pharynx, the thyroid and the salivary glands. The starting point is the mucosa associated lymphoid tissue (MALT) that is already recognized as being particularly rich in this area [5, 6]. In the pathogenesis of ENT lymphomas, there are many factors involved with the role of antigenic stimulation at this level (especially chronic inflammation), an important role in this aspect being held by viral infectious agents: Epstein–Barr virus, human T-cell leukemia virus type 1 (HTLV-1), human herpesvirus-8 (HHV-8) [7–9].

The purpose of this study is to present and comment on the main elements of diagnosis and treatment in the case of sinonasal malignant lymphoma.

Materials and Methods

This study was a retrospective one and included 31 patients hospitalized between January 2008 and December 2013 in the “Prof. Dr. Dorin Hociotă” Institute of Phono-

audiology and Functional ENT Surgery, Bucharest, Romania, diagnosed with malignant sinonasal lymphoma. For each case, the tumor location, the histological type of lymphoma and elements of treatment conduct were considered, from the surgical point of view, in this case the ENT surgeon, faced with such a pathology.

Immunohistochemical (IHC) staining was carried out

Table 1 – Most important antibodies used for IHC diagnosis

Pathological suspicion	Antibody	Specificity (regarding pathological suspicion)	Clone	Dilution	Source
Large B-cell NHL	CD20	Pan B-cells marker	L26	1:400	Dako, Glostrup, Denmark
	CD30	Activated lymphocytes	Ber H2	1:20	Dako, Glostrup, Denmark
	CD10	Centrofollicular cells	56C6	1:100	Novocastra, Leica, UK
	BCL6	Centrofollicular B-cells	LN22	1:100	Novocastra, Leica, UK
	MUM-1/IF-R4	Activated B-cells	EAU32	1:100	Novocastra, Leica, UK
	Ki67	Proliferation index	MIB-1	1:50	Dako, Glostrup, Denmark
	CD5	Pan T-cell marker; 5% of DLBCL are CD5 positive	4C7	1:50	Novocastra, Leica, UK
Small B-cell NHL (nodular and diffuse)	CD20	Pan B-cells marker	L26	1:400	Dako, Glostrup, Denmark
	CD5	Pan T-cells (positive in some B-cell NHL)	4C7	1:50	Novocastra, Leica, UK
	CD23	Follicular dendritic cells (positive in some B-cell NHL)	1B12	1:50	Novocastra, Leica, UK
	Cyclin D1	Mantle-cell NHL	SP4	1:100	Cell Marque, USA
	CD10	Centrofollicular B-cells	56C6	1:100	Novocastra, Leica, UK
	BCL6	Centrofollicular B-cells	LN22	1:100	Novocastra, Leica, UK
	Ki67	Proliferation index	MIB-1	1:50	Dako, Glostrup, Denmark
	BCL2	Bcl2 oncogene protein	124	1:50	Dako, Glostrup, Denmark
	CD138	Plasma cells	MI15	Prediluted	Novocastra, Leica, UK
	Kappa	Kappa light chain	CH15	1:200	Novocastra, Leica, UK
NK/T-cell NHL	Lambda	Lambda light chain	SHL53	1:200	Novocastra, Leica, UK
	CD3	Pan T-cells marker	LN10	1:500	Novocastra, Leica, UK
	CD56	NK-cells	123C3	1:50	Dako, Glostrup, Denmark
	CD4	Helper T-cells	1F6	1:20	Novocastra, Leica, UK
	CD8	Suppressor/cytotoxic T-cells	1A5	1:20	Novocastra, Leica, UK
	CD25	Activated cells	4C9	1:100	Novocastra, Leica, UK

NHL: Non-Hodgkin's lymphoma; DLBCL: Diffuse large B-cell lymphoma.

Results

Of the 242 patients admitted in our Institute between January 2008 to December 2013 and diagnosed with malignant lymphoma in the field of head and neck, a total of 31 (12.8%) cases experienced a form of lymphoma with sinonasal onset. All 31 cases were composed of non-Hodgkin's malignant lymphomas.

Common clinical situations were different, from ordinary sinusitis with various locations until the aggressive and extensive tumor formations, with orbital invasion and skull base involvement. In terms of macroscopic diagnosis of tumor masses, a complete ENT examination was made, both direct and with rigid endoscopy with 0° and 70° optic or flexible. This allowed detailed morphological examination of difficult to access anatomical areas such as nasal sidewall. Imaging investigations were especially helpful (computerized tomography of cranio-facial sinuses, positron emission tomography, magnetic resonance imaging) to assess the precise location of the tumor and its actual local extension. General clinical examination and functional investigations of the general condition of organs and systems like liver, spleen, gastrointestinal tract, respiratory system, and specific analysis of Hematology services were additionally made.

on paraffin-embedded cross-sections using Novolink™ MaxPolymer (Leica, UK). The panel included many monoclonal antibodies; for each case, the selection of antibodies was made in accordance with pathological diagnostic suspicion after carefully examination of standard Hematoxylin–Eosin (HE)-stained slides (Table 1).

Of the 31 patients, a total of six, representing 19.36%, had some form of malignant lymphoma with nasal onset, three of them, representing 9.62%, had sinus lymphoma, 15 (48.39%) patients had sinonasal malignant lymphoma, four (12.91%) patients had sinonasal malignant lymphoma with the involvement of the orbit, and a total of three (9.62%) patients had a form of malignant sinonasal lymphoma with orbital extension and also of the skull base level.

For all the patients included in the study, various surgeries were performed depending on the location of the tumor and complications caused by it, using a range of techniques and technologies adapted to each case: biopsy of the tumor as a single surgical gesture on seven patients; ablation of the tumoral formation by transmaxillary approach on two patients; excision of the tumor and/or external surgical treatment of the frontal sinusitis on three patients; combined tumor ablation (endoscopic endonasal approach and endonasal approach combined with lateral rhinotomy) on four patients, endoscopic surgical treatment of various forms of complicated sinusitis with or without associated septic events on 17 patients; decompression of vascular or nervous structures on three patients; various hemostasis maneuvers using different technologies

and means (argon plasma coagulation) on one patient (Figure 1).

In immunohistochemical terms, the main histological subtypes that we encountered in the sinonasal malignant

lymphomas were: diffuse large B-cell lymphoma (DLBCL) in 45.16% of cases; small B-cell lymphoma in 19.35% of the cases; peripheral NK/T-cell nasal lymphoma in 35.49% of cases (Figures 2–4).

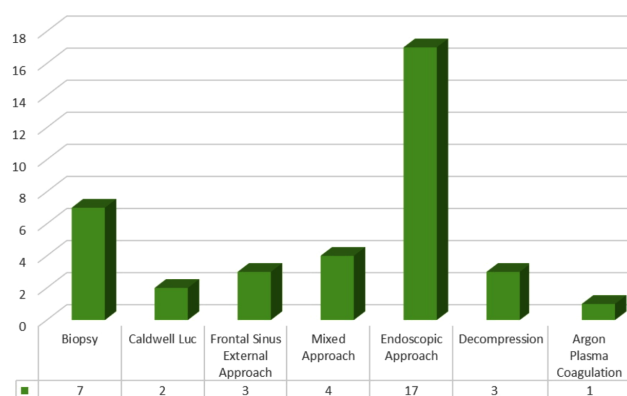


Figure 1 – Surgical procedures performed in sinonasal malignant lymphoma.

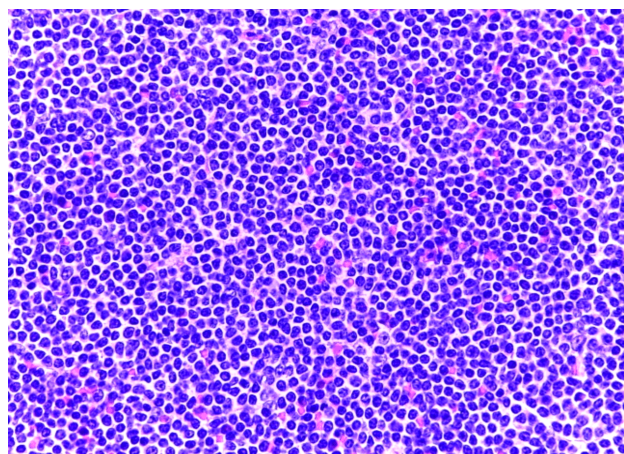


Figure 3 – Small B-cell lymphoma (HE staining, ×400).

Discussion

The clinical and progressive histological heterogeneity onset of sinonasal malignant lymphomas brings into question many aspects of the diagnostic and therapeutic point of view. An essential role for proper management of these lymphoproliferative modifications is in the histopathological and immunohistochemical examinations in detail of the part excised. There are a number of very important techniques in this regard, with a continuous development in recent decades, such as immunophenotypic or immunogenotypic investigation. We can thus distinguish between benign and malignant lymphoproliferations and cell line, the subset and stage of differentiation of malignant lymphocytes [10–12].

Although they are in 2nd place in frequency in ENT, malignant lymphomas with sinonasal onset are still rare, accounting for about 5% of primary extranodal lymphomas. The maxillary sinus is the most common. It represents about 6% of sinonasal tumors [13–15].

Among B-cell lymphomas, diffuse large B-cell lymphoma is the most common by all internationally published studies, which was confirmed in our study as well [16, 17]. The NK/T-cell nasal lymphoma is extremely aggressive,

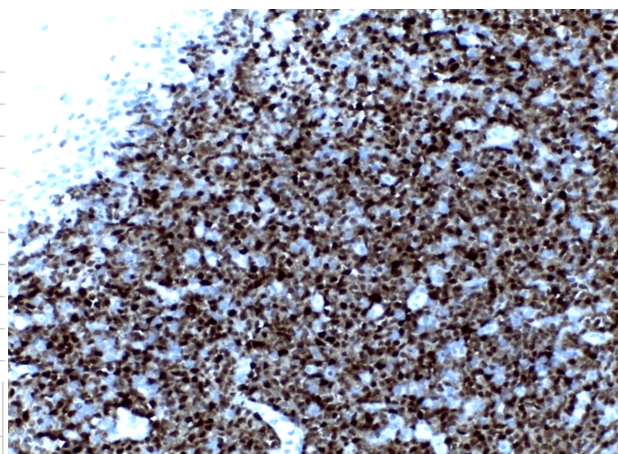


Figure 2 – DLBCL (HE staining, ×200).

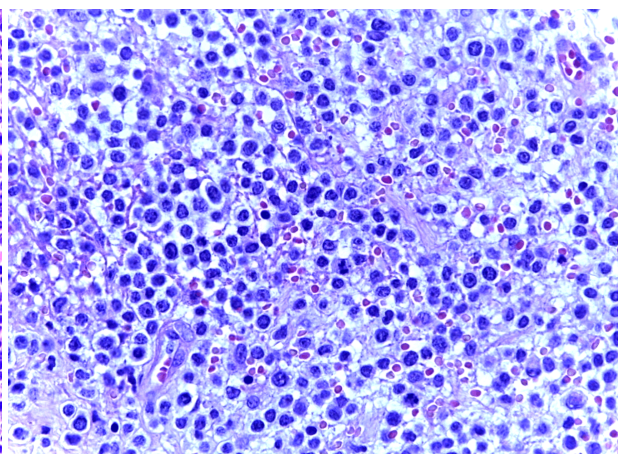


Figure 4 – Nasal cavity, NK/T-cell NHL (HE staining, ×400).

with a tendency to important local extension (especially the orbit, palate and soft parts) and to central nervous system. The B-phenotype is more common in sinus localizations, while T-phenotype is more common in the nasal cavity. Lymphomas developed by T-lymphocyte proliferation frequently evolves with obstructive lesions and with nasal septum perforation [18–20].

In terms of diagnosis, these entities bring important concerns in terms of distinguishing from non-neoplastic diseases of destructive nature (such as Wegener's granulomatosis) or other neoplasms development at this level, due to the association of inflammatory infiltrates with nonspecific neoplastic tissue. It is thus mandatory to collect multiple biopsy fragments from suspicious areas and the size of these fragments must be large enough.

In terms of therapeutic attitude, therapeutic means used were: multi-agent chemotherapy, surgical treatment, radiation therapy and monoclonal antibodies treatment. Although malignant lymphoma is par excellence a blood disease, we found an increasing role of surgical procedures as part of complex multimodal therapy in malignant lymphoma with sinonasal localization. The contribution of surgery was complex: diagnostic, curative ablation, solving complications (video-assisted orbital decompression),

drainage for the control of associated septic phenomena, hemostasis in the remaining area after tumor ablation (using argon plasma coagulation) [21].

An important role in the treatment of certain cases encountered had the Narrow Band Imaging (NBI), a modern diagnostic method useful for the study of the architecture of the surface epithelium and superficial vascularization of the aero-digestive higher tract mucosa [22].

Given the high degree of malignancy of the sinonasal malignant lymphomas, their destructive, invasive and locally extensive and frequent determinations in the central nervous system, most of these cases received radiation therapy treatment more than other localizations, associated with surgery, polychemotherapy and treatment with monoclonal antibodies (mostly Rituximab), which is consistent with data presented in literature [23–27].

✉ Conclusions

Despite advances in immunological techniques, both cytogenetic and molecular, the diagnosis and the histological classification of malignant lymphomas with sinonasal localization is still a problem for the clinician and pathologist. A complex multidisciplinary therapeutic management provides superior results and provides better control over the background lymphatic disease.

Conflict of interests

The authors declare that they have no conflict of interests.

References

- [1] Greer JP, Foerster J, Rodgers GM, Paraskevas F, Glader B, Arber DA, Means RT Jr (eds). Wintrobe's clinical hematology. 12th edition, Lippincott Williams & Wilkins, Philadelphia, 2009, 2071–2130.
- [2] Isaacson PG. The current status of lymphoma classification. *Br J Haematol*, 2000, 109(2):258–266.
- [3] Vlădăreanu AM. Actualități în limfoamele maligne nonhodgkiniene. Ed. Medicală Amaltea, București, 2002, 13–16.
- [4] Oltean G. Limfoamele maligne cu debut extraganglionar. Ed Veritas, Târgu-Mureș, 2001, 112–133.
- [5] Behrbohm H, Kaschke O, Nawka T, Swift A. Ear, nose, and throat diseases with head and neck surgery. Georg Thieme Verlag, Stuttgart, 2009, 398–402.
- [6] Catovsky D, Ralfkiaer E, Müller-Hermelink HK. T-cell pro-lymphocytic leukaemia. In: Jaffe ES, Harris NL, Stein H, Vardiman JW (eds). Pathology and genetics of tumours of haematopoietic and lymphoid tissues. World Health Organization (WHO) Classification of Tumours, International Agency for Research on Cancer (IARC) Press, Lyon, 2001, 195–196.
- [7] Heslop HE. Biology and treatment of Epstein-Barr virus associated non-Hodgkin lymphomas; Oral presentation at 47th Annual Meeting of the American Society of Hematology, Atlanta, Georgia. Hematology Am Soc Hematol Educ Program, 2005: 260–266.
- [8] Taylor GP, Matsuoka M. Natural history of adult T-cell leukemia/lymphoma and approaches to therapy. *Oncogene*, 2005, 24(39):6047–6057.
- [9] Vlădăreanu AM. Limfoamele în corelație cu virusurile limfotrope. Ed. Medicală Amaltea, București, 2007, 159–205.
- [10] Dey P, Amir T, Al Jassar A, Al Shemmari S, Jogai S, Bhat MG, Al Quallaf A, Al Shammari Z. Combined applications of fine needle aspiration cytology and flow cytometric immunophenotyping for diagnosis and classification of non Hodgkin lymphoma. *Cytojournal*, 2006, 3:24.
- [11] Jamal S, Picker LJ, Aquino DB, McKenna RW, Dawson DB, Kroft SH. Immunophenotypic analysis of peripheral T-cell neoplasms. A multiparameter flow cytometric approach. *Am J Clin Pathol*, 2001, 116(4):512–526.
- [12] Kaleem Z. Flow cytometric analysis of lymphomas: current status and usefulness. *Arch Pathol Lab Med*, 2006, 130(12): 1850–1858.
- [13] Han X, Kilfoy B, Zheng T, Holford TR, Zhu C, Zhu Y, Zhang Y. Lymphoma survival patterns by WHO subtype in the United States, 1973–2003. *Cancer Cause Control*, 2008, 19(8):841–858.
- [14] Vose J, Armitage J, Weisenburger D; International T-Cell Lymphoma Project. International peripheral T-cell and natural killer/T-cell lymphoma study: pathology and clinical outcomes. *J Clin Oncol*, 2008, 26(25):4124–4130.
- [15] Laskin JJ, Savage KJ, Voss N, Gascoyne RD, Connors JM. Primary paranasal sinus lymphoma: natural history and improved outcome with central nervous system chemoprophylaxis. *Leuk Lymphoma*, 2005, 46(12):1721–1727.
- [16] Anniko M, Bernal-Sprekelsen M, Bonkowski V, Bradley P, Iurato S (eds). Otorhinolaryngology, head and neck surgery. Springer-Verlag, Berlin–Heidelberg, 2010, 623–628.
- [17] Colomo L, Loong F, Rives S, Pittaluga S, Martínez A, López-Guillermo A, Ojanguren J, Romagosa V, Jaffe ES, Campo E. Diffuse large B-cell lymphomas with plasmablastic differentiation represent a heterogeneous group of disease entities. *Am J Surg Pathol*, 2004, 28(6):736–747.
- [18] Hochberg J, Waxman IM, Kelly KM, Morris E, Cairo MS. Adolescent non-Hodgkin lymphoma and Hodgkin lymphoma: state of the science. *Br J Haematol*, 2009, 144(1):22–40.
- [19] Ellis DW, Eaton M, Fox RM, Juneja S, Leong AS, Miliuskas J, Norris DL, Spagnolo D, Turner J. Diagnostic pathology of lymphoproliferative disorders. *Pathology*, 2005, 37(6):434–456.
- [20] Cheson BD. Staging and evaluation of the patient with lymphoma. *Hematol Oncol Clin North Am*, 2008, 22(5):825–837, vii–viii.
- [21] Tuşaliu M, Zainea V. Indications and surgical techniques in malignant sinonasal lymphomas. *Arch Balkan Med Union*, 2014, 49(1):87–93.
- [22] Kuznetsov K, Lambert R, Rey JF. Narrow-band imaging: potential and limitations. *Endoscopy*, 2006, 38(1):76–81.
- [23] Soutar R, Lucraft H, Jackson G, Reece A, Bird J, Low E, Samson D; Guidelines Working Group of the UK Myeloma Forum; British Committee for Standards in Haematology; British Society for Haematology. Guidelines on the diagnosis and management of solitary plasmacytoma of bone and solitary extramedullary plasmacytoma. *Br J Haematol*, 2004, 124(6): 717–726.
- [24] Elstrom RL, Andreadis C, Aqui NA, Ahya VN, Bloom RD, Brozena SC, Olthoff KM, Schuster SJ, Nasta SD, Stadtmauer EA, Tsai DE. Treatment of PTLN with rituximab or chemotherapy. *Am J Transplant*, 2006, 6(3):569–576.
- [25] Tuşaliu M, Zainea V. Malignant lymphoma with tonsillar onset – comments on a clinical case. *Arch Balkan Med Union*, 2013, 48(4):435–439.
- [26] Liang R. Diagnosis and management of primary nasal lymphoma of T-cell or NK-cell origin. *Clin Lymphoma*, 2000, 1(1):33–37; discussion 38.
- [27] Tuşaliu M, Mogoantă CA, Dobrea CM, Zainea V. Clinical and histological aspects with therapeutic implications in head and neck lymphomas. *Rom J Morphol Embryol*, 2015, 56(2):499–504.

Corresponding author

Mihail Tuşaliu, MD, PhD, “Prof. Dr. Dorin Hociotă” Institute of Phonoaudiology and Functional ENT Surgery, 21 Mihail Cioranu Street, Sector 5, 050751 Bucharest, Romania; Phone: +40729–828 480, e-mail: mtusaliu@yahoo.com