CASE REPORT

RJME
Romanian Journal of Morphology & Embryology
http://www.rjme.ro/

Giant gastrointestinal stromal tumor of the stomach: a challenging diagnostic and therapeutically approach

TIVADAR BARA[1)], IOAN JUNG[2)], SIMONA GURZU[2)], ZOLTÁN KÁDÁR[2,3)], ATTILA KÖVECSI[2)], TIVADAR BARA JR.[1)]

[1)]*Department of Surgery, University of Medicine and Pharmacy of Tirgu Mures, Romania*
[2)]*Department of Pathology, University of Medicine and Pharmacy of Tirgu Mures, Romania*
[3)]*Department of Oncology, University of Medicine and Pharmacy of Tirgu Mures, Romania*

Abstract

Gastrointestinal stromal tumors (GISTs) are rare but challenging tumors regarding the diagnosis and therapy. The symptomatology depends on the tumor size and location, and can be totally non-specific, as in the present case. We present the case of a 76-year-old female that was hospitalized with postprandial nausea and vomiting. Bulging of the posterior wall of the stomach was seen at endoscopically examination and confirmed by the computed tomography. Surgical resection of the 120×100 mm-sized tumor that involved the posterior gastric wall and gastrocolic ligament, was performed; the posterior wall of the stomach was also partially excised. Histological examination revealed a 120×95×70 mm nodular tumor with solid aspect and large necrotic and hemorrhagic area on cut section. The tumor cells were marked by c-KIT, DOG-1, smooth muscle actin and MSH-2 and were negative for Ki67, maspin, E-cadherin, S-100, and keratin AE1/AE3. The resection margins were free of tumor cells. No recurrences were reported three years after surgical intervention; no postoperative chemotherapy was performed. This case highlights that a well-conducted trans-disciplinary approach can have real benefits, even in borderline-operable giant potentially-malignant GISTs. New criteria to establish the malignant potential of GIST should be explored.

Keywords: gastrointestinal stromal tumor, malignant potential, therapy, maspin, E-cadherin, DOG-1.

Introduction

Gastrointestinal stromal tumors (GISTs) are mesenchymal tumors that can occur along the gastrointestinal tract or in the extra-gastrointestinal areas (e-GIST). Clinical symptomatology is determined by the tumor location but unspecific symptoms are frequently reported [1–3].

Most of the papers argue for the origins of GIST from the interstitial Cajal's cells [3] but the role of pluripotent mesenchymal cells was also explored [1]. First report about the heterogeneous origins of the non-epithelial gastric wall tumors was published in 1983 by Mazur & Clark [4]. Since then, several hypotheses were postulated, most of them being based on the focal and heterogenic expression of mesenchymal and epithelial markers such as keratin or E-cadherin [5].

However, despite the well-developed immunohistochemical (IHC) and molecular methods, differentiation of GIST from other tumors such as leiomyoma, epithelioid leiomyoma, schwannoma, and leiomyosarcoma still remains difficult. The rules of classification and criteria of establishing the malignant potential of GIST are constantly modified; the last guideline was published by *World and Health Organization* (WHO) in 2013 [6].

The operative protocol is also under debate, no consensus being established. In some of the papers, it is recommended totally removal of the tumor with free margins of 2 cm while the other researchers advocate for associated-lymphadenectomy and omentectomy [1, 7]. This recommendation is not generally agreed to the fact that malignant GISTs usually present hematogenous spread and lymphatic and peritoneal dissemination is described more rare [1, 2].

In this paper, we present an unusual case of a giant potential malignant-GIST of the posterior gastric wall, which was successfully excised and the patient is free of tumor without additional chemotherapy.

Case report

Clinicopathological data and clinical diagnostic

A 76-year-old previously healthy female presented at Emergency Department with 6-month history of postprandial nausea and vomiting, without other associated symptoms; weight loss, bleeding, and epigastric pain were denied. The patient's weight was of 76 kg; the tallness was of 1.65 m. Except the antihypertensive therapy, no other drugs were used. No personal either familial significant past medical history was noted.

At present admission, the physical examination revealed, at palpation, a huge epigastric tumor. The emergency upper endoscopy showed an intact gastric mucosa and a significant decreasing of the lumen of the stomach. The abdominal computed tomography highlighted a 120×100 mm well-defined nodular tumor that involved the greater curvature of the stomach and the transverse colon. Except a slight anemia (hemoglobin 10.5 g/dL, hematocrit 40.6%), the other serum parameters were within normal limits.

Surgical management and postoperative care

Due to high risk for obstructive phenomenon, an emergency surgical removal of the tumor was decided.

Intraoperatively, it was observed that the tumor, which has a nodular well-defined aspect, involved the posterior wall of the stomach and gastrocolic ligament (Figure 1). However, gastric mucosa and the transverse colon were not involved. Due to huge dimension and high risk of intraoperatively bleeding, although difficult, "en bloc" surgically removal of the tumor and partially resection of the posterior gastric wall was performed (Figure 2). Large parts of the omentum majus and pericolic adipose tissue have been removed, without excision of the colic segments. To avoid postoperatively disorders, two units of blood transfusion and antibiotics were given.

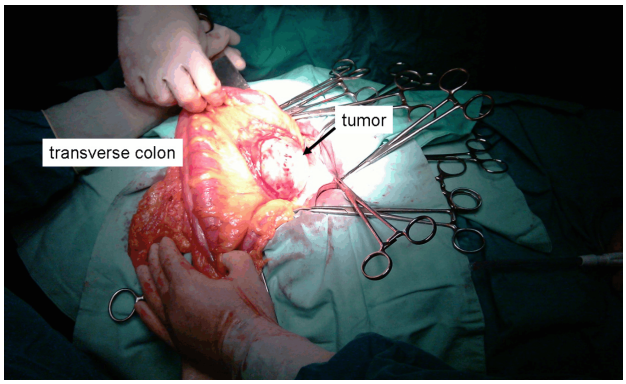

Figure 1 – ***Intraoperative view of the giant gastrointestinal stromal tumor.***

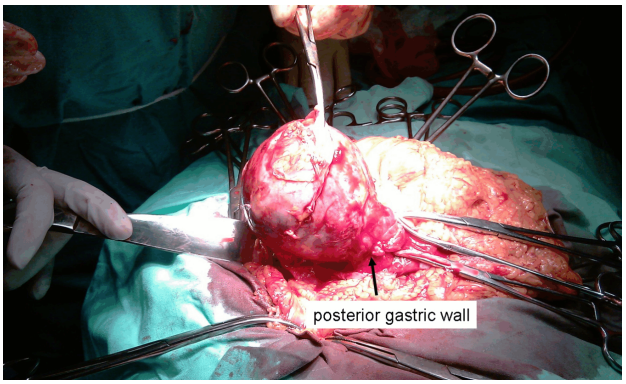

Figure 2 – ***Excision of the giant gastrointestinal stromal tumor partially covered by gastric wall.***

Macroscopically and histological features of the surgical specimen

Gross examination of the surgical specimen revealed a 95×120×70 mm well-defined solid nodular tumor, covered by a 45×30×10 mm-sized gastric mucosa (Figure 3). On cut section, the tumor displayed solid architecture with focal gelatinous areas; large necrotic and hemorrhagic areas were also noted.

Figure 3 – ***Macroscopic aspect of giant gastrointestinal stromal tumor.***

Histopathological examination revealed a tumor that involved the gastric submucosa, muscularis propria, subserosa, and gastrocolic ligament. The covering gastric mucosa was normal, the muscularis mucosae of the stomach was not crossed. The resection margins were free of tumor cells. The tumor architecture was predominantly solid, spindle cells being intermingled with epithelioid areas (Figure 4); the rich stroma was well-vascularized and presented mucoid Alcian blue-dystrophic areas. No necrotic zones were seen inside the tumor clusters; the expanded hemorrhagic areas were observed. The slightly irregular nuclei showed a low mitotic rate (2 mitoses/50 HPF – high-power field).

Immunohistochemical profile of the tumor cells

The tumor cells were diffusely marked by c-KIT (CD117), DOG-1, MLH-1 and MSH-2 (indicators of microsatellite stable status) and vascular endothelial growth factor (VEGF-A) and displayed focal positivity for vimentin, smooth muscle actin (SMA), and CD34. They did not display positivity for S-100 protein, Ki67, maspin, desmin, HER-2, AE1/AE3 keratin, E-cadherin and HMB45. A well-vascularized stroma was emphasized using the endothelial markers CD31 and CD105. No differences among the immunoprofile of the two histological areas were noted (Figure 4).

Based on the clinicopathological and immunohistochemical data, the final diagnosis was GIST with malignant potential. It was mentioned in the histopathological report that the risk of malignant behavior was established based on the tumor size; the microscopic characteristics did not indicate malignant potential. The patient did not receive any postoperative chemotherapy or radiotherapy.

No recurrences, metastases or other clinical disorders were noted after 3-years of follow-up.

Discussion

GISTs represent 1–3% of the tumors of the gastrointestinal tract and are mostly diagnosed in the stomach, more frequent in adults [1, 7–9]. Based on the Fletcher's criteria, GIST is considered to be malignant based on the following characteristics: tumor size >20 mm, presence of large hemorrhagic and necrotic areas, high mitotic rate (>20 mitoses at 50 HPF), and high Ki67 index [3, 6].

The most challenging tumors are those small-sized with high mitotic rate and also GISTs larger than 20 mm that present necrotic and hemorrhagic areas but display a low mitotic rate and R0 margins [10], similar to our case. Based on the last WHO guideline [6], combined to the

most recent data published in the literature [3, 10], the tumor described in this paper is considered to have a high malignant potential (>10 cm-sized, associated-hemorrhages, low mitotic rate, low Ki67).

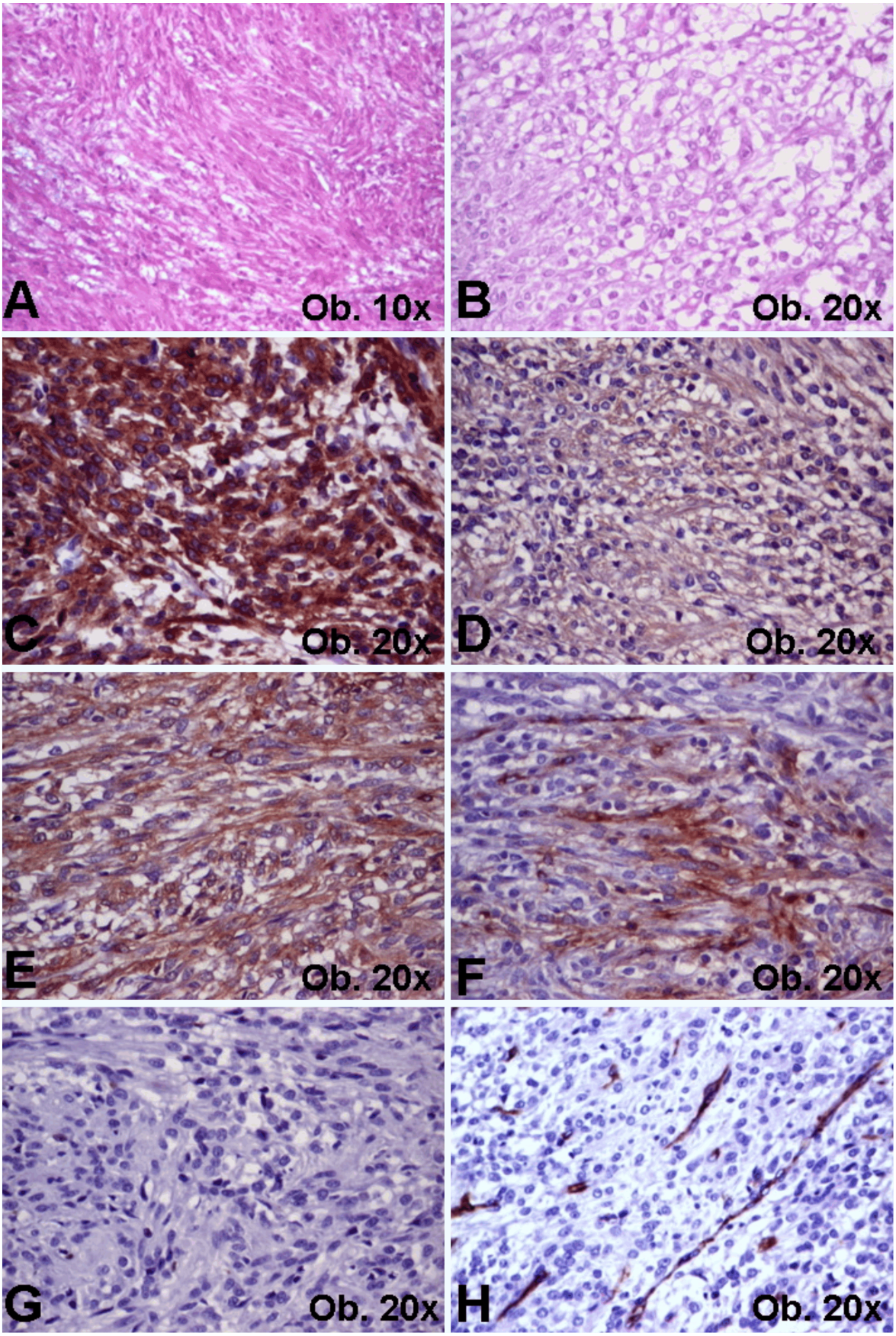

Figure 4 – ***Microscopically features of gastrointestinal stromal tumor. The architecture is partially fusiform (A), partially epithelioid (B). The tumor cells are marked by c-KIT (C), DOG-1 (D), SMA (E), and CD34 (F); they are negative for Ki-67 (G) and CD105 reveals a well-vascularized stroma (H).***

An important aspect is also related to the pathologist. Although necrotic areas were macroscopically identified, they were microscopically seen in only peritumoral stroma, the tumor clusters being free of necroses; this could be a microscopically features which evaluation could be omitted by non-experienced pathologists. Despite of this, no recurrences or metastases occurred in a period of 3-year follow-up period, although postoperative therapy was not added. Based on this aspect and lack of a surgical protocol consensus, it is still very difficult to decide limitation of the therapeutically management to surgical removal or to recommend additional postoperative chemotherapy [11]. Specific criteria used to define the potential aggressiveness of these types of cases would be very useful.

Another aspect regards the differential diagnosis of GISTs, based on their immunoprofile. Although c-KIT and DOG-1 are considered to have a high specificity for GIST [1, 12–14], their immunoreactivity was also described in a broad range of mesenchymal tumors including leiomyosarcomas, tumors with neural origins and Kaposi sarcoma [14–16]. Moreover, c-KIT and DOG-1 positivity is displayed by only 72–99% of the GISTs [7], even more rare in the epithelioid variant that can present atypical phenotype. Although it is considered that differentiation of GIST from liposarcoma and melanoma can be based on DOG-1 positivity, c-KIT being also inconstant positive in these tumors, in some of our cases we noted an unreported DOG-1 positivity in myxoid sarcomas, that include the epithelioid variant, and also in pleomorphic and dedifferentiated liposarcomas (Gurzu *et al.*, personal communication), these aspects increasing the diagnostic difficulty.

Conclusions

Diagnosis and therapeutically protocol of GISTs should be established by a trans-disciplinary team and to be adapted for the clinicopathological and molecular profile of each patient. Despite the utility of molecular methods, the classical examination still remains crucial in establishing the potential malignant behavior, especially in giant GISTs with low mitotic rate and those with epithelioid architecture and unusual immunoprofile. In potential malignant GISTs, long-time patient's follow-up is mandatory, even in R0-non-metastatic cases.

Conflict of interests

The authors declare that they have no conflict of interests.

Acknowledgments

This work was partially supported by the team research project frame POS-UMFTGM-CC-13-01-V01, No. 15/16189/2013 funded by the University of Medicine and Pharmacy of Tîrgu Mureş, Romania, and Studium Foundation.

References

[1] Neagu S, Zărnescu NO, Costea R, Stamatoiu A, Badea V, Dumitrescu C, Grădinaru S, Sajin M, Ardeleanu C, Pelmuş M. Gastric stromal tumors – clinical and histopathological analysis of four cases. Chirurgia (Bucur), 2003, 98(5):443–451.
[2] DeMatteo RP, Lewis JJ, Leung D, Mudan SS, Woodruff JM, Brennan MF. Two hundred gastrointestinal stromal tumors: recurrence patterns and prognostic factors for survival. Ann Surg, 2000, 231(1):51–58.
[3] Pleşea IE, Chiuţu L, Bordu SI, Georgescu I, Georgescu EF, Ciobanu D, Mărgăritescu ND, Comănescu V, Nemeş R. Gastrointestinal stromal tumors – a clinical-morphological study on 15 cases. Rom J Morphol Embryol, 2014, 55(2 Suppl):513–523.
[4] Mazur MT, Clark HB. Gastric stromal tumors. Reappraisal of histogenesis. Am J Surg Pathol, 1983, 7(6):507–519.
[5] Liu S, Liao G, Ding J, Ye K, Zhang Y, Zeng L, Chen S. Dysregulated expression of Snail and E-cadherin correlates with gastrointestinal stromal tumor metastasis. Eur J Cancer Prev, 2014, 23(5):329–335.
[6] Fletcher CDM, Bridge JA, Hogendoorn PCW, Mertens F (eds). Pathology and Genetics of Tumours of Soft Tissue and Bone. 4th edition, World Health Organization (WHO) Classification of Tumours, International Agency for Research on Cancer (IARC) Press, 2013.
[7] Popescu I, Andrei S. Gastrointestinal stromal tumors. Chirurgia (Bucur), 2008, 103(2):155–170.
[8] Bauer S, Corless CL, Heinrich MC, Dirsch O, Antoch G, Kanja J, Seeber S, Schütte J. Response to imatinib mesylate of a gastrointestinal stromal tumor with very low expression of KIT. Cancer Chemother Pharmacol, 2003, 51(3):261–265.
[9] Scherübl H, Faiss S, Knoefel WT, Wardelmann E. Management of early asymptomatic gastrointestinal stromal tumors of the stomach. World J Gastrointest Endosc, 2014, 6(7):266–271.
[10] Yanagimoto Y, Takahashi T, Muguruma K, Toyokawa T, Kusanagi H, Omori T, Masuzawa T, Tanaka K, Hirota S, Nishida T. Re-appraisal of risk classifications for primary gastrointestinal stromal tumors (GISTs) after complete resection: indications for adjuvant therapy. Gastric Cancer, 2014, 18(2):426–433.
[11] Demetri GD, Benjamin RS, Blanke CD, Blay JY, Casali P, Choi H, Corless CL, Debiec-Rychter M, DeMatteo RP, Ettinger DS, Fisher GA, Fletcher CD, Gronchi A, Hohenberger P, Hughes M, Joensuu H, Judson I, Le Cesne A, Maki RG, Morse M, Pappo AS, Pisters PW, Raut CP, Reichardt P, Tyler DS, Van den Abbeele AD, von Mehren M, Wayne JD, Zalcberg J; NCCN Task Force. NCCN Task Force report: management of patients with gastrointestinal stromal tumor (GIST) – update of the NCCN clinical practice guidelines. J Natl Compr Canc Netw, 2007, 5(Suppl 2):S1–S29; quiz S30.
[12] de Silva CMV, Reid R. Gastrointestinal stromal tumors (GIST): C-kit mutations, CD117 expression, differential diagnosis and targeted cancer therapy with Imatinib. Pathol Oncol Res, 2003, 9(1):13–19.
[13] Gleeson FC, Kipp BR, Kerr SE, Voss JS, Graham RP, Campion MB, Minot DM, Tu ZJ, Klee EW, Lazaridis KN, Henry MR, Levy MJ. Kinase genotype analysis of gastric gastrointestinal stromal tumor cytology samples using targeted next-generation sequencing. Clin Gastroenterol Hepatol, 2014, 13(1):202–206.
[14] Hemminger J, Iwenofu OH. Discovered on gastrointestinal stromal tumours 1 (DOG1) expression in non-gastrointestinal stromal tumour (GIST) neoplasms. Histopathology, 2012, 61(2):170–177.
[15] Hwang DG, Qian X, Hornick JL. DOG1 antibody is a highly sensitive and specific marker for gastrointestinal stromal tumors in cytology cell blocks. Am J Clin Pathol, 2011, 135(3): 448–453.
[16] Gurzu S, Ciortea D, Munteanu T, Kezdi-Zaharia I, Jung I. Mesenchymal-to-endothelial transition in Kaposi sarcoma: a histogenetic hypothesis based on a case series and literature review. PLoS One, 2013, 8(8):e71530.

Corresponding author
Simona Gurzu, Associate Professor, MD, PhD, Department of Pathology, University of Medicine and Pharmacy of Tîrgu Mureş, 38 Gheorghe Marinescu Street, 540139 Tîrgu Mureş, Romania; Phone +40745–673 550, e-mail: simonagurzu@yahoo.com

Received: January 17, 2015 *Accepted: December 28, 2015*