ORIGINAL PAPER

RJME
Romanian Journal of Morphology & Embryology
http://www.rjme.ro/

Imaging and histopathological aspects in aseptic osteonecrosis of the femoral head

MAGDALENA-RODICA TRĂISTARU[1)], DIANA KAMAL[2)], KAMAL CONSTANTIN KAMAL[3)], OTILIA CONSTANTINA ROGOVEANU[1)], MIHAI POPESCU[4)], SIMONA BONDARI[4)], DRAGOŞ OVIDIU ALEXANDRU[5)], NINA IONOVICI[6)], DAN CRISTIAN GRECU[7)]

[1)] *Department of Physical Medicine and Rehabilitation, University of Medicine and Pharmacy of Craiova, Romania*

[2)] *Research Center for Microscopic Morphology and Immunology, University of Medicine and Pharmacy of Craiova, Romania*

[3)] *Department of Family Medicine, University of Medicine and Pharmacy of Craiova, Romania*

[4)] *Department of Medical Imaging, Emergency University County Hospital, Craiova, Romania; University of Medicine and Pharmacy of Craiova, Romania*

[5)] *Department of Informatics, University of Medicine and Pharmacy of Craiova, Romania*

[6)] *Department of Labor Medicine, University of Medicine and Pharmacy of Craiova, Romania*

[7)] *Department of Orthopedics and Traumatology, University of Medicine and Pharmacy of Craiova, Romania*

Abstract

Aseptic osteonecrosis causes various clinical manifestations, depending on its location, but has in common a histopathological and radiological substrate. Aseptic osteonecrosis of the femoral head is a condition whose pathogenesis remains unclear despite many theories developed so far, and the discovery of numerous risk factors. The objective of this study is to emphasize the role of imaging techniques and correlating histology and immunohistochemistry methods in order to more accurately stage the disease. This retrospective study was performed on a total of 103 patients with clinical and radiological suspicion of unilateral or bilateral osteonecrosis. For the diagnosis criteria, we used clinical information, pelvic X-ray images, magnetic resonance imaging (MRI) or computed tomography (CT). For the inclusion of patients in a disease stage, we used the *Association Research Circulation Osseous* (ARCO) classification system. For patients diagnosed at an advanced stage, who underwent hip arthroplasty, we harvested biological material necessary for the histopathological study. There were differences in the appearance and extent of the lesion on the histological samples compared to macroscopic examination and even those obtained through imaging means, particularly for patients in evolutionary stage III. Aspects such as the extension of the area of fibrosis, bone tissue remodeling, the density of the newly formed vascular network and degree of impairment of the cartilage, are determined more accurately using histology and immunohistochemistry techniques. Before classifying patients in a certain stage, after correlating clinical and imaging data, histopathological aspects have to be considered, particularly in patients in stages III and IV, in which total hip arthroplasty could be delayed.

Keywords: osteonecrosis, MRI, histopathological aspects.

Introduction

Aseptic osteonecrosis causes various clinical manifestations, depending on its location, but has in common a histopathological and radiological substrate. Aseptic osteonecrosis of the femoral head is a condition whose pathogenesis remains unclear despite many theories developed so far, and the discovery of numerous risk factors [1]. Because the disease predominantly affects individuals aged 30–50 years, active from a socio-professional standpoint, early stage diagnosis and treatment based on a correct staging are desired goals that any clinician has when dealing with a case of aseptic osteonecrosis of the femoral head [2, 3].

The first step in diagnosing this disease is the early use, even before a suspicion of the disease, of imaging techniques such as X-rays, magnetic resonance imaging (MRI), computed tomography (CT), single photon emission computed tomography (SPECT). Depending on their result, we can have a thorough staging, based on which, we will decide the therapeutic approach [1].

Plane radiographic sensitivity for detection in the early stages of the disease is low. MRI is a non-invasive imaging technique with the highest degree of specificity and sensitivity used in the diagnosis of aseptic necrosis of the femoral head [4–8]. Radiographic, aseptic necrosis shows a common element – the evolutionary emergence of a well-defined condensation area, or isolated in a peripheral area of low intensity. MRI – allows early diagnosis of osteonecrosis, even in infra-radiological stages. CT is a very useful assessment tool in later stages, for determining the extent of the lesions such as sclerosis and other events occurring in the state of repair. CT provides a detailed analysis of the morphological aspects.

Regarding the staging systems, over time, many have been proposed, but each of them failed to satisfy all the requirements of practitioners and researchers. Currently, there are more than 16 different known systems of staging the disease, but many of them showing common elements [9, 10]. The therapeutic algorithm depends on the disease stage, location, size and extension degree of the necrosis, associated risk factors and age [1].

The objective of this paper is to emphasize the role of imaging techniques and correlate histology and immunohistochemistry methods in order to more accurately stage the disease, and the application of optimal therapeutic means.

Materials and Methods

This retrospective study was performed on a total of 103 patients with clinical and radiological suspicion of unilateral or bilateral osteonecrosis, hospitalized in the Department of Orthopedic Traumatology, Emergency University County Hospital of Craiova, Romania. Patients were subsequently examined using magnetic resonance in the Department of Radiology and Medical Imaging at the same Hospital and/or various diagnostic imaging centers in Craiova, in the period July 2010–June 2015. Some cases were further investigated using CT.

Magnetic resonance imaging examination was performed with 1–1.5 Tesla apparatus and used the "body" antenna type that allowed evaluating symmetrical comparison of the two hip-femoral joints. Image acquisition was carried out in the coronal, sagittal and native axial plane and sometimes post-contrast to further characterize the morphology of the hip joint. The protocol used for all patients included in the study consisted in acquiring the following planes: coronal T1, T2, news, axial T2/PD, optional 3D sagittal T2 and T1 post-contrast.

CT scans were totally random and consisted of native evaluation of the hip joints. Radiographic examinations – pelvic X-rays, constituted the starting point of imaging investigations of these patients or were conducted during the evolution of the disease for correlation of MRI or CT. We used the *Association Research Circulation Osseous* (ARCO) classification system for staging patients [9].

From the patients in an advanced stage of the disease, who could not benefit from conservative treatment and who underwent hip replacements surgery, we harvested biological material at the femoral neck, both in the lesion area and from the adjacent areas.

The biological material represented by the bone fragments was processed for the use of conventional histology and immunohistochemical techniques. It was first decalcified, using classical histological methods, Hematoxylin–Eosin (HE) and Goldner–Szekely (GS) trichromic staining, respectively, to view microscopic aspects of the lesions and to evaluate its extension to adjacent areas.

Depending on the images obtained using these methods, we selected samples to immunohistochemically highlight tissue antigens. The method used was a two-staged one based on a polymer network visualization system (Dako EnVision). Immunohistochemistry technique itself comprised a standard algorithm. The antibody used for immunohistochemical study to highlight the macrophage reaction was represented by CD68 (monoclonal antibody, clone KP1, 1:50 dilution, Dako manufacturer).

For each patient in the study we created a complete imaging audit of the lesions, in conjunction with the clinical context. We analyzed the cases with osteonecrosis modifications in the hip joint, and correlated the data with the histopathological aspects. Finally, we compared the extension of the actual injuries at the femoral neck, and checked the accuracy of the imaging methods used to diagnose the disease, on which the staging and treatment methods are based on.

Note that this study has obtained the approval of the Scientific Ethics and Deontology Commission from the University of Medicine and Pharmacy of Craiova.

Results

We included a total of 103 patients in the study, aged between 23 and 62 years, with a mean age of 46.29 years. 42.04% of patients were from rural areas and 57.96% in urban areas. Of the 103 patients, 81 were men and 22 women.

Yearly repartition of admissions was the following: in 2011 a total of 13 patients hospitalized with this diagnosis; in 2012 – 24 patients, 21 patients in 2013, in 2014 there were a number of 28 patients and 17 patients in 2015.

The non-invasive imaging means used for diagnosing aseptic osteonecrosis of the femoral head were: plane radiographs on all patients both in anterior and posterior incidence. In 42.71% of patients, nuclear magnetic resonance was used, and in 13.58% we used computer tomography.

Following the imaging results regarding the location of the lesion at the femoral neck and hip joint and the extent of the damage in those areas and correlating them with clinical data, we staged patients using the ARCO classification system (Figures 1–3).

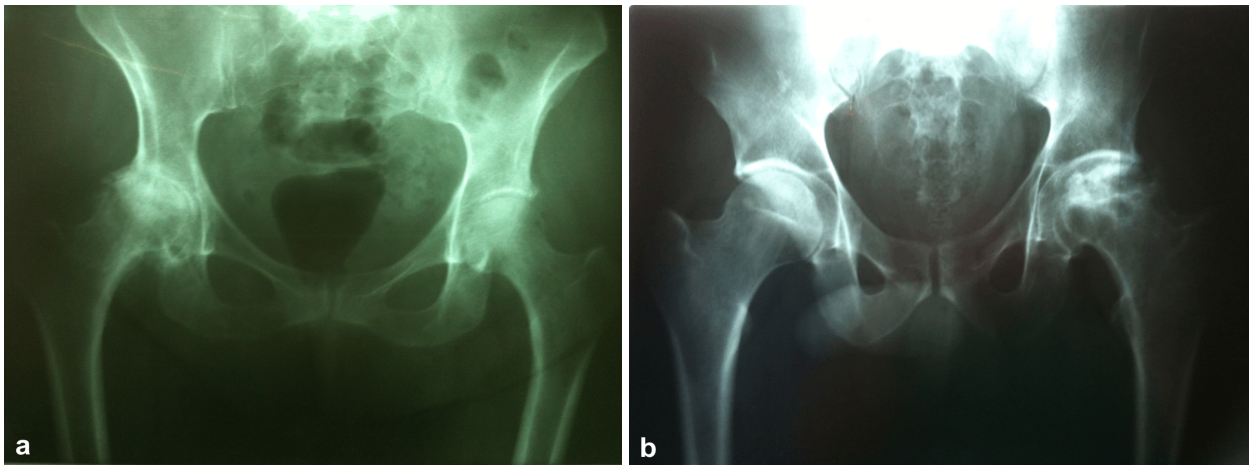

Figure 1 – ***Radiographic appearance. Bilateral aseptic osteonecrosis stage IV left and stage VI right (a) and unilateral stage V left (b).***

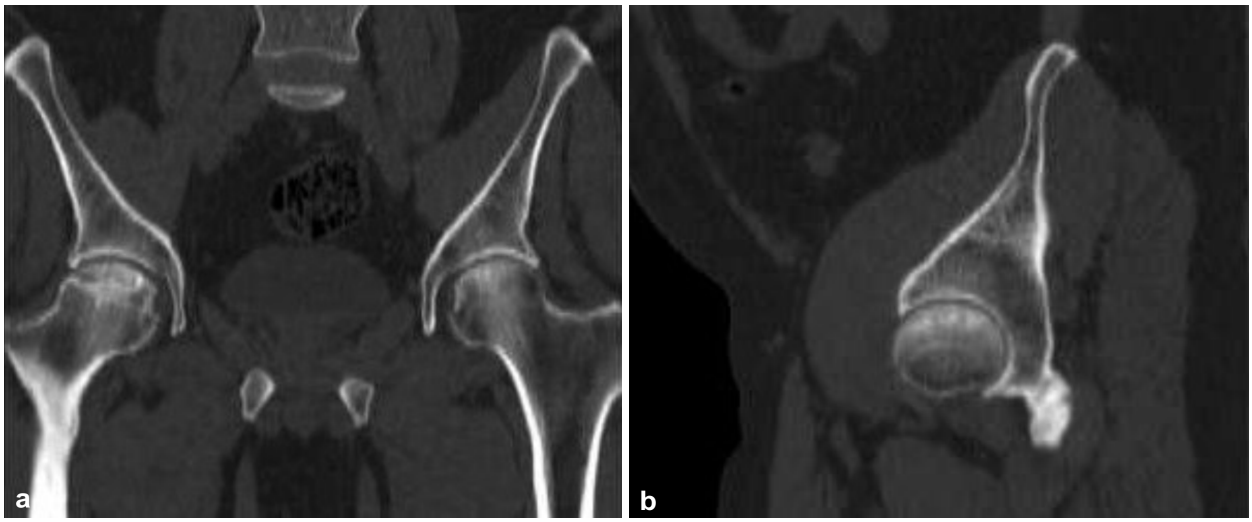

Figure 2 – ***The native CT images in the coronal plane (a) and the sagittal plane (b), in a patient with bilateral osteonecrosis of the femoral head (stage IV left, stage II right).***

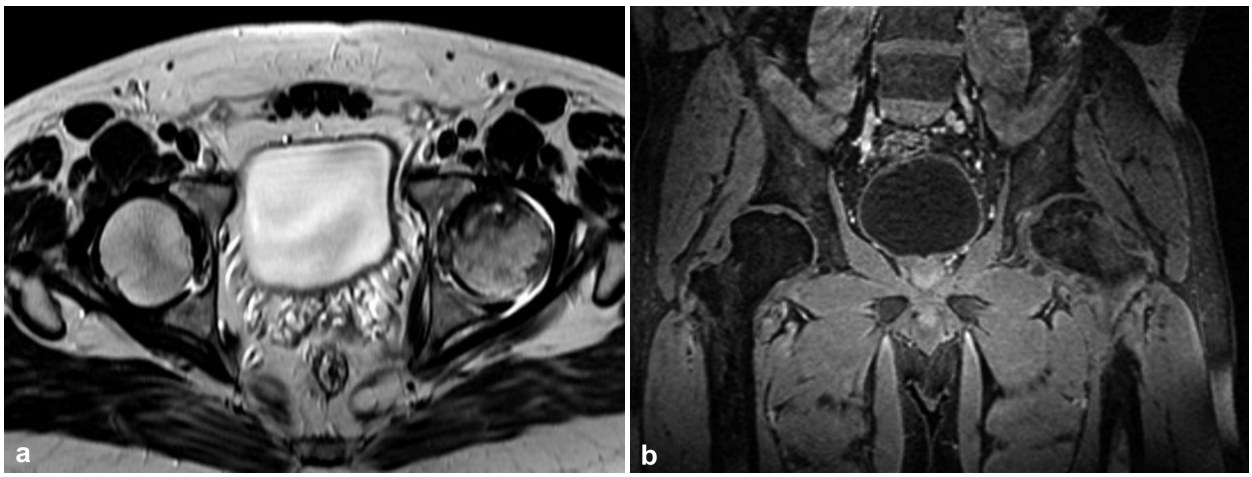

Figure 3 – ***MRI images: Axial T2 (a), cor T1 FS with sdc (b) – osteonecrosis of the left femoral head – stage IV ARCO, osteonecrotic center, with fine marginal line of osteocondensant that separates it from the healthy bone, left cervical and trochanteric edema, T1 low signal with diffuse SDC capture.***

The study results according to stage of disease were the following – 0.97% of patients were diagnosed in stage I of the disease, 3.88% of patients were diagnosed in stage II, 7.76% of patients were diagnosed at stage III of the disease, while 13.59% of patients were diagnosed at stage IV. 32.03% of patients were diagnosed in stage V of the condition, 41.74% of patients were diagnosed in stage VI of the condition.

Regarding the therapeutic means used for patients diagnosed with aseptic osteonecrosis of the femoral head, six patients received non-surgical treatment. For those who underwent surgical treatment, 17 were salvaging procedures (13 decompressive drills and four osteotomies) and 80 patients received reconstructive treatment (17 bipolar prostheses, 34 un-cemented and 29 cemented prostheses).

The biological material necessary for the histological and immunohistochemical study came from 64 patients diagnosed in the last four stages of the disease who have undergone hip replacement surgery.

Macroscopic appearance varied according to the stage of the condition and is similar for patients in the same stage, regardless of age or risk factors. Patients in stage III showed sclerotic changes, cysts, signs of osteoporosis and subchondral fractures. Patients in stage IV presented femoral head flattening, changes in the density of the bone, modifications with osteoporotic appearance (Figures 4 and 5).

In patients from stage V, we noticed, besides changes in the shape and contour of the femoral head, changes in the internal architecture and overlying cartilage. We also detected the presence of subchondral fractures, and large areas of liquefied necrosis penetrating the cartilage.

On macroscopic sections from patients in stage VI, we highlighted massive destruction of the femoral head, which completely compromised functionality of the affected hip-femoral joint.

Regarding the microscopic aspects observed through classical histological staining, they presented particularities concordant with the aseptic osteonecrosis stage. In patients diagnosed in stages III and IV, we noticed osteo-condensation of the perilesional area and the emergence of numerous blood vessels that penetrate the superjacent cartilage. As neoformation vessels reach the outer layer of the cartilage tissue, they tend to disorganize. In most patients, we found subchondral fractures. In these patients, we noticed at the endosteum level, numerous osteoblasts with reduced cytoplasm that line its surface (Figures 6 and 7).

On slides from patients diagnosed in the last three stages, particularly those in evolutionary stages V and VI, we noted the expansion of the lesion to the adjacent cartilage, highlighting multiple neoformation vessels at this level. The chondrocytes in the depth of the cartilage, in close proximity to the area of necrosis, maintain the integrity of their morphology, but as we progress towards the outer layer, there are changes in their shape and structure. Osteocytes near necrotic area have pyknotic nuclei or they are absent, cells becoming elongated, nearly spherical, increasing their sizes. Cellularity of bone tissue decreases as the disease is in a more advanced stage (Figures 8 and 9).

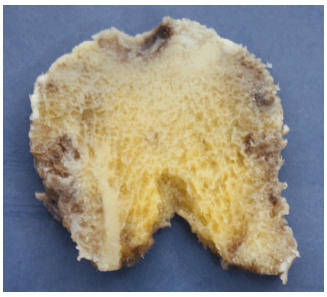

Figure 4 – ***Patient aged 46 years, diagnosed with aseptic osteonecrosis of the femoral head stage V (5 mm section at the femoral neck). Observe the net delimitation of the necrotic area and the lack of the superjacent cartilage.***

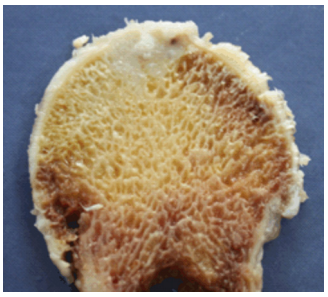

Figure 5 – ***Patients aged 32 years, diagnosed with aseptic osteonecrosis of the femoral head stage IV (5 mm section at the femoral neck). Observe the area of necrosis with a liquefied appearance, delimited by viable tissue and striping of the cartilage.***



Figure 6 – ***Extensive fibrosis, well organized fibers, accompanied by neoformation vessels that enter into the cartilage. Trichromic GS staining, ×100.***

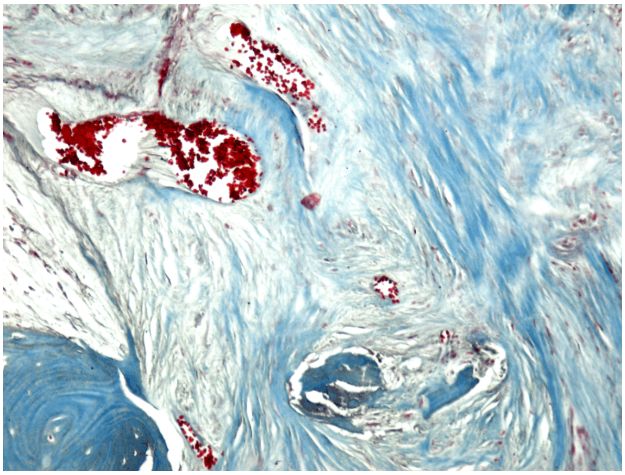

Figure 7 – ***Well-organized bundles of fibrous tissue in the lesioned area, with rare islands of bone tissue and neo-formation vessels. Trichromic GS staining, ×200.***

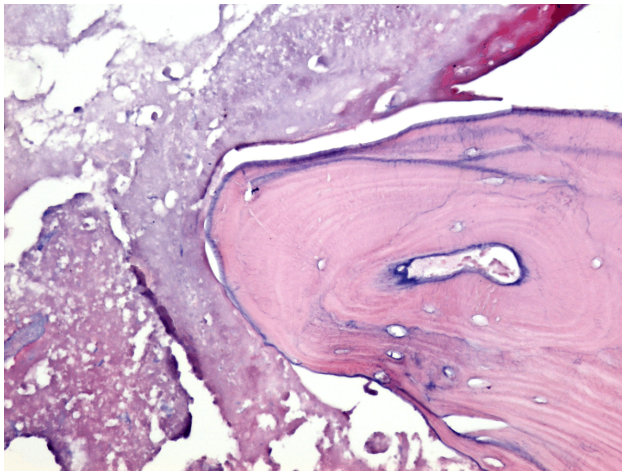

Figure 8 – ***The boundary between the healthy bone tissue and the area of necrosis, which is leading to osteo-condensation of the perilesional bone tissue, reducing the number and structure of bone cells. HE staining, ×200.***

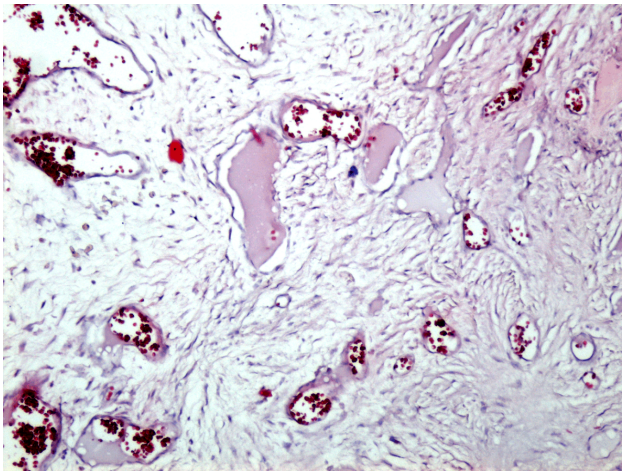

Figure 9 – ***Overview of the area of necrosis. Islands of reshuffled bone tissue, numerous neo-formation vessels and fibrous tissue. HE staining, ×200.***

Staining of the bone tissue in the area bordering the lesion decreases on some samples from patients in the last two stages, this was obvious even far from the affected area. Bone tissue near the necrotic area appears disorganized; it is intertwined or even replaced by fibrous tissue, which is organized according to distance from the affected area. In the remote areas, we can observe thin filaments while close to the affected area they become actual fascicles. Bone tissue observed on slides from patients in the last two stages is thin, bone lamellae can easily be seen, having a diminished staining. Osteocytes at this level have a modified shape, appear without nuclei, only a marginal

condensation zone. In the bone tissue and cartilage, that borders it, there are large areas of fibrous and necrotic tissue (Figures 10 and 11).

All 64 cases showed positive immunostaining for CD68 so macrophages have been highlighted in both the area of necrosis and at the adjacent areas. Macrophages exhibited a particularly intense lysosomal activity especially in patients at stages III and IV. In these patients, we highlighted at and endosteum level, numerous macrophages with foamy cytoplasm, indicating an intense activity of these cells. We noted the presence of macrophages on slides from patients in the last two evolutionary stages, but they are small in number and have an erratic disposition (Figures 12 and 13).

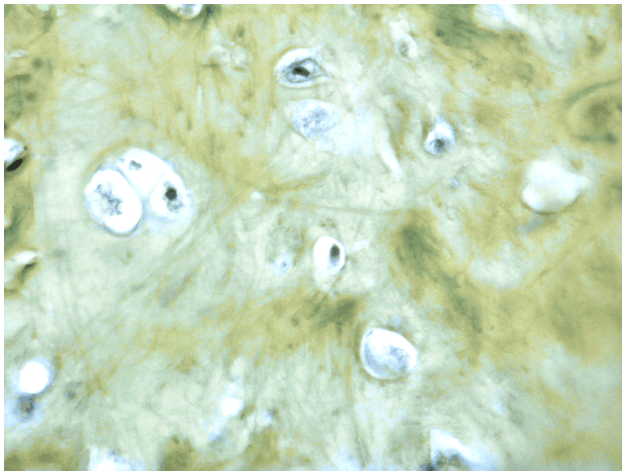

Figure 10 – ***Detail from the perilesional area, there is decreased bone tissue staining and alteration of the shape and size osteocytes. Trichromic GS staining, ×400.***

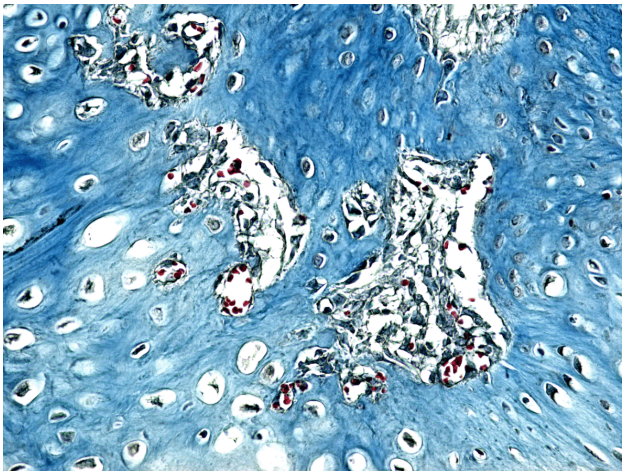

Figure 11 – ***Overview of the perilesional area, osteocytes lose their shape and increase in size, some have lost their nuclei. Trichromic GS staining, ×200.***

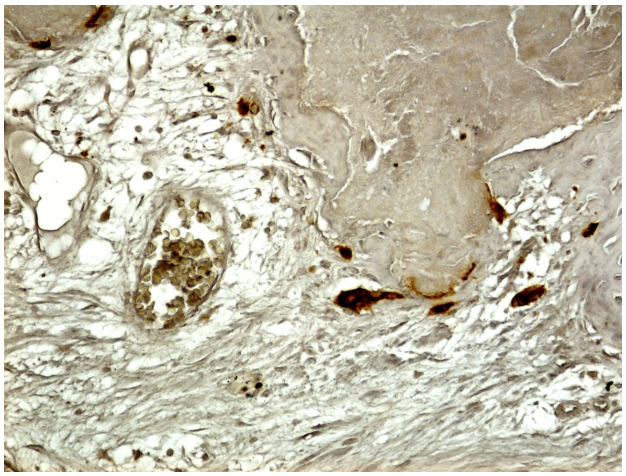

Figure 12 – ***Macrophages of different sizes arranged to the limit of the fibrous tissue and the area of reshuffled bone. CD68 immunostaining, ×200.***

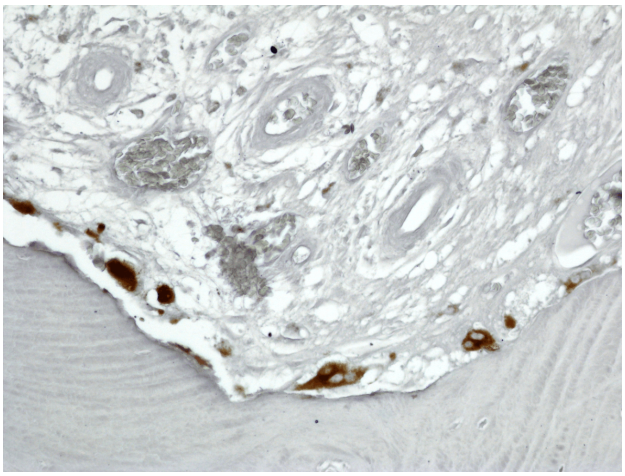

Figure 13 – ***Macrophages arranged at endosteum level, with foamy cytoplasm aspect. CD68 immunostaining, ×200.***

Discussion

For the staging of patients in the study, we used the ARCO classification system. In our study, most patients (91.27%) were diagnosed in the last four stages of the disease. We chose ARCO staging as it contains elements of several staging systems [9]. It has four stages from the FICAT staging, information on the degree of impairment of the femoral head (Steinberg staging) and prognosis based on the location of the lesion (Ohzono staging).

The non-invasive imaging methods used for the diagnosis of aseptic necrosis of the femoral head were the following: all patients were subjected to X-rays in anterior-posterior incidence. In 42.71% of patients, nuclear magnetic resonance was used, and for 13.58% computer tomography was used.

Changes in the early stages of aseptic necrosis of the femoral head are hardly visible on plane radiography. A normal image obtained by X-ray does not necessarily translate in the absence of the disease. Between the debut of the injury and the first suggestive images of the disease on radiography a period of up to five years can pass. A characteristic image, on plane radiography, is the presence of the crescent sign representing the appearance of subchondral fractures.

X-ray images obtained using plane radiography can be differentiated from those seen in other disorders: transitory osteoporosis, osteomyelitis, fractures, epiphyseal dysplasia, osteosarcoma, various cancers, bone metastases.

MRI is the non-invasive imaging technique with the highest degree of specificity and sensitivity used in the diagnosis of aseptic necrosis of the femoral head [4, 11]. It can detect initial injuries in asymptomatic patients, long

before they can be viewed on plain radiography, thus facilitating the initiation of treatment, providing a better response to initial therapy and a favorable prognosis. The MRI images correlate closely with the histological changes occurring in the affected hip, they describe in detail the size of the lesions, enabling accurate staging of the disease, which is used to decide a later therapeutic algorithm [5, 6, 12].

After the MRI scan of the affected hip joint, the images can be compared to those found in algo-dystrophy, transitory osteoporosis, transient medullary syndrome, epiphyseal fractures, infections, malignancies, infiltrative diseases, bone metastasis.

In the early stages, the sensitivity of CT is quite low, being only 55%, but can detect certain alterations in bone density even when radiographic images are normal.

On the images we obtained, alterations of blood vessels or bone marrow are not visible. Osteoporosis is the first pathological aspect that can be viewed. In advanced stages, on the images obtained we detected the collapse of the femoral head and degeneration of the hip joint. CT images can be compared to those of degenerative diseases, infectious, neoplastic disease, bone metastases.

Although patients in stages III and IV presented alterations on the imaging scans such as flattening of the femoral head or the decrease in bone density, the precise extension of the necrotic and perilesional areas was much wider on the histopathological examination. In these patients, we highlighted structural modification of the overlying cartilage that seemed morphologically sound, even if subchondral fractures had been observed. There have been cases where the images, particularly CT and MRI, have not really shown the full extent of the tissue damage.

In patients diagnosed in the last two stages of evolution, after analyzing microscopic images, we found a large area of fibrosis continuing outside the lesion area. This correlates with data captured using MRI and CT.

In all four developmental stages, using immunohistochemical staining, we observed many neoformation vessels, both in the lesion area and the adjacent cartilage, their density being lower in patients in stage III. This cannot be observed on the macroscopic sections, and there was no evidence in 100% of cases investigated with the MRI examination.

All 64 cases showed positive CD68 immunostaining, macrophages being highlighted both in the area of necrosis and at the adjacent areas. Our data in this regard corresponds to that in the literature [13, 14].

The therapeutic approach for the patients diagnosed with aseptic osteonecrosis of the femoral head included non-surgical means in six cases. For the patients who underwent surgical treatment, 17 were salvaging procedures (13 decompressive drills and four osteotomies) and 80 patients received reconstructive treatment (17 bipolar prostheses, 34 un-cemented and 29 cemented prostheses).

The therapeutic modalities used to treat necrosis of the femoral head include: non-surgical and surgical. Non-surgical means are used especially before the femoral head collapse, involve behavioral changes in patients and have not proven effective, even in the early stages [15, 16].

Surgical treatment means are divided into two categories: rescue procedures and reconstructive procedures. Rescue procedures are used in early stages, attempting to stop or delay the progress. These are represented by drilling-biopsy, bone grafts and osteotomies. Reconstructive methods are used after the femoral head collapse and are represented by bipolar arthroplasty or total arthroplasty (cemented or un-cemented) [17].

The decision to treat the condition using therapeutic means saving surgery or decompressive drilling is based on lesion size and not necessarily dependent on the appearance of symptoms. Decompressive drills are used for patients who present moderate lesions (15–30% of the area of the femoral head) [18].

Using drilling decompression without other therapeutic means does not yield very good results [19], but these can be greatly enhanced by using bone morphogenic protein concomitantly, introduced in the drilling channel and electromagnetic stimulation of the affected region [19]. Another therapeutic method that can accompany drilling decompression is harvesting bone blast cells, *in vitro* culturing of mesenchymal stem cells and autologous re-implantation in the tunnel obtained after drilling [20, 21]. Decompressive drilling can be used along with bone grafts.

Another surgical treatment used to treat aseptic necrosis of the femoral head is the osteotomy. Several types of osteotomies are performed before and post-collapse stages, with the purpose of the transferring pressure points from the affected subchondral area of necrosis to the unaffected joint surface [22]. These procedures present some risks, the success rate varies, sometimes it may even jeopardize the future success of hip replacements.

Advanced stages of aseptic necrosis of the femoral head, after developing hip osteoarthritis in the affected joint require arthroplasty. Partial or total prostheses are used (cemented or un-cemented), depending on the stage of evolution, the size of the lesion and the age of patients. Total hip replacements have satisfactory clinical results, clinical symptoms disappear and there is an improvement in the affected hip joint functionality.

The durability of total hip prostheses in patients with aseptic osteonecrosis of the femoral head is lower than those of patients diagnosed with osteoarthritis, because patients first are usually younger and have increased functional needs [23]. Co-morbidity associated with aseptic necrosis such as alcohol, associated inflammatory corticosteroid diseases can lower the rate of success of arthroplasties performed in these patients.

Conclusions

There were differences in the appearance and extent of the lesion on the histological images compared to macroscopic images and even to those obtained using imaging means, particularly in patients presenting evolutionary stage III. Aspects such as the extension of the area of fibrosis, remodeling of the bone tissue, neo-formation vascular network density and degree of impairment of the cartilage are determined more accurately using histology and immunohistochemistry techniques. Before classifying patients in a certain stage, after having correlated clinical and imaging data, histopathological

aspects have to be considered, particularly in patients in stages III and IV, in which total hip arthroplasty could be delayed.

Conflict of interests

The authors declare that they have no conflict of interests.

References

[1] Tripathy SK, Goyal T, Sen RK. Management of femoral head osteonecrosis: current concepts. Indian J Orthop, 2015, 49(1):28–45.

[2] Banerjee S, Issa K, Pivec R, Kapadia BH, Khanuja HS, Mont MA. Osteonecrosis of the hip: treatment options and outcomes. Orthop Clin North Am, 2013, 44(4):463–476.

[3] Seamon J, Keller T, Saleh J, Cui Q. The pathogenesis of nontraumatic osteonecrosis. Arthritis, 2012, 2012:601763.

[4] Malizos KN, Karantanas AH, Varitimidis SE, Dailiana ZH, Bargiotas K, Maris T. Osteonecrosis of the femoral head: etiology, imaging and treatment. Eur J Radiol, 2007, 63(1): 16–28.

[5] Yamaguchi R, Yamamoto T, Motomura G, Ikemura S, Iwamoto Y. MRI-detected double low-intensity bands in osteonecrosis of the femoral head. J Orthop Sci, 2011, 16(4):471–475.

[6] Takao M, Nishii T, Sakai T, Yoshikawa H, Sugano N. Repair in osteonecrosis of the femoral head: MR imaging features at long-term follow-up. Clin Rheumatol, 2010, 29(8):841–848.

[7] Theysohn JM, Kraff O, Theysohn N, Orzada S, Landgraeber S, Ladd ME. Hip imaging of avascular necrosis at 7 Tesla compared with 3 Tesla. Skeletal Radiol, 2014, 43(5):623–632.

[8] Mueller D, Schaeffeler C, Baum T, Walter F, Rechl H, Rummeny EJ, Woertler K. Magnetic resonance perfusion and diffusion imaging characteristics of transient bone marrow edema, avascular necrosis and subchondral insufficiency fractures of the proximal femur. Eur J Radiol, 2014, 83(10): 1862–1869.

[9] Schmitt-Sody M, Kirchhoff C, Mayer W, Goebel M, Jansson V. Avascular necrosis of the femoral head: inter- and intra-observer variations of Ficat and ARCO classifications. Int Orthop, 2008, 32(3):283–287.

[10] Lee GC, Steinberg ME. Are we evaluating osteonecrosis adequately? Int Orthop, 2012, 36(12):2433–2439.

[11] Karantanas AH, Drakonaki EE. The role of MR imaging in avascular necrosis of the femoral head. Semin Musculo-skelet Radiol, 2011, 15(3):281–300.

[12] Yeh LR, Chen CKH, Huang YL, Pan HB, Yang CF. Diagnostic performance of MR imaging in the assessment of subchondral fractures in avascular necrosis of the femoral head. Skeletal Radiol, 2009, 38(6):559–564.

[13] Rabquer BJ, Tan GJ, Shaheen PJ, Haines GK 3rd, Urquart AG, Koch AE. Synovial inflammation in patients with osteonecrosis of the femoral head. Clin Transl Sci, 2009, 2(4):273–278.

[14] Kamal D, Trăistaru R, Kamal CK, Alexandru DO, Ion DA, Grecu DC. Macrophage response in patients diagnosed with aseptic necrosis of the femoral head presenting different risk factors. Rom J Morphol Embryol, 2015, 56(1):163–168.

[15] Kaushik AP, Das A, Cui Q. Osteonecrosis of the femoral head: an update in year 2012. World J Orthop, 2012, 3(5): 49–57.

[16] Marker DR, Seyler TM, McGrath MS, Delanois RE, Ulrich SD, Mont MA. Treatment of early stage osteonecrosis of the femoral head. J Bone Joint Surg, 2008, 90(Suppl 4):175–187.

[17] Jones LC, Johnson AJ, Mont MA, Costa CR. Osteonecrosis of the hip in adults. Clin Rev Bone Miner Metab, 2011, 9:13–22.

[18] Hernigou Ph. Avascular necrosis of head of femur. Indian J Orthop, 2009, 43(1):1–2.

[19] McGrory BJ, York SC, Iorio R, Macaulay W, Pelker RR, Parsley BS, Teeny SM. Current practices of AAHKS members in the treatment of adult osteonecrosis of the femoral head. J Bone Joint Surg Am, 2007, 89(6):1194–1204.

[20] Yan Z, Hang D, Guo C, Chen Z. Fate of mesenchymal stem cells transplanted to osteonecrosis of femoral head. J Orthop Res, 2009, 27(4):442–446.

[21] Sen RK, Tripathy SK, Aggarwal S, Marwaha N, Sharma RR, Khandelwal N. Early results of core decompression and autologous bone marrow mononuclear cells instillation in femoral head osteonecrosis: a randomized control study. J Arthroplasty, 2012, 27(5):679–686.

[22] Biswal S, Hazra S, Yun HH, Hur CY, Shon WY. Transtrochanteric rotational osteotomy for nontraumatic osteonecrosis of the femoral head in young adults. Clin Orthop Relat Res, 2009, 467(6):1529–1537.

[23] Bergh C, Fenstad AM, Furnes O, Garellick G, Havelin LI, Overgaard S, Pedersen AB, Mäkelä KT, Pulkkinen P, Mohaddes M, Kärrholm J. Increased risk of revision in patients with non-traumatic femoral head necrosis. Acta Orthop, 2014, 85(1):11–17.

Corresponding author

Kamal Constantin Kamal, Teaching Assistant, MD, PhD, Department of Family Medicine, University of Medicine and Pharmacy of Craiova, 2 Petru Rareş Street, 200349 Craiova, Dolj County, Romania; Phone +40748–117 735, e-mail: kamalconstantin@gmail.com

Received: March 14, 2015

Accepted: December 30, 2015