

Vascular endothelial growth factor in systemic lupus erythematosus – correlations with disease activity and nailfold capillaroscopy changes

ANDREEA-LILI BĂRBULESCU¹⁾, ANANU-FLORENTIN VREJU²⁾, ANA-MARIA BUGĂ³⁾, RALUCA ELENA SANDU³⁾, CRISTINA CRIVEANU²⁾, DIANA-RODICA TUDORAȘCU⁴⁾, IOANA-ANDREEA GHEONEA⁵⁾, PAULINA-LUCIA CIUREA²⁾

¹⁾Department of Pharmacology, University of Medicine and Pharmacy of Craiova, Romania

²⁾Department of Rheumatology, University of Medicine and Pharmacy of Craiova, Romania

³⁾Department of Biochemistry, University of Medicine and Pharmacy of Craiova, Romania

⁴⁾Department of Internal Medicine, University of Medicine and Pharmacy of Craiova, Romania

⁵⁾Department of Radiology and Imaging, University of Medicine and Pharmacy of Craiova, Romania

Abstract

Our study aimed to quantify serum VEGF (vascular endothelial growth factor) and its inter-relation with the severity of microvascular damage, assessed by nailfold capillaroscopy (NC), and to establish the possible relationship with disease activity score. We included 18 patients, diagnosed with systemic lupus erythematosus (SLE) and 17 gender and age-matched control subjects. For determining serum VEGF, we used a Human VEGF Assay kit-IBL. NC was performed, according to the standard method, using a video-capillaroscope Videocap 3.0, DS Medica, by the same examiner, blinded to clinical and laboratory data. Serum VEGF registered a mean value of 68.99 ± 71.06 pg/mL for SLE patients and 31.84 ± 11.74 pg/mL for controls, differences statistically significant; depending on disease activity, we found a mean value of 60.11 ± 57.74 pg/mL, for patients with moderate disease activity vs. 30.96 ± 11.51 pg/mL for the ones with a low activity ($p=0.014$). We found a moderately positive correlation, statistically significant ($p=0.015$), between serum level of VEGF and Systemic Lupus Erythematosus Disease Activity Index (SLEDAI). Performing NC, we found changes in 88.88% of the patients; the most frequent were increased tortuosity, dilated capillaries, an increased length and a prominent subpapillary plexus. The presence of nailfold capillaroscopy changes and serum level of VEGF, correlated moderately, positive. Since serum levels of VEGF are higher in SLE patients, compared to controls, significantly different according to disease activity degree, and directly inter-related to abnormal NC patterns and a more active disease, we can include these accessible parameters in the routine evaluation, in order to better quantify the systemic damage, individualize the treatment, improve the outcome and life quality for these patients.

Keywords: systemic lupus erythematosus, vascular endothelial growth factor, nailfold capillaroscopy, disease activity severity index.

Introduction

Systemic lupus erythematosus (SLE) is an autoimmune disease, associated with a wide variety of auto-antibodies, immune complexes production and cellular damage, with the primary site represented by vascular endothelial cell injury [1, 2]. Immune mediated vascular damage and the consecutive angiogenesis represent major pathogenic factors, with an essentially mark on multi-systemic organ involvement [3, 4]. Among the wide number of angiogenic factors, vascular endothelial growth factor (VEGF) has been studied as a key mediator of endothelial dysfunction and modulator of neovascularization [5]. Elevated serum levels of VEGF were found to be increased in SLE patients, compared to controls, directly related to disease activity and systemic involvement, especially lupus nephritis; moreover, recent publications posited increased levels of VEGF in patients with moderate or severe capillaroscopic changes, suggesting that these picture the extension of microvascular damage [6–8].

Nailfold capillaroscopy (NC) is a non-invasive, efficient, reproducible technique, used to assess the microcirculation *in vivo*, in order to reveal the peripheral angiopathy, with both diagnostic and prognostic purpose, in patients

with connective tissue diseases [9, 10]. In SLE patients, NC alterations have been known to have a lower specificity [11, 12] and the most frequently lesions are apparently represented by capillaries with an increased tortuosity (described in up to 42% of the patients) [13–15], an increased length of capillaries [14–16], an increased diameter and a prominent subpapillary plexus [14, 15, 17].

Several studies show a direct relation between certain capillaroscopic findings, disease activity and high immunological activity [6, 12, 18, 19], as well as a more frequent presence of NC changes in patients with multisystemic involvement [19, 20].

Due to the major involvement of endothelial dysfunction in the process of microvascular remodeling, secondary to systemic inflammation, and its multiple clinical consequences, evaluating serum VEGF and using a non-invasive, accessible, economic viable method like NC, can be used to better understand the level of vascular injury, in order to improve the prognostic and apply the proper therapeutic measures.

The aim of the study was to quantify serum VEGF and its inter-relation with the severity of microvascular damage, assessed by NC, and to establish the possible relationship with disease activity score.

☐ Patients and Methods

We performed a cross-sectional study, which included 18 patients, diagnosed with SLE, according to ACR (*American College of Rheumatology*) 1982 revised criteria [21], in the Department of Rheumatology, Emergency County Hospital of Craiova, Romania, and 17 gender and age-matched control subjects, without any acute or chronic inflammatory disease, history of connective tissue disease or peripheral vascular diseases.

The study was performed in accordance to the Declaration of Helsinki and approved by the Ethics Committee of the University of Medicine and Pharmacy of Craiova. All patients provided their written informed consent, after receiving a standard form for NC and VEGF evaluation, which mentioned that results are used for research purposes.

Patients' evaluation included anamnestic data, clinical examination, laboratory tests and imagistic methods. Disease activity was assessed using Systemic Lupus Erythematosus Disease Activity Index (SLEDAI) [22], that ranges from 0 to 105, and defines remission when is 0, low activity 1–5, moderate activity 6–11, high disease activity 11–19 and very high disease activity over 20; a persistent SLEDAI over 3 defines a chronic activity [23]. Laboratory tests were performed according to the manufacturer's kit indications.

In order to determine serum VEGF, venous blood samples were centrifuged at 9700 rotations/minute, for 15 minutes, and the serum obtained was stored at -80°C until analyze. The determination was performed using a Human VEGF Assay kit-IBL (Immuno-Biological Laboratories Co.). Both probes and standard were prepared in duplicate. First, we prepared wash buffer, by diluting 50 mL of "8 Wash buffer Conc" with 1.950 mL of deionized water and mix. Afterwards, was prepared the antibody, by diluting concentrate antibody with the solution provided by the kit, in 30 times, according to required quantity into a disposable test tube. Preparation of standard was done by adding 0.5 mL deionized water over the concentrate solution. We performed consecutive dilutions of standard solution, so that the concentration is 1000 pg/mL in the first tube, 500 pg/mL in the second one, until the 8th has the concentration of 0 pg/mL. All the reagents were brought to room temperature approximately 30 minutes before use. Standard curve was prepared simultaneously with the measurement of test samples. The next step was represented by addition of 100 μL of "EIA buffer" into the wells for sample blank, test sample and diluted standard, followed by incubation for 60 minutes at 37°C , then washing five times with wash buffer. We added 100 μL of antibody solution into the wells of test samples, diluted standard and test sample blank, incubated the plate for 30 minutes at 4°C and was it seven times. 100 μg of "Chromogen" was added next into every well and incubated the plate for 30 minutes at room temperature, in the dark. The last step was represented by addition of "Stop solution" and proceeding to the reader and measurement at 450 nm.

NC was performed, according to the standard method, using a video-capillaroscope Videocap 3.0, DS Medica, by the same examiner, blinded to clinical and laboratory

data. All patients were recommended not to cut the cuticles, at least seven days prior to examination, and no nail lacquer should be applied, in order to avoid artifacts and inconclusive results. Each subject was allowed to acclimate at least 15 minutes, at room temperature, ideal $20\text{--}24^{\circ}\text{C}$. NC was performed for the first row capillaries, in II–V fingers, both hands, excepting the ones with a recent trauma, after applying a drop of immersion oil, in order to obtain a better visibility. We assessed the following NC parameters: distribution, shape, width, length, mean capillary density, presence of avascular areas, hemorrhages and visibility of subpapillary plexus. Measurements were taken using the software program of the device.

Statistical analysis was performed using GraphPad Prism 5.5. Results are presented as mean \pm SD and data were analyzed using *t*-test for comparing groups and Pearson/Spearman's coefficient for evaluating correlations. We considered a level of $p < 0.05$ statistically significant.

☐ Results

General characteristics

Of the 18 SLE patients, most of them were female (16; 88.88%), with a mean age of 45 ± 10.81 years, ranging from 20 to 66 years; most of the patients (83.33%) were less than 45 years, as it is described for this connective tissue disorder, and the mean disease duration was 8 ± 5.54 years (Table 1). Female patients prevailed over male also in the control group (16 women and one man) and their ages ranged from 19 to 64 years.

Table 1 – General characteristics of SLE patients

Parameter	Mean \pm SD
Age [years]	45.00 \pm 10.81
Disease duration [years]	8.00 \pm 5.54
Hb [g/dL]	11.26 \pm 1.21
Ht [%]	36.67 \pm 6.01
Le [No./mm ³]	4109.09 \pm 648.71
Ly [%]	35.31 \pm 6.32
Tr [No./mm ³]	161 227.3 \pm 36 069.29
Cr [mg/dL]	0.85 \pm 0.15
24 hours urinary proteins [g/24 h]	0.6 \pm 1.41
Anti-dsDNA [IU/mL]	309.3 \pm 205.9
Anti-Sm [IU/mL]	7.82 \pm 2.72
Anti-U1 RNP [U/mL]	2.58 \pm 3.74
Anti-SS-A/Ro [U/mL]	6 \pm 4.72
Anti-SS-B/La [U/mL]	3.07 \pm 3.34
C3 [mg/dL]	85.65 \pm 21.80
C4 [mg/dL]	11.64 \pm 8.13
aCL-IgG [GPL/mL]	24.86 \pm 16.45
aCL-IgM [GPL/mL]	28.91 \pm 17.93
ESR [mm/h]	33.77 \pm 9.22
CRP [mg/dL]	0.78 \pm 0.40
SLEDAI	7.55 \pm 4.06
GC [n (%)]	16 (88.88)
HCQ [n (%)]	18 (100)
Immunosuppressive agents [n (%)]	14 (77.77)

SD: Standard deviation; Hb: Hemoglobin; Ht: Hematocrit; Le: Leukocytes; Ly: Lymphocytes; Tr: Thrombocytes; Cr: Creatinine; dsDNA: Double-stranded DNA; RNP: Ribonucleoprotein; aCL: Anti-cardiolipin; ESR: Erythrocyte sedimentation rate; CRP: C-reactive protein; SLEDAI: Systemic Lupus Erythematosus Disease Activity Index; GC: Glucocorticoid; HCQ: Hydroxychloroquine.

Laboratory findings

The results of basic complete blood count, with white count differential, fundamental in the assessment of a lupus patient, showed a mean value for hemoglobin (Hb) of 11.26 ± 1.21 g/dL, $4109 \pm 648.71/\text{mm}^3$ leukocytes, ranging from 3100 to $5200/\text{mm}^3$, with leukopenia, sign of active disease, found in 61.11% of the cases; for platelets, we registered a mean number of $161\,227.3 \pm 36\,069.29/\text{mm}^3$. Lymphopenia, the commonest disorder found in the blood count, was present in 10 (55.55%) patients. Erythrocyte sedimentation rate (ESR), often raised in SLE patients, had a mean value of 33.77 ± 9.22 mm/h, ranging from 22 to 58 mm/h. For C-reactive protein (CRP), usually normal or slightly raised, we calculated a mean value of 0.78 ± 0.40 mg/dL, with 12 patients over the upper limit (0.5 mg/dL), most of them not exceeding 1 mg/dL. Renal assessment identified a mean creatinine (Cr) of 0.85 ± 0.15 mg/dL and a mean 24-hour proteinuria, a more sensitive test for assessing lupus nephritis, of 0.6 ± 1.41 g.

Antibodies panel assessment started with anti-doubled-stranded (ds) DNA antibodies, useful not only for diagnostic purposes, but also for monitoring disease activity and therapy, that ranged from 78.5 to 686.6 IU/mL, with a mean value of 309.3 ± 205.9 IU/mL; for 15 patients, we registered a value over the upper limit (100 IU/mL). An active disease also involves decreased levels of C3 and C4 complement fractions; in our cohort, we obtained a mean value of 85.65 ± 21.80 mg/dL for C3 (ranging from 61.5 to 155.1 mg/dL), with more than 50% of the patients

having values under the lower limit (90 mg/dL); regarding C4 fraction, the mean value was 11.64 ± 8.13 mg/dL, most of the patients with C4 deficiency.

Concerning the therapeutic approach, all of the patients received Hydroxychloroquine, 200–400 mg/day, 16 (88.88%) were on oral corticosteroids and for 14 immunosuppressive agents were part of the treatment (Azathioprine 50 to 100 mg/day).

Scoring disease activity, we reckoned a mean value of 7.55 ± 4.06 for SLEDAI (min. 3, max. 20). According to the classification published by Mosca & Bombardieri in 2006 [23], 61.11% (11) of the patients had a moderate disease activity, 27.77% (5) a low disease activity, one patient (5.55%) registered a value of SLEDAI corresponding to an intense activity and one patient (5.55%) a severe disease activity.

Evaluating the serum level of VEGF, we obtained a mean value of 68.99 ± 71.06 pg/mL (95% CI 33.65–104.3). Compared to the control group, were the mean value was 31.84 ± 11.74 pg/mL (95% CI 25.80–37.87), the differences recorded were statistically significant, $p=0.0397$ (Figure 1).

Analyzing serum VEGF depending on disease activity, we found a mean value of 60.11 ± 57.74 pg/mL, for patients with moderate disease activity vs. 30.96 ± 11.51 pg/mL for the group with a low activity ($p=0.014$) (Figure 2).

We found a moderately positive correlation ($r=0.561$), statistically significant ($p=0.015$), between serum VEGF and SLEDAI; also, VEGF correlated significant with ESR ($r=0.543$, $p=0.015$) and CRP ($r=0.5913$, $p=0.009$).

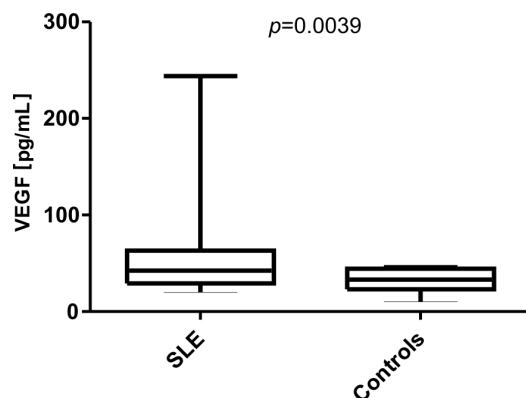


Figure 1 – VEGF distribution in SLE group and controls.

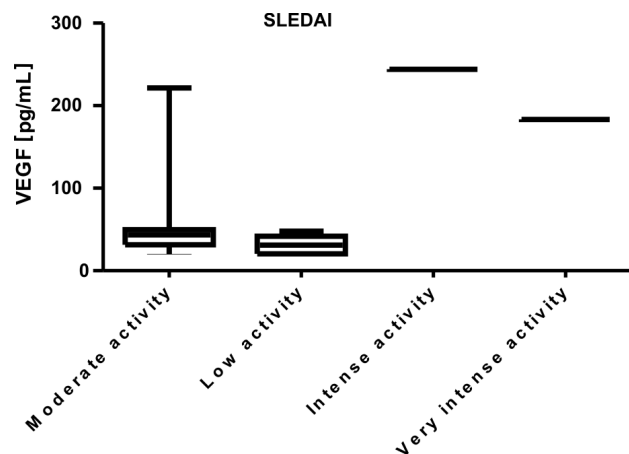


Figure 2 – VEGF distribution depending on the degree of disease activity.

Morphological profile

Performing NC, a non-invasive imaging technique for morphological analysis of capillaries in the nailfold area, we found changes in 16 (88.88%) of the 18 patients included. The most frequent ones were represented by increased tortuosity (15; 83.33%) (Figure 3, a and b), dilated capillaries (12; 66.66%) (Figure 4, a and b), an increased length in 11 patients (Figure 5a), a scleroderma-like pattern, with hemorrhages and avascular areas, in three patients (Figure 5b) and a prominent subpapillary plexus in six patients (Figure 3, a and b).

The “SLE-type” capillaroscopic pattern, with elongated

capillaries, increased tortuosity, dilated capillaries and a prominent subpapillary plexus, was found in 11 (61.11%) of the patients. Most of them, 10 patients, had an increased titer of anti-dsDNA antibodies. Antiphospholipid antibodies (anticardiolipin antibodies IgG and IgM) were negative in patients with a “SLE-type” pattern. The “scleroderma-like” pattern, described in three of them, was associated with a high immunological activity (increased titer of anti-dsDNA antibodies and hypocomplementemia). Although in other studies [11, 12] this pattern was associated with the presence of anti-RNP (ribonucleoprotein) antibodies and overlap syndrome, in the examined SLE group these were not present.

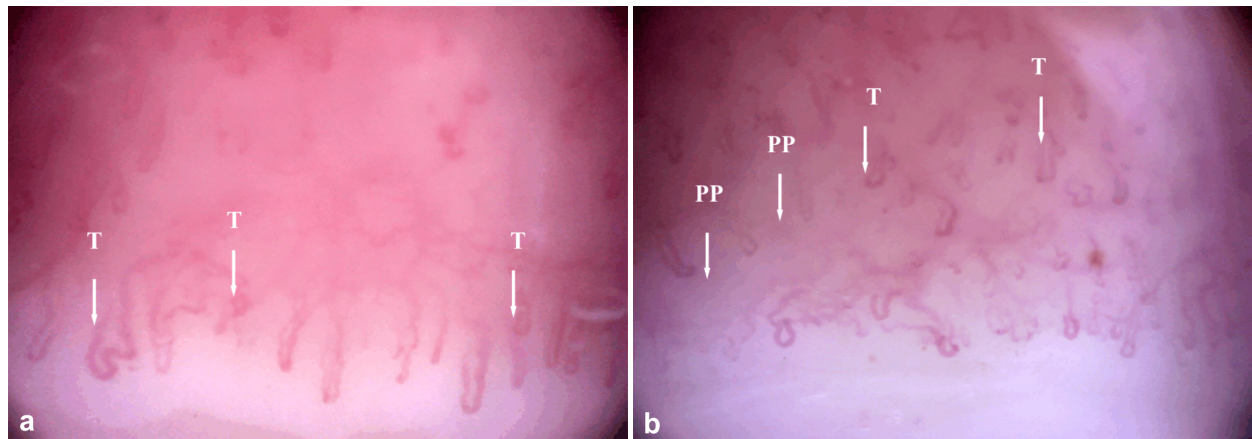


Figure 3 – (a and b) Nailfold capillaroscopy ($\times 200$): Capillaries with increased tortuosity (T) and a prominent subpapillary plexus (PP).

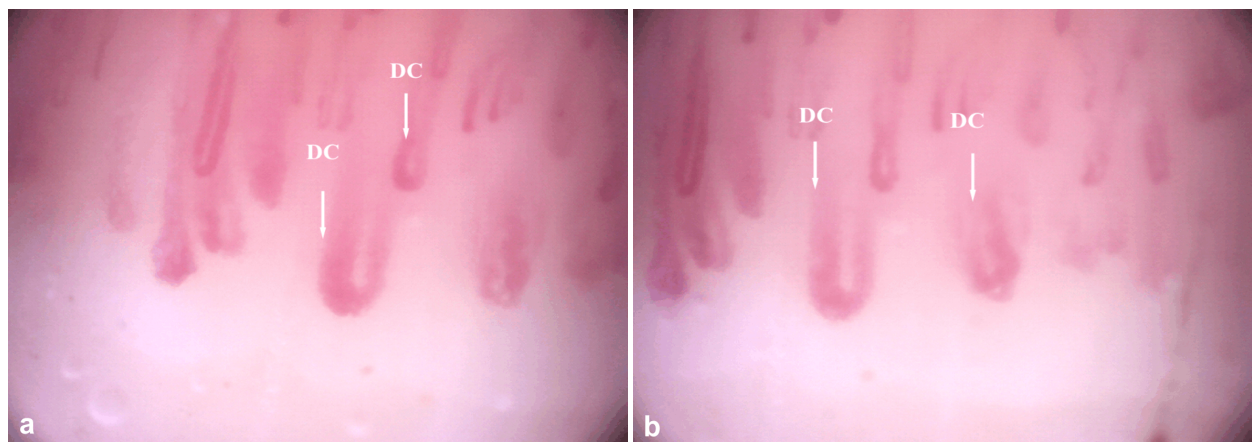


Figure 4 – (a and b) Nailfold capillaroscopy ($\times 200$): Dilated capillaries (DC).

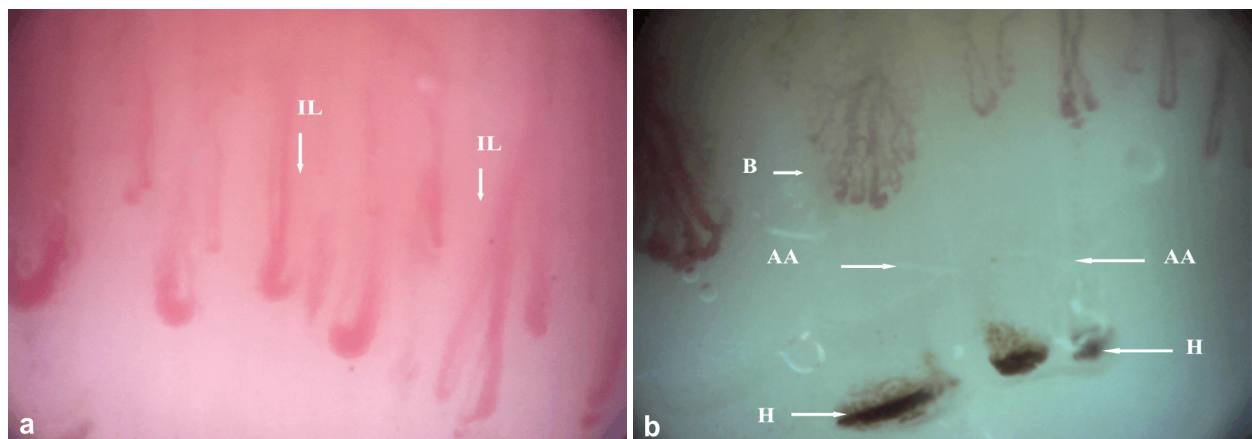


Figure 5 – Nailfold capillaroscopy ($\times 200$): (a) Increased length (IL) of capillaries; (b) Scleroderma-like pattern, with hemorrhages (H), bushy capillaries (B) and avascular areas (AA).

Regarding the control group, we found 1–2 capillary loops with increased tortuosity in two patients, without significance, and one case with hemorrhages, possible traumatic ones.

Analyzing the relationship between the presence of morphological changes, found by capillaroscopic examination, and serum VEGF, the main mediator of angiogenesis, we established a moderately positive correlation ($r=0.477$, $p=0.045$). Also, we noticed different serum VEGF values in patients with/without certain

microvascular abnormalities, considered frequent in SLE: 75.59 ± 76.36 pg/mL vs. 36.33 ± 5.99 pg/mL in patients with/without increased tortuosity ($p=0.001$), 93.17 ± 82.63 pg/mL vs. 31.14 ± 11.61 pg/mL in patients with/without elongated capillaries ($p=0.076$), 85.23 ± 82.91 pg/mL vs. 36.70 ± 10.19 pg/mL for patients with/without dilated capillaries ($p=0.094$) and 123.2 ± 103.7 pg/mL vs. 42.00 ± 22.28 pg/dL for the ones with/without a prominent subpapillary plexus ($p=0.001$) (Figure 6).

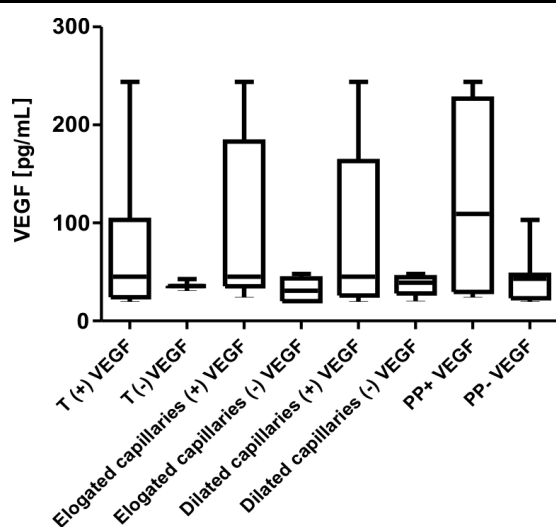


Figure 6 – VEGF distribution depending on NC changes.

Discussion

The significance of vascular damage in SLE, a classic model of systemic autoimmune disease, was underlined since 1904, by Osler [24] and it is very well established that endothelial dysfunction represents *primum movens* in the process of vascular remodeling [3]. VEGF is a key modulator of angiogenesis, endothelial cell proliferation and migration, capillary permeability, and it has been reported that elevated serum levels are found in chronic inflammatory rheumatic diseases, including SLE, compared to healthy controls, as well as a direct correlation between disease activity and its serum level [5–7]. Our data revealed statistically significant differences between patients and controls, as reported by Liu *et al.* in a recent publication (2015) [5], Zhou *et al.* in 2014 [25], Moneib *et al.* in 2012 [26], Ciołkiewicz *et al.* in 2010 [6] and other significant scientific reports [27–29].

Our results also revealed a statistically significant, moderately positive correlation between serum VEGF and disease activity, quantified by SLEDAI, suggesting that it can be a useful evaluation marker, data reported by several recent publications [5, 24–26]. Other data from our study sustained a direct correlation between serum VEGF and inflammatory markers, ESR and CRP, data concordantly with the reports of Kuryliszyn-Moskal *et al.* [8] and Zhou *et al.* [25]. Analyzing serum VEGF dependent on disease activity concluded with a highly divergent mean values for patients with moderate disease activity *versus* low activity. The similar relation between the degree of disease activity and serum levels of VEGF was also reported by other recent publications [5, 6, 8, 26, 28].

Furthermore, we analyzed the microvascular changes, using NC, a safe, non-invasive method, easily reproducible, used to assess microcirculation *in vivo*, in patients with conjunctive tissue disease. Although the capillaroscopic changes are less specific in SLE patients, a series of patterns have been described, as well as a variable prevalence of these. In our cohort, we found changes in 16 (88.88%) patients. Several scientific reports have described different percentages, ranging from 75% in a

group of 40 patients, published by Ragab *et al.* in 2011 [18], 76.7% in a study that included 33 SLE patients, published in *An Bras Dermatol*, in 2006, by Facina *et al.* [30], to 95.5% in the study reported by Kuryliszyn-Moskal *et al.*, in 2007 [8]. The differences between reports may be associated with different disease duration of the included subjects.

The morphological abnormalities found in our study group varied from capillaries with an increased tortuosity, elongated, dilated, ramified capillaries, a prominent subpapillary plexus, to giant capillary loops and hemorrhages. We found an increased tortuosity of the capillaries as the main change, present in 18 (81.81%) of the cases, dilated capillaries in 12 (66.66%) patients, an increased length for 11 subjects and a prominent subpapillary plexus for six patients, results in consistency with the ones reported by several recent publications [8, 20, 30].

NC findings and serum VEGF correlated moderately, positive, and we noticed significant different values of serum VEGF in patients with/without certain microvascular abnormalities, considered frequent in SLE patients: increased tortuosity, elongated capillaries, dilated capillaries and a prominent subpapillary plexus. This association, that sustain that VEGF reflects the microcirculatory changes in SLE patients, explained by inflammation, endothelial damage and stimulation of angiogenic factors production, was reported by Moneib *et al.* in 2012 [26], Ciołkiewicz *et al.* in 2010 [6] and previously, in 2009 [27] and 2007 [8], and Heshmat *et al.* in 2007 [29].

Conclusions

Our study is seemingly the first in Romania and despite the relatively low number of subjects, it strongly resulted in agreement with other recently published data and determines the extension of the study, with a multi-centric involvement. Since serum levels of VEGF are higher in SLE patients, compared to controls, significantly different according to disease activity degree, and directly inter-related to abnormal NC patterns and a more active disease, we can include these accessible parameters in the routine evaluation. A complex approach of each patient is essential, in order to better quantify the systemic damage and individualize the treatment, so that we can improve the outcome and life quality for these patients.

Conflict of interests

The authors declare that they have no conflict of interests.

Acknowledgments

This paper was published under the frame of European Social Fund, Human Resources Development Operational Program 2007–2013, Project No. POSDRU/159/1.5/136893.

References

- [1] Dias SS, Isenberg DA. Advances in systemic lupus erythematosus. *Medicine*, 2014, 42(3):126–133.
- [2] Grossman JM, Kalunian KC. Definition, classification, activity, and damage indices. In: Wallace DJ, Hahn BH (eds). *Dubois' lupus erythematosus*. Lippincott Williams & Wilkins, Philadelphia, PA, 2002, 19–31.
- [3] Belmont HM, Abramson SB, Lie JT. Pathology and pathogenesis of vascular injury in systemic lupus erythematosus. *Interaction of inflammatory cells and activated endothelium*. *Arthritis Rheum*, 1996, 39(1):9–22.

- [4] Hurairah H, Ferro A. The role of the endothelium in the control of vascular function. *Int J Clin Pract*, 2004, 58(2):173–183.
- [5] Liu J, Wang X, Yang X, Yan Q, Wang S, Han W. Investigating the role of angiogenesis in systemic lupus erythematosus. *Lupus*, 2015, 24(6):621–627.
- [6] Ciolekiewicz M, Kuryliszyn-Moskal A, Klimiuk PA. Analysis of correlations between selected endothelial cell activation markers, disease activity, and nailfold capillaroscopy microvascular changes in systemic lupus erythematosus patients. *Clin Rheumatol*, 2010, 29(2):175–180.
- [7] Robak E, Woźniacka A, Sysa-Jedrzejowska A, Stepień H, Robak T. Serum levels of angiogenic cytokines in systemic lupus erythematosus and their correlation with disease activity. *Eur Cytokine Netw*, 2001, 12(3):445–452.
- [8] Kuryliszyn-Moskal A, Klimiuk PA, Sierakowski S, Ciolekiewicz M. Vascular endothelial growth factor in systemic lupus erythematosus: relationship to disease activity, systemic organ manifestation and nailfold capillaroscopic abnormalities. *Arch Immunol Ther Exp (Warsz)*, 2007, 55(3):179–185.
- [9] Cortes S, Cutolo M. Capillaroscopic patterns in rheumatic diseases. *Acta Reum Port*, 2004, 32(1):29–36.
- [10] Cutolo M, Pizzorni C, Sulli A. Capillaroscopy. *Best Pract Res Clin Rheumatol*, 2005, 19(3):437–452.
- [11] Ingegnoli F, Zeni S, Meani L, Soldi A, Lurati A, Fantini F. Evaluation of nailfold videocapillaroscopic abnormalities in patients with systemic lupus erythematosus. *J Clin Rheumatol*, 2005, 11(6):295–298.
- [12] Lambova SN, Müller-Ladner U. Capillaroscopic pattern in systemic lupus erythematosus and undifferentiated connective tissue disease: what we still have to learn? *Rheumatol Int*, 2013, 33(3):689–695.
- [13] Redisch W, Messina EJ, Hughes G, McEwen C. Capillaroscopic observations in rheumatic diseases. *Ann Rheum Dis*, 1970, 29(3):244–253.
- [14] Bergman R, Sharony L, Schapira D, Nahir MA, Balbir-Gurman A. The handheld dermatoscope as a nail-fold capillaroscopic instrument. *Arch Dermatol*, 2003, 139(8):1027–1030.
- [15] Cutolo M, Sulli A, Secchi ME, Paolino S, Pizzorni C. Nailfold capillaroscopy is useful for the diagnosis and follow-up of autoimmune rheumatic diseases. A future tool for the analysis of microvascular heart involvement? *Rheumatology (Oxford)*, 2006, 45(Suppl 4):iv43–iv46.
- [16] Granier F, Vayssairat M, Priollet P, Housset E. Nailfold capillary microscopy in mixed connective tissue disease. Comparison with systemic sclerosis and systemic lupus erythematosus. *Arthritis Rheum*, 1986, 29(2):189–195.
- [17] Kabasakal Y, Elvins DM, Ring EF, McHugh NJ. Quantitative nailfold capillaroscopy findings in a population with connective tissue disease and in normal healthy controls. *Ann Rheum Dis*, 1996, 55(8):507–512.
- [18] Ragab O, Ashmawy A, Abdo M, Mokbel A. Nailfold capillaroscopy in systemic lupus erythematosus. *Egyptian Rheumatologist*, 2011, 33(1):61–67.
- [19] Dancour MA, Vaz JL, Bottino DA, Bouskela E. Nailfold videocapillaroscopy in patients with systemic lupus erythematosus. *Rheumatol Int*, 2006, 26(7):633–637.
- [20] Riccieri V, Spadaro A, Ceccarelli F, Scrivo R, Germano V, Valesini G. Nailfold capillaroscopy changes in systemic lupus erythematosus: correlation with disease activity and autoantibody profile. *Lupus*, 2005, 14(7): 521–525.
- [21] Hochberg MC. Updating the American College of Rheumatology revised criteria for the classification of systemic lupus erythematosus. *Arthritis Rheum*, 1997, 40(9):1725.
- [22] Bombardier C, Gladman DD, Urowitz MB, Caron D, Chang CH. Derivation of the SLEDAI. A disease activity index for lupus patients. The Committee on Prognosis on Studies in SLE. *Arthritis Rheum*, 1992, 35(6):630–640.
- [23] Mosca M, Bombardieri S. Assessing remission in systemic lupus erythematosus. *Clin Exp Rheumatol*, 2006, 24(6 Suppl 43): S-99–S-104.
- [24] Osler W. On the visceral manifestations of the erythema group of skin disease. *Am J Med Sci*, 1904, 127:1–23.
- [25] Zhou L, Lu G, Shen L, Wang L, Wang M. Serum levels of three angiogenic factors in systemic lupus erythematosus and their clinical significance. *BioMed Res Int*, 2014, 2014:627126.
- [26] Moneib HA, Salem SA, Aly DG, Khedr HT, Wafaey HA, Hassan HE. Assessment of serum vascular endothelial growth factor and nail fold capillaroscopy changes in systemic lupus erythematosus with and without cutaneous manifestations. *J Dermatol*, 2012, 39(1):52–57.
- [27] Kuryliszyn-Moskal A, Ciolekiewicz M, Klimiuk PA, Sierakowski S. Clinical significance of nailfold capillaroscopy in systemic lupus erythematosus: correlation with endothelial cell activation markers and disease activity. *Scand J Rheumatol*, 2009, 38(1):38–45.
- [28] Colombo BM, Cacciapaglia F, Puntoni M, Murdaca G, Rossi E, Rodriguez G, Nobili F, Pisciotta L, Bertolini S, Moccetti T, Dentali F, Steidl L, Ciprandi G, Afeltra A, Indiveri F, Puppo F. Traditional and non traditional risk factors in accelerated atherosclerosis in systemic lupus erythematosus: role of vascular endothelial growth factor (VEGATS Study). *Autoimmun Rev*, 2009, 8(4):309–315.
- [29] Heshmat NM, El-Kerdany TH. Serum levels of vascular endothelial growth factor in children and adolescents with systemic lupus erythematosus. *Pediatr Allergy Immunol*, 2007, 18(4):346–353.
- [30] Facina AS, Pucinelli MLC, Vasconcellos MRA, Ferraz LB, de Almeida FA. Capillaroscopy findings in lupus erythematosus. *An Bras Dermatol*, 2006, 81(6):527–532.

Corresponding author

Ioana-Andreea Gheonea, Lecturer, MD, PhD, Department of Radiology and Imaging, University of Medicine and Pharmacy of Craiova, 2 Petru Rareș Street, 200349 Craiova, Dolj County, Romania; Phone +40751–268 732, e-mail: iagheonea@gmail.com

Received: February 20, 2015

Accepted: November 10, 2015