

## The involvement of upper airway in Wegener's granulomatosis – about four cases

CRISTIAN ANDREI SARĂU<sup>1)</sup>, DANIEL FLORIN LIGHEZAN<sup>1)</sup>, ION CAIUS DOROȘ<sup>2)</sup>,  
 EUGEN HORĂȚIU ȘTEFĂNESCU<sup>2)</sup>, GHEORGHE IOVĂNESCU<sup>2)</sup>, NICOLAE CONSTANTIN BALICA<sup>2)</sup>,  
 IOANA DELIA HORHAT<sup>2,3)</sup>, MARIOARA POENARU<sup>2)</sup>

<sup>1)</sup>Department of Medical Semiology I, "Victor Babeș" University of Medicine and Pharmacy, Timisoara, Romania

<sup>2)</sup>Department of ENT, "Victor Babeș" University of Medicine and Pharmacy, Timisoara, Romania

<sup>3)</sup>Department of Microscopic Morphology, "Victor Babeș" University of Medicine and Pharmacy, Timisoara, Romania

### Abstract

The authors present four cases of Wegener's granulomatosis patients with multiorgan manifestation forms, but with a prevalent involvement in upper-airway. Granulomatosis diseases of the nose include bacterial infections (rhinoscleroma, tuberculosis, syphilis, lupus, and leprosy), fungal infections (rhinosporidiosis, aspergillosis, mucormycosis, candidosis, histoplasmosis, and blastomycosis) and diseases with unspecified etiology (Wegener's granulomatosis, mediocranial malignant granuloma, and sarcoidosis). We consider an interesting experience regarding Wegener's granulomatosis due to its rarity, being an autoimmune systemic disease, with continuous evolution and multiorgan involvement. The beginning of the disease is like upper airway affection, a kind of "persistent cold", being difficult to differentiate it from a common cold in the head, with a prolonged evolution. It is important to mention that we establish the diagnosis of Wegener's granulomatosis starting with Ear Nose and Throat (ENT) clinical exam, followed by other tests and investigations realized in our Clinic and completed with specialty tests (nephrology, internal medicine and dermatology), meaning that we need a close cooperation with these medical specialties. All the patients presented multiorgan involvement. Notably significant for our four cases is the prolonged evolution in a stable condition in one patient.

**Keywords:** Wegener's granulomatosis, upper airway, subglottic stenosis, prolonged evolution.

### Introduction

Wegener's granulomatosis represents a systemic vasculitis with respiratory tract involvement. It was named after Friedrich Wegener (1939) [1] who first established the syndrome. Until 1966, when Carrington & Liebow [1, 2] reported for the first time the limited forms of Wegener's granulomatosis, the disease was diagnosed with the classic triad (upper airway, pulmonary and renal involvement).

DeRemee proposed the "ELK" classification (1976) [3, 4] as a useful tool for clinical practice, assessing the extent of the organ system involvement: "E" stands for ear, nose and throat involvement; "L" for lung involvement; and "K" for kidney involvement. Clinical diagnosis is established on the following signs and symptoms:

In the limited forms: there are present symptoms of airway involvement such as nasal obstruction, epistaxis and crusting, vague pain over the nose and dorsum nasi tenderness. The onset signs and symptoms are often confused with a prolonged upper respiratory tract infection. On clinical exam it is encountered diffuse mucosal ulceration of the nose, with ulceration of the posterior surfaces of the vomer, with or without nasal septal perforation, with or without associated otologic, orbital, or upper tracheal involvement.

In more severe forms, all three sites (ELK) are involved with systemic symptoms such as severe malaise, weakness, night sweats and arthralgias with or without cutaneous involvement like tick-bite lesions on the lower extremities.

Paraclinical diagnosis should comprise a complete blood cell count, chemistry group, urinalysis, anticyto-

plasmatic autoantibodies (ACPA) test, rheumatoid factor and chest radiograph. In limited forms, there may be a mild anemia, minimal elevation of the erythrocyte sedimentation rate (30–50 mm in one hour), normal serum creatinine, urinalysis and negative chest radiograph. In the more severe forms, there are multiple lung cavity lesions and renal involvement (nonspecific glomerulonephritis) associated with abnormal urinary sediment and elevated serum creatinine levels. The paraclinical investigations will present a highly elevated erythrocyte sedimentation rate (above 100 mm in one hour), marked anemia and a very high titer ACPA test.

The most important factor in the diagnosis is represented by the nasal biopsy revealing a mucosal and submucosal inflammation with extensive necrosis and ulceration. There are also evident predominantly epithelioid necrotizing granulomas and vasculitis involving small arteries and veins. In addition, there is encountered a granulation tissue containing cells of chronic inflammation, occasionally with abundant eosinophils.

The ACPA based on the presence of serum antibodies (IgG) directed against cytoplasmic components of neutrophils in patients with Wegener's granulomatosis causing a characteristic diffuse cytoplasmic granular staining pattern in cytopsin preparations of neutrophils isolated from the blood of normal donors.

### Aim

The aim of this paper was to describe four confirmed cases of Wegener's granulomatosis with a prolonged

evolution for more than 10 years in a stable condition in one patient.

### ☞ Case reports

The authors present four clinical cases of Wegener's granulomatosis, the patients being hospitalized in our ENT Clinic, in a 10 years period. We retrospectively studied the medical documents of our patients. Nowadays, there is under the observation one case, because, unfortunately, the other three patients deceased.

#### Case No. 1

Female patient, I.Z., 27-year-old, has been transferred into Department of ENT, 3<sup>rd</sup> Clinic of Internal Medicine, Emergency County Hospital, Timișoara, Romania, with the following symptoms: left frontal headache, bilateral nasal obstruction, bilateral mucopurulent rhinorrhea and anosmia. Personal pathological antecedents: left chronic maxillary sinusitis, secondary anemia. The patient presented multiple hospitalizations for repeated epistaxis accompanied by bilateral nasal obstruction, anosmia, bilateral hearing loss, for approximately 1.5–2 years ago prior diagnosis.

Nasal rigid endoscopy showed bilateral nasal mucosa affected by a granulomatosis inflammatory process, hemorrhagic crusts and granulation tissue, septal ulceration (Figure 1). A biopsy has been performed, and the histopathological exam revealed a granulomatosis inflammatory process, with extensive fibrinoid necrotic zones and necrotic epithelioid granulomas. Paraclinic exam comprised on: erythrocyte sedimentation rate (ESR) 103 mm/h, hemoglobin (Hb) 8.6 mg%, hematocrit (Ht) 28.6%, blood urea 17mg%, serum creatinine 1 mg%, chest radiography – normal X-ray image, and ACPA test with high level of anticytoplasmic autoantibodies. The patient presented a segmental and focal chronic glomerulonephritis. Wegener's granulomatosis diagnosis has been established on the clinic, paraclinic and histopathological exam.

Biopsy revealed necrotising granulomatous vasculitis with Langhans' giant cells, neutrophil infiltration of the small arteries and venules and fibrinoid necrosis.

The patient was rehospitalized in the Department of Internal Medicine and started corticosteroid and Cyclophosphamide treatment. Serum ANCA (anti-neutrophil cytoplasmic antibody) were increased in the early phase of the disease, but normalized with treatment. No relapses have occurred. The clinical and laboratory analyses were performed at every third month, the patient being in a stable condition.

#### Case No. 2

Female patient, S.M., 25-year-old, presented to our Department of ENT with bilateral chemosis and nasal obstruction, mild dyspnea, headache and anosmia. Personal pathological antecedents revealed a bronchial asthma diagnosed three years ago. Nasal rigid endoscopic exam showed bloody crusts covering nasal mucosa (Figure 2) and a nasal septum cartilage perforation. The nasal biopsy and subsequent histopathological exam revealed a mucosal and submucosal inflammatory process. The patient underwent a dermatologic and biopsy exam

from elbows and knees petechial cutaneous lesions revealing a non-specific inflammatory process.

During admission period, the dyspnea has aggravated, especially the inspiratory phase. On nasopharyngolaryngeal fiber optic endoscopy, we encountered a subglottic stenosis (Figure 3). Paraclinic exam showed: ESR 120 mm/h, Hb 8.2 mg%, Ht 27.4%, chest radiography revealed multiple cavitary and non-cavitary nodules in both lungs and high level of anticytoplasmic autoantibodies on ACPA test. The patient presented a focal chronic glomerulonephritis and bilateral episcleritis.

The patient was transferred into Department of Internal Medicine and started corticosteroid and Cyclophosphamide treatment. The serum ANCA was still present. We performed frequent urinalyses and measurement of serum ANCA levels. The patient was followed by nephrologists specialized in the treatment of immunological diseases. The patient died three years later.

#### Case No. 3

Male patient, N.P., of 52-year-old has been admitted into our Department of ENT with the following symptoms and signs: bilateral nasal obstruction, oral breathing, bilateral mucopurulent rhinorrhea, headache, asthenia and severe malaise. The general clinical exam was under normal limits. Nasal endoscopic exam: nasal mucosa congested and swollen covered with bloody crusts and associated with mucosal ulceration. We performed a nasal biopsy with a histopathological exam: chronic inflammatory granulomatosis process with extended areas of suppurative necrosis. Paraclinical exam: ESR 116 mm/h, Hb 10.7%, serum creatinine 2.1 mg%, and high level of anticytoplasmic autoantibodies on ACPA test. The patient was admitted to Department of Nephrology and started the same therapeutic scheme, but after two years, the patient died.

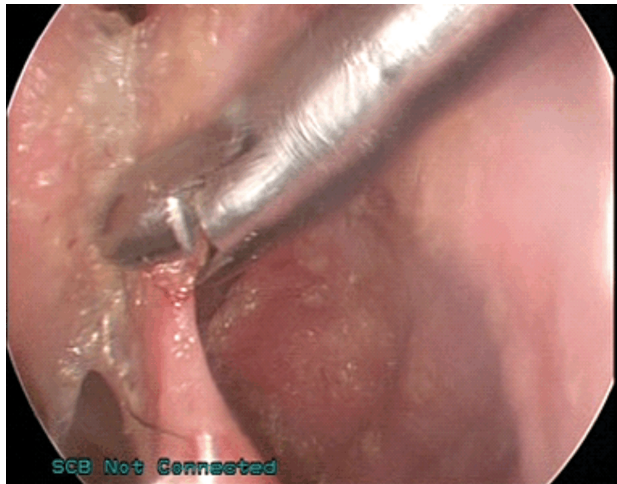
#### Case No. 4

Female patient, Z.I., 27-year-old, presented to the Department of Nephrology with the following diagnosis: ANCA positive vasculitis, chronic secondary glomerulonephritis with nephritic syndrome, urinary infection with *Klebsiella*, mild secondary anemia, respiratory insufficiency. Due to respiratory and aural symptoms and signs, the patient was addressed to our Department of ENT establishing the diagnosis: subglottic stenosis, bilateral suppurative otitis media, chronic nasal inflammatory granulomatous process, left maxillary and frontal sinusitis (Figure 4). A nasal biopsy has been performed revealing Wegener's granulomatosis. Paraclinical exam: ESR 91 mm/h, Hb 8.58%, serum creatinine 2.6 mg%, high level of anticytoplasmic autoantibodies on ACPA test, anti-MPO (myeloperoxidase antibody) was negative and anti-PR3 (proteinase 3) was positive. Chest X-ray was in normal limits. In Department of Nephrology, the patient started treatment with corticosteroid and Cyclophosphamide treatment with a favorable evolution. The patient developed a secondary arterial hypertension and iatrogenic secondary amenorrhea, segmental and focal chronic glomerulonephritis and deceased four years later. In Figures 5–10, there are Hematoxylin–Eosin (HE) staining, Periodic Acid–Schiff (PAS) reaction and argentic staining

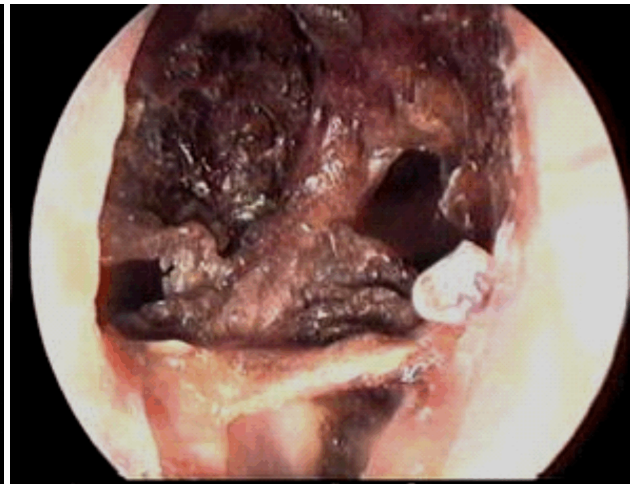


(PASM, Periodic Acid–Silver Methenamine) microscopic aspects of glomerulonephritis with loop necrosis, semi-

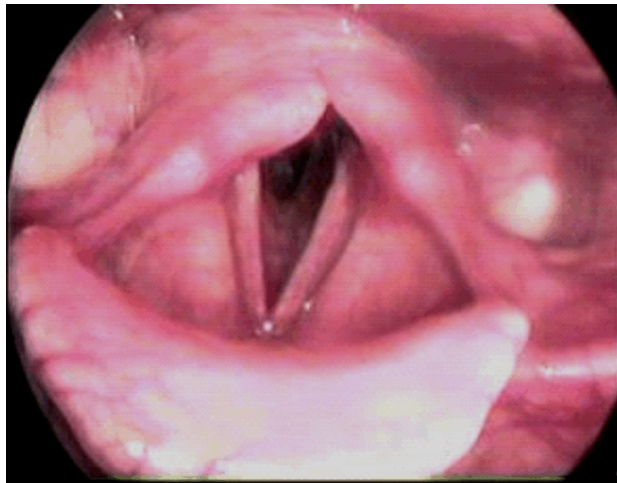
lunar cells and fibrosis (20×), skin ulceration and striated muscle inflammatory reactions.



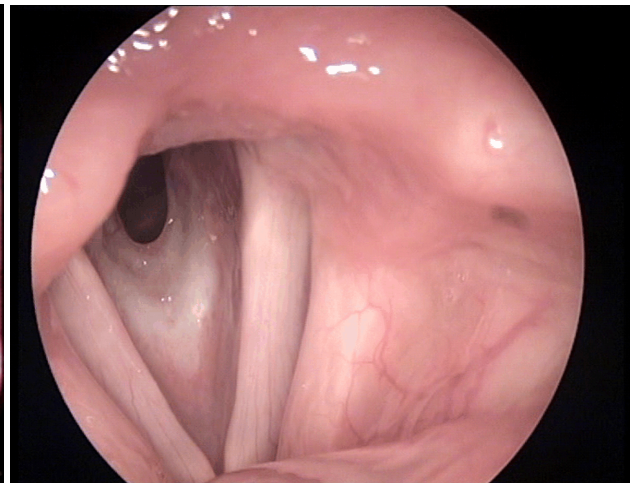
**Figure 1 – 0° nasal rigid endoscopic exam revealing the septal perforation and the biopsy forceps on granulomatous tissue.**



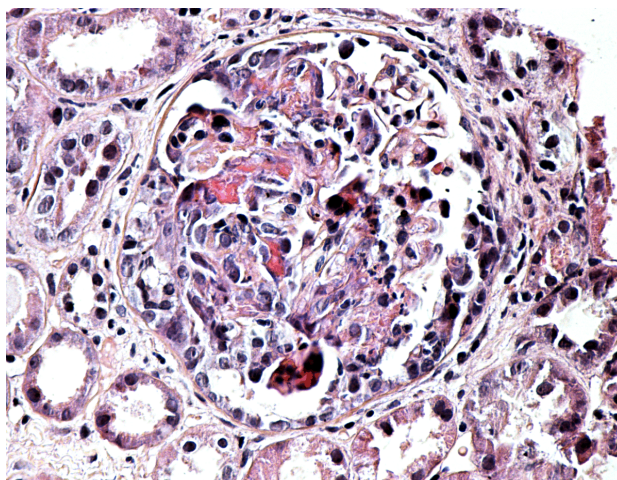
**Figure 2 – 0° nasal rigid endoscopic exam revealing in left nasal fossa in posterior 1/3, anterior to the left choanae, bloody crusts covering nasal mucosa.**



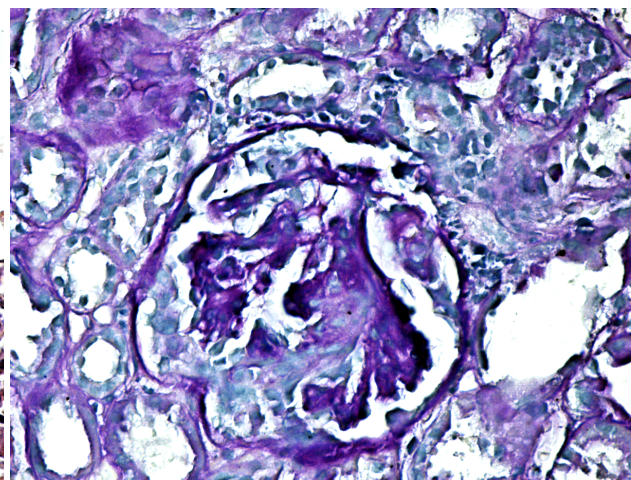
**Figure 3 – 70° rigid laryngeal endoscopic exam: normal aspect of the supraglottic and glottic level with subglottic stenosis.**



**Figure 4 – 70° rigid laryngeal endoscopic exam: subglottic concentric stenosis with respiratory impairment.**



**Figure 5 – Glomerulonephritis with loop necrosis and semilunar cells. HE staining, ×200.**



**Figure 6 – Glomerulonephritis with semilunar cells. PAS staining, ×200.**



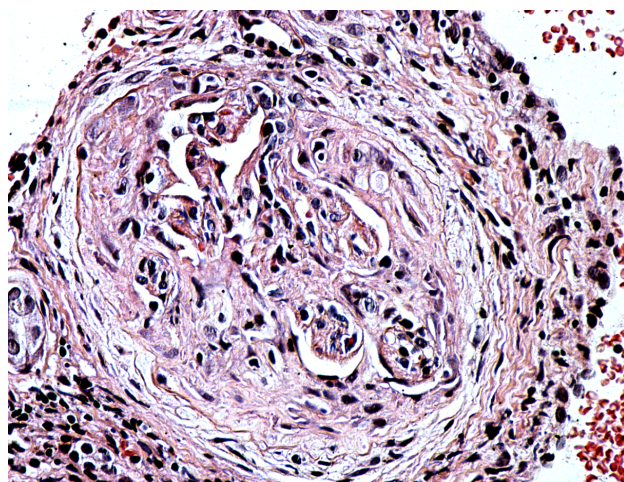


Figure 7 – Glomerulonephritis with semilunar fibrosis. HE staining,  $\times 200$ .

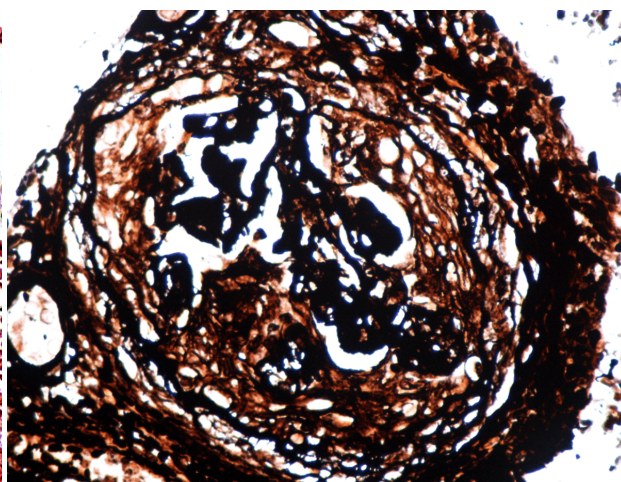


Figure 8 – Glomerulonephritis with semilunar fibrosis. Argentic staining (PASM),  $\times 200$ .

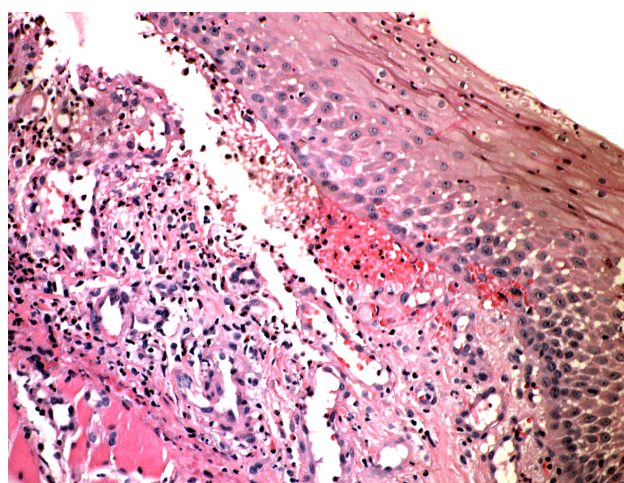


Figure 9 – Skin ulceration. HE staining,  $\times 200$ .

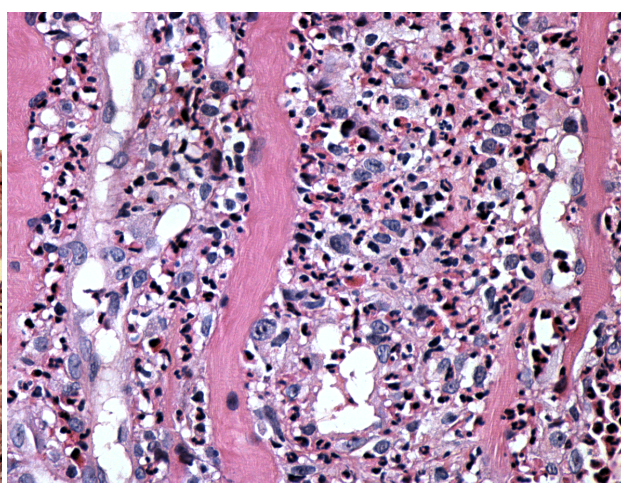


Figure 10 – Striated muscle inflammatory reactions underneath the skin ulceration. HE staining,  $\times 200$ .

## Discussion

Nasal granulomatosis lesions are determined by a variety of affections, with different etiology: bacterial, fungal or still unknown (Table 1). Lesion biopsy is essential not only for establishing the diagnosis of granulomatosis disease, but also for excluding a neoplasm [5].

Table 1 – Granulomatosis diseases of the nose

Bacterial etiology	Fungal etiology	Unspecified etiology
Rhinoscleroma	Rhinosporidiosis	Wegener's granulomatosis
Syphilis	Aspergillosis	Mediofacial malignant granuloma
Tuberculosis	Mucormycosis	Sarcoidosis
Lupus	Candidosis	
Leprosy	Blastomycosis	

Wegener's granulomatosis symptoms misinterpretation as respiratory tract infectious disease symptoms may appear especially in young patients [6]. There are indicated laboratory tests such as C-reactive protein (CRP) measurement, hemoleucogram, erythrocytes sedimentation rate, urinalysis and serology for detection of antibodies anti-glomerular basement membrane and ANCA. Disease prognosis is less favorable once the kidneys are affected [7]. Early detection and treatment of renal disease should

improve patient prognosis [8, 9]. Upper airway signs and symptoms involve nasal crusting, ulceration, and, in advanced cases, saddle nose by septal destruction [10]. Otological and ophthalmic implications are also common, being manifested as serous otitis media or conjunctivitis, episcleritis, uveitis and scleritis. Subglottic stenosis is not uncommon [11–13].

Pulmonary fibrosis has been rarely reported in patients with vasculitis and typically with active disease rather than after remission [14]. Pulmonary fibrosis has been occasionally reported to be associated with Cyclophosphamide therapy [15].

Up to 95% of patients will present with ear, nose and throat involvement as the first sign of the disease: signs as epistaxis, sinusitis, nasal disease or hearing loss. Granular, irregular thickening and crusting of the mucosa are characteristic aspects for Wegener's granulomatosis (WG). The nasal endoscopy is indicated showing typical mucosal changes [16, 17].

Cannady *et al.* studied 120 patients with nasal manifestations of WG. Their most frequent findings were: nasal crusts (69.2%), chronic sinusitis (60.8%), nasal obstruction (58.3%), bloody rhinorrhea (51.7%), septal perforation (32.5%) and "saddle nose" deformity (22.7%) [18].

Septal perforations were also common in these patients, due to vasculitis in the Kiesselbach's plexus, with consequent necrosis and cartilage resorption. There are few studies regarding septal perforation. Jennings *et al.* reported this finding in three of 49 (6%) patients studied [19]. In our paper, three out of four patients presented septal perforation. Regarding "saddle nose" deformity, this is described in 10–25% of patients with nasal involvement [18, 20, 21].

Ear involvement may occur in 20–70% of cases and often also represents the first sign of the disease [19, 21]. Involvement of the outer ear is rare, with the most common cases being external otitis secondary to chronic otitis media. The middle ear can be affected in 40–70% of cases [19, 22]. Otitis media with effusion is the most common otological manifestation of WG, secondary to dysfunction of the Eustachian tube [23–25]. Chronic suppurative otitis media is present in 24% of cases and may be complicated by contiguity with mastoiditis, which is associated with facial nerve palsy in 8–10% of cases [22, 26].

We administer steroids and Cyclophosphamide in all four cases, as an early stage favorable initial immunosuppressive regimen, being more advantageous than pulse doses, stage-adapted treatment, or Cyclosporin A [7, 26–30]. Other studies support the advantages of pulse doses of steroid [31] or Cyclophosphamide [32]. Relapses are common in this disease. Rituximab, a monoclonal antibody directed against the B-lymphocyte protein CD20, in combination with glucocorticosteroids, is considered a safe and effective alternative to Cyclophosphamide [33].

Springer *et al.* [34] assessed the length of treatment, considered as a continuous factor, and its inverse relationship with the risk of relapse (52% of relapses occurred while the patients were off maintenance therapy). Regarding overall side effects or disease related morbidity, the authors established no differences between the short- and long-term maintenance therapy groups [35].

The patient global assessment disease activity score rise is evaluated by the physician as a period of remission and subsequent disease relapse lowering, supporting the addition of this score in Wegener's granulomatosis outcome measurement [36, 37].

## ✉ Conclusions

Wegener's granulomatosis is a rare and a serious systemic vasculitis with preferential involvement of the respiratory tract, lungs, eyes and kidneys. The diagnosis is established based on the clinical and paraclinical exam, histopathological exam and ACPA test. Although the unfavorable prognosis is not related to the upper airway involvement but by kidney involvement (renal insufficiency because of chronic glomerulonephritis), the authors want to stress out the importance of ENT clinical exam and investigations needed to establish the diagnosis of a systemic disease. Notably significant for our four cases is the prolonged evolution for more than 10 years in a stable condition in one patient.

## Conflict of interests

The authors declare that they have no conflict of interests.

## Author contribution

C.A. Sarău, Marioara Poenaru, D.F. Lighezan, I.C. Doroș, E.H. Ștefănescu, Ioana Delia Horhat, and N.C. Balica performed the article design, patient diagnosis and follow-up evaluation. C.A. Sarău and Marioara Poenaru wrote the manuscript. All the authors design acquisition, analysis and interpretation of data in preparation of the article and approved the final version.

## Acknowledgments

This work was supported by the Department of ENT "Victor Babeș" University of Medicine and Pharmacy, Timișoara, Romania.

## References

- [1] Carrington CB, Liebow AA. Limited forms of angitis and granulomatosis of Wegener's type. *Am J Med*, 1966, 41(4): 497–527.
- [2] Daggett RB, Haghighi P, Terkeltaub RA. Nasal cocaine abuse causing an aggressive midline intranasal and pharyngeal destructive process mimicking midline reticulosis and limited Wegener's granulomatosis. *J Rheumatol*, 1990, 17(6):838–840.
- [3] DeRemee RA, McDonald TJ, Harrison EG Jr, Coles DT. Wegener's granulomatosis. Anatomic correlates, a proposed classification. *Mayo Clin Proc*, 1976, 51(12):777–781.
- [4] DeRemee RA, McDonald TJ, Weiland LH. Wegener's granulomatosis, polymorphic reticulosis, and lymphomatoid granulomatosis: a comparative analysis in sarcoidosis and other granulomatous diseases. *Proceedings of the 8<sup>th</sup> International Conference on Sarcoidosis and Other Granulomatous Diseases*, United Kingdom, Alpha Omega Publishing, 1980, 738–742.
- [5] McDonald TJ. Granulomatous diseases of the nose. In: English GM (ed). *Otolaryngology*. Vol. 2, J.B. Lippincott Co., Philadelphia, 1990, 1–14.
- [6] Stegmayr BG, Gothefors L, Malmer B, Müller Wiefel DE, Nilsson K, Sundelin B. Wegener granulomatosis in children and young adults. A case study of ten patients. *Pediatr Nephrol*, 2000, 14(3):208–213.
- [7] Briedigkeit L, Kettritz R, Göbel U, Natusch R. Prognostic factors in Wegener's granulomatosis. *Postgrad Med J*, 1993, 69(817):856–861.
- [8] Holle JU, Gross WL, Latza U, Nölle B, Ambrosch P, Heller M, Fertmann R, Reinhold-Keller E. Improved outcome in 445 patients with Wegener's granulomatosis in a German vasculitis center over four decades. *Arthritis Rheum*, 2011, 63(1):257–266.
- [9] Hilhorst M, Wilde B, van Paassen P, Winkens B, van Breda Vriesman P, Cohen Tervaert JW; Limburg Renal Registry. Improved outcome in anti-neutrophil cytoplasmic antibody (ANCA)-associated glomerulonephritis: a 30-year follow-up study. *Nephrol Dial Transplant*, 2013, 28(2):373–379.
- [10] Leavitt RY, Fauci AS. Less common manifestations and presentations of Wegener's granulomatosis. *Curr Opin Rheumatol*, 1992, 4(1):16–22.
- [11] Murty GE. Wegener's granulomatosis: otorhinolaryngological manifestations. *Clin Otolaryngol Allied Sci*, 1990, 15(4):385–393.
- [12] Bevelacqua F, Schicchi JS, Haas F, Axen K, Levin N. Aortic arch anomaly presenting as exercise-induced asthma. *Am Rev Respir Dis*, 1989, 140(3):805–808.
- [13] Mokoka MC, Ullah K, Curran DR, O'Connor TM. Rare causes of persistent wheeze that mimic poorly controlled asthma. *BMJ Case Rep*, 2013, 2013.
- [14] Bhanji A, Karim M. Pulmonary fibrosis – an uncommon manifestation of anti-myeloperoxidase-positive systemic vasculitis? *NDT Plus*, 2010, 3(4):351–353.
- [15] Hamada K, Nagai S, Kitaichi M, Jin G, Shigematsu M, Nagao T, Sato A, Mishima M. Cyclophosphamide-induced late-onset lung disease. *Intern Med*, 2003, 42(1):82–87.
- [16] Gottschlich S, Ambrosch P, Kramkowski D, Laudien M, Buchelt T, Gross WL, Hellmich B. Head and neck manifestations of Wegener's granulomatosis. *Rhinology*, 2006, 44(4): 227–233.

- [17] Haris M, Koulaouzidis A, Yasir M, Clark S, Kaleem M, Mallya R. Wegener's granulomatosis. *CMAJ*, 2008, 178(1):25–26.
- [18] Cannady SB, Batra PS, Koenig C, Lorenz RR, Citardi MJ, Langford C, Hoffman GS. Sinonasal Wegener granulomatosis: a single-institution experience with 120 cases. *Laryngoscope*, 2009, 119(4):757–761.
- [19] Jennings CR, Jones NS, Dugar J, Powell RJ, Lowe J. Wegener's granulomatosis – a review of diagnosis and treatment in 53 subjects. *Rhinology*, 1998, 36(4):188–191.
- [20] McDonald TJ, DeRemee RA. Wegener's granulomatosis. *Laryngoscope*, 1983, 93(2):220–231.
- [21] McDonald TJ, DeRemee RA, Kern EB, Harrison EG Jr. Nasal manifestations of Wegener's granulomatosis. *Laryngoscope*, 1974, 84(12):2101–2112.
- [22] Vartiainen E, Nuutinen J. Head and neck manifestations of Wegener's granulomatosis. *Ear Nose Throat J*, 1992, 71(9):423–424; 427–428.
- [23] Bradley PJ. Wegener's granulomatosis of the ear. *J Laryngol Otol*, 1983, 97(7):623–626.
- [24] Parra-García GD, Callejas-Rubio JL, Ríos-Fernández R, Sainz-Quevedo M, Ortego-Centeno N. Manifestaciones otorrinolaringológicas de las vasculitis sistémicas. *Acta Otorrinolaringol Esp*, 2012, 63(4):303–310.
- [25] Pereira DB, Amaral JLA, Szajubok JCM, Lima SMAL, Chahade WH. Otorhinolaryngologic manifestations of autoimmune rheumatic diseases. *Rev Bras Reumatol*, 2006, 46(2):118–125.
- [26] Takagi D, Nakamaru Y, Maguchi S, Furuta Y, Fukuda S. Otologic manifestations of Wegener's granulomatosis. *Laryngoscope*, 2002, 112(9):1684–1690.
- [27] Allen NB, Caldwell DS, Rice JR, McCallum RM. Cyclosporin A therapy for Wegener's granulomatosis. *Adv Exp Med Biol*, 1993, 336:473–476.
- [28] Briedigkeit L, Ulmer M, Göbel U, Natusch R, Reinhold-Keller E, Gross WL. Treatment of Wegener's granulomatosis. In: Gross WL (ed). *ANCA-associated vasculitides: immunological and clinical aspects*. Vol. 336, *Advances in Experimental Medicine and Biology*, 1993, 491–495.
- [29] Reinhold-Keller E, Kekow J, Schnabel A, Schwarz-Eywill M, Schmitt WH, Gross WL. Effectiveness of cyclophosphamide pulse treatment in Wegener's granulomatosis. *Adv Exp Med Biol*, 1993, 336:483–486.
- [30] Reinhold-Keller E, Kekow J, Schnabel A, Schmitt WH, Heller M, Beigel A, Duncker G, Gross WL. Influence of disease manifestation and antineutrophil cytoplasmic antibody titer on the response to pulse cyclophosphamide therapy in patients with Wegener's granulomatosis. *Arthritis Rheum*, 1994, 37(6):919–924.
- [31] Frascà GM, Zoumparidis NG, Borgnino LC, Neri L, Neri L, Vangelista A, Bonomini V. Combined treatment in Wegener's granulomatosis with crescentic glomerulonephritis – clinical course and long-term outcome. *Int J Artif Organs*, 1993, 16(1):11–19.
- [32] Georganas C, Ioakimidis D, Iatrou C, Vidalaki B, Iliadou K, Athanassiou P, Kontomerkos T. Relapsing Wegener's granulomatosis: successful treatment with cyclosporine-A. *Clin Rheumatol*, 1996, 15(2):189–192.
- [33] Bolton WK, Sturgill BC. Methylprednisolone therapy for acute crescentic rapidly progressive glomerulonephritis. *Am J Nephrol*, 1998, 9(5):368–375.
- [34] Springer J, Nutter B, Langford CA, Hoffman GS, Villa-Forte A. Granulomatosis with polyangiitis (Wegener's): impact of maintenance therapy duration. *Medicine (Baltimore)*, 2014, 93(2):82–90.
- [35] Adu D, Pall A, Luqmani RA, Richards NT, Howie AJ, Emery P, Michael J, Savage CO, Bacon PA. Controlled trial of pulse *versus* continuous prednisolone and cyclophosphamide in the treatment of systemic vasculitis. *QJM*, 1997, 90(6):401–409.
- [36] Clain JM, Cartin-Ceba R, Fervenza FC, Specks U. Experience with rituximab in the treatment of antineutrophil cytoplasmic antibody associated vasculitis. *Ther Adv Musculoskelet Dis*, 2014, 6(2):58–74.
- [37] Tomasson G, Davis JC, Hoffman GS, McCune WJ, Specks U, Spiera R, St Clair EW, Stone JH, Merkel PA. Brief report: The value of a patient global assessment of disease activity in granulomatosis with polyangiitis (Wegener's). *Arthritis Rheumatol*, 2014, 66(2):428–432.

### Corresponding author

Marioara Poenaru, Professor, MD, PhD, Department of ENT, "Victor Babeș" University of Medicine and Pharmacy, 6 Revoluției 1989 Avenue, 300024 Timișoara, Romania; Phone +40722–282 906, e-mail: marioara.poenaru@gmail.com

*Received: December 15, 2014*

*Accepted: July 8, 2015*