

## CASE REPORT

# Single ectopic thoracic renal artery associated with a normal kidney position and renal artery stenosis: a case report and review of literature

PETRU MATUSZ<sup>1)†</sup>, GRAȚIAN DRAGOSLAV MICLĂUȘ<sup>1,2)†</sup>, ABIGAIL GABRIEL<sup>3,4)</sup>, ILIA CATERENIUC<sup>5)</sup>, SORIN OLARIU<sup>6)</sup>, R. SHANE TUBBS<sup>7)</sup>, MARIOS LOUKAS<sup>3,8)</sup>

<sup>1)</sup>Department of Anatomy, "Victor Babeș" University of Medicine and Pharmacy, Timisoara, Romania

<sup>2)</sup>Neuromed Diagnostic Imaging Centre, Timisoara, Romania

<sup>3)</sup>Department of Anatomical Sciences, School of Medicine, St. George's University, Grenada, West Indies

<sup>4)</sup>Department of Internal Medicine, Harlem Hospital Center New York, New York, NY, USA

<sup>5)</sup>Department of Human Anatomy, "Nicolae Testemițanu" State University of Medicine and Pharmacy, Kishinev, Republic of Moldova

<sup>6)</sup>Department of Surgery II, "Victor Babeș" University of Medicine and Pharmacy, Timisoara, Romania

<sup>7)</sup>Pediatric Neurosurgery, Children's Hospital, Birmingham, AL, USA

<sup>8)</sup>Department of Anatomy, Medical School Varmia and Mazuria, Olsztyn, Poland

†These authors contributed equally to this work.

## Abstract

There are several reports of multiple ectopic renal arteries (RA) in the literature. However, the ectopic origin of a single RA with a normal kidney position is rare. Knowledge of this variant is extremely important in clinical, surgical and radiological practice. Using MDCT angiography examination, we describe a rare case of a right kidney located in a normal lumbal position with a single ectopic thoracic renal artery originating in the thorax, above the diaphragmatic dome, at the level of the upper one-third of the T12 vertebral body. With an "S"-shaped course and a total length of 103 mm, this artery had an intrathoracic portion of 38 mm. It crossed the diaphragm at 23 mm lateral to the right side of the TA, through a hiatus located on the lateral side of the right crus of the diaphragm. The right inferior phrenic artery arose from the left lateral wall of the right RA, 5 mm below the level of CT (45 mm distal to the right RA origin). Remarkably, this variant was associated with an area of proximal arterial stenosis, which produced signs and symptoms of hypertension secondary to renal arterial stenosis. To the authors' knowledge, this is the first reported case of a stenotic single ectopic thoracic renal artery associated with a normal kidney position.

**Keywords:** ectopic renal artery, thoracic origin, embryology, clinical implications, multidetector computed tomographic (MDCT) angiography.

## Introduction

There are several reports of multiple ectopic renal arteries (RA) in the literature [1, 2]. The ectopic origin of a single RA with a normal kidney position, however, is a rare variant. The first case of a single ectopic RA (SERA) without renal malformation or misposition was reported by Doppman in 1967 [3]. He described a RA originating at the level of the T11 vertebra, just beneath the right crus of the diaphragm. A comprehensive literature search using *SpringerLink*, *ScienceDirect*, *Wiley Online Library*, *Google Scholar*, and *PubMed* bibliographic databases demonstrated only 11 reports (12 cases in total) of this rare anatomic variant. Moreover, an explicit description of a thoracic origin of the RA has only been described in three cases [4, 5].

We report, by MDCT angiography, an extremely rare case of a right SERA originating in the thorax, above the diaphragmatic dome, at the level of the upper one-third of the T12 vertebral body (Figure 1). To our knowledge, this is only the fourth report of a SERA originating in the thorax with a normal kidney position. This is the

first case, however, of SERA diagnosed *in vivo* by MDCT angiography. In addition, this is the first reported case of SERA associated with renal artery stenosis at the level of the thorax.

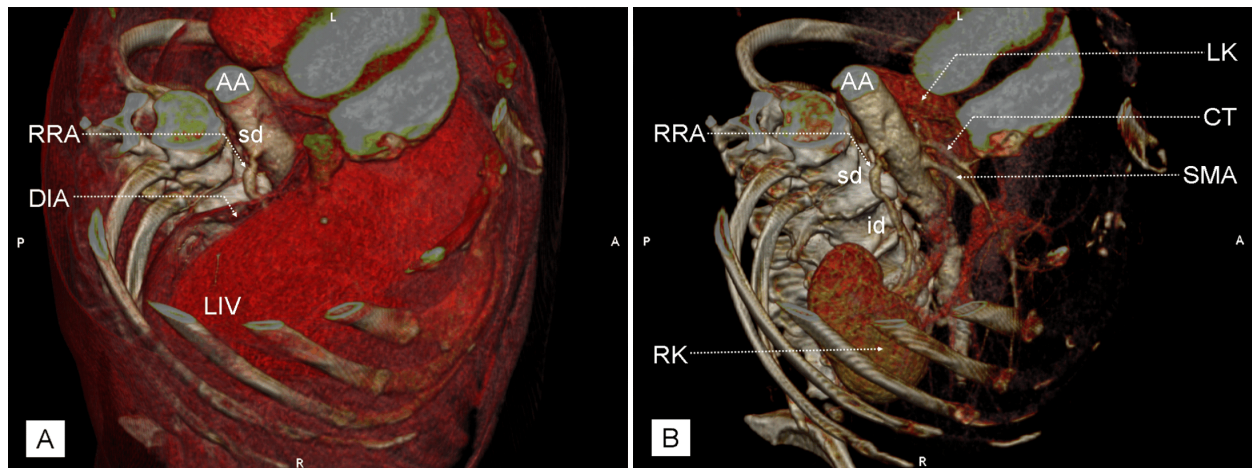
## Case report

We report a 72-year-old male who was examined for hypertension secondary to suspected renal artery stenosis. Imaging was performed using MDCT angiography (64-slice MDCT scanner, SOMATOM Sensation, Siemens Medical Solutions, Forchheim, Germany). All imaging data was reconstructed with a body soft tissue algorithm and transferred to an offline workstation (Syngo Multi Modality Workplace) for post-processing. The images were analyzed using a 3D task card, performing 3D Maximum Intensity Projection (MIP) reconstruction, and an in-space task card for 3D Volume Rendering Technique (VRT) reconstructions. The patient was found to have a right SERA originating in the thoracic region. In addition, the SERA was associated with a normal kidney position and an area of arterial stenosis, proximally.

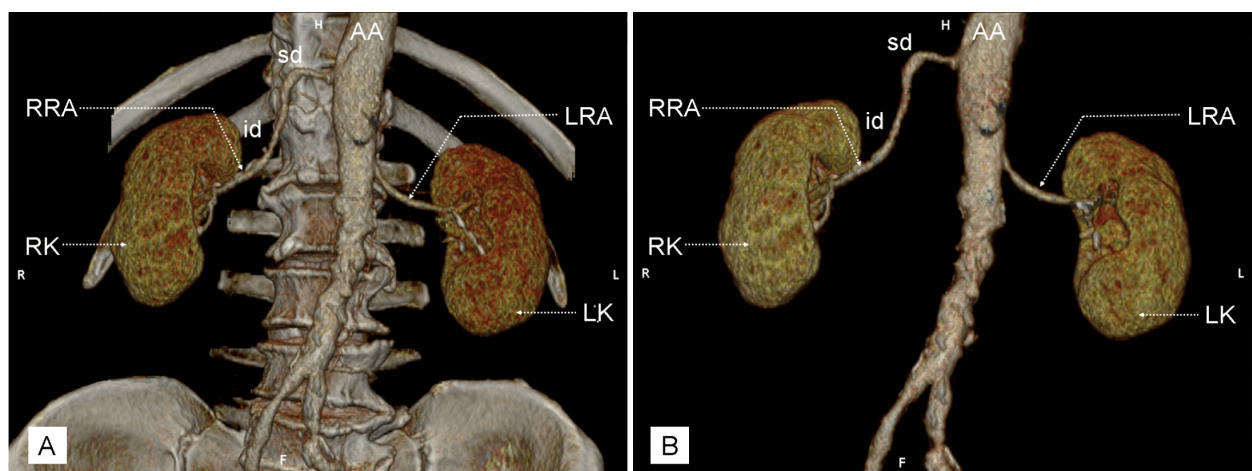
The superior pole of the right kidney was located at the level of the lower 1/3 of T12 vertebral body, which corresponded to the level of origin of the celiac trunk (CT). The superior pole of the left kidney was located at the level of the upper 1/3 of the L1 vertebral body, corresponding with the level of origin of the superior mesenteric artery (SMA) (Figure 2). The aortic hiatus was situated between the middle and lower 1/3 of the T12 vertebra, just above the CT origin. The SMA arose from the anterior wall of the abdominal aorta (AA), at the level of the upper 1/3 of the L1 vertebra. The right RA originated from the right side of the thoracic aorta (TA) at the level of the upper 1/3 of the T12 vertebra (35 mm above the origin of the SMA) and had an endoluminal diameter of 6.6 mm at its origin. With an “S”-shaped course and a total length of 103 mm, this artery had an intrathoracic portion of 38 mm. It crossed the diaphragm at 23 mm lateral to the right side of the TA, through a hiatus located on the lateral side of the right crus of the diaphragm. At the diaphragmatic level, the right RA had an endoluminal diameter of 5.8 mm. Most of the infradiaphragmatic course was located retrocavally (Figure 3). The left RA arose from the left lateral side of the AA at the level of the lower 1/3

of the L1 vertebra (18 mm below the origin of the SMA) and had an endoluminal diameter of 3.4 mm at its origin. The artery descended a total length of 52 mm. The distance between the level of origin of the CT and SMA was 13 mm, while the distance between the aortic origins of the respective renal arteries was 53 mm. The right inferior phrenic artery, which had an endoluminal diameter of 1.2 mm at its origin, arose from the left lateral wall of the right RA, 5 mm below the level of CT (45 mm distal to the right RA origin). The left inferior phrenic artery arose from the left lateral wall of the AA (24 mm above the level of CT) and had an endoluminal diameter of 1.65 mm at its origin (Figure 4). MDCT angiography did not reveal the presence or location of adrenal or testicular arteries.

The area of arterial stenosis of the right proximal RA had a length of 12.4 mm and a minimum endoluminal diameter of 4.0 mm. This was followed distally by a post-stenotic expansion with a length of 18.5 mm and a maximum endoluminal diameter of 8.4 mm (Figure 5). The calculated degree of renal arterial stenosis was 40%. After imaging diagnosis was obtained, the patient was admitted to a specialized endovascular treatment center where the stenotic artery was stented.

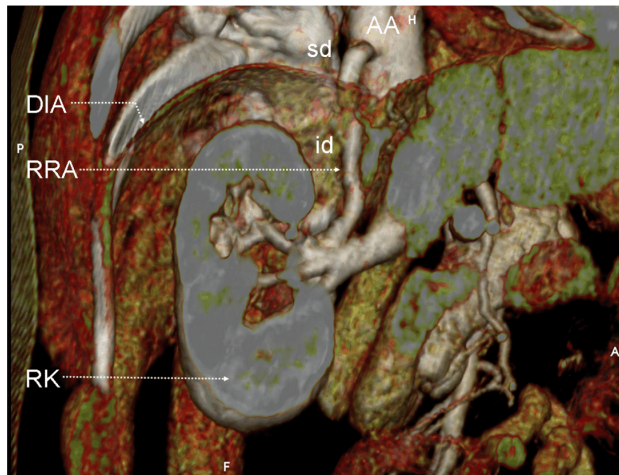


**Figure 1 – Right supero-lateral volume rendering images demonstrates the supra- and infradiaphragmatic part of the right renal artery: (A) with the liver in situ; (B) after subtraction of the liver. AA: Abdominal aorta; CT: Celiac trunk; DIA: Diaphragm; LIV: Liver; LK: Left kidney; RK: Right kidney; RRA: Right renal artery [id: Infradiaphragmatic part; sd: Supradiaphragmatic part]; SMA: Superior mesenteric artery.**

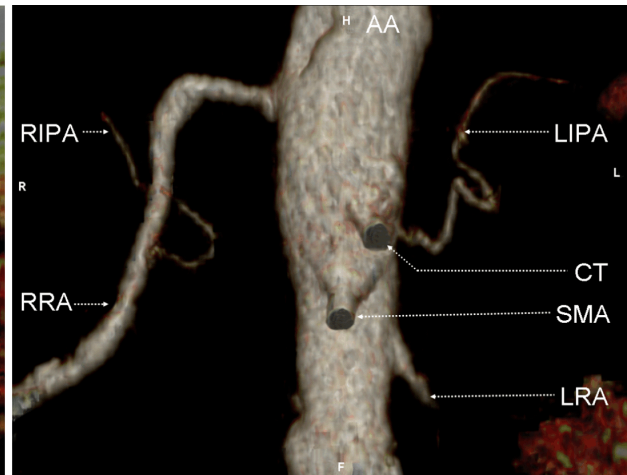


**Figure 2 – Coronal volume rendering images demonstrates the kidneys and the renal arteries: (A) with the relationship with the skeletal structures (vertebral bodies and costal arches); (B) after subtraction of the skeletal structure. AA: Abdominal aorta; LK: Left kidney; LRA: Left renal artery; RK: Right kidney; RRA: Right renal artery [id: Infradiaphragmatic part; sd: Supradiaphragmatic part].**

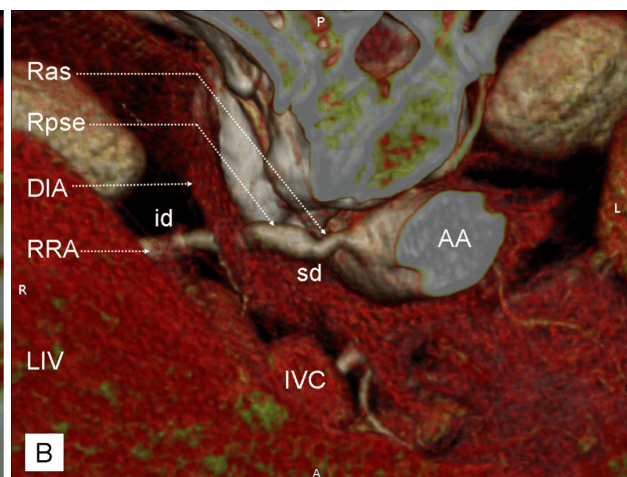
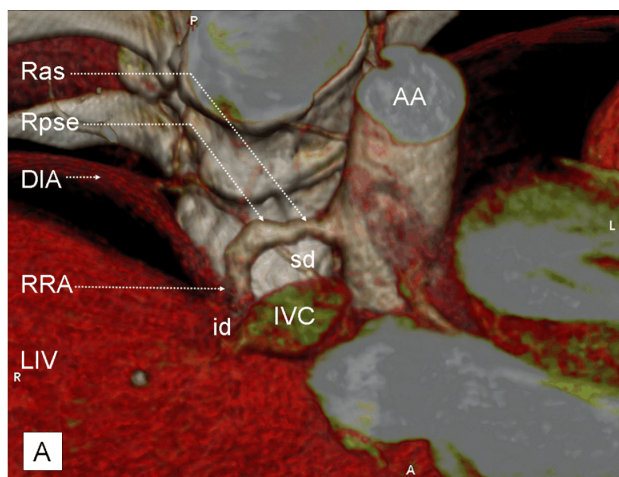




**Figure 3** – Coronal volume rendering images demonstrates the abdominal aorta with the origin of the inferior phrenic arteries (right and left). AA: Abdominal aorta; CT: Celiac trunk; LIPA: Left inferior phrenic artery; RIPA: Right inferior phrenic artery; LRA: Left renal artery; RRA: Right renal artery [id: Infradiaphragmatic part; sd: Supradiaphragmatic part]; SMA: Superior mesenteric artery.



**Figure 4** – Coronal volume rendering images demonstrates the supra-, trans- and infradiaphragmatic part of the right renal artery. AA: Abdominal aorta; DIA: Diaphragm; RK: Right kidney; RRA: Right renal artery [id: Infradiaphragmatic part; sd: Supradiaphragmatic part].



**Figure 5** – Volume rendering images demonstrates the supradiaphragmatic part of the right renal artery, with the renal artery stenosis and the renal post-stenotic expansion: (A) Coronal image; (B) Transversal image. AA: Abdominal aorta; DIA: Diaphragm; IVC: Inferior vena cava; LIV: Liver; RRA: Right renal artery [id: Infradiaphragmatic part; sd: Supradiaphragmatic part; Ras: Renal arterial stenosis; Rpse: Renal post-stenotic expansion]; SMA: Superior mesenteric artery.

## Discussion

### Embryology

An embryologic explanation regarding the thoracic origin of a single renal artery must include three points: (i) the development of three pairs of “kidneys” (the primitive first stage – pronephros; the transitory kidney – mesonephros; and the permanent kidney – metanephros), (ii) the development of the renal arteries, and (iii) the development of the diaphragm. The metanephros appears in the pelvis, at the level of S1–S2, in the 28<sup>th</sup>–32<sup>nd</sup> days of gestation [6]. Between the 6<sup>th</sup> and 9<sup>th</sup> week of gestation the kidneys rotate medially and ascend in the retroperitoneal space from the pelvic to the lumbar level. Upon this evolution, the mesonephros is supplied on either side by a maximum of 30 mesonephric arteries [7]. These arteries are temporary aortic branches [8–10] distributed

from the 6<sup>th</sup> cervical to the 3<sup>rd</sup> lumbar segments. At the 18 mm embryo, there is complete degeneration of mesonephros. At this stage, there are nine mesonephric arteries, distributed from the 10<sup>th</sup> thoracic to the 3<sup>rd</sup> lumbar segments [7]. Normally, all but one mesonephric artery degenerates, leaving the remaining artery at the level of the 2<sup>nd</sup> lumbar vertebral body. This artery becomes the main renal artery (metanephric artery), which persists into adult life [9, 10]. The rapid growth of the dorsal part of the embryo results in an apparent descent of the diaphragm. By the 6<sup>th</sup> week, the developing diaphragm is at the level of the thoracic somites. At the beginning of the 8<sup>th</sup> week, its dorsal part lies at the level of the first lumbar vertebra. The diaphragm assumes its adult shape and position at 12–13 weeks of gestation [11].

Although the embryology of the SERA remains obscure, it is easy to imagine that an ectopic main renal

artery may develop when a more caudal [9] or cephalad [8] mesonephric artery persists at the metanephric stage, while all other arterial mesonephric branches involute. This process has only been reported unilaterally and most commonly on the right (Table 1). In the case of the presence of the more cephalad SERA (with origin in the

TA), this process must be associated with the relative descent of the mesonephric arteries [7] and a possible slowing of the apparent descent of the diaphragm, thus retaining the position of the RA within the thoracic cavity (at the level of the inferior TA).

**Table 1 – Reported cases of the single ectopic renal artery (with the kidney a normal position)**

Author(s)	Year	Method of diagnosis	No. of cases	Left/Right	Level of origin	Structure of origin	Symptoms and associated lesions
Doppman [3]	1967	Aortogram	1	Right	T11	Upper abdominal aorta, beneath the right crus of the diaphragm.	
Tegtmeyer & Stanton [12]	1969	Aortogram	1	Right	T11	Aorta agenesis of the left kidney	Agenesis of the left kidney. Discomfort of several weeks' duration in the left lower quadrant of the abdomen. Normal right kidney and collecting system
Cerny & Karsch [13]	1973	Aortogram	1	Right	T11	Aorta 6 cm proximal to the celiac axis	Hypertension. Routine intravenous pyelogram were described as normal. Tortuous course of the right renal artery with presence of an aneurysm.
Garti & Meiraz [8]	1980	Angiography	1	Left	Upper 1/2 T12	Aorta 2 cm cephalad to the exit of the celiac trunk	Advanced hirsutism and secondary amenorrhea of eighteen months' duration.
		Angiography	1	Left	T12-L1 interspace	Celiac trunk	Lymphadenopathy, bilateral leg edema, and weight loss.
Wilms <i>et al.</i> [14]	1987	Angiography	1	Right	T12	Aorta above the origin of the visceral arteries	
van Baalen & van Bockel [5]	1994	Angiography	1	Right	T11	Lower thoracic aorta	
Cocheteux <i>et al.</i> [15]	2001	Helical-CT angiography	2/1389	Right	T11	Lower thoracic aorta	
Inoue <i>et al.</i> [16]	2003	Surgical procedure	1	Right	Unspecified	Lower abdominal aorta	
Malcolm <i>et al.</i> [17]	2007	CT angiography	1	Left	T11-T12 interspace	Upper abdominal aorta	
Sueyoshi <i>et al.</i> [4]	2009	CT angiography	1	Right	Upper 1/3 T12	Lower thoracic aorta	
Nachiappan <i>et al.</i> [18]	2011	MRI and CT scan	1	Right	T12-L1 interspace	Celiac trunk	
Matusz <i>et al.</i> (present case)	2014	MDCT angiography	1	Right	Upper 1/3 T12	Lower thoracic aorta	Hypertension, thoraco-abdominal bruit on physical exam

### Origin level of SERA

The kidneys are normally situated retroperitoneal, flanking the vertebral column. The superior and inferior poles usually lie at T12 and L3, respectively, although the right kidney is slightly inferior and medially, which reflects its relationship to the liver [19]. The right and left main RA originate between the upper margin of L1 and the lower margin of L2 vertebrae in 98% and 97% of cases, respectively [20]. The origin of multiple ectopic RAs (additional and accessory) varies between the level of the common iliac artery [2] and the lower part of the TA [21]. Their presence is usually associated with an ectopic position of the kidney. The majority of the reports analyzing the origin of a SERA in relationship to the vertebral bodies [3, 5, 12, 13] highlight its origin from the aorta at the level of the T11 vertebra.

The origin of the CT is considered to be the least variable, with the inferior mesenteric artery (IMA) demonstrating the greatest variability [22]. Using spiral CT angiography and arteriography in 100 patients, Beregi *et al.* [23] demonstrated that 50% of cases have the right and left renal ostia at the same level; in 37% of cases,

the ostium of the right RA was located above that of the left RA. The mean distance between the origin of the right RA and SMA was 14.5 mm (range from 2 to 35 mm). The mean distance between the origin of the left RA and SMA was 18 mm (range from 4 to 50 mm). The relationship between the SMA and the renal ostia is an important one when considering diagnostic renal arteriography and endovascular interventions, such as balloon angioplasty and endoluminal stenting [22, 23]. The majority of reports describing the aortic origin of the SERA in relationship to the anterior visceral branches of the AA [5, 14, 24] highlight its origin above the CT. Garti & Meiraz [8] described two cases of ectopic left RA: one originated above the CT and the other from the CT itself. Additionally, Nachiappan *et al.* [18] reported one case of ectopic right RA originating from the celiac trunk.

The majority of previous reports [3–5, 12–16] describe the SERA located on the right side. When the SERA is reported to originate at the thoracic level, all reports have been exclusively of a right-sided SERA [5, 12, 15]. Indeed, in our case report the thoracic SERA was also located on the right.

## Clinical implication

Knowledge of variations of the renal vascular anatomy is important for diagnosis and treatment of renal trauma, conservative or radical renal surgery, renal transplantation, surgery for abdominal aortic aneurysm, renal artery embolization, renovascular hypertension and angioplasty or a vascular reconstruction for congenital and acquired lesions [9]. Variations of the renal vasculature are relatively common, with a reported incidence of 20–75% [25]. A single main ectopic renal artery is an extremely rare variant and has important clinical and surgical implications.

Given the considerable variability in renal vascular anatomy, preoperative vascular mapping should be routinely used in order to avoid intraoperative complications [9, 17]. Garti & Meiraz, in 1980 [8], demonstrated that whenever the main renal artery lies parallel with the aorta (with the kidney in normal position), high ectopic origin of the main renal artery should be suspected.

Previous reports [13] suggest that aberrant renal vessels (especially the lower polar renal artery) can lead to obstruction of the ureteropelvic junction and the proximal ureter. However, Glodny *et al.* [1] demonstrated, in 1072 patients (2132 kidneys) *via* MDCT scan, that accessory or additional renal arteries have no significant affect on the width of the upper urinary tract.

Renal artery stenosis accounts from approximately 1–5% of all hypertensive patients and is usually secondary to atherosclerosis (80%) or fibromuscular dysplasia (20%) [26]. Atherosclerotic renal artery stenosis usually affects the proximal one-third or the aortorenal ostium of the main renal artery, and often the adjacent aorta [27]. Corriere *et al.* [28] demonstrated that 73% of atherosclerotic renal artery stenosis was categorized as ostial, while 18% involved the proximal renal artery, and 9% involved the truncal renal artery. Severe atherosclerotic renal artery stenosis can result in post-stenotic dilatation of the artery [29]. A study by Marshall [30] demonstrated a significantly higher incidence of aberrant renal arteries in hypertensive than in normotensive patients, suggesting a causal relationship secondary to renal ischemia. Using current methods of diagnosis and treatment, renal artery stenosis (including stenosis of a SERA, as in our patient) is a correctable cause of hypertension.

Early report [31] reveal on six studies involving 1696 cases, that the origin of the RIPA was: CT in 27.5% of cases, AA in 24.5% of cases, right renal artery (RRA) in 9.5% of cases, left gastric artery (LGA) in 2% of cases, hepatic artery proper (HAP) in 0.5% of cases and testicular/ovarian artery in 0.05% of cases. In unresectable hepatocellular carcinoma (HCC) transcatheter arterial chemoembolization is used for treatment. In these situations, even when the hepatic artery is patent, six groups of extrahepatic collateral arteries supplied the tumoral parenchyma [32]. Kim *et al.* [33] analyzing 3179 cases of unresectable HCC, revealed that the RIPA is the first, and LIPA is the sixth most common vessel that supplies peripherally located hepatocellular carcinomas. In our case, RIPA rose from the left lateral wall of the right RA, 45 mm distal to the right RA origin (5 mm below the level of CT) making impossible the catheter approach *via* the abdominal aorta and right renal artery.

## Conclusions

Review of the literature has demonstrated that the single ectopic thoracic renal artery is an extremely rare phenomenon. This anatomical variant is usually present on the right side. Use of MDCT angiography offers excellent three-dimensional reformatted images, which are helpful in delineating details of the supradiaphragmatic origin of the ectopic thoracic renal artery. In addition, MDCT angiography also provides clear imaging of the thoraco-abdominal border, which is helpful in evaluating the stenotic segments. Identifying such a variant prior to any radiological or surgical interventions is crucial in order to prevent possible complications.

## Conflict of interests

The authors declare that they have no conflict of interests.

## References

- [1] Glodny B, Rapf K, Unterholzner V, Rehder P, Hofmann KJ, Straszak A, Herwig R, Petersen J. Accessory or additional renal arteries show no relevant effects on the width of the upper urinary tract: a 64-slice multidetector CT study in 1072 patients with 2132 kidneys. *Br J Radiol*, 2011, 84(998):145–152.
- [2] Satyapal KS, Haffjee AA, Naidoo ML, Robbs JV, Akojee S, Ramsaroop L. Rare additional renal artery in live-related transplantation. *Clin Anat*, 2006, 19(4):363–364.
- [3] Doppman J. An ectopic renal artery. *Br J Radiol*, 1967, 40(472):312–313.
- [4] Sueyoshi E, Sakamoto I, Uetani M. Right renal artery originating above celiac axis. *J Vasc Surg*, 2009, 49(6):1588.
- [5] van Baalen JM, van Bockel HJ. Thoracic origin of right renal artery. *J Vasc Surg*, 1994, 19(4):762–763.
- [6] Woolf AS, Winyard PJD, Hermanns MH, Welham SJM. Maldevelopment of the human kidney and lower urinary tract: an overview. development of kidney blood vessels. In: Vize PD, Woolf AS, Bard JBL (eds). *The kidney: from normal development to congenital disease*. Academic Press, China, 2003, 377–393.
- [7] Felix W. The development of the urogenital organs. In: Keibel F, Mall FP (eds). *Manual of human embryology*. Vol. II, Lippincott & Crowell, Philadelphia, 1912, 752–799.
- [8] Garti I, Meiraz D. Ectopic origin of main renal artery. *Urology*, 1980, 15(6):627–629.
- [9] Halloul Z, Meyer F, Buerger T. Ectopic vascularization of the right kidney by a contralateral origin of the main renal artery from the left common iliac artery: report of a case. *Surg Today*, 2001, 31(4):371–373.
- [10] Miclaus GD, Matusz P. Bilateral quadruple renal arteries. *Clin Anat*, 2012, 25(8):973–976.
- [11] Moore KL, Persaud TVN, Torchia MG. The developing human: clinically oriented embryology. 8<sup>th</sup> edition, W. B. Saunders–Elsevier, Philadelphia, 2008, 249–255.
- [12] Tegtmeyer CJ, Stanton LW. Thoracic origin of a single renal artery. *JAMA*, 1969, 209(8):1223.
- [13] Cerny JC, Karsch D. Aberrant renal arteries. *Urology*, 1973, 2(6):623–626.
- [14] Wilms G, Borremans JP, Oyen R, Baert AL. Une artère rénale ectopique [Ectopic renal artery]. *J Radiol*, 1987, 68(2):137–138.
- [15] Cocheteux B, Mounier-Vehier C, Gaxotte V, McFadden EP, Francke JP, Beregi JP. Rare variations in renal anatomy and blood supply: CT appearances and embryological background. A pictorial essay. *Eur Radiol*, 2001, 11(5):779–786.
- [16] Inoue T, Oka H, Saga T. Renal preservation in low ectopic right renal artery reconstruction during abdominal aortic aneurysm repair: report of a case. *Surg Today*, 2003, 33(2): 117–119.
- [17] Malcolm JB, Derweesh IH, Gold R. Ectopic supraceliac renal artery take-off: imaging with digital subtraction angiography and computed tomography angiography. *Urology*, 2007, 69(4): 776–777.

- [18] Nachiappan S, Franks S, Thomas P. Single ectopic main right renal artery originating from the coeliac axis. *J Surg Case Rep*, 2011, 12:10.
- [19] Standing S, Ellis H, Berkovitz BKB, Gray H (eds). *Gray's anatomy: the anatomical basis of clinical practice*. 40<sup>th</sup> edition, Elsevier-Churchill Livingstone, Edinburgh, 2008, 1225–1238.
- [20] Özkan U, Oğuzkurt L, Tercan F, Kizilkiliç O, Koç Z, Koca N. Renal artery origins and variations: angiographic evaluation of 855 consecutive patients. *Diagn Interv Radiol*, 2006, 12(4):183–186.
- [21] Fernet M, Goldlust D, Salama J, Chevrel JP. A case of ectopic right renal artery: a radiologic-anatomic variant. *Surg Radiol Anat*, 1987, 9(4):319–320.
- [22] Pennington N, Soames RW. The anterior visceral branches of the abdominal aorta and their relationship to the renal arteries. *Surg Radiol Anat*, 2005, 27(5):395–403.
- [23] Beregi JP, Mauroy B, Willoteaux S, Mounier-Vehier C, Rémy-Jardin M, Francke JP. Anatomic variation in the origin of the main renal arteries: spiral CTA evaluation. *Eur Radiol*, 1999, 9(7):1330–1334.
- [24] Schaffer R, Gordon DH, Glanz S. Renal artery. Originating above celiac axis. *N Y State J Med*, 1981, 81(7):1109–1111.
- [25] Bayazit M, Göl MK, Zorlutuna Y, Tasdemir O, Bayazit K. Bilateral triple renal arteries in a patient with iliac artery occlusion: a case report. *Surg Radiol Anat*, 1992, 14(1):81–83.
- [26] Coulier B. Multidetector-row CT of renal arteries: review of the performances in normo- and hypertensive patients. *JBR-BTR*, 2005, 88(6):311–321.
- [27] Kaatee R, Beek FJ, Verschuyt EJ, vd Ven PJ, Beutler JJ, van Schaik JP, Mali WP. Atherosclerotic renal artery stenosis: ostial or truncal? *Radiology*, 1996, 199(3):637–640.
- [28] Corriere MA, Edwards MS, Pearce JD, Andrews JS, Geary RL, Hansen KJ. Restenosis after renal artery angioplasty and stenting: incidence and risk factors. *J Vasc Surg*, 2009, 50(4):813–819.e1.
- [29] Lao D, Parasher PS, Cho KC, Yeghiazarians Y. Atherosclerotic renal artery stenosis – diagnosis and treatment. *Mayo Clin Proc*, 2011, 86(7):649–657.
- [30] Marshall AG. Aberrant renal arteries and hypertension. *Lancet*, 1951, 2(6686):701–705.
- [31] Miclaus GD, Matusz P, Loukas M, Ples H. Rare case of the trunk of the inferior phrenic arteries originating from a common stem with a superior additional left renal artery from the abdominal aorta. *Clin Anat*, 2012, 25(8):979–982.
- [32] Matusz P, Loukas M, Iacob N, Ples H. Common stem origin of left gastric, right and left inferior phrenic arteries, in association with a hepatosplenomesenteric trunk, independently arising from the abdominal aorta: case report using MDCT angiography. *Clin Anat*, 2013, 26(8):980–983.
- [33] Kim HC, Chung JW, Lee W, Jae HJ, Park JH. Recognizing extrahepatic collateral vessels that supply hepatocellular carcinoma to avoid complications of transcatheter arterial chemoembolization. *Radiographics*, 2005, 25(Suppl 1):S25–S39.

### **Corresponding author**

Sorin Olariu, Associate Professor, MD, PhD, Department of Surgery II, “Victor Babeș” University of Medicine and Pharmacy, 2 Eftimie Murgu Square, 300041 Timișoara, Romania; Phone +40723–658 323, Fax +40256–494 403, e-mail: [smolariu@yahoo.com](mailto:smolariu@yahoo.com)

*Received: December 20, 2014*

*Accepted: May 10, 2015*