

CASE REPORT

Segmental aganglionosis in Hirschsprung's disease in newborns – a case report

RADU NINEL BĂLĂNESCU, LAURA BĂLĂNESCU, ANDREEA ALECSANDRA MOGA, GABRIEL CRISTIAN DRĂGAN, FLORIN BOGDAN DJENDOV

Department of Pediatric Surgery, "Grigore Alexandrescu" Clinical Emergency Hospital for Children, Bucharest, Romania

Abstract

Segmental aganglionosis Hirschsprung's is an extremely rare condition. Described as a segment of normally ganglionated bowel surrounded proximally and distally by aganglionosis, zonal aganglionosis is of interest because it may cause confusion in interpreting surgical margins. Diagnosis of segmental lesions in Hirschsprung's disease may be missed as it is rarely suspected at initial surgery. We report the case of a 2-week-old baby girl admitted to our clinic for abdominal distension and vomiting. Considering the family history (near total colonic aganglionosis in a 2-month-old sister with unfavorable outcome), the suspicion of Hirschsprung's is raised and serial large intestine biopsies are taken. Intraoperatively, a transverse colon stenosis caused by an incomplete web is noticed and segmental colectomy with anastomosis is performed at this level. Histopathological and immunohistochemical results established the diagnosis of segmental transverse colon aganglionosis, with the presence of ganglia cells in the ascending and descending colon. Subtotal colectomy with ascending colon pull-through was performed with favorable postop evolution. In our patient, the association with a transverse colon stenosis raised suspicion concerning the diagnosis of Hirschsprung's disease, but considering the family history, extended biopsies were taken and the correct diagnosis of zonal aganglionosis was established. Although zonal aganglionosis lesions are extremely rare, this case illustrates the point that the presence of ganglia cells at the resection line is not sufficient to guarantee postoperative function. Extended intestinal biopsies should be included in the algorithm for management of long segment Hirschsprung's disease and will enable the surgeon to correctly detect zonal aganglionosis.

Keywords: Hirschsprung's disease, zonal aganglionosis, immunohistochemistry, congenital megacolon.

Introduction

Hirschsprung's disease (HD), also known as "congenital megacolon" is characterized by the absence of ganglion cells in the myenteric and submucosal plexus of the intestine [1–4]. The absence of ganglion cells begins in the distal rectum and extends proximally for varying distances [5, 6]. The etiopathogenic mechanisms of the disease are only known in part. It is known that, during the embryonic development, the nervous system of the intestine structure mainly develops from the cells derived from the vagal area of the neural crests, which caudally migrate, thus colonizing the entire length of the intestine. During this migration process through the primitive intestine wall mesenchyme, the cells derived from the neural crests behave as multipotent progenitor cells, as they proliferate and differentiate in the glial neurons and cells [7]. Even though there have been made significant progresses in the biological study of derived cells from the neural crests [8], the mechanisms that trigger the migration of these cells, its cessation and the proliferation and differentiation in specific and/or glial neuronal phenotypes, are not completely known [9].

Unusual or "variant" forms of Hirschsprung's disease have been described over the years, leading to considerable discussion. "Zonal aganglionosis" is a rare phenomenon (only 28 cases reported in the literature), which involves a zone of aganglionosis occurring within normally ganglionated intestine [6, 10]. Diagnosis of segmental aganglionosis in HD may be missed as it is rarely suspected at initial surgery.

We present the case of a 2-week-old baby girl, who was diagnosed with a particular form of Hirschsprung's disease, namely segmental aganglionosis.

Case report

We report the case of a 2-week-old baby girl admitted to our clinic for abdominal distension and vomiting. The patient history reveals delayed passing of meconium. The family history reveals a 2-month-old sister diagnosed with near total colonic aganglionosis with unfavorable outcome. The clinical exam shows a distended abdomen, with generalized bloating. The patient is started on daily enemas with clinical improvement. The family history and clinical appearance raises the suspicion of Hirschsprung's disease and a contrast enema is performed. No pathognomonic findings are seen on the radiological study, so the patient is scheduled for serial intestinal biopsies. Intraoperatively, the rectum, sigmoid, descending colon and left transverse colon were of slightly reduced caliber and right transverse colon, ascending colon and cecum were dilated, with no typical transition zone. An enterotomy is performed at the level of the decalibration zone and an incomplete mucosal web is noticed. Resection of this segment and a termino-terminal colo-colonic anastomosis is performed. Leveling biopsies from the rectum, sigmoid, descending, transverse and ascending colon are sent for histopathological and immunohistochemical analysis (Figure 1).

Immunohistochemistry for calretinin and S100 was performed and the results showed the presence of gan-

glionic cells in the rectum, descending and ascending colon (Figures 2 and 3), and the absence of ganglionic cells in the transverse colon (Figures 4 and 5).

One month later, the patient underwent a subtotal colectomy with ascending colon transanal pull-through.

The postoperative evolution was uneventful. The patient began having bowel function two days post surgery, with 8–10 stools per day. She is currently being monitored on an outpatient basis. Three months after the surgery, she gained weight satisfactorily and she is having 3–4 stools per day.

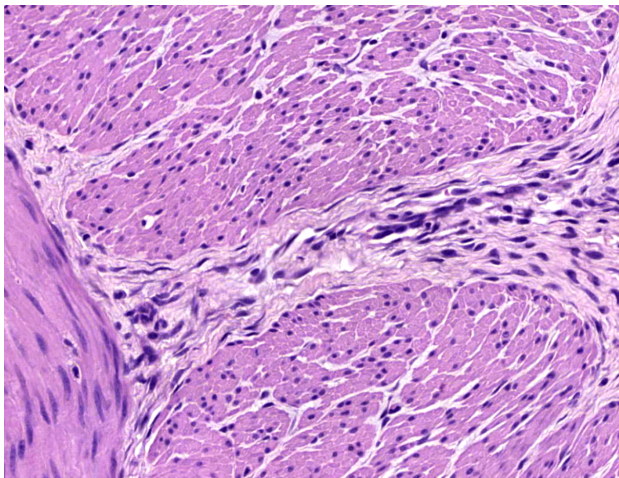


Figure 1 – Presence of nervous cells, but absence of ganglion cells in the transverse colon. HE staining, $\times 400$.

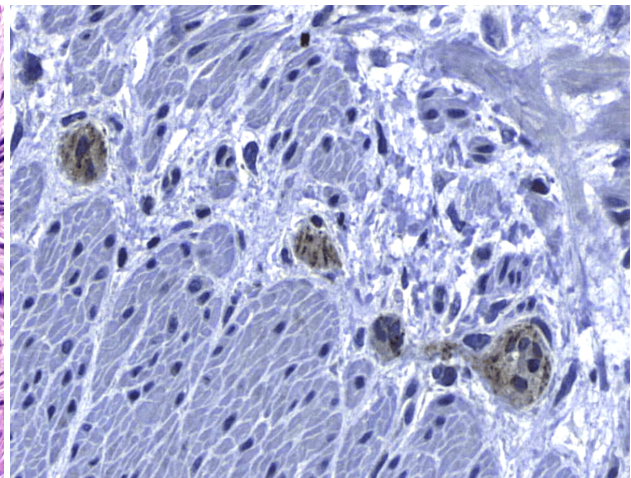


Figure 2 – Positive calretinin reaction in ganglion cells at the ascending colon. Immunomarking with anti-calretinin antibody, $\times 400$.

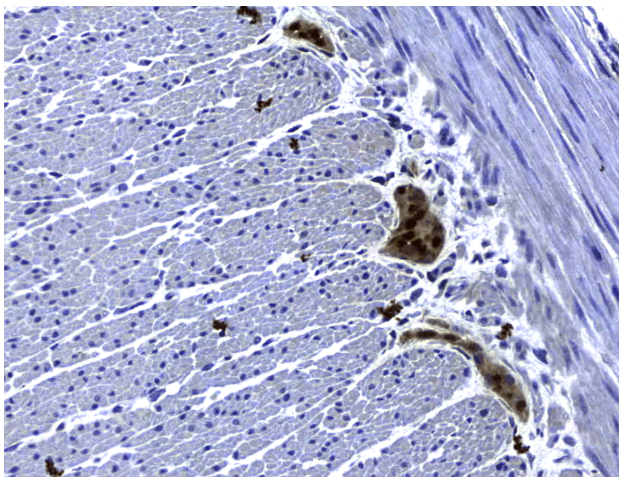


Figure 3 – Positive S100 immunohistochemistry in ganglion cells at the ascending colon. Immunomarking with anti-S100 antibody, $\times 400$.

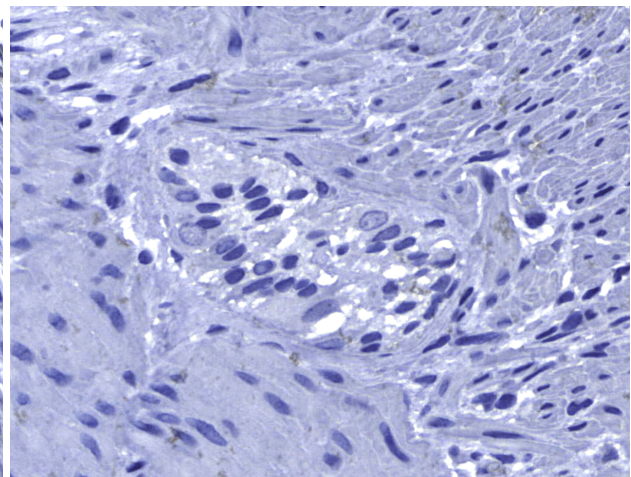


Figure 4 – Absence of ganglion cells in the transverse colon (negative reaction of calretinin). Immunomarking with anti-calretinin antibody, $\times 400$.

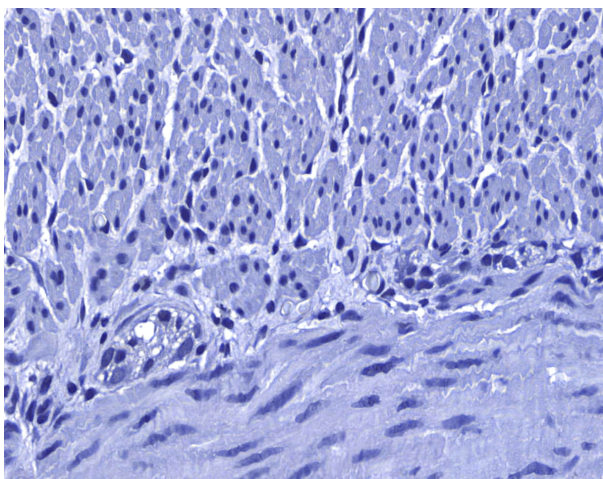


Figure 5 – Rare ganglion cells with positive S100 immunohistochemistry in the transverse colon. Immunomarking with anti-S100 antibody, $\times 400$.

Discussion

HD occurs in approximately 1:5000 live births [11, 12]. Approximately 80% of children have a ‘transition zone’ in the rectum or rectosigmoid colon. Another 10% have more proximal colonic involvement, and about 5–10% have total colonic aganglionosis with variable involvement of the distal small intestine. Rarely, babies are afflicted with near-total intestinal aganglionosis [5, 13].

Over the years, “variant” forms of the typical Hirschsprung’s disease phenotype have been reported leading to considerable discussions. “Skip segment” Hirschsprung’s disease (SSHD) involves a “skip area” of normally ganglionated intestine, surrounded proximally and distally by aganglionosis. Zonal or segmental aganglionosis involves a zone of aganglionosis occurring within normally innervated intestine. While Hirschsprung’s disease is believed to be the result of incomplete cranio-caudal migration of neural crest-derived cells, the occurrence

of these “variant” forms has no clear embryological explanation [5, 6, 10].

In the majority of Hirschsprung's cases, no clear pattern of inheritance exists. Patients with very long-segment aganglionosis seem to have a higher rate of familial incidence. In our case, the patient was diagnosed with segmental aganglionosis in the transverse colon and had a family history of near total colonic aganglionosis [6, 14].

Once the diagnosis of HD is suspected from clinical and contrast enema findings, the diagnosis must be confirmed by intestinal biopsies. The proximal extent of the biopsies is roughly guided by the location of the transition area as detected on the contrast enema or by surgical findings of dilated intestine proximal to the aganglionic segment. However, there is often a significant geographical discrepancy between the radiological and pathological transition zones and surgical judgment of pathological transition zones are often inaccurate and hence cannot be relied upon to determine the proximal extent of biopsies [10, 14]. The existence of the “variant” forms of HD makes the decision-making in biopsy level and surgical management much more difficult. In our case, the intraoperative discovery of a transverse colon stenosis made the diagnosis of HD less likely. However, considering the family history, leveling biopsies were performed [5, 14].

The gold standard for the diagnosis is the absence of ganglion cells in the submucosal and myenteric plexuses on histological examination. Most patients will also have evidence of hypertrophied nerve trunks, although this finding is not always present, particularly in children with total colonic disease or a very short aganglionic segment [12]. Recently, in addition to Hematoxylin and Eosin (HE), it has been shown that immunohistochemical staining for calretinin is almost always absent in patients with HD [5, 6]. In our patient, the histological examination and immunohistochemical analysis of calretinin and S100 confirmed the presence of ganglion cells in the rectum, ascending and descending colon, and the absence of ganglion cells in a segment in the transverse colon.

Calretinin is a binding protein of the intracellular calcium, working as a modulator for neuronal excitability. That is why its expression is quite high within the neurons [15–18]. Numerous studies showed that this immunomarker is very useful in diagnosing the Hirschsprung's disease [19–22]. In our case, the absence of neurons in the myenteric and submucosal plexus of the transverse colon generated the whole digestive symptoms, through the absence of contractility and motility of that specific colon segment. Some studies showed that, alongside the absence of ganglionic cells in the colon, there also appeared abnormally thickened nervous trunks [23], microscopic aspects characteristic to the immature peripheral nerves [24, 25].

Our case shows that Hirschsprung's disease is a congenital condition, our patient having a sister with total colonic aganglionosis, who deceased at the age of two months.

✎ Conclusions

“Skip lesion” and zonal aganglionosis are two rare forms of Hirschsprung's disease. Clinical and radiological

findings are useful, but not pathognomonic, making the diagnosis and treatment of these forms very difficult. Extensive intestinal biopsies, including the cecum and terminal ileum could prevent misdiagnosis of SSHD or segmental aganglionosis.

Conflict of interests

The authors declare that they have no conflict of interests.

References

- [1] Bennett A, Garrett JR, Howard ER. Adrenergic myenteric nerves in Hirschsprung's disease. *Br Med J*, 1968, 1(5590): 487–489.
- [2] Howard ER. Hirschsprung's disease: a review of the morphology and physiology. *Postgrad Med J*, 1972, 48(562): 471–477.
- [3] Guirguis E. Hirschsprung's disease: a review. *Can Fam Physician*, 1986, 32:1521–1523.
- [4] Ferris Villanueva E, Guerrero Bautista R, Chica Marchal A. Hirschsprung disease associated with Mowat–Wilson syndrome: report of a case. *Nutr Hosp*, 2015, 31(4):1882–1884.
- [5] Moore SW, Sidler D, Schubert PA. Segmental aganglionosis (zonal aganglionosis or “skip” lesions) in Hirschsprung's disease: a report of 2 unusual cases. *Pediatr Surg Int*, 2013, 29(5):495–500.
- [6] Raghunath BV, Shankar G, Babu MN, Kini U, Ramesh S, Jadhav V, Aravind KL. Skip segment Hirschsprung's disease: a case report and novel management technique. *Pediatr Surg Int*, 2014, 30(1):119–122.
- [7] Obermayr F, Hotta R, Enomoto H, Young HM. Development and developmental disorders of the enteric nervous system. *Nature Rev Gastroenterol Hepatol*, 2013, 10(1):43–57.
- [8] Sasselli V, Pachnis V, Burns AJ. The enteric nervous system. *Dev Biol*, 2012, 366(1):64–73.
- [9] Wilkinson DJ, Bethell GS, Shukla R, Kenny SE, Edgar DH. Isolation of enteric nervous system progenitor cells from the aganglionic gut of patients with Hirschsprung's disease. *PLoS One*, 2015, 10(5):e0125724.
- [10] Erten EE, Çavuşoğlu YH, Arda N, Karaman A, Afşarlar ÇE, Karaman I, Özgüner IF. A rare case of multiple skip segment Hirschsprung's disease in the ileum and colon. *Pediatr Surg Int*, 2014, 30(3):349–351.
- [11] Rosai J. Rosai and Ackerman's surgical pathology. 9th edition, vol. 2. Mosby, New York, 2004, 777–779.
- [12] Alehossein M, Roohi A, Pourgholami M, Mollaeian M, Salamati P. Diagnostic accuracy of radiologic scoring system for evaluation of suspicious Hirschsprung disease in children. *Iran J Radiol*, 2015, 12(2):e12451.
- [13] Castle S, Suliman A, Shayan K, Kling K, Bickler S, Losasso B. Total colonic ganglionosis with skip lesions: report of a rare case and management. *J Pediatr Surg*, 2012, 47(3):581–584.
- [14] Doi T, O'Donnell AM, McDermott M, Puri P. Skip segment Hirschsprung's disease: a rare phenomenon. *Pediatr Surg Int*, 2011, 27(7):787–789.
- [15] Parmentier M, Passage E, Vassart G, Mattei MG. The human calbindin D28k (CALB1) and calretinin (CALB2) genes are located at 8q21.3–q22.1 and 16q22–q23, respectively, suggesting a common duplication with the carbonic anhydrase isozyme loci. *Cytogenet Cell Genet*, 1991, 57(1):41–43.
- [16] Baimbridge KG, Celio MR, Rogers JH. Calcium-binding proteins in the nervous system. *Trends Neurosci*, 1992, 15(8): 303–308.
- [17] Weidmann S, Schrödl F, Neuhauser W, Brehmer A. Quantitative estimation of putative primary afferent neurons in the myenteric plexus of human small intestine. *Histochem Cell Biol*, 2007, 128(5):399–407.
- [18] Jande SS, Maler L, Lawson DE. Immunocytochemical mapping of vitamin D-dependent calcium binding protein in brain. *Nature*, 1981, 294(5843):765–767.
- [19] Kapur RP, Reed RC, Finn LS, Patterson K, Johanson J, Rutledge JC. Calretinin immunohistochemistry versus acetylcholinesterase histochemistry in the evaluation of suction rectal biopsies for Hirschsprung disease. *Pediatr Dev Pathol*, 2009, 12(1):6–15.

- [20] Holland SK, Ramalingam P, Podolsky RH, Reid-Nicholson MD, Lee JR. Calretinin immunostaining as an adjunct in the diagnosis of Hirschsprung disease. *Ann Diagn Pathol*, 2011, 15(5):323–328.
- [21] Hiradfar M, Sharifi N, Khajedaluee M, Zabolinejad N, Taraz JS. Calretinin immunohistochemistry: and aid in the diagnosis of Hirschsprung's disease. *Iran J Basic Med Sci*, 2012, 15(5): 1053–1059.
- [22] Yadav L, Kini U, Das K, Mohanty S, Puttegowda D. Calretinin immunohistochemistry *versus* improvised rapid acetylcholinesterase histochemistry in the evaluation of colorectal biopsies for Hirschsprung disease. *Indian J Pathol Microbiol*, 2014, 57(3):369–375.
- [23] Kobayashi H, O'Briain DS, Puri P. Nerve growth factor receptor immunostaining suggests an extrinsic origin for hypertrophic nerves in Hirschsprung's disease. *Gut*, 1994, 35(11):1605–1607.
- [24] Wang X, Chan AKK, Sham MH, Burns AJ, Chan WY. Analysis of the sacral neural crest cell contribution to the hindgut enteric nervous system in the mouse embryo. *Gastroenterol*, 2011, 141(3):992–1002.e1–6.
- [25] Erickson CS, Zaitoun I, Haberman KM, Gosain A, Druckenbrod NR, Epstein ML. Sacral neural crest-derived cells enter the aganglionic colon of *Ednrb*^{-/-} mice along extrinsic nerve fibers. *J Comp Neurol*, 2012, 520(3):620–632.

Corresponding author

Laura Bălănescu, MD, Department of Pediatric Surgery, "Grigore Alexandrescu" Clinical Emergency Hospital for Children, 32–34 Iancu de Hunedoara Avenue, Sector 1, 011743 Bucharest, Romania; Phone +40722–984 237, e-mail: laura7balanescu@yahoo.com

Received: January 10, 2015

Accepted: June 25, 2015