

Microscopic morphological changes of the tooth surface in relation to fixed orthodontic treatment

CRISTINA TEODORA PREOTEASA¹⁾, DAN FLORIN NIȚOI²⁾, ELENA PREOTEASA³⁾

¹⁾Department of Oral Diagnosis, Ergonomics, Scientific Research Methodology, Faculty of Dental Medicine, "Carol Davila" University of Medicine and Pharmacy, Bucharest, Romania

²⁾Department of Materials Technology and Welding, Polytechnic University of Bucharest, Romania

³⁾Department of Prosthodontics, Faculty of Dental Medicine, "Carol Davila" University of Medicine and Pharmacy, Bucharest, Romania

Abstract

Orthodontic treatment has, as any other medical intervention, in addition to its benefits, side effects, some of them being perceived as unavoidable. The aim of this case series was to microscopically evaluate the changes of the tooth surface in relation to fixed orthodontic treatment. A case series study was implemented by the usage of four extracted first maxillary premolars, from patients with previous orthodontic treatment, of 12 and 23 months. Analysis was performed using the high precision stereomicroscope (Axiovert, Carl Zeiss, Germany), at magnifications from 10× to 50×. The tooth surface corresponding to the bracket bonding area registered numerous disorderly grooves and cracks, with various directions and depths, and was flattened, having lower convexity compared to teeth surfaces where brackets were not bonded. Root resorption lacunae were more frequently observed in teeth under orthodontic treatment, these having various depths, and sizes considerably larger than those observed in teeth without orthodontic treatment. Following orthodontic treatment, teeth exhibit changes that can be perceived as being directly linked to this medical intervention. These teeth changes usually have low or moderate severity, which can be influenced at some degree by the clinical conduct of the orthodontic treatment. The stereomicroscope proved to be a high sensitivity tool for the analysis of morphological changes of teeth in relation to the fixed orthodontic treatment.

Keywords: bracket, bonding, stereomicroscope, root resorption, enamel.

Introduction

Orthodontic treatment, due to its positive health effects and also associated esthetic benefits, has currently an increased use. Even so, as in any other treatment, in addition to benefits, side effects may occur, these being perceived sometimes as being unavoidable [1, 2]. Among others, morphological changes of the tooth surface are encountered, related part to specific treatment factors, and part to patient's particularities. These are localized both on the crown or root of the tooth, different etiological factors being implied.

Morphological changes of the surface of the tooth crown where orthodontic brackets are bonded are at most importance, considering their impact on the esthetic appearance. Bonding and debonding the brackets associates inherent morphological changes, which sometimes negatively influences the esthetic treatment outcome, this being frequently a primary treatment objective from patient's point of view [3, 4]. These alterations may be enhanced by patients' behavioral risk factors as improper oral hygiene maintenance, which promotes development of caries lesion, which implies also additional morphological changes of tooth surface [5]. Usually, patients related factors have a greater impact on the severity of the alterations, as compared to treatment related factors. Considering that most frequently brackets are bonded on the buccal tooth surfaces, and also acknowledging these alterations' negative impact on dento-facial esthetics, numerous researches aiming to identify

the techniques and materials that minimize them as much as possible, as well as assessing the best treatment conduct to prevent them, were implemented.

Morphological changes of the root of the tooth are usually integrated to root resorption, condition that is perceived as being encountered, with different severity degrees, to all orthodontic treated patients. Its etiology also relates to treatment and patient's factors. Increased root apices displacement, higher or continues orthodontic forces, increased duration of the orthodontic treatment, teeth extractions in orthodontic purposes are the main treatment related risk factors for a more increase degree of the severity of root resorption. Even so, high severity root resorption is seen as mainly being encountered in relation to a rather unknown and difficult to identify patient related risk factor, usually named "individual susceptibility". Several studies confirmed that predisposition to root resorption exists and is enhanced by the orthodontic treatment, these results mainly being based upon depicting higher incidence of severe root resorption in patients with signs of this alteration prior to orthodontic therapy. Other patient related risk factors, as systemic conditions (allergies, asthma, diabetes, metabolic diseases) and oral particularities (density of alveolar bone, type of dental anomaly, abnormal root morphology, hypodontia) were linked to higher severity of this condition [6, 7].

In order to properly address these side effects of orthodontic treatment, both preventively and therapeutically, knowledge of their manifestation is mandatory. The

usually used assessment methods (*i.e.*, by clinical and radiological means) have their limitations in depicting low severity alterations, as well as some of their main features.

The aim of this case series was to assess by microscopic and radiological means in conjunction, the changes of tooth surface related to fixed orthodontic treatment, by usage of extracted teeth with prior orthodontic treatment.

☐ Materials and Methods

A case series study was implemented on extracted teeth, from patients with previous orthodontic treatment. Usage of these teeth was possible by identifying, in the Department of Orthodontics and Dento-Facial Orthopedics of the Faculty of Dentistry, "Carol Davila" University of Medicine and Pharmacy, Bucharest, Romania, of two cases with fixed orthodontic appliances, on which was considered appropriate to change the treatment plan, with the assessment of the need to extract the maxillary first premolars for orthodontic purposes. Prior to teeth extraction, in all cases, explanations were brought to patients and their legal guardians and informed consent was obtained for this study, namely the patients agreed to give the extracted teeth in order to be microscopically analyzed.

Therefore, seven extracted teeth were analyzed: four first maxillary premolars with previous orthodontic treatment of 12 and 23 months, in which self-cured acrylic resins were used as bracket bonding material (as the study group), and three teeth with other clinical situations (*i.e.*, one included wisdom tooth, two newly erupted maxillary first premolars extracted for orthodontic purposes).

Tooth surface was analyzed considering two significant areas, regarding the orthodontic treatment context. Therefore, there were analyzed the tooth crowns, considering the changes that appear as a result of the bracket bonding, and also the tooth roots, as localization of the root resorption process, condition that is perceived as being unavoidable during orthodontic treatment. Mainly microscopic analysis was performed, this being used comparatively with the radiological examination, for the root resorption analysis.

The microscopic analysis was performed using the high precision stereomicroscope (Axiovert, Carl Zeiss, Germany). This type of optical microscope was considered appropriate, taking into account the convexity of the tooth surfaces, as favoring a lower image distortion. Progressive magnifications were used (of 10× to 50×), in order to acknowledge surface characteristics. For sample stabilization, teeth were placed into a putty holder. The crown of the teeth was analyzed to depict changes of the surface corresponding to the bracket bonding area. Therefore, both buccal and lingual surfaces of the teeth crown, for all teeth with or without orthodontic treatment, were analyzed. The tooth roots were analyzed in the apical part, as site where root resorption is usually encountered with the highest severity, but also to the lateral sides of the roots. Mainly root resorption signs were targeted, that corresponds to the microscopic aspect of root surface with higher rugosity and tooth substance loss corresponding to the aspect of lacunae of root resorption. Additionally, periapical radiographs were

made for all extracted teeth, in order to assess root resorption severity by the method that is generally used during clinical practice. This analysis is mainly based upon evaluating the contour line of the tooth root, as presenting or not irregularities or a blunted shape.

Microscopic evaluation of these teeth, by usage of lower magnifications, up to 5×, was previously reported and discussed, in the manuscript referred being presented more information regarding the patients and coordinates of the orthodontic treatment, the teeth extraction and preparation [8].

☐ Results

Microscopic analysis revealed surface particularities that can be considered specific to the orthodontic treatment, as a direct effect of bracket bonding, or as indirect effect of orthodontic forces and tooth movement.

The tooth surface corresponding to the bracket bonding area (middle third of the buccal surface of the tooth crown) had a different microscopic aspect compared to the lingual crown surface of the same tooth, or the ones of the teeth from the control group. The bracket bonding area registered numerous disorderly grooves and cracks, with various directions, that were superficial, but with various depths (Figure 1). This microscopic aspect probably is related to the removal of the bracket and the remained bonding material with burs, this aspect persisting despite of tooth surface polishing that was done. The lingual surface of the same teeth registered a more uniform microscopic aspect of the surface. Surface grooves were also encountered in some of the teeth, but fewer and more superficial compared to the buccal aspect. They are probably integrated to the occlusal contacts during oral functions. Buccal surfaces of the teeth without prior orthodontic treatment had a uniform microscopic aspect, without grooves (Figure 2). Also, on a comparative view, the surface where the bracket was bonded was the flattest, with lower convexity compared to the lingual surfaces or the buccal one where brackets were not bonded. This aspect may be linked to hard tissue loss during clinical procedures of bracket bonding and removal.

Root resorption lacunae were observed in both groups, with and without orthodontic treatment, but with differences regarding their frequency and size. In teeth with previous orthodontic treatment, root resorption lacunae were observed more frequently, in size at about tens of μm diameter (Figure 3). Root resorption lacunae were observed also in the recently erupted premolars, but with a reduced frequency and reduced size, having usually a diameter less than 5 μm (Figure 4). Also, lacunae of root resorption for the previous orthodontic treated teeth had shown more frequently higher variability regarding their depth and localization – in both root apices and lateral sides of the tooth root (Figure 5).

Periapical radiographs of the teeth revealed an aspect slightly suggestive for root resorption process for some of the teeth with prior orthodontic treatment. In these, a slightly irregular contour of the apical part of the root was noticed, indicating a decreased root resorption severity. In one tooth, in one root, a more severe alteration was observed, with a blunted aspect of the root apex. Even so, most probably the signs of root

resorption are probably more obvious when radiographs are made of extracted teeth, compared to *in vivo* radiographs, due to eliminating the overlapping of the adjacent oral structure.

The teeth without orthodontic treatment presented a regular linear contour of the root. The recently erupted premolars presented the characteristic image of erupting

teeth, with wide-open apex. Therefore, there was considered that radiological signs of decreased severity root resorption were encountered only in the study group, namely in the teeth with previous orthodontic treatment, and were not encountered in the control group, namely teeth without prior orthodontic treatment.




Figure 1 – Microscopic aspect of the enamel corresponding to the bracket bonding area.




Figure 2 – Microscopic aspect of the enamel of the buccal surface, in teeth without orthodontic treatment.




Figure 3 – Root resorption lacunae in teeth under orthodontic treatment, with lacunae of various diameter (e.g., diameter of 99 μm , respectively 64 μm).

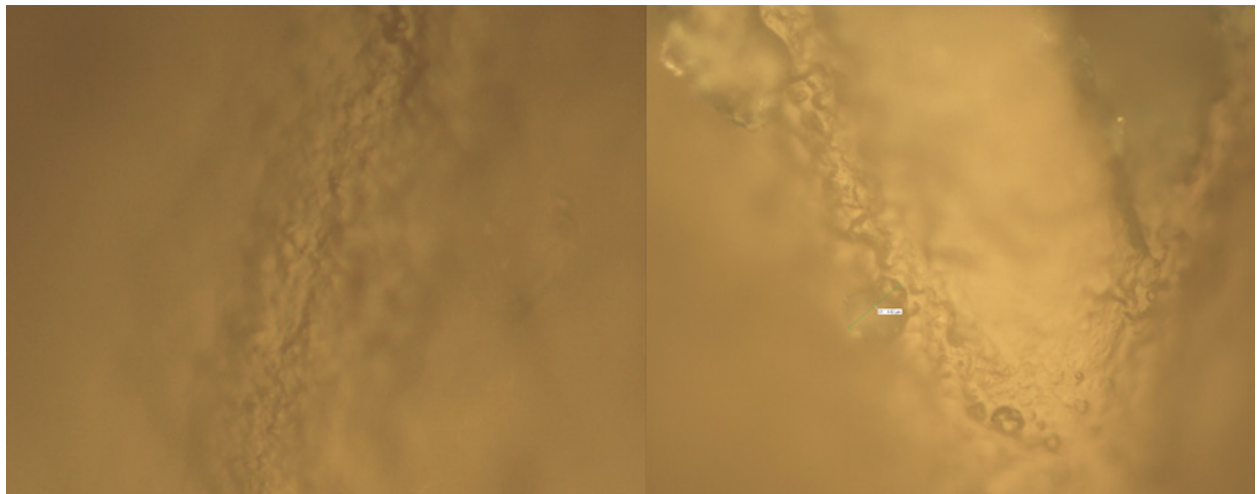


Figure 4 – Root resorption lacunae in teeth without orthodontic treatment, with lacunae diameter usually less than 5 μm .

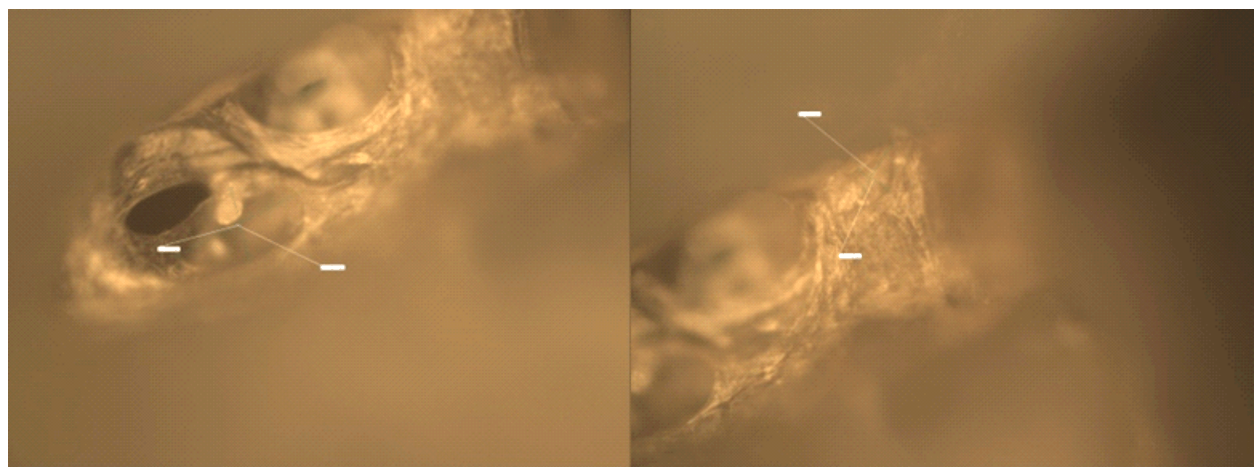


Figure 5 – Root apices in teeth under orthodontic treatment, with lacunae of various diameter (e.g., diameter of 140 μm , respectively 65 μm).

Discussion

Based upon study results, considering the methodological limitations, there is suggested that teeth with orthodontic treatment register changes that can be related to the characteristics of the medical intervention applied. In the tooth crown, the bracket bonding area registers sequelae of the clinical procedures of bonding and debonding the brackets. In the root, there can be seen root resorption lacunae, linked to tooth movement.

These may be considered as unavoidable side effects, but being acceptable due to their relative decreased severity, balanced by the benefits of the orthodontic treatment. Usually medical interventions, beside their positive effects, that represent the major rationale for implementing them, associate unavoidable side effects. Considering that, the most important part may be the magnitude or severity of the negative conditions associated, that must be put in balance with the positive effects related to implementing a specific medical intervention. Even so, the negative side effect must be well known in order to adequate conduct the treatment (*i.e.*, to minimize as much as possible their frequency and severity), and also acknowledging them may be the starting point for researches that aim finding a pathway to prevent or properly address them.

Changes identified in the middle third of tooth crown

of the teeth with previous orthodontic treatment consisted of disorderly grooves and cracks, with various directions, that were superficial and had various depths. These can be linked to the clinical procedures of bracket bonding and debonding, especially when acrylic materials are used, as in case of this study. The high frequency of cracks and fissures in the teeth with fixed orthodontic treatment is confirmed by several studies. Ryf *et al.*, by the usage of a three-dimensional laser scanner, identify that breakouts after debonding were detectable in 27% of teeth, with a mean depth of 44.9 μm [9]. Vertical fissures of the enamel are relatively frequent in general population, being not entirely linked to the orthodontic treatment. However, horizontal fissures and cracks observed in teeth with previous orthodontic treatment are mainly linked to the removal of the bracket and the remained bonding material. Higher incidence of enamel fissures was observed when clinical procedures that aimed debonding the fixed appliances are done improperly [10]. Therefore, the high irregularity of the enamel surface, with high-density grooves with various directions, is probably directly linked to the usage of orthodontic bracket, and indicates the need of performing a rigorous polishing in order to obtain a final situation as similar as possible to the natural one. The impact of their presence is unclear, but probably due to higher surface rugosity plaque, accumulation may be favored, as well as changes

of the optical perception of the teeth. Even so, grooves were also encountered on the lingual surfaces of the upper premolars, fewer as number. The latter are probably related to the occlusal contacts and mastication, this aspect being important to be further studied in order to link them as occlusal effects for the lingual technique. The surface where the bracket was bonded appeared flattest compared to the one of the teeth without orthodontic treatment. This may be explicable by the enamel loss due to bracket debonding, removal of bonding material and polishing procedures [9]. These clinical procedures associate limited volume loss, but their presence probably affects the properties and geometry of the enamel surface. Additionally, as proved by Tüfekçi *et al.*, enamel loss is dependent upon the presence of white spot lesions and clinical procedures used for bracket removal, as being higher for burs than for disks [11]. Regarding this study, in respect to the previous, the patients from this study presented moderate level of plaque control and removal of bonding materials was done with burs, both favoring greater enamel loss, that probably relates to the flatten of the surface that was observed. Microscopic evaluation gives different details about changes particularities upon the magnification used. As presented in a previous manuscript, lower magnifications, up to 5 \times , give information on general description of the defect, as clear demarcation area of the bracket bonding area, that register different color and an increased rugosity [8]. Higher magnifications, of 10 \times to 50 \times , give more detailed information on the surface characteristics, as presenting a high number of grooves with various directions and being more flatten. Usage of various magnifications is beneficial in order to understand the nature of the changes of tooth surface after orthodontic treatment, which is directly linked to the manner of addressing them.

The root of the teeth with previous orthodontic treatment showed signs of root resorption, as lacunae, with frequency and size superior to the ones of those found in teeth without orthodontic treatment. This confirms that root resorption, even if has an increased severity during orthodontic treatment, it is not a specific condition of it. Root resorption lacunae are also found in teeth with conditions as periapical or periodontal lesions [12]. In this study, root resorption lacunae were even observed in healthy erupting teeth, suggesting that at some decreased severity level these may be considered even normal, taking into account also the high reparatory properties of the tooth cementum. Even so, concerns were raised upon orthodontic root resorption considering higher frequency of the cases with severe alterations, as unexpected phenomena that considerably affect treatment outcome. Sreeja *et al.* found that microscopic signs of root resorption, as root resorption craters, appear shortly after the action of light orthodontic forces [13]. Even more, resorption severity it is influenced by the amount of tooth movement and the particularities of the orthodontic treatment applied. Weiland demonstrated, by a split mouth study, using for assessment a confocal laser scanning microscope, that usage of superelastic wires, compared to stainless steel wires, favors occurrence of root resorption lacunae with similar depth but higher perimeter, area and volume (at about 140% greater

[14]. In this study, there was a considerable difference between the sizes of root resorption lacunae in teeth with and without orthodontic treatment, which may be explicable by the long duration of previous orthodontic treatment in this case series above one year. Between radiological and microbiological assessment was not an obvious link, as regard to root resorption diagnosis. Even if by the microscopic evaluation root resorption was clearly diagnosed by detection of the root resorption lacunae, with high frequency and increased size, by radiological examination only in some of the cases an irregular contour of the root apex was identified as a suggestive sign of this condition. Considering that, and also the high repair capacity of the cementum it is possible that resorption lacunae to be part of a transitory process during the orthodontic treatment. Additionally, decreased microscopic magnifications may be more appropriate for assessing the localization of most severe alterations integrated to root resorption process [8].

Imaging techniques, as the microscopic ones, brought great knowledge to the medical field [15–18]. They are used for diagnostic purposes, but limitations are encountered sometimes for their *in vivo* use. Changes of the surface of the teeth crown can be evaluated *in vivo* by microscopy, even by using the devices developed especially for clinical use in dentistry. Root resorption analysis by microscopy is limited due to access impediments, therefore, microscopic analysis of rare cases as these presented in this study may bring valuable information.

The limitations of this study are mainly in relation to the decreased number of teeth analyzed, not allowing generalization. Even so, analyzing teeth under a long previous orthodontic treatment (above one year) is difficult to accomplish, in this study being possible as an exceptional condition, namely identifying two cases in which, due to treatment plan reassessment was decided to extract the first maxillary premolars, which were analyzed.

☞ Conclusions

Teeth with previous fixed orthodontic treatment exhibit changes that can be perceived as being directly linked to the medical intervention applied. The bracket bonding area presents numerous grooves with various directions and appears to be more flattened, therefore being necessary to select best clinical alternatives to remove the bracket and bonding material, followed by adequate polishing procedures. The tooth root surface exhibits root resorption lacunae with increased frequency, size and various depths. These teeth changes usually have low or moderate severity, which can be influenced at some degree by the clinical conduct of the orthodontic treatment. The stereomicroscope proved to be a high sensitivity tool for the analysis of morphological changes of teeth in relation to the fixed orthodontic treatment.

Conflict of interests

The authors declare that they have no conflict of interests.

Acknowledgments

We would like to express our gratitude to Professor Ecaterina Ionescu for her invaluable help.

References

- [1] Graber T, Eliades T, Athanasiou A. Risk management in orthodontics: experts' guide to malpractice. Quintessence Publishing Co., Chicago, 2004, 1–7.
- [2] Preoteasa CT, Ionescu E, Preoteasa E. Risks and complications associated with orthodontic treatment. In: Bourzgui F (ed). Orthodontics – basic aspects and clinical considerations. InTech, 2012, 403–428.
- [3] Karamouzos A, Athanasiou AE, Papadopoulos MA, Kolokithas G. Tooth-color assessment after orthodontic treatment: a prospective clinical trial. Am J Orthod Dentofacial Orthop, 2010, 138(5):537.e1–537.e8.
- [4] Hosein I, Sherriff M, Ireland AJ. Enamel loss during bonding, debonding, and cleanup with use of a self-etching primer. Am J Orthod Dentofacial Orthop, 2004, 126(6):717–724.
- [5] Shungin D, Olsson AI, Persson M. Orthodontic treatment-related white spot lesions: a 14-year prospective quantitative follow-up, including bonding material assessment. Am J Orthod Dentofacial Orthop, 2010, 138(2):136.e1–136.e8; discussion 136–137.
- [6] Preoteasa CT, Ionescu E, Preoteasa E, Comes CA, Buzea MC, Grănescu A. Orthodontically induced root resorption correlated with morphological characteristics. Rom J Morphol Embryol, 2009, 50(2):257–262.
- [7] Preoteasa CT, Ionescu E, Preoteasa E, Tenreiro Machado JA, Baleanu MC, Baleanu D. Multidimensional scaling for orthodontic root resorption. Math Probl Eng, 2013, 2013:383698. e1–383698.e6.
- [8] Preoteasa CT, Ionescu E, Didilescu AC, Meleşcanu-Imre M, Bencze MA, Preoteasa E. Undesirable dental hard tissue effects hypothetically linked to orthodontics – a microscopic study. Rom J Morphol Embryol, 2011, 52(3):937–941.
- [9] Ryf S, Flury S, Palaniappan S, Lussi A, van Meerbeek B, Zimmerli B. Enamel loss and adhesive remnants following bracket removal and various clean-up procedures *in vitro*. Eur J Orthod, 2012, 34(1):25–32.
- [10] Øgaard B, Fjeld M. The enamel surface and bonding in orthodontics. Semin Orthod, 2010, 16(1):37–48.
- [11] Tüfekçi E, Merrill TE, Pintado MR, Beyer JP, Brantley WA. Enamel loss associated with orthodontic adhesive removal on teeth with white spot lesions: an *in vitro* study. Am J Orthod Dentofacial Orthop, 2004, 125(6):733–739.
- [12] Felipe WT, Ruschel MF, Felipe GS, Pozzobon MH, Felipe MC. SEM evaluation of the apical external root surface of teeth with chronic periapical lesion. Aust Endod J, 2009, 35(3):153–157.
- [13] Sreeja R, Minal C, Madhuri T, Swati P, Vijay W. A scanning electron microscopic study of the patterns of external root resorption under different conditions. J Appl Oral Sci, 2009, 17(5):481–486.
- [14] Weiland F. Constant *versus* dissipating forces in orthodontics: the effect on initial tooth movement and root resorption. Eur J Orthod, 2003, 25(4):335–342.
- [15] Preoteasa E, Iosif L, Amza O, Preoteasa CT, Dumitrascu C. Thermography, an imagistic method in investigation of the oral mucosa status in complete denture wearers. J Optoelectron Adv Mater, 2010, 12(11):2333–2340.
- [16] Iosif L, Amza OE, Preoteasa E, Amza G, Preoteasa CT, Dumitrascu C. Contributions regarding the assessment of polymeric materials used in complete dentures by thermographic analysis – experimental study. Mater Plast, 2011, 48(1):104–109.
- [17] Preoteasa E, Imre M, Preoteasa CT. A 3-year follow-up study of overdentures retained by mini-dental implants. Int J Oral Maxillofac Implants, 2014, 29(5):1170–1176.
- [18] Oancea R, Podariu AC, Vasile L, Sava-Roşianu R, Folescu R. *In vitro* evaluation of laser fluorescence devices for caries detection through stereomicroscopic imaging. Rom J Morphol Embryol, 2013, 54(2):333–341.

Corresponding author

Cristina Teodora Preoteasa, Assistant Professor, DMD, PhD, Department of Oral Diagnosis, Ergonomics, Scientific Research Methodology, Faculty of Dental Medicine, “Carol Davila” University of Medicine and Pharmacy; Eforiei Dental Clinic, 4–6 Eforiei Street, 50037 Bucharest, Romania; Phone +40726–275 525, e-mail: cristina_5013@yahoo.com

Received: June 8, 2014

Accepted: February 2, 2015