

## LETTER TO THE EDITOR

## Parotid Warthin tumor with mucous differentiation

ADRIANA HANDRA-LUCA<sup>1,2)</sup>, MOUNA BENDIB<sup>1,3)</sup>

<sup>1)</sup>Service d'Anatomie pathologique, APHP GHU Avicenne, France

<sup>2)</sup>Université Paris Nord Sorbonne Cité, France

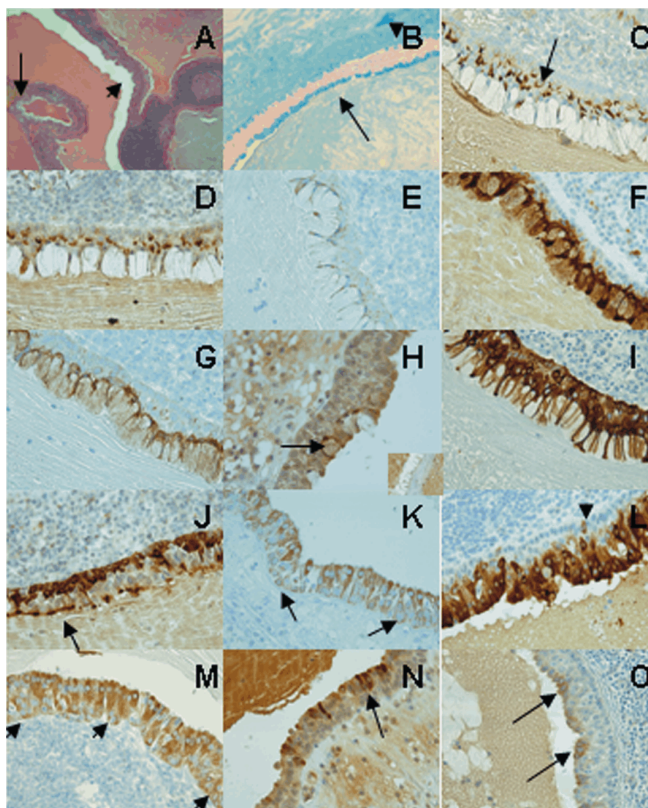
<sup>3)</sup>Université Paris Descartes Sorbonne Cité, France

Sir,

Mucus secreting cells in salivary gland Warthin tumor are rare, one case with goblet cells being reported in a series of 22 Warthin tumors, in recent years [1]. Other types of mucus secreting cells may occur but less frequently, as mentioned in the medical available literature, mainly in textbooks [2–7]. Here we report the case of a parotid Warthin tumor showing an aberrant digestive differentiation of mucous type and discuss the immunohistochemical profile of tumor cells.

A 76-year-old female patient presented with a right parotid tumor of 6 cm known for 15 years, showing also satellite adenopathy. The parotid mass was heterogeneous on computed tomography scan. Patient's history showed right facial paresthesia, anemia, reactive gastropathy and a history of colon polyps. A superficial exofacial parotidectomy with satellite nodule resection has been performed. The surgical specimen was entirely analyzed on microscopy on Hematoxylin and Eosin stained slides. The tumor consisted in two components, epithelial and lymphocytic, suggestive of a Warthin tumor. The epithelial component showed varied aspects: hyperplastic, pluristratified with oncocytic appearance (comprising basal cells, abluminal non-basal cells and luminal cells), classical bistratified, atrophic or with very rare foci of squamous metaplasia. There were multiple zones of mucous differentiation, encompassing approximately 10–15% of the tumor epithelium. Mucous cells were large, more frequently forming the luminal layer of tumor vegetations, disposed in large number (20–30 or more) (Figure 1).

**Figure 1 – The Warthin tumor comprised isolated, small (arrowhead) or large groups (arrow) of mucus secreting cells (A, Hematoxylin and Eosin stain, ob. ×5), showing blue, Alcian positive intracytoplasmic mucin (B, arrow indicating extensive mucous differentiation, arrowhead indicating isolated or small groups of mucin producing cells, ob. ×10). Mucin secreting cells did not express CD10 (C, arrows indicating positive abluminal non-basal cells, ob. ×40), MUC1 (D, ob. ×40), MUC2 (E, ob. ×40), and expressed MUC4 (F, ob. ×40), MUC5AC (G, ob. ×40) and faintly and sparsely MUC6 (H, arrow for positive mucous cell, inset with group of negative mucus secreting cells, ob. ×40) as well as CK7 (I, ob. ×40). MUC1 was expressed in basal cells as well as at the apical border of luminal cells (J, arrow indicating the luminal expression) and in basal cells. MUC2 was expressed in basal, abluminal non-basal and in luminal cells (K, arrows for basal cells, ob. ×40). MUC4 was expressed in very rare basal cells, and strongly in luminal and abluminal non-basal cells (L, arrows indicating positive basal cells, ob. ×40). MUC5AC was expressed in basal, luminal and abluminal cells (M, arrows indicating positive basal cells, ob. ×40), while MUC6 showed a strong cytoplasmic expression in rare luminal cells (arrows) (for this antibody a possibly nonspecific staining being seen in the fibrous stroma and in the cytoplasm of the other epithelial cells) (N, ob. ×40). CK20 was expressed in rare luminal cells, in the cytoplasm (O, arrows indicating positive luminal cells, ob. ×40).**



In other zones, single cells or small groups (2–10 cells) were disposed within the thickness of the tumor epithelium or at the luminal border. Nuclei were eccentric, basal, regular. Intracytoplasmic voluminous vacuoles were Alcian Blue and PAS positive. The lymphoid tissue component was admixed with adipocytes and showed hemorrhage and fibrosis. These same tumor components were observed in the two satellite nodules, along with residual parotid gland type lobules and a more abundant lymphoid tissue suggestive of a lymph node. On immunohistochemistry, the large mucous cells expressed cytokeratin CK7 (membrane, cytoplasmic), cytoplasmic mucins MUC4, MUC5AC, and rarely MUC6, without expressing CK5/6, CK20, CD10, or MUC1 (Figure 1). Basal epithelial cells expressed heterogeneously CD10 (cytoplasmic), CK7 (membrane, cytoplasmic), CK5/6 (membrane, cytoplasmic) as well as heterogeneously cytoplasmic mucins MUC1, MUC2, MUC5AC, MUC6, and sparsely MUC4. Abluminal non-basal cells, having most frequently an oncocytic appearance on Hematoxylin and Eosin stain, expressed diffusely CK7 (membrane, cytoplasmic), very focally CK20 (membrane, cytoplasmic), heterogeneously CK5/6 (membrane) and CD10 (cytoplasmic), and diffusely cytoplasmic mucins MUC1, MUC2, MUC4, MUC5AC, and MUC6 in a granular weak staining pattern. Luminal epithelial cells expressed diffusely CK7 (membrane, cytoplasmic), CK5/6 (membrane) and very focally CK20 (membrane, cytoplasmic), as well as luminal CD10 (in atrophic or pre-atrophic epithelium). They also expressed heterogeneously cytoplasmic mucins MUC1 (also showing luminal expression), MUC2, MUC4, MUC5AC, and MUC6 (sparse cells strongly positive). Ki67 and p63 nuclear expression was restrained to some basal, and abluminal cells.

Here we report the case of a parotid Warthin tumor with conspicuous mucous differentiation. Mucous cells were voluminous, frequently columnar, disposed in groups of 20–30 forming the luminal cell layer of the tumor vegetations. A second distribution pattern was noted, that of sparsely distributed mucous cells, isolated or in small groups, in the epithelial thickness. The MUC4, MUC5AC, and heterogeneously MUC6 positive immunophenotype of these mucus-secreting cells was suggestive of an aberrant gastro-enteric type of mucinous metaplasia [8, 9]. Histogenesis of Warthin tumors is still debated and both mucous metaplasia as occurring in normal salivary ducts [10, 11] and a neoplastic transformation of epithelial cells might be in question in occurrence of mucous differentiation. We have also found mucin expression in cells without cytoplasmic mucus on standard histological analysis, Alcian Blue or PAS positive. Abluminal and luminal cells expressed MUC1 and MUC2 as previously reported [9]. Here we show that basal cells also expressed MUC4, MUC5AC and MUC6, as well as the abluminal non-basal cells, raising the hypothesis that this mucin immunohistochemical profile might reflect an incomplete digestive aberrant differentiation, rare luminal cells also expressing CK20, although not associated with Alcian Blue or PAS positivity. However, cytoplasmic staining patterns should be checked carefully for specificity in the mitochondria-rich Warthin tumor cells.

The diagnostic relevance of mucous differentiation in Warthin tumors is limited in case of biopsy or surgically resected specimen as compared to cytology specimen, the differential diagnostic with associated mucoepidermoid carcinoma or adenocarcinoma remaining rather theoretical/academical [5, 12]. CK20 expression may occur, possibly also as part of a metaplastic process, and should be carefully considered since, to our knowledge CK20 has been reported, only in Merkel cell carcinoma associated with a Warthin tumor [13, 14]. Since Warthin tumors with mucous differentiation are very rare [1, 2, 6, 13], the evolution of such cells still remains difficult to predict.

### Acknowledgments

The authors thank the Garance Germain and Dr. Sylvain Benzakin involved in the management of the patient, Dr. Dominique Cazals-Hatem, Pr. Anne Couvelard, Pr. Benoît Terris for constructive discussions, as well as Annick Lecoant, Brigitte Mechekour, Sylvie Mosnier, Pascal Cusenier, Laurent Lefebure, Eddy Amelaise and the BIUM team for technical and administrative help.

### References

- [1] Faur A, Lazăr E, Cornianu M, Dema A, Vidita CG, Gălușcan A, *Warthin tumor: a curious entity – case reports and review of literature*, Rom J Morphol Embryol, 2009, 50(2):269–273.
- [2] Gorlin RJ, Chaudhry AP, *On the occurrence of mucous cells in papillary cystadenoma lymphomatosum*, Oral Surg Oral Med Oral Pathol, 1957, 10(10):1091–1093.
- [3] Batsakis JG, *Tumors of the head and neck: clinical and pathological considerations*, 2<sup>nd</sup> edition, Williams & Wilkins, Baltimore, 1979.
- [4] Barnes L, Eveson JW, Reichart P, Sidransky D (eds), *Pathology and genetics of head and neck tumours*, World Health Organization Classification of Tumors, International Agency for Research on Cancer, IARC Press, Lyon, 2005.
- [5] Gnepp DR, *Diagnostic surgical pathology of the head and neck*, 2<sup>nd</sup> edition, Saunders Elsevier, Philadelphia, 2009.
- [6] Rosai J, *Rosai and Ackerman's surgical pathology*, 10<sup>th</sup> edition, Elsevier Mosby, Philadelphia, 2011.
- [7] Ellis GL, Auclair PL, *Atlas of tumor pathology. Tumors of salivary glands*, 3<sup>rd</sup> series, Fascicle 17, Armed Forces Institute of Pathology, Washington, D.C., 1995.
- [8] Fenoglio-Preiser CM, Noffsinger AE, Stemmermann GN, Lantz PE, Isaacson PG, *Gastrointestinal pathology: an atlas and text*, 3<sup>rd</sup> edition, Lippincott Williams & Wilkins, Philadelphia, 2007.
- [9] Mannweiler S, Beham A, Langner C, *MUC1 and MUC2 expression in salivary gland tumors and in non-neoplastic salivary gland tissue*, APMIS, 2003, 111(10):978–984.
- [10] Ihrler S, Zietz C, Sendelhofert A, Lang S, Blasenbren-Vogt S, Löhns U, *A morphogenetic concept of salivary duct regeneration and metaplasia*, Virchows Arch, 2002, 440(5):519–526.
- [11] Mills SE (ed), *Histology for pathologists*, 3<sup>rd</sup> edition, Lippincott Williams & Wilkins, Philadelphia, 2007.
- [12] Alos L, Lujan B, Castillo M, Nadal A, Carreras M, Caballero M, de Bolos C, Cardesa A, *Expression of membrane-bound mucins (MUC1 and MUC4) and secreted mucins (MUC2, MUC5AC, MUC5B, MUC6 and MUC7) in mucoepidermoid carcinomas of salivary glands*, Am J Surg Pathol, 2005, 29(6):806–813.

- [13] Dăguci L, Stepan A, Mercuț V, Dăguci C, Bătăiosu M, Florescu A, *Immunohistochemical expression of CK7, CK5/6, CK19, and p63 in Warthin tumor*, Rom J Morphol Embryol, 2012, 53(3):603–607.
- [14] Fornelli A, Eusebi V, Pasquinelli G, Quattrone P, Rosai J, *Merkel cell carcinoma of the parotid gland associated with Warthin tumour: report of two cases*, Histopathology, 2001, 39(4):342–346.

**Corresponding author**

Adriana Handra-Luca, MD, PhD, Service d'Anatomie pathologique, APHP GHU Avicenne, Université Paris Nord Sorbonne Cité, 125 rue de Stalingrad, 93009 Bobigny Cedex, Paris, France; Phone 0033 1 48955555 ext. 2047, Fax 0033 1 48955602, e-mail: [adriana.handra-luca@avc.aphp.fr](mailto:adriana.handra-luca@avc.aphp.fr)

*Received: February 12<sup>th</sup>, 2013*

*Accepted: March 5<sup>th</sup>, 2013*