

## Histological and immunohistochemical study of cutaneous angiogenesis process in experimental third-degree skin burns treated with allograft

CRISTINA JANA BUSUIOC<sup>1)</sup>, FLORINA CARMEN POPESCU<sup>2)</sup>,  
G. D. MOGOȘANU<sup>3)</sup>, H. PÂRVĂNESCU<sup>4)</sup>, LILIANA STREBA<sup>1)</sup>,  
L. MOGOANTĂ<sup>2)</sup>

<sup>1)</sup>Department of Histology

<sup>2)</sup>Research Center for Microscopic Morphology and Immunology

<sup>3)</sup>Department of Pharmacognosy & Phytotherapy,  
Faculty of Pharmacy

<sup>4)</sup>Department of Plastic Surgery and Reconstructive Microsurgery  
University of Medicine and Pharmacy of Craiova  
"Carol Davila" University of Medicine and Pharmacy, Bucharest

### Abstract

Skin burns are a rather high incidence lesions which, depending on their depth and extension, can severely affect not only the skin but the entire organism. Third-degree skin burns extended on over 20% of the body surface often require skin graft. Skin allograft is a therapeutic alternative when autograft cannot be used. We investigated the allograft influence on the angiogenesis process in third-degree skin burns, using an experimental model. We noticed that the allograft induces a stronger inflammatory reaction associated with intense angiogenesis process by about 10–15% compared to control group.

**Keywords:** angiogenesis, skin burns, endothelial cells, pericyte, allograft.

### ✉ Introduction

Burns are a major public health problem worldwide [1] with their quite high incidence and chronic lesions they produce. Thus, it is estimated that worldwide, each year more than 6.6 million people suffer from various burns [2]; in the U.S. alone, it is estimated that each year more than 1.2 million Americans get to medical units with burn injuries [3], out of which over 450 000 require hospitalization and treatment.

Third-degree skin burns, besides total destruction of the epidermis and dermis, depending on location, can also cause lesions of muscles tendons and underlying bones, inducing more severe stress than other trauma [4]. When there is interested a more than 20% surface, they produce a rapid and dangerous loss of fluids, electrolytes and proteins, altering the body's vital functions. Often these burns difficultly heal, with hypertrophic, thick, unaesthetic scars, resulting in contractures, which distort the surrounding tissues [5] and sometimes create various physical handicaps, requiring surgery for correcting these defects [6]. Also, third-degree skin burns, spread over large areas may induce different mental disorders that require specialized treatment [7].

Third-degree skin burns healing process is very complex, involving different tissues and cell lines which

cooperate together by intracellular and extracellular signals [8].

In the healing of skin burns, angiogenesis plays a key role as newly formed blood vessels supply oxygen, nutrients, vitamins, enzymes, growth factors needed for the healing process [9].

When lesions are much extended, third-degree skin burns often require skin graft to achieve wound closure and restore the structural and functional integrity of the skin. Autografts are the most effective. Sometimes, because of the extent of burned wounds, there is no possibility of using an autograft. In these situations there are used a variety of synthetic and biological dressings, including allografts, to combat plasmatic and hydroelectrolyte losses, prevent microbial infection, accelerate healing and reduce scarring [10].

In this study, we evaluated the process of angiogenesis in experimental third-degree skin burns on animal model by applying skin allograft compared with angiogenesis in the third-degree skin burns during spontaneous healing of the wound.

### ✉ Materials and Methods

The study was conducted on two batches of 35 Wistar common adult rats each, weighing between 280 and 310 g. Animals were held both before and during

the experiment, at the Animal Facility of the University of Medicine and Pharmacy of Craiova, Romania, in standard light, temperature and humidity conditions, also having always access to food and water (*ad libitum*).

For the experiment, we obtained the agreement of the Ethics Committee of the University of Medicine and Pharmacy of Craiova, in accordance with the European Council Directive 86/609 from 24.11.1986 (86/609/EEC), the European Convention for the Protection of Vertebrate Animals (2005) and the Romanian Government Decree No. 37/2002.

For the experiment, animals received general anesthesia by intramuscular injection of Ketamine hydrochloride (Ketalar®, Parke-Davis), 85 mg/kg of body weight, and Xylazine hydrochloride (Rompun®, Bayer), 6 mg/kg of body weight each. After removing hair on the back of the dorsal region, on an area of about 4–5 cm<sup>2</sup>, each animal was applied a stainless steel specially made metal device, cone-shaped, with a diameter of 1 cm, equipped with a control thermometer, heated to 100°C in a pot of boiling water for 5 seconds. After conducting the burn, each animal was applied a dry dressing to the wound. Evolution of the burned wound and animal welfare were daily monitored.

A first group of 35 animals was left to spontaneously heal (control group). The animals were randomly divided into seven subgroups of five animals each. Every three days and at 3, 6, 9, 12, 15, 18, and 21 days, under general anesthesia, from each subset of five animals lesional area was harvested, with about 2–3 mm perilesional, to dynamically follow the angiogenesis process in the burned wound during spontaneous healing. Then, each animal's remaining wound was surgically sutured.

On the second group, after 24 hours since the burn was produced, each animal was removed the burned skin area and applied a skin allograft under general anesthesia. Skin allografts were harvested from a group of the same breed rats under general anesthesia with Ketamine hydrochloride and Xylazine hydrochloride using an Acculan type dermatome (Aesculap®), fitted with an adjustable depth system between 0.1–1 mm. Skin fragments were kept in heated to 37°C saline for a few minutes and small holes were conducted for drainage of possible fluid accumulation and then were applied to the receiving animal. Allograft was sutured with non-absorbable thread, at the edges of the wound, and then applied a moistened compress bandage, fixed

with adhesive tape. Animals were daily monitored and kept under standard conditions of light, heat and food. To achieve the study, animals of this group were also divided into seven subgroups of five animals each, which were taken under general anesthesia, allografted areas at 3, 6, 9, 12, 15, 18, and 21 days respectively after achieving the allograft.

### Histological study

Burnt-skin fragments harvested not only from spontaneously-healed animals but also from allograft treated ones, were fixed in neutral formalin solution for 72 hours, at room temperature (21–23°C), and included in histological paraffin.

Biological material was sectioned with Microm HM350 rotary microtome equipped with a section transfer system on a water bath (STS, Microm).

For the histological study, there were used classical stains with Hematoxylin–Eosin and Goldner–Szekely trichomic.

### Immunohistochemical study

For the immunohistochemical study, there were performed 3-µm thick sections which were collected on poly-L-Lysine coated slides to increase adherence of biological material to object-slide, after which they were kept in the thermostat at 37°C for 24 hours. Then, after dewaxing and hydration of the histological sections, the biological material was incubated for 30 minutes in a solution of 1% hydrogen peroxide. Sections were then washed in tap water after which they were boiled in pH 6 citrate buffer solution for 20 minutes for antigen unmasking.

After boiling, were left to cool for 15 minutes, followed by washing them in bisaline phosphate buffer solution (PBS), followed by endogenous peroxidase blocking step in 2% skimmed milk for 30 minutes. Then, sections were incubated overnight with primary antibodies at 4°C, and the next day, the signal was amplified 30 minutes using peroxidase secondary antibody on polymer support (EnVision, Dako).

The signal was detected with 3,3'-diaminobenzidine (DAB) (Dako) and after contrasting with Hematoxylin slides were covered with DPX (Fluka).

The markers used for the immunohistochemical study are presented in Table 1.

**Table 1 – Panel of antibodies for immunostaining**

| Antibody  | Host/Target      | Epitope  | Clone  | Dilution | Antigen retrieval      | Producer                               |
|-----------|------------------|--|--------|----------|------------------------|--|
| Anti-CD34 | Rabbit/Rat       | Vascular endothelium                           | EP373Y | 1:100    | Citrate buffer boiling | Epitomics, Medcalkit, Craiova, Romania |
| Anti-CD68 | Mouse/Rat        | Macrophages                                    | ED1    | 1:200    | Citrate buffer boiling | AbD Serotec, Medcalkit                 |
| Anti-SMA  | Mouse/Human, Rat | Smooth muscle cells, pericytes, myofibroblasts | 1A4    | 1:100    | Citrate buffer boiling | Dako, Bucharest, Romania               |

To assess angiogenesis vessel density, were chosen areas of maximum vascular density (hotspot method) and four microscopic images were captured. Vessel count was performed manually using the “Manual tagging” function in ImageProPlus program and acquired

data were exported to Excel for automatic calculation of vascular density per unit area (mm<sup>2</sup>).

Microscopic evaluation was performed by grabbing 20× images under the Nikon Eclipse 55i microscope equipped with a 5 Mp CCD color sensor (Apidrag,

Romania). Images were captured, stored and analyzed utilizing the Image ProPlus 7 AMS package (Media Cybernetics, Inc., Buckinghamshire, UK).

For statistical analysis, we first normalized all counts for a 1-mm<sup>2</sup> area, and then we plotted the means and standard deviations for each day stage. To compare all-time points, we used ANOVA testing, and to appreciate the correlation degree between the variables a Pearson correlation coefficient was utilized.

### Fluorescent immunohistochemistry

Double immunohistochemistry was performed for anti-CD34 (1:300, rabbit, Epitomics) in combination with anti-SMA antibody (1:50, mouse, Dako). The immunodetection was a sequential protocol that begun with the overnight incubation in the anti-CD34 antibody, amplification with a goat anti-rabbit HRP secondary (1:100, Dako) for 30 minutes, followed by a 30 seconds precipitation step of fluoresceinated tyramide (Perkin Elmer, Mediatech, Romania). Next, the anti-SMA antibody was added in another overnight incubation, this being detected with a goat-anti mouse Alexa 596 antibody (30 minutes, 1:300, Invitrogen, Mediatech, Romania). After DAPI counterstaining, the sections were coverslipped in anti-fading fluorescent mounting medium (Dako).

Fluorescently-labeled sections were imaged with an Eclipse 90i microscope (Nikon, Apidrag, Romania) equipped with a QImaging Rolera cooled CCD camera and with narrowband fluorescent filters centered for Alexa 594, Alexa 488 and DAPI excitation and emission wavelengths. Images were captured and analyzed using the Image ProPlus 7 AMS software (Media Cybernetics, Inc., Buckinghamshire, UK). For fluorescence, images were obtained by sequential scanning of each channel with the specific pair of filters to eliminate the cross-talk of the fluorophores, and to ensure a reliable quantification. Next, the fluorescent images were subjected to a blind deconvolution algorithm based on a

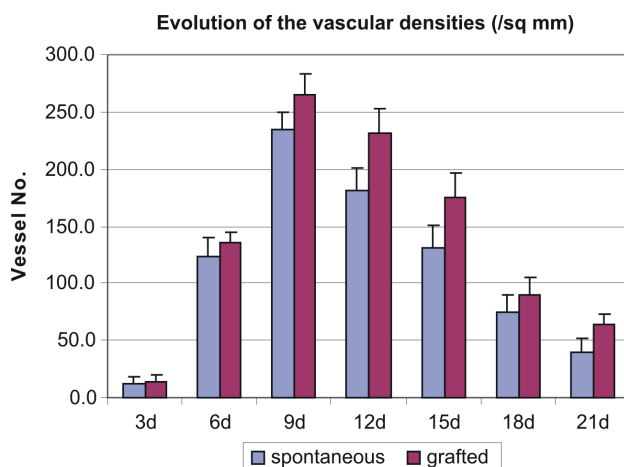
multi-pass, adaptive point spread function (PSF) subtraction of diffracted light (Sharp Stack, Media Cybernetics, Inc.).

### Results

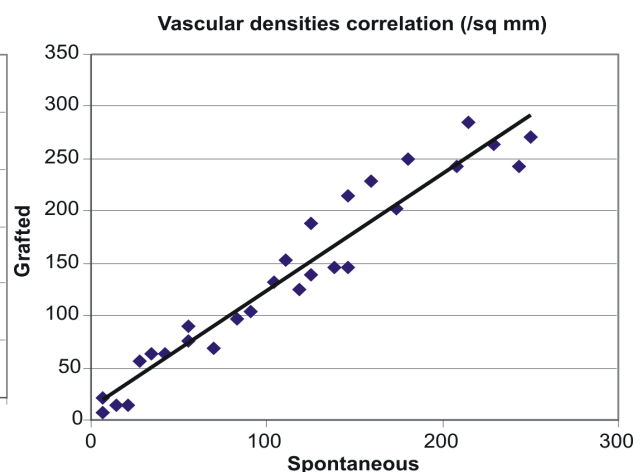
New injuries that we provoked in experimental animals were third-degree skin burns by their depth, causing coagulation necrosis in the epidermis, dermis and partly superficial muscles. The skin vascular bed beneath the wound was altered.

Three days after the lesion, both the control animals group and the allograft treated animals, most of the burn wound was occupied with cellular and tissue debris. On the outskirts of the wound bed, we noted the presence of vascular congestion with blood vessels with altered walls and with microbleeds or rare vascular thrombosis and capillary angiogenesis. Also, here we noticed the presence of a moderate inflammatory infiltrate consisting of polymorphonuclear neutrophils, macrophages and lymphocytes scattered unevenly and the start of the recovery process through the appearance of dermal connective tissue fibroblasts. To date we did not report significant changes between microscopic aspects of restorative process between the two groups of animals.

Both angiogenesis vessels number in the group treated with allograft and a control group suddenly increased from day one to day three, reaching a maximum between 9 and 12 days after the lesion. Thus, three days after the lesion angiogenesis vessel number was about 14/mm<sup>2</sup> in the group treated with allograft and 12/mm<sup>2</sup> in the spontaneous healing group. At six days, angiogenesis vessel number increased in the group treated with allograft to 135/mm<sup>2</sup>, and up to 123/mm<sup>2</sup> respectively in the group with spontaneous healing. At nine days, the number has reached 265/mm<sup>2</sup> in burns treated with allograft and up to 134/mm<sup>2</sup> in the group of spontaneous healing burns (Figures 1 and 2).



**Figure 1 – Vascular densities gradually increased with a peak of 9–12 days and then gradually decreased towards the 21<sup>st</sup> day, for both spontaneous and grafted experiment tissue samples. There was a significant difference between the means of all the groups for both spontaneous [ $F(1,54)=59.87$ ,  $p<0.001$ ] and grafted experiments [ $F(1,54)=67.76$ ,  $p<0.001$ ].**



**Figure 2 – In fact, it was a very tight direct correlation between the vascular densities for spontaneous and for grafted areas ( $r=0.967$ ).**

After this date, the number of angiogenesis vessels decreased progressively with increased maturation process of granulation tissue and reducing of the inflammatory response.

However, even after 21 days, when most of the wound was occupied by mature granulation tissue and the epidermis was restored, we noted the persistence of a relatively large number of angiogenesis vessels with CD34 positive cells and/or alpha-SMA positive, 64 vessels/mm<sup>2</sup> in the group treated with allograft and 40 vessels/mm<sup>2</sup> within the group with spontaneous healing.

These microscopic aspects show that the dermal connective tissue remodeling continues long after the wound is healed macroscopically.

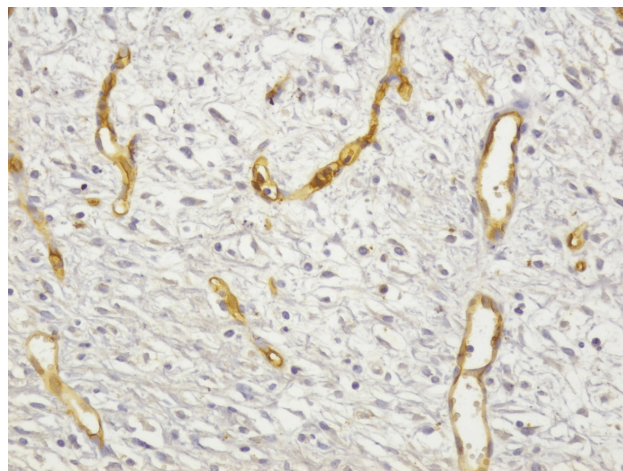
In our study, it was noted that in animals with applied allograft (which served as a natural bandage), inflammation and polymorphonuclear neutrophil response and especially macrophages was more intense than in the control group, something which materialized and appearance of a greater number of vessels angiogenesis by 10–15% compared to the control group, in which healing occurred naturally.

Because in the formation of angiogenesis vessels two types of cells are involved, respectively angioblasts and pericytes, we wanted to highlight the role of these cells in the emergence and development of the vascular wound healing of burned treated *vs.* allograft healing spontaneous.

To capture the interrelations between the two cell types we used chemical immunostaining and immunofluorescence of these cells with CD34 antibody for endothelial progenitor cells, or alpha-SMA pericytes.

As shown in our images (Figure 3), endothelial progenitor cells, CD34 positive, appeared among the first in granulation tissue structure.

Sometimes they appeared as solid cell cords, which then forms the lumen, the ramifications of preexisting vessels or vessels unrelated to the burn wound.



**Figure 3** – Immunohistochemical image of angiogenesis vessels with positive immunostaining for CD34, six days after applying the allograft: cords of angioblasts in contact or at a distance of preexistent vessels that progressively form a lumen. LSAB technique,  $\times 200$ .

Pericytes, highlighted with alpha-SMA antibody had a significantly lower expression at six days (Figure 4) compared with CD34 positive cells.

To highlight more precisely the relationship between the two cell types involved in angiogenesis, we performed a double immunostaining by immunofluorescent assay of angioblasts (green) and pericytes (red).

We noted that the first and most numerous cells forming granulation tissue vascular tubes are CD34 positive cells (Figure 5).

Pericytes, alpha-SMA positive cells, appeared on the periphery of vessels later than angioblasts, when neoformation vessels became functional and reached a vascular lumen.

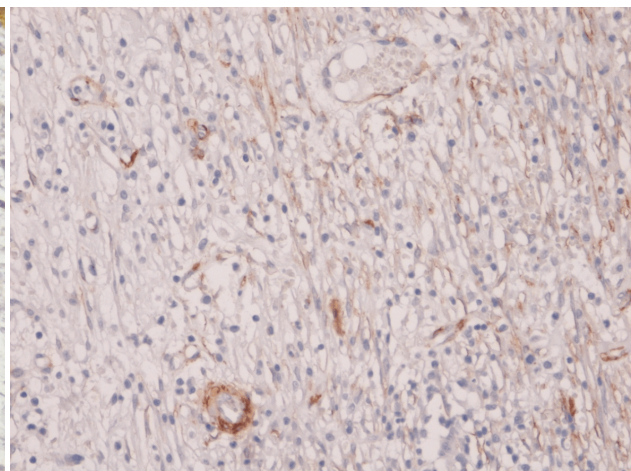
As the number of angiogenesis vessels increased and as their lumen inside the granulation tissue increased, pericytes appeared on the periphery of neoformation vessels (Figure 6).

The same was reported in histological and immunohistochemical stains (Figures 7 and 8).

With the start of the maturation granulation tissue characterized by reduced inflammatory response and increased extracellular matrix, especially collagen fibers, the number of angiogenesis vessels gradually decreased both in animals treated with allograft and animals in the control group.

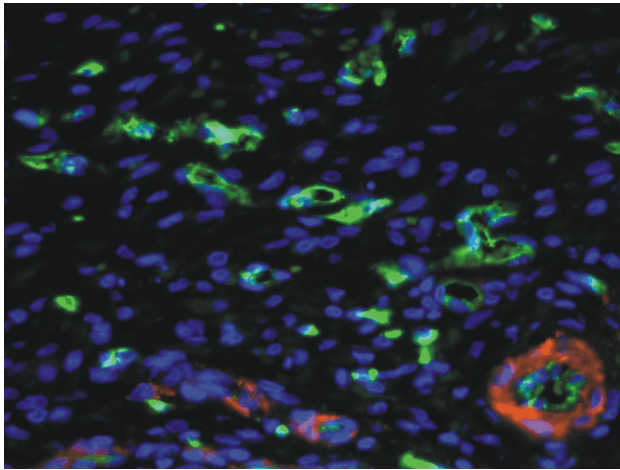
This reduction evolved from deep wound to the surface. Some of the newly formed vessels acquired a wider lumen and pericytes were ordered in several layers transformed into smooth muscle cells, giving rise to arterioles and venules. Thus, on the same histological specimen we found both young angiogenesis vessels and mature blood vessels (Figure 9).

Compared with controls, in animals treated with allograft reaction was observed more intense and longer duration of pericytes. This may be due to the appearance of large quantities of induced stimuli by stronger inflammatory response in animals treated with allograft.

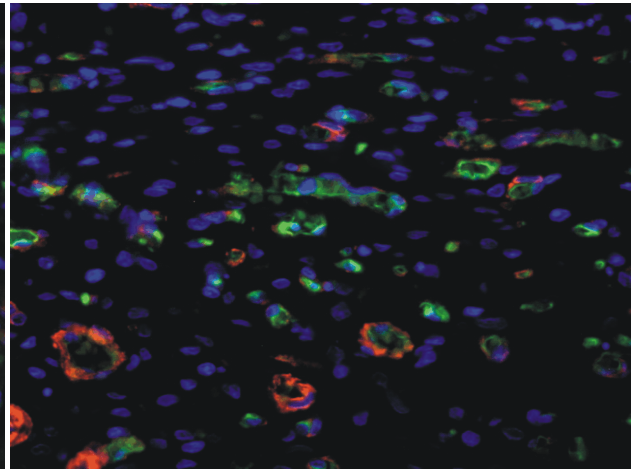


**Figure 4** – Granulation tissue microscopical image, six days after applying the allograft, with reduced number of positive alpha-SMA pericytes. LSAB technique,  $\times 200$ .

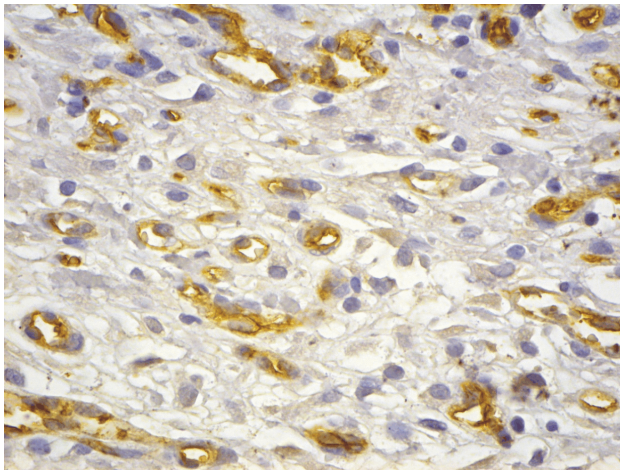




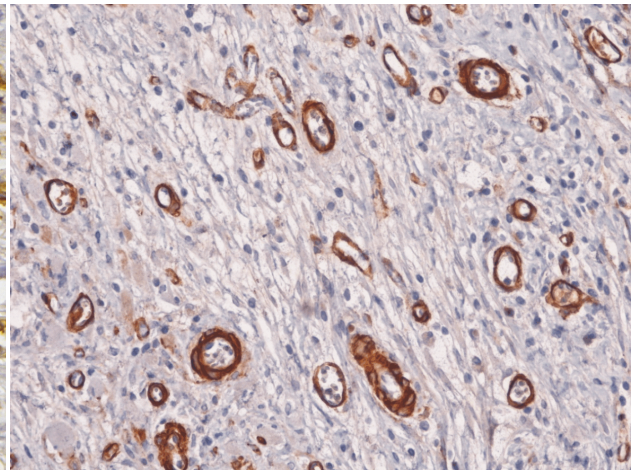
**Figure 5** – Granulation tissue immunofluorescence image, six days after applying the allograft, with numerous CD34 positive angioblasts (green) that form vascular tubules and rare alpha-SMA positive pericytes. Double immunostaining with CD34 and alpha-SMA,  $\times 400$ .



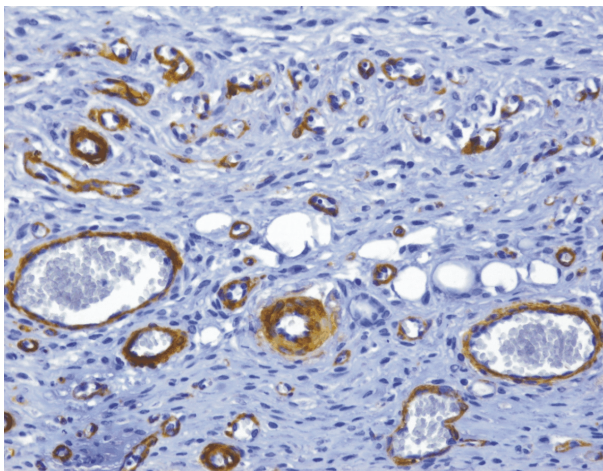
**Figure 6** – Granulation tissue after nine days: rising number of angiogenesis vessels but alpha-SMA positive pericytes also. Double immunostaining with anti-CD34 (green) and anti-alpha-SMA (red) antibodies,  $\times 400$ .



**Figure 7** – Numerous angiogenesis vessels with CD34 positive cells in granulation tissue, nine days after applying the allograft. LSAB technique,  $\times 400$ .



**Figure 8** – Angiogenesis vessels with positive alpha-SMA pericytes well expressed in granulation tissue, nine days after applying the allograft. LSAB technique,  $\times 200$ .



**Figure 9** – Under maturation deep wound granulation tissue, 15 days after applying the allograft, with small vessels of angiogenesis persistence, but also mature type vessels appearance (arterioles and venules) with positive immunostaining for alpha-SMA in pericytes. LSAB technique,  $\times 200$ .

## Discussion

The skin is a vital organ of the body to maintain homeostasis, the first line of defense against the aggression of external factors. It is a mechanical barrier attenuating or canceling energy of blunt objects, prevents pathogens (bacteria, viruses, fungi) or toxic substances in the air or dissolved in water, toxins or UV radiation. Also, skin limits the loss of water and salts from the body, synthesizes vitamin D, participates in maintaining constant body temperature by reducing heat loss when the body is exposed to cold or accelerates heat loss (thermolysis) to avoid overheating the body. It represents a vast surface receptors for pain, pressure, stretching, temperature, being considered the largest sensory organ. Therefore, the skin is equipped with a high capacity to autoregenerate by various physical, thermal or chemical aggressions.

Third-degree burns of the skin, on large areas, are a major cause of morbidity and mortality because skin functions are profoundly altered and its restorative

capacity is reduced [11]. In addition, extensive burns are associated with higher systemic changes, up to heart failure, renal or hepatic impairment. Therefore, in clinical practice, in deep and extensive burns of over 20% of the skin, skin graft is necessary for more rapid recovery and resumption of skin organ function [12].

Restoring third-degree skin burns triggers a cascade of cellular, tissue and molecular events aimed at restoring homeostasis. These processes consist of migration of blood cells in the wound and the development of a local inflammatory reaction, which aims to remove cellular debris and pathogens, connective tissue cell proliferation and extracellular matrix deposits, development of a blood vascular network new and newly formed tissue remodeling (granulation tissue) [13, 14]. In these processes, angiogenesis and recovery process of a new network of blood vessels from existing ones [15] has a primary role because through these vessels oxygen and nutrients are supplied to granulation tissue [9], and eliminate waste products. Insufficient angiogenesis process may result in coagulation necrosis area enlargement enabling the development of microbial flora and wound healing is more prolonged and often determines the appearance of scarring [4].

In our study, we evaluated angiogenesis in the third-degree skin burns after treatment with allograft *vs.* spontaneous angiogenesis in the healing process, highlighting the CD34 positive cells. CD34 is a highly glycosylated transmembrane glycoprotein expressed by hematopoietic stem cells, progenitor cells [16] and endothelial cells of small blood vessels and lymphatic [17].

Application of skin allograft with a biological dressing role, led to a broader inflammation and angiogenesis vessels increase by about 10–15% compared to control group. Angioblasts, vascular endothelial precursor CD34 positive cells of bone marrow origin, often formed solid cell cords, which later transformed into lumen endothelial tubes. Most often, these cords arrangement was from deep wound to its surface or from lesion edges to the center. This arrangement means that angiogenesis vessels are related to healthy vessels from the periphery of the burned region [18, 19].

Concept that bone marrow-derived cells contribute to postnatal neoangiogenesis by endothelial differentiation was first issued by Asahara T *et al.*, in 1997. It is now widely accepted that circulating endothelial precursor cells have a significant contribution to wound tissue healing [20–22]. These cells can be collected from the bone marrow and peripheral blood can be grown and can be used by direct inoculation within the wound to form angiogenesis vessels. Relatively recent data show that guiding these cells in tissues is performed by cells that synthesize proangiogenic factors [23].

Cells that release proangiogenic factors include macrophages, cells that, as we have seen, are plenty within young granulation tissue. More recent studies [24], however, showed that macrophages occurring during various phases of skin repair, perform distinct functions, including that of stimulating angiogenesis. Currently, there have been identified at least two types of macrophages: type M1 that secrete proinflammatory

mediators, and M2 that stimulate angiogenesis and wound healing [25–27].

In our study, it was noted that in the group of animals who underwent allograft, pericytes had a stronger reaction than the control group. Pericytes are the second most important cellular element, which appeared in neoformation vessels. In normal tissues, pericytes are arranged discontinuously in the basal membrane of capillaries and post-capillary venules. Contractile proteins in the cytoplasm emit many extensions around endothelial cells within the vascular wall with the role of stabilizing and regulating microvascular blood flow. Recent data [28] show that between pericytes and endothelial cells appears to be a very well controlled balance.

In our study, pericytes occurred at the periphery of angiogenesis capillaries after the formation of endothelial tubules. By other authors [29], pericytes are among the first cells that invade the newly formed tissues, being located in the area in front of endothelial growth buds, causing vascular bud formation and guidance of newly formed vessels. We believe that pericytes are mesenchymal cells that differentiate after receiving stimuli coming from the angioblasts, with the main role to stabilize the newly formed capillary structure.

## ✎ Conclusions

Restoring blood vascular network from third-degree skin burns treated skin allograft had a similar dynamic process of angiogenesis as those occurring during spontaneous healing, but it was more intense by about 10–15% compared to control group. Therefore, allograft allows and even encourages the restoration of vasculature within the burned wound. Dynamic vessel angiogenesis know a faster growth in the first 9–12 days, after which the number of vessels regresses as the dermal granulation tissue matures. Persistence of angiogenesis vessels in the dermis after fully recovered epidermis shows that maturation processes and modeling of dermal connective tissue continues after this stage.

## Acknowledgments

This paper is partially supported by the Sectoral Operational Programme Human Resources Development, financed from the European Social Fund and by the Romanian Government under the contract number POSDRU/89/1.5/S/64153.

## References

- [1] Zhang X, Wei X, Liu L, Marti GP, Ghanamah MS, Arshad MJ, Strom L, Spence R, Jeng J, Milner S, Harmon JW, Semenza GL, *Association of increasing burn severity in mice with delayed mobilization of circulating angiogenic cells*, Arch Surg, 2010, 145(3):259–266.
- [2] Penn JW, Grobbelaar AO, Rolfe KJ, *The role of the TGF- $\beta$  family in wound healing, burns and scarring: a review*, Int J Burns Trauma, 2012, 2(1):18–28.
- [3] Brigham PA, McLoughlin E, *Burn incidence and medical care use in the United States: estimates, trends, and data sources*, J Burn Care Rehabil, 1996, 17(2):95–107.
- [4] Sun G, Zhang X, Shen YI, Sebastian R, Dickinson LE, Fox-Talbot K, Reinblatt M, Steenbergen C, Harmon JW, Gerech S, *Dextran hydrogel scaffolds enhance angiogenic responses and promote complete skin regeneration during burn wound healing*, Proc Natl Acad Sci U S A, 2011, 108(52):20976–20981.

- [5] Zhang X, Liu L, Wei X, Tan YS, Tong L, Chang R, Ghanamah MS, Reinblatt M, Marti GP, Harmon JW, Semenza GL, *Impaired angiogenesis and mobilization of circulating angiogenic cells in HIF-1alpha heterozygous-null mice after burn wounding*, Wound Repair Regen, 2012, 18(2):193–201.
- [6] Woo SH, Seul JH, *Optimizing the correction of severe postburn hand deformities by using aggressive contracture releases and fasciocutaneous free-tissue transfers*, Plast Reconstr Surg, 2001, 107(1):1–8.
- [7] Taal LA, Faber AW, *Posttraumatic stress and maladjustment among adult burn survivors 1–2 years postburn*, Burns, 1998, 24(4):285–292.
- [8] Gurtner GC, Werner S, Barrandon Y, Longaker MT, *Wound repair and regeneration*, Nature, 2008, 453(7193):314–321.
- [9] Li J, Zhang YP, Kirsner RS, *Angiogenesis in wound repair: angiogenic growth factors and the extracellular matrix*, Microsc Res Tech, 2003, 60(1):107–114.
- [10] Wang YB, Kusumoto K, Kakudo N, Ogawa Y, *The use of skin allograft with donor-specific tolerance in a rabbit model of full-thickness burn*, Burns, 2006, 32(6):737–743.
- [11] Branski LK, Gauglitz GG, Herndon DN, Jeschke MG, *A review of gene and stem cell therapy in cutaneous wound healing*, Burns, 2009, 35(2):171–180.
- [12] Burd A, Chiu T, *Allogenic skin in the treatment of burns*, Clin Dermatol, 2005, 23(4):376–387.
- [13] Singer AJ, Clark RA, *Cutaneous wound healing*, N Engl J Med, 1999, 341(10):738–746.
- [14] Wu Y, Chen L, Scott PG, Tredget EE, *Mesenchymal stem cells enhance wound healing through differentiation and angiogenesis*, Stem Cells, 2007, 25(10):2648–2659.
- [15] Vong S, Kalluri R, *The role of stromal myofibroblast and extracellular matrix in tumor angiogenesis*, Genes Cancer, 2011, 2(12):1139–1145.
- [16] Nielsen JS, McNagny KM, *CD34 is a key regulator of hematopoietic stem cell trafficking to bone marrow and mast cell progenitor trafficking in the periphery*, Microcirculation, 2009, 16(6):487–496.
- [17] Young PE, Baumhueter S, Lasky LA, *The sialomucin CD34 is expressed on hematopoietic cells and blood vessels during murine development*, Blood, 1995, 85(1):96–105.
- [18] Busuioc CJ, Popescu FC, Mogoșanu GD, Lascăr I, Pirici I, Pop OT, Mogoantă L, *Angiogenesis assessment in experimental third degree skin burns: a histological and immunohistochemical study*, Rom J Morphol Embryol, 2011, 52(3):887–895.
- [19] Mogoșanu GD, Popescu FC, Busuioc CJ, Pârvănescu H, Lascăr I, *Natural products locally modulators of the cellular response: therapeutic perspectives in skin burns*, Rom J Morphol Embryol, 2012, 53(2):249–262.
- [20] Asahara T, Murohara T, Sullivan A, Silver M, van der Zee R, Li T, Witzenbichler B, Schatteman G, Isner JM, *Isolation of putative progenitor endothelial cells for angiogenesis*, Science, 1997, 275(5302):964–967.
- [21] Asahara T, Masuda H, Takahashi T, Kalka C, Pastore C, Silver M, Kearne M, Magner M, Isner JM, *Bone marrow origin of endothelial progenitor cells responsible for postnatal vasculogenesis in physiological and pathological neovascularization*, Circ Res, 1999, 85(3):221–228.
- [22] Wu Y, Zhao RC, Tredget EE, *Concise review: bone marrow-derived stem/progenitor cells in cutaneous repair and regeneration*, Stem Cells, 2010, 28(5):905–915.
- [23] Gerhardt H, Golding M, Fruttiger M, Ruhrberg C, Lundkvist A, Abramsson A, Jeltsch M, Mitchell C, Alitalo K, Shima D, Betsholtz C, *VEGF guides angiogenic sprouting utilizing endothelial tip cell filopodia*, J Cell Biol, 2003, 161(6):1163–1177.
- [24] Lucas T, Waisman A, Ranjan R, Roes J, Krieg T, Müller W, Roers A, Eming SA, *Differential roles of macrophages in diverse phases of skin repair*, J Immunol, 2010, 184(7):3964–3977.
- [25] Auffray C, Sieweke MH, Geissmann F, *Blood monocytes: development, heterogeneity, and relationship with dendritic cells*, Ann Rev Immunol, 2009, 27:669–692.
- [26] Geissmann F, Manz MG, Jung S, Sieweke MH, Merad M, Ley K, *Development of monocytes, macrophages, and dendritic cells*, Science, 2010, 327(5966):656–661.
- [27] Yona S, Yung S, *Monocytes: subsets, origins, fates and functions*, Curr Opin Hematol, 2010, 17(1):53–59.
- [28] Ribatti D, Nico B, Crivellato E, *The role of pericytes in angiogenesis*, Int J Dev Biol, 2011, 55(3):261–268.
- [29] Nehls V, Denzer K, Drenckhahn D, *Pericyte involvement in capillary sprouting during angiogenesis in situ*, Cell Tissue Res, 1992, 270(3):469–474.

### Corresponding author

Laurențiu Mogoantă, Professor, MD, PhD, Research Center for Microscopic Morphology and Immunology, University of Medicine and Pharmacy of Craiova, 2–4 Petru Rareș Street, 200349 Craiova, Romania; Phone +40251–523 654, e-mail: laurentiu\_mogoanta@yahoo.com

Received: September 5<sup>th</sup>, 2012

Accepted: December 20<sup>th</sup>, 2012