

## CASE REPORT

# Refractory anemia with ring sideroblasts associated with marked thrombocytosis: case report and literature review

MIHAELA GĂMAN, ANA-MARIA VLĂDĂREANU, MINODORA ONISAI

Department of Hematology,  
 Emergency University Hospital, Bucharest  
 "Carol Davila" University of Medicine and Pharmacy, Bucharest

## Abstract

"Refractory anemia with ring sideroblasts and thrombocytosis" (RARS-T) is a rare disease, a provisional entity, with a controversial status in the 2008 revised *WHO* classification. Even at present time, RARS-T is a matter of debate whether it is a distinct clinicopathological entity or more likely a constellation of clinical and pathological features of two well-defined myeloid neoplasms, myelodysplastic syndrome and myeloproliferative neoplasm. Perhaps none of the clonal disorders illustrates better the challenges presented by the current classification of myeloid neoplasms, than this clinical entity with overlapping features of both refractory anemia with ring sideroblasts and essential thrombocythemia. The purpose of this study is to present the evolution of such a case, with difficulties in establishing not only the correct diagnosis, but also the appropriate therapeutic approach. For this reported case, we present documented details regarding persistent thrombocytosis, slightly increased number of leukocytes and analysis of Janus kinase 2 (JAK2) genes that revealed a V617F mutation, confirming the presence of an underlying myeloproliferative neoplasm, followed later in the evolution by occurrence of myelodysplastic features as ring sideroblasts. This case might interest pathologists, but especially clinicians, for at least two reasons: the rarity of this disease and the lack of data on prognosis of these patients, probably because of relatively recent established diagnosis criteria and existence of few studies with small number of patients. The third interesting aspect for practitioners would be the absence of consensus on optimal clinical treatment for this disorder, because there are few cases that meet the rigorous diagnostic criteria.

**Keywords:** refractory anemia with ring sideroblasts and thrombocytosis, overlapping syndromes, prognosis, treatment.

## Introduction

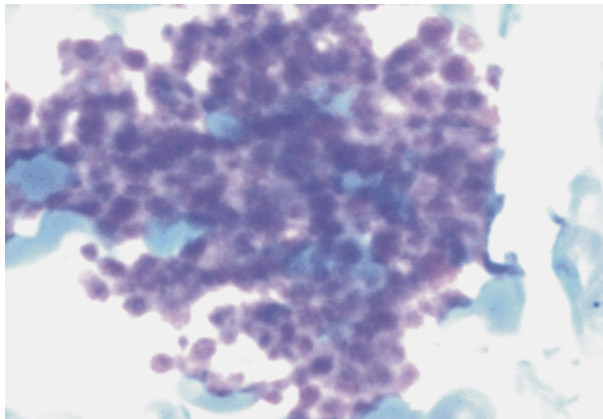
Both 2001 *World Health Organization* (WHO) classification of hematopoietic neoplasms and 2008-revised *WHO* classification include a provisional entity, "refractory anemia with ring sideroblasts and thrombocytosis". RARS-T was defined for the first time in 2001 as an overlap syndrome with clinical and morphologic features of "myelodysplastic syndrome" (MDS), as well as features of BCR-ABL1-negative myeloproliferative neoplasm (MPN), marked thrombocytosis associated with abnormal megakaryocytes [1, 2]. The inclusion criteria were platelet count over  $600 \times 10^9/L$ ,  $\geq 15\%$  ring sideroblasts,  $< 5\%$  undifferentiated marrow blasts, and megakaryocytic proliferation with morphologic pattern similar to essential thrombocythemia (ET), with the exclusion of chromosome abnormalities 5q-syndrome or rearrangements of the long arm of chromosome 3 [3]. In 2005, Shaw GR proposed similar inclusion criteria for "ringed sideroblasts with thrombocytosis" (RST), but he included patients with platelet count over  $500 \times 10^9/L$ , with no evidence of iron deficiency or splenectomy and with more than 3% marrow blasts [4]. However, since 2006, several working groups have reported the association of this clinical provisional entity with high frequency of JAK2 V617F or MPL W515 mutations [5–7]. Because of this molecular abnormalities and other clinical and morphological features some researchers

questioned whether RARS-T is a separate entity in the 2008 revised *WHO* classification [8–10] or it is simply a variant of RARS with thrombocytosis, ET with more ringed sideroblasts, or the coexistence of these two disorders (RARS and ET) [11, 12]. Whether RARS-T is a separate clinical entity or a result of additional acquired genetic abnormality resulting in progression of RARS or ET, is still a topic opened for debate.

## Patient, Methods and Results

We present the case of a 75-year-old man with prior history of cardiac disease (ischemic heart disease and hypertension, mixed dyslipidemia) and chronic renal failure due to chronic kidney disease stage IV and hyperuricemia, who presented to our clinic for investigation of blood count abnormalities (slight increase in the number of leukocytes and marked thrombocytosis). On examination, the patient appeared well, without respiratory or cardiac distress, with a spleen tip palpated below the left costal margin (110 mm antero-posterior spleen diameter), and no hepatomegaly. Blood cell count revealed the following: elevated number of leukocytes  $11.6 \times 10^9/L$  (57% segmented neutrophils, 12% monocytes, 3% basophils, 3% eosinophils, 24% lymphocytes), thrombocytosis  $812 \times 10^9/L$ , hemoglobin of 13.5 g/dL. The mean corpuscular volume was 56.5 fL, with elevated RBC  $7.40 \times 10^6/mm^3$  (NR 3.8–5.8  $\times 10^6/mm^3$ ), MCH 17.8 pg

(NR 27–31), MCHC 31.4 g/dL (NR 32–36), RDW 34.9% (NR 11.5–15.5). Peripheral blood smear revealed anisocytosis, microcytosis, poikilocytosis (targeted red cells, erythrocytes with basophilic stippling), severe platelet anisocytosis (enlarged platelet) (Figure 1).



**Figure 1 – Examination of peripheral blood smear: increased number of platelets with large forms present (MGG stain,  $\times 100$ ).**

For the severe microcytosis of this patient without anemia, but with an elevated red cell count, hemoglobin electrophoresis was performed. The result was an inherited defect in globin synthesis (HbA=95.8%, HbA2=4.2% – minor thalassemia – thalassemia trait).

After confirming persistent thrombocytosis on peripheral blood smear review, our diagnostic evaluation focused on determining whether this process was reactive or clonal.

CRP and other acute phase reactants were evaluated. Results were within normal ranges. Ferritin and iron studies revealed the following: normal level of ferritin – 50 ng/mL, slightly decreased value of iron – 42  $\mu$ g/dL (NR 40–140), with normal total iron-binding capacity (250  $\mu$ g/dL), folate (20.5 ng/mL) and cobalamine (581 pg/mL) level. Erythropoietin (EPO) level was 1.3 UI/L (NR 3.7–29.5). Other methods used for evaluation of a possible reactive thrombocytosis included: upper gastrointestinal endoscopy (acute erosive gastroduodenitis, but no signs of active bleeding and negative biopsy for *Helicobacter pylori*), lower gastrointestinal endoscopy (colonic polyps – with no signs of bleeding and normal endoscopic biopsy). Serum level of lactate dehydrogenase (LDH) was within normal ranges (237 U/L). Due to known renal pathology persistent elevated values of creatinine and BUN were present (creatinine 2.6 mg/dL, BUN 73 mg/dL).

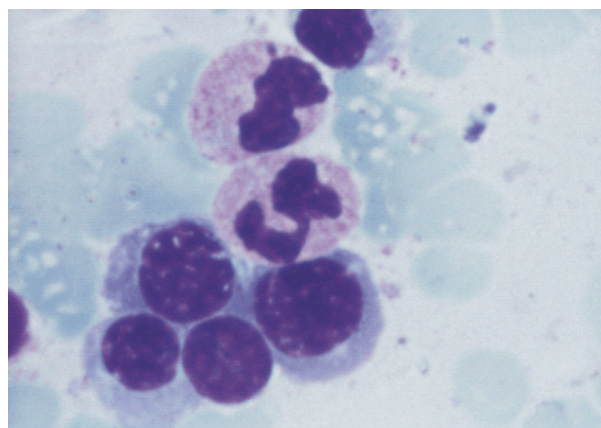
Bone marrow aspiration and biopsy were performed. Bone marrow aspirate showed increased cellularity, with normal granulocytic and erythroid series, and rare atypical megakaryocytes with large lobulated nuclei; normal storage iron; no signs of erythroid dysplasia as ring sideroblasts. Pathological examination of core-biopsy specimen revealed a hypercellular marrow 80% cellularity, erythroid hyperplasia with normoblastic erythroid proliferation and no other signs of dyserythropoiesis; megakaryocytes with marked proliferation, relatively frequent atypical megakaryocytes with hyper-

lobulated nuclei arranged in loose perivascular groups, absence of intrasinusoidal hematopoiesis. There were no morphologic abnormalities in the granulocytic series. Reticulin deposition was not increased (MF=0). A diagnostic test result of chronic myeloproliferative neoplasm was established. For this reason, JAK2 mutational analysis was the next step in our diagnostic algorithm. Using allele-specific PCR method JAK2-V617 mutation was identified. MPL and FLT 3 were negative. Based on these findings, the diagnosis was chronic myeloproliferative neoplasm JAK2 (V617F) positive.

Because he was considered to have a high risk for thrombosis (age >60 years, elevated number of leukocytes and platelets, JAK2-V617F mutation, mixed dyslipidemia and cardiac disease), the patient received treatment with anagrelide 1.5 mg daily, an orally active quinazolinone derivative capable to block megakaryocytic differentiation and proliferation, in association with antiplatelet therapy (low doses of Aspirin – 75 mg/daily). Anagrelide appeared to have a small benefit in reducing the platelet number.

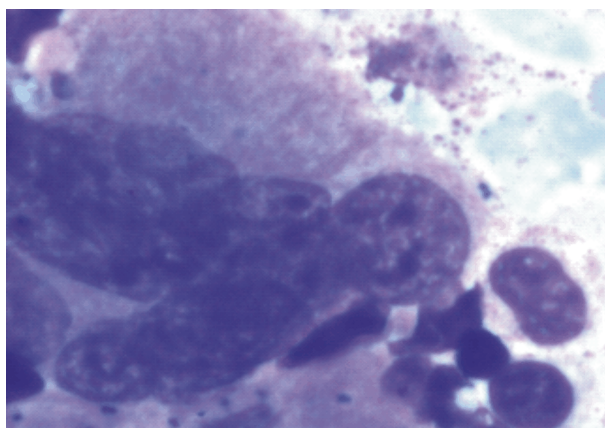
After almost five months of treatment, he presented progressive anemia Hb=8.7 g/dL, normal number of leukocytes –  $8.7 \times 10^9$ /L with 52% segmented neutrophils, 3% basophils, 3% eosinophils, 13% monocytes, 29% lymphocytes and a persistent thrombocytosis –  $500 \times 10^9$ /L.

Bone marrow aspiration and biopsy were repeated. The bone marrow aspirate showed increased cellularity, dysgranulopoiesis features – few Pelger–Huet-like granulocytes, erythroid proliferation with myelodysplastic features (megaloblastoid changes, asynchrony of nuclear-cytoplasmic maturation, basophilic stippling) (Figure 2) and marked proliferation of megakaryocytes, some of them with hyperlobulated nuclei (Figure 3) and micromegakaryocytes (Figure 4). Increased medullar hemosiderin and 28% ringed sideroblasts in bone marrow were present on Prussian blue iron stain (Figure 5). Serum and urinary lead values were normal. EPO was 1.8 UI/mL.

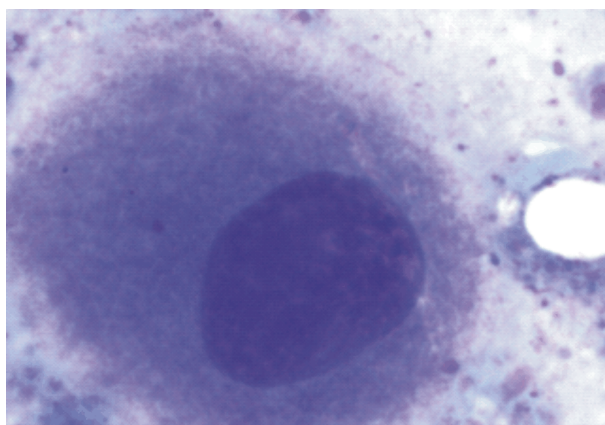


**Figure 2 – Bone marrow aspiration. Dysgranulopoiesis: hypogranulation of myeloid cells, and pseudo-Pelger forms, erythroid proliferation with myelodysplastic features (megaloblastoid changes, asynchrony of nuclear-cytoplasmic maturation, basophilic stippling) (MGG stain,  $\times 100$ ).**

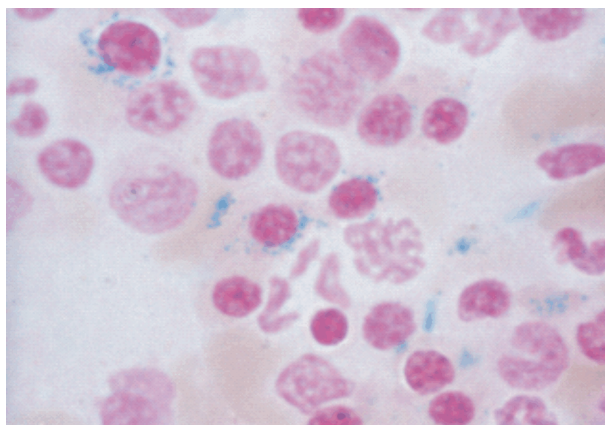




**Figure 3 – Bone marrow aspiration: increased number of megakaryocytes, some of them with hyperlobulated nuclei (MGG stain,  $\times 100$ ).**



**Figure 4 – Bone marrow aspiration: atypical megakaryocytes (hypolobulated micromegakaryocyte) (MGG stain,  $\times 100$ ).**



**Figure 5 – Bone marrow aspiration: ringed sideroblasts (Prussian Blue iron stain,  $\times 100$ ).**

Bone marrow biopsy sample revealed a hypercellular marrow, with erythroid hyperplasia with normoblastic and megaloblastic erythroid proliferation, G/E~3/1, with left shift, absent ALIP (abnormal localized immature granulocytic precursors), megakaryocytes with marked proliferation, with hyperlobulated nuclei in clusters and small-sized, others with hypolobulated or widely spared nuclei, arranged in loose perivascular groups, absence of intrasinusoidal hematopoiesis. CD34+ cells <5%. Reticulin deposition was not increased (MF=0).

A diagnosis of refractory anemia with ring sidero-

blasts associated with marked thrombocytosis (RARS-T) according to the 2008 *WHO* criteria was established.

Cytogenetic analysis was performed. Using the direct method, 24 metaphases were examined, only one was karyotyped; cells processed by the direct method showed no structural or numerical abnormalities. Karyotype: 46XY. Twenty-four hours *in vitro* marrow cells assay: 21 metaphases were analyzed, only one of them had a cytogenetic abnormality: trisomy 8; the others had normal karyotype.

After approximately six months of anagrelide treatment with no significant improvement, we preferred another treatment approach: hydroxycarbamide, an anti-metabolite that primarily acts in S-phase, very effective in reducing platelet count in ET, 500 mg twice a day, with successful results in this case (PLT  $253 \times 10^9/L$ ), a normal value of leukocytes ( $7300/mm^3$ ) without worsening anemia (Hb level of 9 g/dL), with no transfusion dependency. Currently, the patient continues treatment with hydroxycarbamide, 1 g daily.

## Discussion

Myelodysplastic syndromes (MDSs) are characterized by ineffective hematopoiesis and peripheral cytopenia. Myeloproliferative neoplasms (MPNs) are associated with overproduction of mature blood cells. The existence of conditions with overlapping features was first acknowledged in the 2001 *WHO* classification [1, 2] and then mentioned in the 2008 *WHO* classification [2, 9, 10]. Four main subcategories are included: chronic myelomonocytic leukemia (CMML), atypical chronic myeloid leukemia, BCR-ABL1-negative (aCML), juvenile myelomonocytic leukemia (JMML), and myelodysplastic/myeloproliferative neoplasm, unclassifiable (MDS/MPN-U). The latter also includes the provisional entity, refractory anemia with ring sideroblasts associated with marked thrombocytosis (RARS-T) [13, 14].

Ringed sideroblasts are erythroblasts with iron-loaded mitochondria visualized by Prussian Blue staining as a perinuclear ring of blue granules. A positive diagnosis of RARS-T requires the presence of persistent thrombocytosis (over  $400 \times 10^9/L$ ) [2, 8] and ringed sideroblasts in the bone marrow (BM>15% or more). The first one is a feature characteristic to MPN and the last one a feature of MDS, but not specific to this subgroup of myeloid tumors. Ringed sideroblasts can also be occasionally found in MPN, such as essential thrombocythemia or primary myelofibrosis [15].

In the previously reported case, the reason for evaluation in the Hematology Department of our hospital was persistent thrombocytosis. Usually thrombocytosis is described as reactive or clonal, for this reason a careful evaluation of patient's history, associated diseases and other parameters including cytogenetic and molecular analysis were required. Once the diagnosis of thrombocytosis was confirmed by peripheral blood smear ( $812 \times 10^9/L$ ) the diagnostic evaluation consisted of determining whether the process is reactive or clonal. The digestive tract was evaluated. Upper and lower digestive endoscopy showed no evidence of active bleeding. Iron profile was not one of an iron deficiency anemia. Iron marrow storage was normal. Other acute

phase reactants useful to exclude an infection or inflammation as C-reactive protein, fibrinogen or ESR were within normal ranges. The role of EPO in iron-deficiency-related thrombocytosis generated much interest because administration of human recombinant EPO results in thrombocytosis in healthy individuals as well as patients with chronic kidney disease. The physiology underlying this finding is controversial, as human recombinant EPO growth factor administration often leads to iron deficiency, leading to difficulty in determining whether elevated EPO is a cause of thrombocytosis or a surrogate for iron deficiency [16]. In this case, the level of EPO was normal.

Once a reactive thrombocytosis was excluded and thrombocytosis was persistent, our diagnostic evaluation focused on distinguishing between the various causes of clonal thrombocytosis. Possible causes of clonal thrombocytosis are CML Ph 1 chromosome positive and the other three classical BCR-ABL negative chronic myeloproliferative neoplasms. There was no evidence for CML, no clinical, biological and cytogenetic similarities to this disorder. For the differential diagnosis with the others, bone marrow biopsy was performed. Bone marrow biopsy revealed a hypercellular marrow with erythroid hyperplasia, with no signs of dyserythropoiesis; megakaryocytes with marked proliferation, frequent atypical megakaryocytes with hyperlobulated nuclei arranged in loose perivascular groups, absence of intrasinusoidal hematopoiesis, no granulocytic morphologic abnormalities, no reticulin deposition (MF=0). Primary myelofibrosis was excluded because of clinical findings (no splenomegaly), biological findings (normal LDH, no leukoerythroblastic elements on peripheral blood smear), no reduced erythropoiesis and no increased reticulin fibrosis on bone marrow biopsy. The presence of JAK2 (V617F) mutation was confirmed by quantitative polymerase chain reaction (PCR). At first, none of the following, bone marrow pattern, clinical and biological features, were conclusive for any of the two classical BCR-ABL negative MPN (ET and PV). For PV, one of the major criteria for diagnosis was absent (elevated Hb, Ht, even with increased red cell mass, because of his thalassemic trait), and the other two minor criteria (subnormal serum erythropoietin level and endogenous erythroid colony growth) were not fulfilled. For ET, bone marrow morphology included only megakaryocytic proliferation with large and mature morphology, no erythroid and granulocytic hyperplasia like in our case. The diagnosis at that moment seemed to be an unclassifiable myeloproliferative neoplasm JAK2 (V617F) positive. Another clonal condition associated with thrombocytosis is MDS with del 5q. An important morphologic finding in 5q syndrome is the presence of increased number of small or normal sized megakaryocytes, with monolobed or hypolobated nuclei, usually placed eccentrically. An isolated 5q deletion by cytogenetic exam is required to confirm the diagnosis. Such a cytogenetic abnormality was not found in this case [17].

The patient has been observed for more than five months. The treatment of choice during this period was anagrelide and low doses of aspirin. He developed

myelodysplastic features of moderate anemia with ringed sideroblasts and erythroid and granulocytic dysplasia on BM. The presence of persistent platelet count over  $450 \times 10^9/L$ , refractory anemia associated with erythroid dysplasia and ringed sideroblasts of 28%, less than 5% blasts in the BM and the absence of del(5q), t(3;3)(q21;q26) or inv(3)(q21q26), fulfilled the 2008 WHO criteria for RARS-T [2, 9, 10]. An interesting fact is that in the criteria proposed by Shaw GR, in 2005, anemia was not necessary of RST diagnosis. Therefore, what he than named "refractory sideroblasts with thrombocytosis" can be comparable to RARS-T (WHO 2008), but not equivalent. This is an important distinction. Shaw GR described, in his study of 16 RST patients, one patient who developed anemia after a 7-year period of observation [4].

### Prognosis

In these limited series of studied RARS-T patients, there seemed to be no differences between patients with RARS-T and RARS, they had similar median survival, but the survival tended to be shorter than in patients with ET [4]. This may reflect an adverse impact of myelodysplastic features, with anemia as clinical finding, which often requires erythropoietin or red cell transfusion. So far, with the available follow-ups, no RARS-T patients are known to have died of disease-related causes.

A few additional tests should be considered with respect to RARS-T patient prognosis. Since 2005, the association between these patients, that presented clinical and morphological features of both MDS (RARS) and MPN (ET), and the acquired somatic mutation in JAK2 gene, resulting in a valine to phenylalanine substitution at position 617 (JAK2-V617F) has provided new insights into the pathogenesis and prognosis of this rare disorder. In contrast to all other MDS/MPN cases, where this mutation is positive in a minority of patients, up to 60% RARS-T cases are JAK2-V617F positive [4, 6]. Frequent detection of the JAK2-V617F mutation within RARS-T patients classifies them more as MPN. In our case, the presence of JAK2-V617F mutation has been identified by allele-specific PCR method. Apart from the quantitative real-time polymerase chain reaction (PCR)-based allelic discrimination assay, used for the detection of the JAK2 (V617F) mutation in circulating granulocytes, what other data would be helpful regarding the prognosis and JAK2-V617F mutational status in this reported case? The answer to this question may include the distinction between the two categories, heterozygous or homozygous type.

Data provided by several studies focused on the relationship between JAK2-V617F mutational status and morphologic, laboratory, clinical parameters and survival [18], suggest the following:

- JAK2-V617F-positive patients have a more favorable prognosis than patients without the JAK2 mutation;
- Progression in the allelic burden from low heterozygous to high homozygous JAK2-V617F was parallel with increasing thrombocytosis;

▪ JAK2-V617F-positive patients had significantly higher red blood cell counts and hemoglobin level, lower mean corpuscular volume and higher leukocyte count.

Another molecular exam useful for RARS-T evaluation, especially for those JAK2-negative patients is MPL W515K/L mutation, negative in our case. More rarely, the association between MPL W515K/L mutation and RARS-T patients has also been reported. Schmitt-Graeff AH *et al.* reported, in 2008 [18], the presence of MPL mutation in a study of 23 RARS-T patients, 11 of them JAK2-positive and only one MPL-positive and JAK2-negative. Unlike their predecessors, Malcovati L *et al.* reported, in 2009 [19], the rare association between JAK2 and MPL W515K/L mutation with the published results of 19 RARS-T patients study (11 cases JAK2-V617F-positive and only two JAK2-positive patients had also MPL mutation). No prognostic relevance of MPL association is known at this moment.

Another mutation that seems to have prognostic value is the recently identified TET2 mutation (Ten–Eleven Translocation-2 gene) [20, 21] in a substantial number of myeloid neoplasms. TET2 seems to precede JAK2 mutation. At this moment, the prognosis value of TET2 for RARS-T patients is not known. There is few data to indicate the exact incidence of this mutation among patients with RARS-T. In only one study, conducted by Flach J, in 2009, with 23 RARS-T patients, TET2 mutation was identified by sequencing only for five cases (26%), three of them (3/5 patients) also presented mutated JAK2-V617F [22].

Regarding the cytogenetic finding, in our case trisomy 8 in only one of the karyotyped cells, this has no known prognostic value, but it might be explained by the myelodysplastic feature of RARS-T.

### Treatment

Because there are few patients that fulfill all RARS-T diagnostic criteria, the clinical experience with such cases is limited. In our case, at first, when the patient did not have anemia, it seemed logic to focus our attention on the elevated number of platelets, considering the fact that the patient associated several risk factors with great impact on thrombotic complications (the elevated number of leukocytes, JAK2 mutation, the dyslipidemic condition and the presence of cardiac disease). The first treatment option, anagrelide and low doses of aspirin, did not have a significant impact on platelet number. During these five months of treatment, the patient developed moderate anemia. More likely, this new hematological finding, anemia, well tolerated, with no substitution required, was not a consequence of anagrelide treatment. It was more likely a consequence of myelodysplastic features appearance in bone marrow (dysplastic erythropoiesis, ring sideroblasts and others). Later, the introduction of hydroxycarbamide in the patient's treatment did not worsen anemia (on his last medical check-up his hemoglobin level was 8.9 g/dL), and successfully controlled the platelet number (PLT  $230 \times 10^6/L$ ), with no venous thrombotic complications or any other side effects.

EPO may be considerate as primary treatment for all RARS-T patients with symptomatic anemia, according to the same guidelines for MDS treatment with growth factors [23].

As a successful treatment option for these patients, Huls G *et al.* have recently published in 2010 the efficacy of single-agent lenalidomide in two RARS-T patients. The daily lenalidomide dose for these two cases was 10 mg. Both patients became transfusion independent after treatment with lenalidomide, one of them had even a molecular response (negative detection for JAK2-V617F mutation by quantitative PCR) [24].

Until now, there are no published data regarding thrombocytosis in RARS-T and association with increased thrombotic risk and there is no reason to believe that treatment of very high platelet counts in RARS-T should differ from that of ET patients. Clinical experience suggests that cytoreductive effect of hydroxycarbamide is helpful in this category of patients, but there are no clinical trials until now focused on this particular group of patients and their treatment. The role of the new JAK2 inhibitors in JAK2-positive RARS-T patients remains to be discovered.

### Conclusions

RARS-T is an extremely rare disease that appears to represent the coexistence of two disorders, with erythropoiesis showing the characteristics of RARS and megakaryocytes those of ET. The uniqueness of RARS-T as a distinct entity has been debated in the literature since 2001. Because there are few cases that meet all diagnostic criteria for RARS-T, there is no consensus on the optimal clinical treatment for this disorder. A better understanding of the prognosis and management of RARS-T patients would require a more detailed investigation of these patients, especially on molecular level. This report demonstrates the difficulty of establishing an accurate diagnosis, particularly because myelodysplastic features occurred late in the evolution, as myeloproliferative features were those that prevailed in the early stage.

### References

- [1] Jaffe ES, Harris NL, Stein H, Vardiman JW (eds), *Pathology & genetics of tumours of haematopoietic and lymphoid tissues*, World Health Organization Classification of Tumours, IARC Press, Lyon, 2001.
- [2] Găman M, Vlădăreanu AM, Radesi S, *The implications of revised WHO classification (2008) of chronic myeloid neoplasms*, Rom J Intern Med, 2011, 49(1):25–30.
- [3] Schnittger S, de Sauvage FJ, Le Paslier D, Fonatsch C, *Refined chromosomal localization of the human thrombopoietin gene to 3q27-q28 and exclusion as the responsible gene for thrombocytosis in patients with rearrangements of 3q21 and 3q26*, Leukemia, 1996, 10(12):1891–1896.
- [4] Shaw GR, *Ringed sideroblasts with thrombocytosis: an uncommon mixed myelodysplastic/myeloproliferative disease of older adults*, Br J Haematol, 2005, 131(2):180–184.
- [5] Steensma DP, Caudill JS, Pardanani A, McClure RF, Lasho TL, Tefferi A, *MPL W515 and JAK2 V617 mutation analysis in patients with refractory anemia with ringed sideroblasts and an elevated platelet count*, Haematologica, 2006, 91(12 Suppl):ECR57.

- [6] Wang SA, Hasserjian RP, Loew JM, Sechman EV, Jones D, Hao S, Liu Q, Zhao W, Mehdi M, Galili N, Woda B, Raza A, *Refractory anemia with ringed sideroblasts associated with marked thrombocytosis harbors JAK2 mutation and shows overlapping myeloproliferative and myelodysplastic features*, *Leukemia*, 2006, 20(9):1641–1644.
- [7] Szpurka H, Tiu R, Murugesan G, Aboudola S, Hsi ED, Theil KS, Sekeres MA, Maciejewski JP, *Refractory anemia with ringed sideroblasts associated with marked thrombocytosis (RARS-T), another myeloproliferative condition characterized by JAK2 V617F mutation*, *Blood*, 2006, 108(7):2173–2181.
- [8] Steensma DP, Hanson CA, Tefferi A, *Independent validation of the 2008 World Health Organization (WHO) reclassification of myelodysplastic syndromes (MDS) associated with ring sideroblasts*, 50<sup>th</sup> ASH Annual Meeting and Exposition, 2008, San Francisco, Abstract 2686.
- [9] Tefferi A, Vardiman JW, *Classification and diagnosis of myeloproliferative neoplasms: the 2008 World Health Organization criteria and point-of-care diagnostic algorithms*, *Leukemia*, 2008, 22(1):14–22.
- [10] Orazi A, Germing U, *The myelodysplastic/myeloproliferative neoplasms: myeloproliferative diseases with dysplastic features*, *Leukemia*, 2008, 22(7):1308–1319.
- [11] Steensma DP, Tefferi A, *JAK2 V617F and ringed sideroblasts: not necessarily RARS-T*, *Blood*, 2008, 111(3):1748.
- [12] Malcovati L, Cazzola M, *Myelodysplastic/myeloproliferative disorders*, *Haematologica*, 2008, 93(1):4–6.
- [13] Foucar K, *Myelodysplastic/myeloproliferative neoplasms*, *Am J Clin Pathol*, 2009, 132(2):281–289.
- [14] Vardiman JW, Thiele J, Arber DA, Brunning RD, Borowitz MJ, Porwit A, Harris NL, Le Beau MM, Hellström-Lindberg E, Tefferi A, Bloomfield CD, *The 2008 revision of the World Health Organization (WHO) classification of myeloid neoplasms and acute leukemia: rationale and important changes*, *Blood*, 2009, 114(5):937–951.
- [15] Schmitt-Graeff A, Thiele J, Zuk I, Kvasnicka HM, *Essential thrombocythemia with ringed sideroblasts: a heterogeneous spectrum of diseases, but not a distinct entity*, *Haematologica*, 2002, 87(4):392–399.
- [16] Stohlawetz PJ, Dzirio L, Hergovich N, Lackner E, Mensik C, Eichler HG, Kabrna E, Geissler K, Jilma B, *Effects of erythropoietin on platelet reactivity and thrombopoiesis in humans*, *Blood*, 2000, 95(9):2983–2989.
- [17] Ingram W, Lea NC, Cervera J, Germing U, Fenaux P, Cassinat B, Kiladjian JJ, Varkonyi J, Antunovic P, Westwood NB, Arno MJ, Mohamedali A, Gaken J, Kontou T, Czepulkowski BH, Twine NA, Tamaska J, Csomer J, Benedek S, Gattermann N, Zipperer E, Giagounidis A, Garcia-Casado Z, Sanz G, Mufti GJ, *The JAK2 V617F mutation identifies a subgroup of MDS patients with isolated deletion 5q and a proliferative bone marrow*, *Leukemia*, 2006, 20(7):1319–1321.
- [18] Schmitt-Graeff AH, Teo SS, Olschewski M, Schaub F, Haxelmans S, Kirm A, Reinecke P, Germing U, Skoda RC, *JAK2V617F mutation status identifies subtypes of refractory anemia with ringed sideroblasts associated with marked thrombocytosis*, *Haematologica*, 2008, 93(1):34–40.
- [19] Malcovati L, Della Porta MG, Pietra D, Boveri E, Pellagatti A, Galli A, Travaglino E, Brisci A, Rumi E, Passamonti F, Invernizzi R, Cremonesi L, Boultonwood J, Wainscoat JS, Hellström-Lindberg E, Cazzola M, *Molecular and clinical features of refractory anemia with ringed sideroblasts associated with marked thrombocytosis*, *Blood*, 2009, 114(17):3538–3545.
- [20] Delhommeau F, Dupont S, Della Valle V, James C, Trannoy S, Massé A, Kosmider O, Le Couedic JP, Robert F, Alberdi A, Lécluse Y, Plo I, Dreyfus FJ, Marzac C, Casadevall N, Lacombe C, Romana SP, Dessen P, Soulier J, Viguie F, Fontenay M, Vainchenker W, Bernard OA, *Mutation in TET2 in myeloid cancers*, *N Engl J Med*, 2009, 360(22):2289–2301.
- [21] Tefferi A, Lim KH, Abdel-Wahab O, Lasho TL, Patel J, Patnaik MM, Hanson CA, Pardanani A, Gilliland DG, Levine RL, *Detection of mutant TET2 in myeloid malignancies other than myeloproliferative neoplasms: CMML, MDS, MDS/MPN and AML*, *Leukemia*, 2009, 23(7):1343–1345.
- [22] Flach J, Dicker F, Schnittger S, Kohlmann A, Haeflacher T, Haeflacher C, *Mutations of JAK2 and TET2, but not CBL are detectable in a high portion of patients with refractory anemia with ring sideroblasts and thrombocytosis*, *Haematologica*, 2010, 95(3):518–519.
- [23] Jädersten M, Montgomery SM, Dybedal I, Porwit-MacDonald A, Hellström-Lindberg E, *Long-term outcome of treatment of anemia in MDS with erythropoietin and G-CSF*, *Blood*, 2005, 106(3):803–811.
- [24] Huls G, Mulder AB, Rosati S, van de Loosdrecht AA, Vellenga E, de Wolf JT, *Efficacy of single-agent lenalidomide in patients with JAK2 (V617F) mutated refractory anemia with ring sideroblasts and thrombocytosis*, *Blood*, 2010, 116(2):180–182.

### Corresponding author

Mihaela Găman, MD, Emergency University Hospital, 169 Independenței Avenue, 050098 Bucharest, Romania; Phone +4021–318 05 23, e-mail: mihaela\_dervesteanu@yahoo.com

Received: April 5<sup>th</sup>, 2012

Accepted: September 5<sup>th</sup>, 2012