Rom J Morphol Embryol 2011, 52(3):831–835

ORIGINAL PAPER

RJME
Romanian Journal of Morphology & Embryology
http://www.rjme.ro/

Histopathological aspects of benign epithelial tumors located in areas of friction or chronic irritation of the tongue

A. FRONIE[1)], DANIELA DUMITRESCU[2)], V. VASCĂ[3)], ANCA SIMONA FRONIE[4)]

[1)]*Department of Oral and Maxillofacial Surgery*
[2)]*Department of Radiology*
University of Medicine and Pharmacy of Craiova
[3)]*Department of Oral and Maxillofacial Surgery, "Vasile Goldiş" Western University, Arad*
[4)]*Department of Anesthesiology and Intensive Care, University of Medicine and Pharmacy of Craiova*

Abstract

Besides lesions considered to be premalignant (such as erythroplasia, Bowen disease), a number of other potentially malignant lesions with higher or lower degree of epithelial dysplasia depending on the keratinization degree or determined by the action of carcinogens and irritants substances are described in the oral mucosa. Although they are practically considered the most harmless formations located on the oral mucosa, papillomas and condylomas are also the most frequent. In this study (conducted on a total of 38 cases with benign neoplasia) we planned a histopathological evaluation of surgical excision samples obtained from interventions on lingual neoplasias and harvested from the areas most exposed to chronic trauma or the areas in direct contact with mechanical irritants, in order to determine the histopathological pattern of the different types of histopathological lesions, the possible presence of keratosis-type changes or even possible dysplasias.

Keywords: papilloma, condyloma, adenoma, histopathological examination, dysplasia.

Introduction

When compared to clinical trials, histopathology studies have the great advantage of reflecting the exact status of the tissue structure at a time, either physiological or pathological, providing high quality results due to the objectivity that can not be excluded or discussed by means of other clinical and laboratory studies. They give us an image of the local, regional or even remote tumor extension, whenever such doubt exists. The histopathological diagnosis is also the basis for the initiation of complementary chemotherapy or radiotherapy. Meanwhile, the histopathological result represents a confirmation of the therapeutical approach for the surgeon as to the scale of the surgical intervention that was performed (radical or palliative).

Papilloma is considered by most authors as the most frequent lingual tumor. Despite their great variety, Pine and Braccini (cited by [1]) divided them into six categories:

- acantosic;
- protoplastic;
- fibrous;
- angioblastic;
- fibroangioblastic;
- mixed.

Schuerman (cited by [1]), taking into account only the stromal appearance, distinguished only two varieties of papilloma:

- fibrous, in which stromal tissue is composed of connective tissue more or less rich in collagen;
- fibrous and telangiectasic, in which the vascular component prevails.

Papilloma is a benign tumor originating on the surface of the lingual epithelium. The development of this neoformation is linked to the inflammatory response to mechanical or bacterial irritation. Lingual location is most common in the oral cavity. Tumor size varies, ranging from a few millimeters to 4–5 cm. It occurs at any age, is usually singular, and has a verrucous or cauliflower-like appearance, sessile or pedunculated, with variable consistency. It may be associated with leukoplakia or show dysplasia with dyskeratosis [2].

Papillomatosis with oral localization may develop independently or in combination with other oral lesions without malignant connotations, but in some lingual malignant tumor tissue fragments, the presence of traces of DNA as well as the antigen of human papilloma virus (HPV type 16) was reported in about 20% of subjects, as compared to 80–90% in cases with cervical cancer. HPV contains a variety of genes, but those that are expressed early in the process of viral replication (gene E) produce proteins that can bind and inactivate the products of two tumor-suppressor genes: p53 and Rb (retinoblastoma gene). In this respect, HPV was detected in half of cases with precancerous lesions and

subsequently to all subjects who developed squamous cell carcinoma [3].

Material and Methods

The material investigated in this study was human material from the Oral and Maxillofacial Surgery Clinic, Emergency County Hospital of Craiova, sent to the Pathology Department of the same hospital for histopathological examination.

The material came from patients between 3 and 89-year-old who shared the clinical diagnosis of lingual tumor. They were either submitted to diagnostic biopsy, or therapeutic and diagnostic excision or partial resection of the tongue were performed.

Surgical samples were taken from areas of chronic irritation that such formations are mostly exposed to, in this case the tip of the tongue, the edges of the tongue or the ventral surface of the tongue in close proximity to the pelvilingual groove.

From the histogenetic point of view, we found that benign tumors had epithelial or mesenchymalorigin, or their histogenesis was uncertain. Benign epithelial tumors were papillomas, condylomas and adenomas.

For histopathological study of selected cases, we used the classical technique for paraffin inclusion, followed by classic Hematoxylin–Eosin stain and van Gieson's trichrome stain, and when it was required, we also used the special stains (Gömöri's silver impregnation).

We also used the clinical observation charts, both current and retrospective, which provided a series of clinical data useful for the diagnosis. In this respect, we mention: patients' age and gender, clinical diagnosis, lesion topography and its relationship with adjacent structures (root debris, inadequate prosthetics, tartar, parodontic teeth, level of oral hygiene, vicious habits, etc.). The most useful data from the current and retrospective histopathological records were the macroscopic appearance of surgical samples, as well as the final histopathological diagnosis of the studied tumors.

Results

From the histogenetic and microscopic point of view, the 38 benign tumors of the tongue had different origins: epithelial origin (18 cases), mesenchymal origin (16 cases), and four cases belonged to the category of tumors of uncertain origin (Table 1).

Table 1 – ***Histogenetic distribution of benign tumors of the tongue***

Type of tumor	Epithelial tumors	Mesenchymal tumors	Tumors of uncertain origin
No. of cases	18	16	4
Percentage	47.36	42.10	10.52

The benign epithelial tumors found in 18 cases represented 47.36% of all benign lingual tumors that were studied. They represented the larges histogenetic group of benign tumors.

From the histopahologic point of view, the 18 epithelial benign tumors were squamous papillomas, condylomas and adenomas (Table 2).

Table 2 – ***Histopathologic distribution of benign epithelial tumors of the tongue***

Type of tumor	Squamous papilloma	Condyloma acuminata	Adenoma
No. of cases	14	2	2
Percentage	77.78	11.11	11.11

Squamous papillomas of the tongue were seen in 14 cases, representing the most common benign tumors of epithelial origin and also the most common benign tumors diagnosed in the time period take into consideration. They represented 77.78% of benign tumors of epithelial origin and 47.36% of benign tumors of the tongue. Lesions were located at the tip of the tongue or on its lateral edges, and especially the right one. They were seen in patients aged between 17 and 82 years, with the highest incidence after the age of 40 years (more than half of the cases analyzed). As to the gender distribution, we noticed a slight preponderance in males (eight of all papillomas).

Microscopically, tumors were composed of a thin branching shaft with connective-vascular structure, covered by a proliferated squamous epithelium. Neoplastic squamous epithelium appeared evenly thickened, with varying degrees of hyperkeratosis (Figure 1).

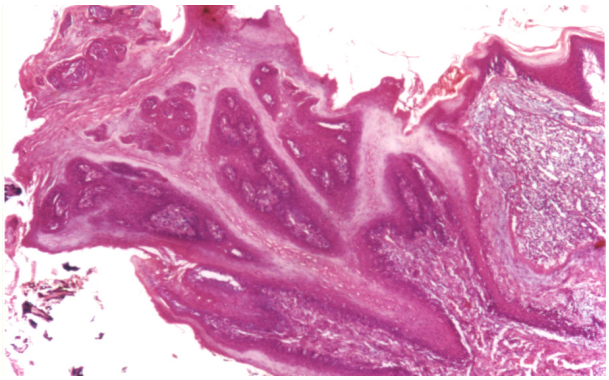

Figure 1 – ***Squamous papilloma of the tongue (HE stain, ob. 6×).***

In two of the cases, the tumor epithelium showed superficial ulcerations with hematoxylinophilic clusters of fungal colonies (Figure 2). Both cases were accompanied by simple dysplasia of the neoplastic epithelium. Thus, the deeper epithelial layers in the lower third of the epithelium showed cellular atypia. Epithelial cells in this area were small sized, with large hyperchromatic nuclei, and scant basophilic cytoplasm. We also found an increased mitotic activity.

Tumor stroma showed variable changes. In nine cases, the pattern was that of a balanced conjunctive-vascular proliferation. In two cases, we observed an increased fibroblastic-fibrocytic proliferation along with the presence of collagen fibers, raising the problem of differential diagnosis with a fibroma. In this situation the lack of separation of connective proliferation, the lack of a particular proliferation pattern of neoplastic cells as well as the presence of characteristic changes in the overlying epithelium, allowed the diagnosis of sessile papilloma with fibrous stroma (Figure 3).

There were two cases with *condyloma acuminata*, accounting for 11.11% of all benign epithelial tumors,

5.26% of all benign tumors with this localization, and only 1.19% of all lingual tumors that were analyzed. Both tumors were located in the anterior portion of the right side of the tongue. They were seen in two male patients aged 23 and 34 years, respectively.

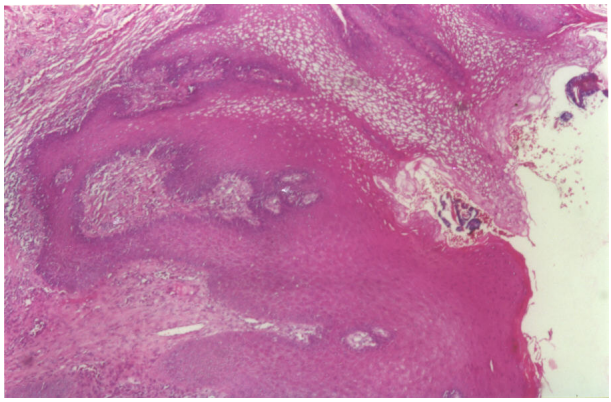

Figure 2 – ***Papilloma with fungal infestation (HE stain, ob. 6×).***

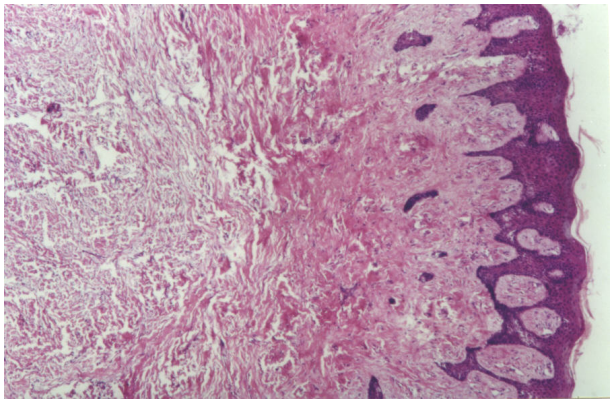

Figure 3 – ***Sessile papilloma with fibrous stroma (HE stain, ob. 6×).***

The microscopic examination revealed connective-vascular shafts, with occasional finger-like branching, covered by a proliferated squamous epithelium. Overall, the tumoral epithelium showed papillomatosis, acanthosis, parakerathotic and sometimes hyperkeratotic changes (Figure 4).

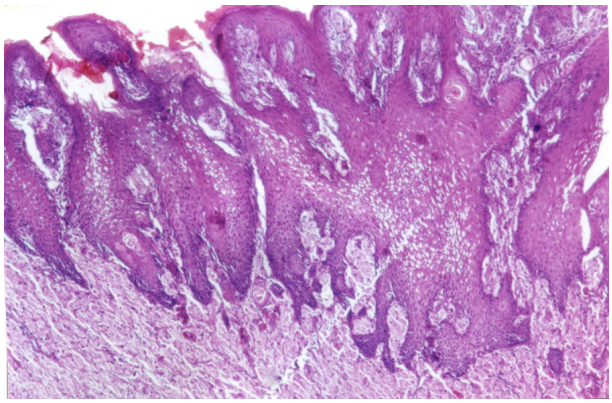

Figure 4 – ***Condyloma of the tongue (HE stain, ob. 6×).***

Squamous cells of the superficial and middle layers showed characteristic aspects of koilocytotic atypia which are considered to be the morphological expression of infection with HPV (Human Papilloma Virus). HPV infected squamous cells were large and had a perinuclear clear cytoplasmic halo, which was surrounded by a layer of reduced condensed cytoplasm. We also noted the atypical nuclear changes. Koilocyte nuclei were hyperchromatic and had a central location, with rough chromatin piles along a nuclear membrane with irregular outline (Figure 5).

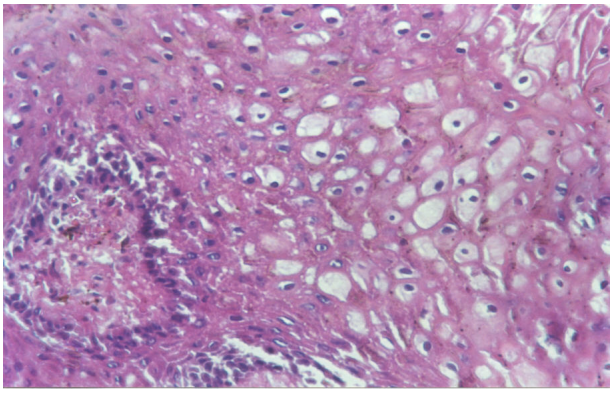

Figure 5 – ***Condyloma of the tongue (HE stain, ob. 20×).***

There was one case with pleomorphic adenoma (72-year-old male). The tumor developed at the base of the tongue. The microscopic structure of the tumor on serial sections from different parts of it was characterized by a marked lesional pleomorphism. It was formed made up of both epithelial cell proliferations and mesenchymal tissue (Figure 6).

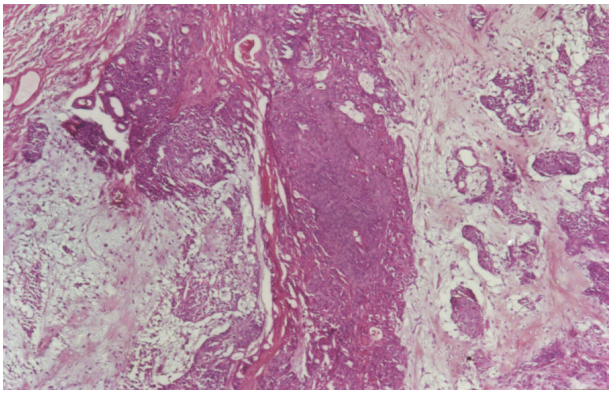

Figure 6 – ***Pleomorphic adenoma of the tongue (HE stain, ob. 6×).***

The epithelial component was composed of cells with highly variable morphology: cubic, cylindrical, spindle-like, plasmacytoid; the transition from one cell type to another was brutal. Neoplastic cell nuclei had a normal appearance and mitoses were rare and typical. The disposition of epithelial cells was extremely diverse. They formed solid areas or tubular ductal structures and in some cases anastomosed trabeculae. Ductal structures were the main means of disposal of epithelial cells. They showed well established or abortive lumina that were lined by cubic or cylindrical cells surrounded by a row of spindle or star-shaped cells (Figure 7). The mesenchymal stromal component was composed of myxoid or chondromyxoid areas as well as fibrohyaline ones. It separated the islands of epithelial cells and sometimes accumulated around individual cells (Figure 8).

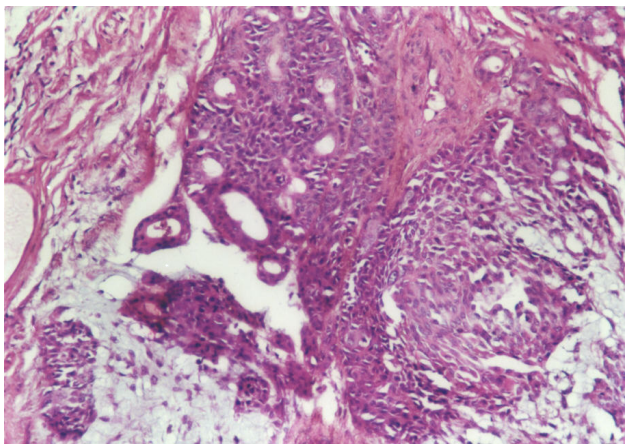

Figure 7 – ***Pleomorphic adenoma of the tongue: epithelial component (HE stain, ob. 10×).***

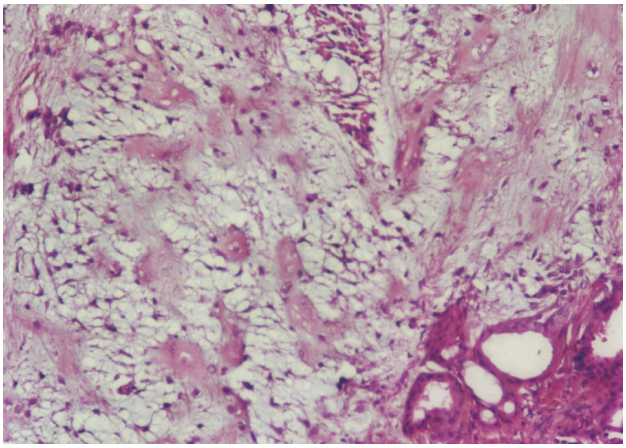

Figure 8 – ***Pleomorphic adenoma of the tongue: stromal component (HE stain, ob. 10×).***

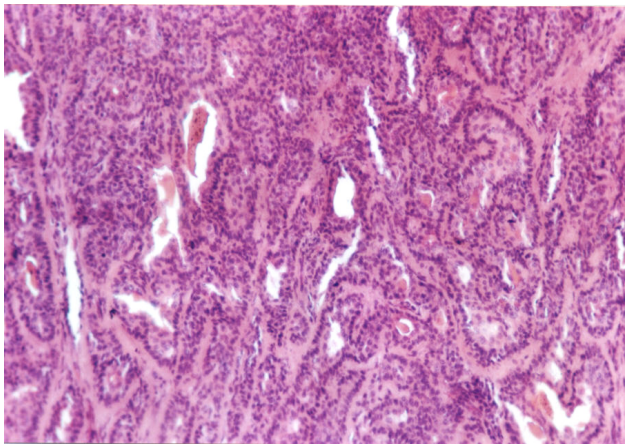

Figure 9 – ***Basal cell adenoma (HE stain, ob. 10×).***

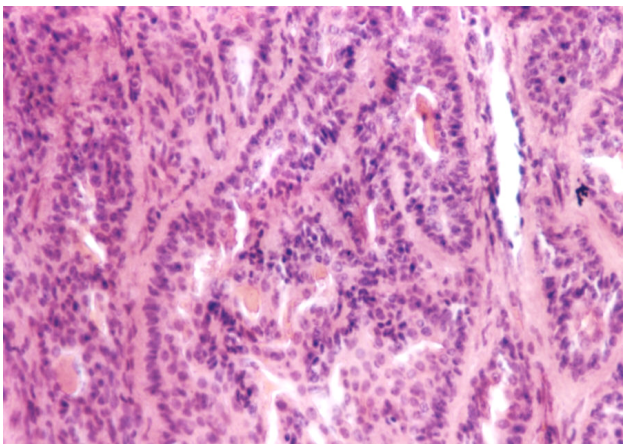

Figure 10 – ***Basal cell adenoma (HE stain, ob. 10×).***

There was one case with basal cell adenoma (a male patient aged 58 years). The tumor developed at the base of the tongue.

Microscopically, the tumor had a monomorphic appearance, consisting of a proliferation of basaloid type cells, among which we observed rare myoepithelial or ductal type cells. Neoplastic cells were oval shaped, with small and uniform appearance. Their cytoplasm was weakly eosinophilic or amphophilic, with imprecise boundaries. Tumor cell nuclei were round or oval, generally hyperchromatic, sometimes with visible nucleoli. Neoplastic cells showed a variable growth pattern; areas with tumor islands alternated with areas of trabecular and tubular appearance (Figure 9). The boundary between neoplastic cells and stroma often showed a palisade arrangement of tumor cells, especially in island-like areas (Figure 10). Tumor stroma was of fibrocollagenous type and showed a variable representation.

Discussion

Solitary squamous papillomas are considered the most common benign tumors of the oral mucosa. It is estimated that the tongue is the second location in terms of frequency of tumors, after the mouth palate [4]. Data on the incidence of lingual squamous papillomas according to gender and age group indicates that tumors occur with equal frequency in both males and females, mostly around an age between 30 and 40 years [5, 6].

The etiologic factors of the lesions include mechanical irritation, which explains their preferential location on the lateral aspect of the tongue. It is hypothesized that a large number of lingual papillomas also show related dysplasia, which is more pronounced in the case of infections with *Candida albicans*. Some authors prefer to include such combinations in a separate group, known as chronic hyperplastic candidiasis or candidiasic hyperplasia [7, 8].

One peculiar etiologic aspect is the existence of papillomas with genetic determinism such as those that occur in Cowden syndrome, regarded as modified paraneoplastic change that may accompany a breast carcinoma.

Some authors consider that condilomas are a type of squamous papillomas [9]. In the present study, due to the particular etiology as well as the distinct histopathological changes we preferred to classify them as an independent entity. Complex immunohistochemical and hybridization studies demonstrated that several subtypes of HPV are involved in the etiology of lingual condilomas. Among those, the most frequently identified ones were the HPV 6 and 11 subtypes, which were associated with benign squamous lesions, but also subtypes 16 and 18, which were associated with squamous lesions with malignant potential. The infection with the more rare HPV subtypes, 31 and 33, also belongs to the latter [10–13].

The literature mentions an increased incidence of condilomas HIV infected patients also showing frequent nuclear atypia.

The literature also indicates that the lingual pleomorphic adenomas are rarely encountered. Tumors are located at the base of the tongue, arising from the minor salivary glands and affects mostly females of old age [8, 14, 15].

Yoshitara T and Suzuki S [16] communicated the case of an 87-year-old female with a tumor at the base of the tongue, which was clinically manifested by dysphagia and dysphasia. Histopathological examination of the surgical sample revealed the diagnosis of pleomorphic adenoma. Researchers also show that tumors such as basal cell adenomas rarely originate from minor salivary glands, with more than 75% of cases located within the parotid gland.

They occur preferentially in elderly adults, over the age of 70 years, and they are two times more frequent in women than men [8, 14, 17], but literature also reports the case of a middle age man with a bilateral adenoma [18].

Conclusions

In two of the papillomas, the tumor epithelium showed superficial ulcerations with hematoxylinophilic clusters of fungal colonies. Both cases were accompanied by simple dysplastic changes of the neoplastic epithelium with increased mitotic activity.

Tumor stroma showed various changes ranging from a evenly balanced connective-vascular proliferation (nine cases) to an intense fibroblastic-fibrocytic type proliferation (two cases).

Overall, the tumoral epithelium of condilomas showed papillomatosis, acanthosis, parakeratosis and occasional hyperkeratotic changes.

Squamous cells of the superficial and middle layers of condillomas showed characteristic aspects of koilocytotic atypia, which are considered the morphological expression of HPV infection. We also noticed atypical nuclear changes.

Although they are considered the most harmless benign neoplasias of the oral cavity, both lingual papillomas and condilomas may show sufficient structural changes in the epithelium that would allow grafting of malignant lesions at this level as long as the irritant that induced the lesion persists, or if its action is also associated with a carcinogenic agent.

Both pleomorphic and basal cell adenomas were mostly located at the base of the tongue, a region that is somewhat protected from friction or chronic mechanical irritation; this is the reason why no dysplastic or keratotic changes of the overlying epithelium were noticed.

References

[1] Borio PS, Glossopatie. In: De Michelis B, Modica R, Re G, (eds), *Trattato di clinica odontostomatologica*, 3-a edizione, Edizioni Minerva Medica, Torino, 1998, 659–685.

[2] Fronie A, *Glosopatiile. Ghid clinic*, Ed. Alma, Craiova, 2006, 127–128.

[3] Soames JV, Southam JC, *Oral pathology*, 4th edition, Oxford University Press, Oxford, 2005.

[4] Batsakis JG, Raymond AK, Rice DH, *The pathology of head and neck tumors: papillomas of the upper aerodigestive tracts, Part 18*, Head Neck Surg, 1983, 5(4):332–344.

[5] Lung T, Tumorile benigne şi hiperplaziile țesuturilor moi orofaciale. In: Burlibaşa C (ed), *Chirurgie orală şi maxilofacială*, Ed. Medicală, Bucureşti, 1999, 753–773.

[6] Abbey LM, Page DG, Sawyer DR, *The clinical and histopathologic features of a series of 464 oral squamous cell papillomas*, Oral Surg Oral Med Oral Pathol, 1980, 49(5):419–428.

[7] Lipperheide V, Quindós G, Jiménez Y, Pontón J, Bagán-Sebastián JV, Aguirre JM, *Candida biotypes in patients with oral leukoplakia and lichen planus. Candida biotypes in leukoplakia and lichen planus*, Mycopathologia, 1996, 134(2):75–82.

[8] Fletcher CDM, *Diagnostic histopathology of tumors*, 2nd edition, vol. 1, 2, Churchill Livingstone, 2000.

[9] Adler-Storthz K, Newland JR, Tessin BA, Yeudall WA, Shillitoe EJ, *Identification of human papillomavirus types in oral verruca vulgaris*, J Oral Pathol Med, 1986, 15(4):230–233.

[10] Green TL, Eversole LR, Leider AS, *Oral and labial verruca vulgaris: clinical, histologic and immunohistochemical evaluation*, Oral Surg Oral Med Oral Pathol, 1986, 62(4):410–416.

[11] Miller CS, White DK, Royse DD, *In situ hybridization analysis of human papillomavirus in orofacial lesions using a consensus biotinylated probe*, Am J Dermatopathol, 1993, 15(3):256–259.

[12] Tong P, Mutasim DF, *Herpes simplex virus infection masquerading as condyloma acuminata in a patient with HIV disease*, Br J Dermatol, 1996, 134(4):797–800.

[13] Bouquot JE, Wrobleski GJ, *Papillary (pebbled) masses of the oral mucosa: more than simple papillomas*, Pract Periodontics Aesthet Dent, 1996, 8(6):533–543; quiz 543.

[14] Pindborg JJ, Reichart PA, Smith CJ, van der Waal I, Sobin LH, *Histological typing of cancer and precancer of the oral mucosa*, 2nd edition, Springer-Verlag, Berlin, 1997.

[15] El Kohen A, Essakalli L, Kzadri M, Sefiani S, Seffar Andaloussi Z, *Pleomorphic adenoma of tongue base*, Rev Stomatol Chir Maxillofac, 2007, 108(3):215–217.

[16] Yoshihara T, Suzuki S, *Pleomorphic adenoma of tongue base causing dyphagia and dysphasia*, J Laryngol Otol, 2000, 114(10):793–795.

[17] Tonigaki Y, Mikami Y, Ono M, Tsukuda M, *Pleomorphic adenoma of the lateral side of the tongue*, Acta Otolaryngol, 2004, 124(5):649–651.

[18] Virk RS, Hundal H, *Bilateral pleomorphic adenoma of the anterior tongue: a case report*, Ear Nose Throat J, 2005, 84(12):789–790.

Corresponding author

Adrian Fronie, Lecturer, MD, PhD, Department of Oral and Maxillofacial Surgery, University of Medicine and Pharmacy of Craiova, 2–4 Petru Rareş Street, 200349 Craiova, Romania; Phone +40723–774 725, e-mail: adrianfronie@yahoo.com

Received: May 19th, 2011 *Accepted: July 25th, 2011*