

Gross morphometric reduction of rats' cerebellum by gamma irradiation was mitigated by pretreatment with *Vernonia amygdalina* leaf extract

O. OWOEYE¹⁾, E. O. FAROMBI²⁾, S. K. ONWUKA³⁾

¹⁾Department of Anatomy

²⁾Department of Biochemistry

Faculty of Basic Medical Sciences, College of Medicine

³⁾Department of Veterinary Anatomy,
Faculty of Veterinary Medicine

University of Ibadan, Ibadan, Nigeria

Abstract

The methanolic extract of *Vernonia amygdalina* (M) or "bitter leaf" is known for its antioxidant activity, and antioxidants are noted to mitigate radiation damage in tissues. The aim of the present study was to observe the radioprotective effect of M on the cerebellum of gamma irradiated rats using alpha-tocopherol (TOCO) as a reference antioxidant. Forty-two male Wistar rats (n=42) weighing 200–240 g were taken for the study. The study comprised of seven groups, with each group comprising of six (n=6) rats i.e. control, M at 250, and 500 mg/kg/day, radiation only, radiation plus M at 250, and 500 mg/kg/day, and TOCO. After 14 days of treatment administered via oral gavage, rats were irradiated with a single dose of 2.0 Gy of gamma rays on the 15-th day and euthanized the next day. Rats cerebella were removed, fixed in 10% formalin saline, weighed and vernier caliper used to obtain cerebellar dimensions as follows: (i) maximum width, (ii) rostrocaudal dimension, and (iii) dorsoventral extent. Data were analyzed using ANOVA with post-test. Gamma radiation caused a statistically significant reduction of the relative weight of the rats' whole brain, relative weight of the cerebellum, the maximum width, rostrocaudal dimension, and dorsoventral extent of the cerebellum. However, pretreatment with M and TOCO significantly mitigated these effects. This study demonstrated that administration of M and TOCO before 2.0 Gy gamma irradiation reduced significantly the radiation induced gross morphometry changes in rats' cerebellum, suggesting that M may qualify for consideration as a medicinal radioprotector.

Keywords: cerebellum, irradiation, morphometry, rats, *Vernonia amygdalina*.

Introduction

Despite great advancements in medicine, cancer still causes great morbidity and mortality [1]. The treatment regime for cancer includes radiotherapy, which uses high-energy rays to damage cancer cells, thereby stopping them from further growth and cell division. Despite precautions by radiation oncologists, radiation side effects may still occur after radiation therapy and this is due largely to radiation's non-discrimination between cancer and normal tissue adjacent to the cancer tissue destined for elimination [2]. Normal host tissue may be protected from the toxic actions of radiation by radio-protectors, which may be beneficial during radiotherapeutic procedures [3, 4].

Radiation toxicity was reported to be mediated by the mechanism of free radical injury of tissues thereby causing oxidative damage [5–7]. Antioxidants reduce the toxicity associated with radiation damage by mopping up the free radicals. Antioxidant activities reported in some plants have been studied for their radio protective properties as part of prevention strategies. Some plants reported to have demonstrated radio-protection include *Terminalia chebula*, *Phyllanthus emblica*, and *Terminalia bellerica* commonly called

"Triphala" [8], *Amaranthus paniculatus* leaf extract [9], *Panax ginseng* [6], *Hibiscus sabdariffa* [4]. It is recognized that normal tissue protection in radiotherapy is as important as the destruction of the cancer cells. Since herbal drugs being either non-toxic or less toxic have been found to offer an alternative to synthetic compounds known to have cytotoxic effects, research has intensified on protection modalities [10]. The antioxidant activity of the leaf extract of *Vernonia amygdalina* ("bitter leaf") is based on the presence of flavonoids such as luteolin, luteolin-7-O- β -glucuronide and β -glucoside as described by Igile GO *et al.* [11] and flavonoids are known to possess antioxidant activity [12, 13]. Although the antioxidant activity of the leaf extract of *V. amygdalina* was reported to offer radio-protection in gastrointestinal and liver tissues [4, 14, 15], there is paucity of literature concerning its effect on neural tissue. The cerebellum was chosen as a model of nervous tissue for this study because of its importance. The cerebellum, a fist-sized, transversely fissured mass of central nervous system (CNS) tissue, is attached to the dorsum of the brain stem by three peduncles namely, brachium conjunctivum, brachium pontis, and the corpus restiformis/juxta-restiform [16]. The major functions of

the cerebellum include its influence on muscle tone, coordination of motor function, and maintenance of equilibrium, in addition to its regulation of both accurate saccadic and smooth eye movements [17–19].

The present study was therefore designed, to evaluate the effect of the leaf extract of *V. amygdalina*, on the interaction of gamma radiation and rats' cerebellum, using α -tocopherol (vitamin E) as a reference antioxidant compound and therefore address the question "can the leaf extract of *V. amygdalina* mitigate the effect of radiation injury on the gross morphometry of rat's cerebellum?".

Materials and Methods

Animals

Adult male Wistar rats, aged 12–16 weeks, whose initial body weight was 200–240 g, fed on standard commercial mouse cubes and water *ad libitum* were used for this study. They were housed in transparent plastic cages with wood shavings as bedding, at a fly-proof, freely ventilated and naturally illuminated animal room of the Department of Anatomy, University of Ibadan, Nigeria. The University of Ibadan Ethical Committee's approval was obtained and all procedures on animal handling conformed to the acceptable guidelines on the ethical use of animals in research [20].

Experimental design

The forty-two rats were randomly assigned into one of seven treatment groups of six animals per group and then allowed five days to acclimatize to animal room conditions before administration of intervention parameters. Animals received distilled water alone (Control), M at 250 or 500 mg/kg/day doses, radiation (R), radiation plus M, or radiation plus α -tocopherol (R + TOCO), as detailed in Table 1. All animals in both control and experimental groups were sacrificed on the 16th day of the experiments.

Table 1 – Grouping and treatment of experimental animals

Group	Treatment
Control	Un-irradiated control.
M 250	Un-irradiated rats treated with M 250 mg/kg \times 14 days.
M 500	Un-irradiated rats treated with M 500 mg/kg \times 14 days.
R	Rats treated with 2.0 Gy gamma rays on day 15.
R + M 250	Irradiated rats pretreated with M 250 mg/kg \times 14 days.
R + M 500	Irradiated rats pretreated with M 500 mg/kg \times 14 days.
R + TOCO	Irradiated rats pretreated with α -tocopherol 500 mg/kg \times 14 days.

M – methanolic extract of *V. amygdalina*; Gy – Gray unit (1 Gy = 100 rads); R – radiation; TOCO – α -tocopherol.

Plant material

Vernonia amygdalina Del., "bitter leaf", belongs to the *Asteraceae* family. The leaves were harvested at a farm in Ibadan, South-West Nigeria, in May 2006. Botanical identification and authentication was done at the Forest Research Institute of Nigeria, Ibadan, Nigeria,

where the voucher sample number FHI 107408, was deposited for reference. The leaves were rendered pest-free, after treatment at the Plant Quarantine Service of the Federal Department of Agriculture, Ibadan, Nigeria. Thereafter, 4.55 kg of the air-dried and pulverized leaves were packed into white polythene bags with the opened end sealed.

Chemicals

Chemicals and reagents were purchased from Sigma Chemical Co., USA. Methanol (MeOH) and other materials were of the highest analytical grade.

Extraction procedures, preparation and administration of methanolic extract of *V. amygdalina*

The leaves (4.55 kg) were extracted with 100% MeOH (3 \times 17 L) at room temperature over a period of three weeks. The cumulated solvent was evaporated with a Rotary Vacuum Evaporator (Eyela N.21, Tokyo) to afford a methanolic extract of *V. amygdalina* (M) weighing 700 g, a yield of 15.4%. From M, a stock solution of two different concentrations was prepared for this experiment, namely the 250 mg/kg and 500 mg/kg concentrations. 1 mL of the prepared stock solution containing 250 mg/kg/day or 500 mg/kg/day depending on the treatment group of the rat, was withdrawn with 2 mL hypothermic syringes (Becton Dickinson S.A., Spain), after stirring with a clean glass rod. M was administered orally to experimental animals using gavage daily for 14 days. The rats were weighed at the start of the experiment, on day of irradiation and on the day of sacrifice.

Preparation and administration of α -tocopherol (vitamin E)

Each soft gelatin capsule containing 100 mg of DL- α -tocopheryl acetate as 100 mg vitamin E acetate (G. A. Pharmaceuticals, Athens, Greece) was punctured with a new size 21G needle (Hypojet, Spain) attached to a new 1 mL hypothermic syringe (Becton Dickinson, La Port-de-Clair, France). The oily formulation of vitamin E was then neatly and completely aspirated out with the syringe. Each aspirate measured approximately 0.2 mL containing 100 mg of DL- α -tocopherol. The insulin syringe was thereafter attached to a clean intra-gastric gavage through which each rat was administered orally the measured dose of 500 mg/kg/daily for 14 days.

Irradiation procedures

Twenty-four hours after completing the administration of M and α -tocopherol, rats were given Ketamine hydrochloride injection (Rotex Medica, Trittau, Germany, batch 40092) at 10 mg/kg body weight and Diazepam injection (Roche, Switzerland) at 3 mg/kg body weight, both intraperitoneally. Rats were restrained by strapping in a prone position within the well-ventilated cardboard boxes using cotton strapping. A batch of four animals was whole body irradiated at a time with a single fraction of 2.0 Gy of gamma rays at a dose rate of 106.965 cGy/min., for 2.19 minutes, obtained from a Cobalt-60 source. The radiation was delivered by an AECL Theratron 780-C Teletherapy machine with

energy of 1.25 MeV, at source to surface distance of 72 cm, at a depth of 4 cm, and a field size of 18 cm by 18 cm, with an equivalent square area of 18 cm²; the percentage depth dose was 85.32%. There was no shielding of any part of the rat's body. Post irradiation the rats were placed in their cages and transferred to the animal room for recovery from anesthesia. The dosimetry and irradiation procedures were carried out at the Radiotherapy Department of the University College Hospital, Ibadan, Nigeria.

Sample collection

On the 16th day, all animals were weighed and thereafter, Ketamine anesthesia administered at 10 mg/kg to each rat intraperitoneally. Rats were positioned on the dissection table and the heads severed at the cervico-medullary junction for uniformity and then fixed in labeled bottles containing 10% formalin saline. The brain remained *in situ* for seven days before its removal from the skull, by careful dissection applying the method of Rowett HGQ [21]. The whole brain and cerebellum were weighed and then immersed in bottles containing fresh 10% formalin saline.

Gross morphometric studies

The gross body weight of rats was measured with a Swiss Microwa Balance 7740, at the beginning and at the end of the experiments, while whole brain and cerebellar weights were obtained on a Mettler analytic balance (Ohaus, Switzerland). From these data, the Organosomatic Index or relative weight for the whole brain and cerebellum was calculated by applying the method of Shoyinka SVO *et al.* [22].

Morphometry of gross cerebellar parameters

A pair of vernier calipers was used by two separate observers to obtain the following cerebellar dimensions: (i) maximum width, defined as the distance between the left and right paraflocculus in millimeters, (ii) rostro-caudal dimension or vermal length, defined as the distance between the apices of cerebellar lobules III and IX at the midline in millimeter, and (iii) dorsoventral extent defined as the extent between lobules I and IV at the midline in millimeter [17, 23–25]. These parameters are shown in Figures 1–4.

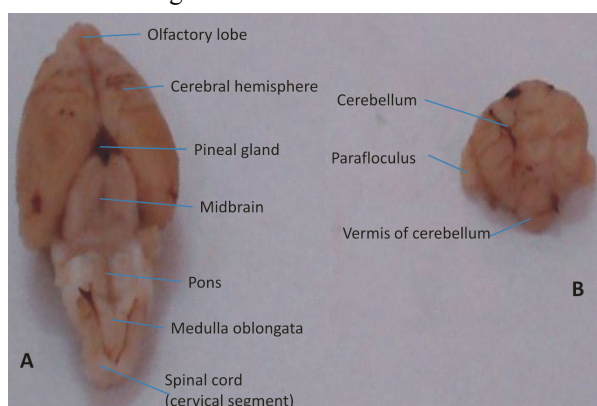


Figure 1 – Picture (A) shows a fully extracted whole brain of a representative rat used in the experiment, with the cerebellum dissected out of the same brain (B).

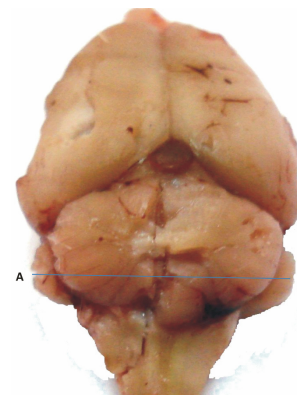


Figure 2 – Picture showing the dimension A–B, the maximum width of cerebellum (MWC), defined as the distance between the left and right paraflocculus in millimeters.

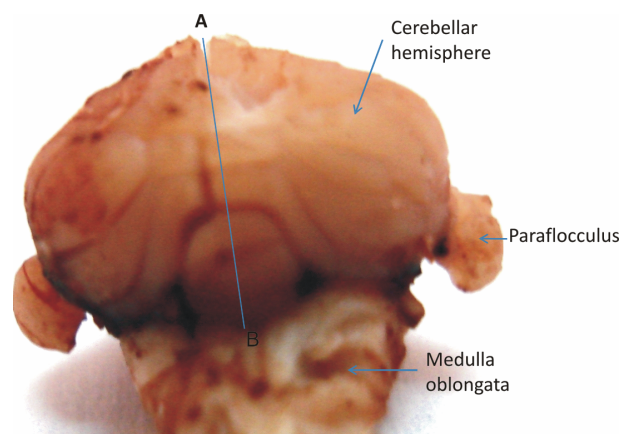


Figure 3 – Showing the dorsal aspect of the cerebellum and the dimension A–B, the rostrocaudal length of cerebellum (RCLC), defined as the distance between the apices of cerebella lobules III and IX at the midline in millimeter (the cerebella lobule III is not shown as it is in the anterior aspect).

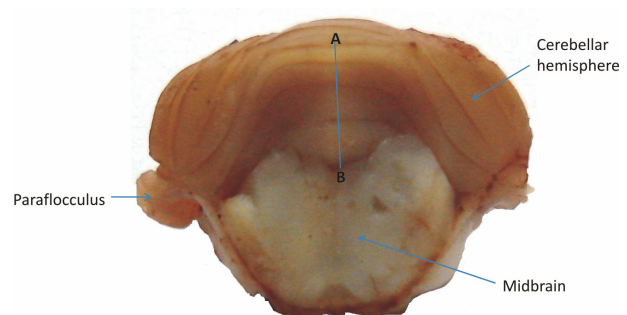


Figure 4 – Showing the anterior aspect of the detached cerebellum, and the dimension A–B, the dorsoventral extent of cerebellum (DVEC), defined as the extent between cerebella lobules I and IV at the midline in millimeter.

Three measurements for each parameter were taken by each observer using the same vernier calipers, and the average of the values taken.

Statistical analysis

The data were analyzed with One-way ANOVA, and Tukey's post-test was performed for multiple comparisons using GraphPad Prism version 4.0 (2003) for Windows GraphPad Software, San Diego, California,

USA (www.graphpad.com). Statistical significance was set at $p < 0.05$, for the null hypothesis being true by chance.

Results

This study evaluated the effect of gamma radiation on the nervous tissue in a mammalian model. The possible ameliorative effect of the antioxidant property of the leaf extract of *V. amygdalina* (M) on rat's brain was studied using α -tocopherol (TOCO), an established antioxidant known for its potency in fatty tissue as a reference compound.

General

Animals in the control, M 250, M 500, and R +

Table 2 – Effects of methanolic extract of *V. amygdalina* (M), γ -radiation and α -tocopherol on the weight, relative weights of the brain and cerebellum, maximum width of cerebellum (MWC), rostrocaudal dimension of cerebellum (RCDC), dorsoventral extent of cerebellum (DVEC) of rats on day 16 of the experiment

Group	Treatment	Weight of rats [g]	Relative weight of brain [%]	Relative weight of cerebellum [%]	MWC [mm]	RCDC [mm]	DVEC [mm]
I	Control	228 \pm 11.66	0.863 \pm 0.01	0.119 \pm 0.00	11.88 \pm 0.37	6.46 \pm 0.24	5.3 \pm 0.22
II	M 250	220 \pm 10.95	0.887 \pm 0.3	0.122 \pm 0.00	11.98 \pm 0.38	6.46 \pm 0.23	5.38 \pm 0.37
III	M 500	227 \pm 6.0	0.872 \pm 0.02	0.119 \pm 0.00	11.98 \pm 0.13	6.5 \pm 0.18	5.46 \pm 0.36
IV	R	218 \pm 14.70	0.850 \pm 0.04	0.101 \pm 0.00	9.74 \pm 0.26 ^{***}	5.26 \pm 0.23 ^{***}	4.36 \pm 0.33 ^{***}
V	R + M 250	220 \pm 5.48	0.894 \pm 0.02*	0.116 \pm 0.00*	9.8 \pm 0.5	5.38 \pm 0.24	4.66 \pm 0.33
VI	R + M 500	219 \pm 3.59	0.888 \pm 0.04*	0.118 \pm 0.01*	10.98 \pm 0.64	5.62 \pm 0.16**	4.98 \pm 0.13**
VII	R + TOCO	234 \pm 4.90	0.908 \pm 0.02	0.112 \pm 0.00	12.1 \pm 0.35	6.9 \pm 0.06**	6.64 \pm 0.14***

Values are mean \pm SD of five animals per treatment; *Significantly different from R ($p < 0.05$); ***Significantly different from control ($p < 0.01$); **Significantly different from R ($p < 0.01$); ***Significantly different from R ($p < 0.001$); R – 2.0 Gy gamma radiation treatment as a single dose on day 15 of experiment; Control – 1 mL distilled water (d.w)/oral daily for 14 days; M – 250 mg/kg/day/oral of M in 1 mL d.w daily for 14 days; M 500 – 500 mg/kg/day/oral of M in 1 mL d.w daily for 14 days; TOCO – 500 mg/kg/day/oral of α -tocopherol for 14 days.

Effects of treatments on the relative weight of rats' brain

In Table 2, the results of the effects of treatments on the relative weight of rats' brain are presented. It is noted that there were slight alterations in the means of the relative weight of whole brain of rats treated with both M 250 and M 500 only which were not significant ($p > 0.05$) when compared with the control animals. Gamma radiation (R) caused a non-significant 1.6% reduction as compared with the control. However, pretreatment with M 250 caused a significant ($p < 0.05$) increase from 0.85 \pm 0.05% in the R group to 0.894 \pm 0.02% in the R + M 250 group. Similarly, pretreatment with M 500 caused a significant ($p < 0.05$) increase by increasing the R-value to 0.888 \pm 0.4% in the R + M 500 group. In the R + TOCO group, pretreatment caused a non-significant increase ($p > 0.05$) when compared with the radiation treatment as shown in Table 2.

Effects of treatments on the relative weight of rats' cerebellum

The data obtained when the effects of treatments on the relative weight of rats cerebellum was studied are presented in Table 2. It shows that minimal non-significant ($p > 0.05$) alterations were observed in the means of the relative weight of the cerebellum of rats treated with both doses of M 250 and M 500. A non-significant reduction ($p > 0.05$) of the cerebellum size was induced by gamma radiation. However, pre-treatment with both

TOCO treatments groups did not record any mortality during the whole observation period. However, one each of the R and R + M 250 treatment groups died, either during irradiation procedure or did not recover from anesthesia.

Gross morphometry

Effects of treatments on rats' body weight

Table 2 shows the data obtained when the effects of treatments on rats body weight were studied. The minimal alterations in the means of the body weights of rats caused by radiation treatment, M 250, M 500, R + M 250, R + M 500, and TOCO were not significant ($p > 0.05$) when compared with the control animals.

doses of M caused a significant ($p < 0.05$) increase from 0.101 \pm 0.00% in the R only group to 0.116 \pm 0.00% in the R + M 250 group, and 0.118 \pm 0.01% in the R + M 500 group. The increase caused by pretreatment with TOCO (R + TOCO) was not significant ($p > 0.05$) when compared with the R group.

Effects of treatments on the maximum width of rats' cerebellum

The results of the effects of treatments on the maximum width of rats' cerebellum are presented in Table 2 and Figure 5. They show that gamma radiation caused an 18% reduction in the means of the maximum width of the cerebellum from 11.88 \pm 0.37 mm in the control, to 9.74 \pm 0.26 mm in the R group which was statistically significant ($p < 0.01$). The increases caused by pretreatment with M and TOCO were, however, not significant ($p > 0.05$).

Effects of treatments on the rostrocaudal dimension (vermal length) of rats' cerebellum

In Table 2 and Figure 6, the data obtained when the effects of treatments on the rostrocaudal dimension (vermal length) of rats' cerebellum was studied are presented. They both show that gamma radiation caused an 18.6% reduction in the means of the rostrocaudal dimension (vermal length) of the cerebellum from 6.46 \pm 0.24 mm in the control to 5.26 \pm 0.23 mm in the R group which was statistically significant ($p < 0.01$).

The table and figure also show that pretreatment with M caused an improvement in this parameter when compared with radiation only treatment. While the R + M 250 treatment caused an increase of 2.3% which was not significant ($p>0.05$), the R + M 500 caused a 6.8% increase which was significant ($p<0.01$). However, treatment with R + TOCO significantly ($p<0.01$) increased this parameter by about 18% compared in the cerebellum of rats in the radiation group.

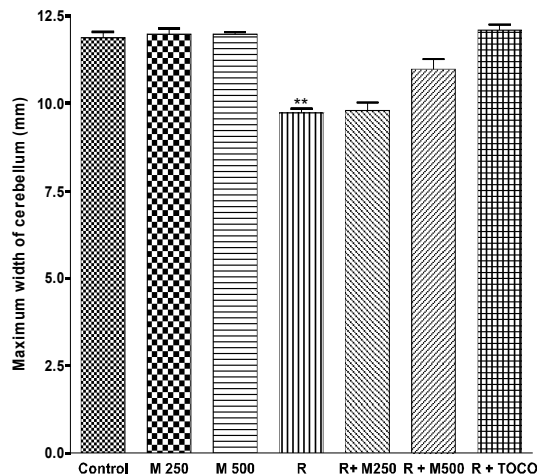


Figure 5 – Effect of M, α -tocopherol and γ -radiation on maximum width of cerebellum of the brain of Wistar rats. Values are mean \pm SD of five animals per treatment. **Significantly different from control group ($p<0.01$). Control – 1 mL distilled water (d.w)/oral daily for 14 days. M – methanolic extract of *V. amygdalina*. R – 2.0 Gy gamma radiation treatment as a single dose on day 15 of experiment. M 250, M 500 – 250, 500 mg/kg/day/oral of M in 1 mL d.w daily for 14 days. TOCO – 1 mL d.w + 500 mg/kg/day/oral of α -tocopherol for 14 days.

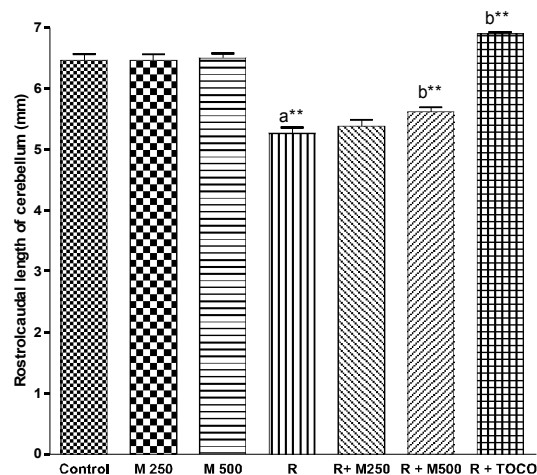


Figure 6 – Effect of M, α -tocopherol and γ -radiation on the rostrocaudal length of cerebellum of the brain of Wistar rats. Values are mean \pm SD of five animals per treatment. *Significantly different from control group ($p<0.01$). ***Significantly different from the radiation only group ($p<0.01$). Control – 1 mL distilled water (d.w)/oral daily for 14 days. M – methanolic extract of *V. amygdalina*. R – 2.0 Gy gamma radiation treatment as a single dose on day 15 of experiment. M 250, M 500 – 250, 500 mg/kg/day/oral of M in 1 mL d.w daily for 14 days. TOCO – 1 mL d.w + 500 mg/kg/day/oral of α -tocopherol for 14 days.**

Effects of treatments on the dorsoventral extent of rats' cerebellum

The results of the effects of treatments on the dorsoventral extent of rats' cerebellum are presented in Table 2 and Figure 7.

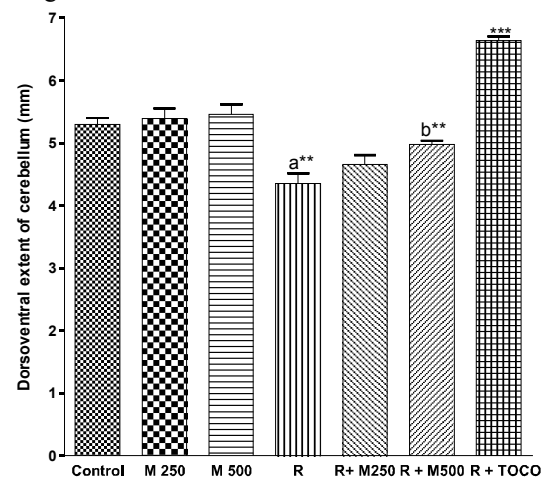


Figure 7 – Effect of M, α -tocopherol and γ -radiation on the dorsoventral extent of the cerebellum of brain of Wistar rats. Values are mean \pm SD of five animals per treatment. *Significantly different from control group ($p<0.01$). ***Significantly different from the radiation only group ($p<0.01$). ***Significantly different from the radiation only group ($p<0.001$). Control – 1 mL distilled water (d.w)/oral daily for 14 days. M – methanolic extract of *V. amygdalina*. R – 2.0 Gy gamma radiation treatment as a single dose on day 15 of experiment. M 250, M 500 – 250, 500 mg/kg/day/oral of M in 1 mL d.w daily for 14 days. TOCO – 1 mL d.w + 500 mg/kg/day/oral of α -tocopherol for 14 days.**

Both show that there were slight alterations in the means of the dorsoventral extent of the cerebellum of the rats. Gamma radiation treatment caused a 17.7% decrease in this parameter from 5.3 ± 0.22 mm in the control to 4.36 ± 0.33 mm in the R only group which was significant ($p<0.01$). However, pretreatment with both doses of M and TOCO caused an increase in the parameter when compared with R. While the R + M 250 treatment caused a non-significant ($p<0.05$) increase when compared with the radiation only group, the R + M 500 treatment elicited a significant ($p<0.01$) increase from 4.36 ± 0.33 mm in the radiation only group to 4.98 ± 0.13 mm (an increase of 14.2%). Similarly, there was a significant elevation of the means in the R + TOCO treatment ($p<0.001$) as shown in the table and figure.

Discussion

In this work, we were interested in addressing the question of whether the leaf extract of *V. amygdalina* can mitigate the gross morphometric changes induced by gamma irradiation in the cerebellum of male Wistar rats or not. Our observations showed that while the rats in the control, M 250, M 500, and R + TOCO treatment groups were not adversely affected by the interventions used during the experiments, one rat each in the R, R + M 250 treatment groups died either during the irradiation procedure or did not recover from anesthesia.

In conventional radiotherapy of head and neck cancer, treatment is given daily over three to seven weeks. Depending on the center, up to 50 Gy to 70 Gy may be given over six and one-half to seven weeks per adult patient [26]. The dose is, however, usually fractionated and given either twice or thrice daily or weekly in fractionated doses, which may range from 1.6 Gy to 2 Gy [27–29]. In this study, we chose 2 Gy as a single dose to mimic the higher fraction dose in human medical practice, though in an experimental setting.

The results of this study showed that the various treatments did not have any significant effect on the body weight of rats when compared with the control. However, gamma radiation given as a single dose was observed to have significantly caused a reduction in the relative weight of the cerebellum, maximum width, rostrocaudal dimension or vermal length, and the dorsoventral extent of the cerebella of the experimental rats. Also, pretreatment with the varying doses of M and α -tocopherol (TOCO) for 14 days before exposing the rats to radiation was observed to have protected the brain, especially the cerebellum from radiation injury by reducing the effect of gross morphological damage as measured by the amount of alterations in the parameters measured.

The non-significant reduction of the means of the body weights of the rats in the radiation group as compared with both the control and the rats pretreated with the two varying doses of M and TOCO groups may have been due to fact that the rats used in this study were euthanized within twenty-four hours post irradiation. It was reported that the onset of diarrhea tended to set in after twenty-four hours after whole body irradiation [30], but this was not recorded in this study. Significant weight reduction would then have been ascribed to body fluid loss due to diarrhea. This observation agrees with the report of Sugihara I *et al.* [24] and Amano T *et al.* [31] who both reported no significant weight changes in the irradiated animals, although these authors used different radiation doses ranging from 1 to 5 Gy. However, both authors irradiated their rats with X-rays in contrast to the gamma rays utilized in this present study, though both rays are ionizing radiations having short wavelengths and high frequencies.

The minimal but significant decreases in the mean of the relative weight of the cerebellum, the maximum width, the rostrocaudal dimension (vermal length) and the dorsoventral extent of rats cerebellum, caused by gamma radiation might have been due to the damage induced by the gamma rays at such a close source to surface distance without shielding, which could possibly have damaged some cerebella cells. It was reported that reducing the distance from the radiation beam increases the risk of exposure and that lead shields and shielding will significantly reduce the risk of exposure [32]. In this experiment, the source to surface there was as short as 72 cm and there was no shielding. Though low levels of radiation may kill or damage insignificant numbers of cells in the body, which will be replaced through normal growth cycles, higher radiation dosages kill large portions of cells in the body, in either a localized or

generalized pattern. If enough body cells are damaged by an acute radiation dose, immediate organ and tissue damage can occur [33]. Radiation has been reported to induce cell death and reduce the size of the brain if given in excess of acute radiation dose, which is about 10 rads (0.1 Gy), in this study, the rats were irradiated with 2.0 Gy gamma radiations [34–36]. Also, since DNA is damaged by radiation injury, the biological effect of the irradiation depends on two distinct factors: the greater efficacy of the DNA repair at low dose rates, and the probability of damaged cells to be eliminated by death. In this study, the rats were sacrificed within twenty-four hours after the radiation damage, thus not allowing much time for repairs. The alterations observed might therefore, be a cumulative effect of these cell deaths.

The observation in this study of a significant reduction by gamma radiation of the maximum width of the cerebellum by about 18%, the rostrocaudal dimension (vermal length) by 18%, and the dorsoventral extent of rats cerebellum by 17.7% is much less than the values recorded by Sugihara I *et al.* [24], whose team observed decreases in the width of the rats' cerebella by as much as 26.5 to 29% in the irradiated rats. However, Sugihara and his colleagues had irradiated the rats with 5 Gy in comparison to the 2 Gy used by the authors in this study.

The effect of M and α -tocopherol pretreatment before irradiation were observable in the statistically significant increases of the rostrocaudal dimension (vermal length) and dorsoventral extent of the cerebellum when compared with irradiated rats. While the M doses increased the rostrocaudal dimension (vermal length) by 2.3–6.8%, it increased the dorsoventral extent of the cerebellum by 6.9–14.2%. The better effectiveness of α -tocopherol pretreatment could be observed as it increased the rostrocaudal dimension (vermal length) by 19% while the dorsoventral extent of the cerebellum was increased by 52%.

These results point to the capacity of M and α -tocopherol to mitigate the effect of gamma radiation damage in the irradiated cerebellum of Wistar rat. This capacity might be due to the antioxidant activity already demonstrated in the M [4, 11, 14, 15], and the well-known activity of α -tocopherol as a major lipid soluble antioxidant and radical scavenger in biological systems [37–39]. Since the mode of radiation pathology has been reported to be via free radical damage, both M and α -tocopherol might have mitigated the effect by neutralizing the released free radicals via their antioxidant activity. Obviously, the antioxidant compounds in M, namely flavonoids like luteolin, luteolin-7-O- β -glucuronoside and 7-O- β -glucoside [11] would likely be the active compounds in this case. Flavonoids are known antioxidants [13, 40, 41] and the activity of flavonoids in the brain, especially the fact that flavonoids are able to traverse the blood-brain barrier, had been previously demonstrated [12, 42].

The impact of radiotherapy on the human cranial topography includes its effect on the lymph nodes, the skin of the head and neck damage to eye, since relatively high doses of radiation can damage the conjunctiva,

iris, sclera, blood vessels of the retina and the lens. The lens is a particularly critical site since it may sustain irreversible damage from a relatively low dose of radiation and subsequently formation of cataract [32]. Cranial radiotherapy could also affect brain tissue as previously observed by Schmitz C *et al.* [43] who reported neuronal loss in rat cerebellum, Malomo AO *et al.* [30] who reported neuronal shrinkages, and Belka C *et al.* [44] who reported demyelination, and degenerative glial reactions. As observed in this study, radiation also caused morphological alterations in the parameters measured.

The medical implication of the radiation effects observed in the cerebellar structures in this study is its potential to affect the functional integrity of the organ, leading to abnormalities like loss of muscular coordination, cerebellar ataxia, asthenia, hypotonia, dysmetria, inability to perform rapid alternating movements (adiadochokinesia), dysarthria, intention tremors, nystagmus and decomposition of movements, amongst others [18, 19]. This list of possible clinical effects resulting from cerebellar injury irrespective of the etiology justifies the need for a continuous search for preventive measures. As has been demonstrated in this study, this radiation damage may be ameliorated by preventing or minimizing the associated side effects of irradiation therapy, with M and α -tocopherol.

Taken together, the results from this study have shown that 2.0 Gy of gamma radiation from Cobalt-60 caused damage to the gross structure of the cerebellum of Wistar rats. Pretreatment with 250 mg/kg and 500 mg/kg body weight of M and also with 500 mg/kg body weight of TOCO for fourteen days before gamma irradiation mitigated this damage. This mitigation was probably mediated by the antioxidant capacity of the extract in neutralizing the oxidative damage of radiation injury. Overall, the leaf extract of *V. amygdalina* may qualify as a medicinal radioprotector and needs be considered for further scientific evaluation in other parts of the nervous system.

Conclusions

2.0 Gy gamma radiation caused a significant alteration in the gross parameters of rats' cerebellum, namely, the relative weight of the rats' whole brain, relative weight of the cerebellum, the maximum width, rostro-caudal dimension, and the dorsoventral extent. Pretreatment with M and TOCO significantly mitigated these alterations. This study demonstrated the potential of M as a medicinal radioprotector.

Acknowledgements

The authors gratefully acknowledge the kind permission granted by Professor O. B. Campbell, Head, Department of Radiotherapy, University College Hospital, Ibadan, Nigeria, for use of radiation and dosimetry facilities. We also appreciate Mrs B. O. Akinlade, Mrs A. O. Ekisola and Pastor A. M. Akinwande, all of the same department, for technical help in the irradiation procedures.

References

- [1] Jemal A, Siegel R, Ward E, Hao Y, Xu J, Murray T, Thun MJ, *Cancer statistics, 2008*, CA Cancer J Clin, 2008, 58(2):71–96.
- [2] Nieder C, Andratschke A, Astner ST, *Experimental concepts for toxicity prevention and tissue restoration after central nervous system irradiation*, Radiat Oncol, 2007, 2:23; <http://www.ro-journal.com/content/2/1/23>.
- [3] Jagetia GC, Venkatesh P, Baliga MS, *Fruit extract of Aegle marmelos protects mice against radiation-induced lethality*, Integr Cancer Ther, 2004, 3(4):323–332.
- [4] Adaramoye O, Ogungbenro B, Anyaegbu O, Fafunso M, *Protective effects of extracts of Vernonia amygdalina, Hibiscus sabdariffa and vitamin C against radiation-induced liver damage in rats*, J Radiat Res (Tokyo), 2008, 49(2):123–131.
- [5] Aruoma OI, *Free radicals, oxidative stress, and antioxidants in human health and disease*, JAOCS, 1998, 75(2):199–208.
- [6] Lee HJ, Kim SR, Kim JC, Kang CM, Lee YS, Jo SK, Kim TH, Jang JS, Nah SY, Kim SH, *In vivo radioprotective effect of Panax ginseng C.A. Meyer and identification of active ginsenosides*, Phytother Res, 2006, 20(5):392–395.
- [7] Farombi EO, Ugwuezunmba MC, Ezenwadu TT, Oyeyemi MO, Ekor M, *Tetracycline-induced reproductive toxicity in male rats: effects of vitamin C and N-acetylcysteine*, Exp Toxicol Pathol, 2008, 60(1):77–85.
- [8] Naik GH, Priyadarsini KI, Bhagirathi RG, Mishra B, Mishra KP, Banavalikar MM, Mohan M, *In vitro antioxidant studies and free radical reactions of Triphala, an ayurvedic formulation and its constituents*, Phytother Res, 2005, 19(7):582–586.
- [9] Maharwal J, Samarth RM, Saini MR, *Antioxidant effect of Rajgira leaf extract in liver of Swiss albino mice after exposure to different doses of gamma radiation*, Phytother Res, 2005, 19(8):717–720.
- [10] Jagetia GC, Baliga MS, Malagi KJ, Sethukumar Kamath MS, *The evaluation of the radioprotective effect of Triphala (an ayurvedic rejuvenating drug) in the mice exposed to gamma-radiation*, Phytomedicine, 2002, 9(2):99–108.
- [11] Igile GO, Oleszek W, Jurzysta M, Burda S, Fafunso M, Fasanmade AA, *Flavonoids from Vernonia amygdalina and their antioxidant activities*, J Agric Food Chem, 1994, 42(11):2445–2448.
- [12] Markham KR, Bloor SJ, *Analysis and identification of flavonoids in practice*. In: Rice-Evans CA, Packer L (eds), *Flavonoids in health and disease*, Marcel Dekker Inc., New York, 1998, 1–32.
- [13] Prabhakar KR, Veeresh VP, Vipin K, Sudheer M, Priyadarsini KI, Satish RBSS, Unnikrishnan MK, *Bioactivity-guided fractionation of Coronopus didymus: a free radical scavenging perspective*, Phytomedicine, 2006, 13(8):591–595.
- [14] Iwalewa EO, Adewunmi CO, Omisore NO, Adebajani OA, Azike CK, Adigun AO, Adesina OA, Olowoyo OG, *Pro- and antioxidant effects and cytoprotective potentials on nine edible vegetables in southwest Nigeria*, J Med Food, 2005, 8(4):539–544.
- [15] Iwalokun BA, Efede BU, Alabi-Sofunde JA, Oduala T, Magbagbeola OA, Akinwande AI, *Hepatoprotective and antioxidant activities of Vernonia amygdalina on acetaminophen-induced hepatic damage in mice*, J Med Food, 2006, 9(4):534–530.
- [16] Sinnatamby CS, *Last's anatomy: regional and applied*, 11th edition, Churchill Livingstone Elsevier, Edinburgh, 2006, 1–3.
- [17] West JR, *The cerebellum*. In: Conn PM (ed), *Neuroscience in medicine*, J.B. Lippincott, Philadelphia, 1995, 213–225.
- [18] Afifi AK, Bergman RA, *Functional neuroanatomy: text and atlas*, 2nd edition, McGraw-Hill, New York, 2005, 201–222.
- [19] Singh I, *Textbook of anatomy with colour atlas*, 4th edition, Jaypee Publishers, New Delhi, 2007, 994–1003.
- [20] Clarke JD, *The guide for the care and use of laboratory animals report*, National Academy of Science Revision Committee, Washington, D.C., 1996.
- [21] Rowett HGQ, *Guide to dissection*, John Murray, London, 1970, 161–168.

- [22] Shoyinka SVO, Obidike IR, Ndunneko CO, *Effect of iodine supplementation on thyroid and testicular morphology and function in euthyroid rats*, Proceedings of the 43rd Annual Conference of the Nigeria Veterinary Medical Association, 2006, 80–86.
- [23] Peeters RR, Verhoye M, Vos BP, Van Dyck D, Van Der Linden A, De Schutter E, *A patchy horizontal organization of the somatosensory activation of the rat cerebellum demonstrated by functional MRI*, Eur J Neurosci, 1999, 11(8):2720–2730.
- [24] Sugihara I, Bailly Y, Mariani J, *Olivocerebellar climbing fibers in the granulo-prival cerebellum: morphological study of individual axonal projections in the X-irradiated rat*, J Neurosci, 2000, 20(10):3745–3760.
- [25] Paxinos G, Watson C, *The rat brain in stereotaxic coordinates*, 5th edition, Elsevier Academic Press, Amsterdam, 2005, 1109–1126.
- [26] Saunders MI, *Head and neck cancer: altered fractionation schedules*, The Oncologist, 1999, 4(1):11–16.
- [27] Peracchia G, Salti C, *Radiotherapy with thrice-a-day fractionation in a short overall time: clinical experiences*, Int J Radiat Oncol Biol Phys, 1981, 7(1):99–104.
- [28] Wang CC, Suit HD, Blitzer PH, *Twice-a-day radiation therapy for supraglottic carcinoma*, Int J Radiat Oncol Biol Phys, 1986, 12(1):3–7.
- [29] Wang CC, *Local control of oropharyngeal carcinoma after two accelerated hyperfractionation radiation therapy schemes*, Int J Radiat Oncol Biol Phys, 1988, 14(6):1143–1146.
- [30] Malomo AO, Owoeye O, Elumelu TN, Akang EEU, Adenipekun A, Campbell OB, Shokunbi MT, *The effect of dexamethasone, metronidazole, and ascorbic acid on the morphological changes induced by gamma rays on the spinal cord of Wistar rats*, Afr J Med Med Sci, 2005, 34(2):161–165.
- [31] Amano T, Inamura T, Wu CM, Kura S, Nakamizo A, Inoha S, Miyazono M, Ikezaki K, *Effects of single low dose irradiation on subventricular zone cells in juvenile rat brain*, Neurol Res, 2002, 24(8):809–816.
- [32] Raza SMS, *Radiation exposure in the cath lab – safety and precautions*, 2006; <http://priory.com/med/radiation.htm>.
- [33] Graybeal L, *What are the effects of an acute radiation dose?*, eHow, http://www.ehow.com/how-does_5498108_effects-acute-radiation-dose.html, 2010.
- [34] Ferrer I, *Cell death in normal developing brain, and following ionizing radiation, methyl-azoxymethanol acetate, and hypoxia-ischaemia in the rat*, Neuropathol Appl Neurobiol, 1996, 22(6):489–494.
- [35] Hyodo-Taguchi Y, Fushiki S, Kinoshita C, Ishikawa I, Hirobe T, *Effects of low-dose X-irradiation on the development of the mouse cerebellar cortex*, J Radiat Res (Tokyo), 1998, 39(1):11–19.
- [36] Jefferson Lab, *Radiological fundamentals*, http://www.lab.org/div_dept/train/rad_guide/effects.html#accute, 2010.
- [37] Bender DA, Mayes PA, *Vitamins and minerals*. In: Murray RK, Granner DK, Mayes PA, Rodwell VW (eds), *Harper's illustrated biochemistry*, 26th edition, Lange Medical Books / McGraw-Hill, New York, 2003, 481–497.
- [38] Harvey HB, *Diet and exercise*. In: Dale DC, Federman DD, Antman K, Atkinson JP, Cassel CK, Feldman M, Gibbons RJ, Hanes RB, Henrich WI, Lebowitz MJ, Levison W, Lorianx DL, Ruddy S, Wolinsky JS (eds), *ACP Medicine*, vol. 1, www.acpmedicine.com, WebMD, Inc., 2005, 19–33.
- [39] Cerecetto H, López GV, *Antioxidants derived from vitamin E: an overview*, Mini Reviews in Medicinal Chemistry, 2007, 7(3):315–338.
- [40] Marston A, Hostettman K, *Separation and quantification of flavonoids*. In: Andersen OM, Markham KR (eds), *Flavonoids: chemistry, biochemistry and applications*, Taylor and Francis, Boca Raton, 2006, 1–34.
- [41] Clifford M, Brown JE, *Dietary flavonoids and health-broadening the perspective*. In: Andersen OM, Markham KR (eds), *Flavonoids: chemistry, biochemistry and applications*, Taylor and Francis, Boca Raton, 2006, 319–370.
- [42] Youdim KA, Dobbie MS, Kuhnle G, Proteggente AR, Abbott NJ, Rice-Evans C, *Interaction between flavonoids and the blood-brain barrier: in vitro studies*, J Neurochem, 2003, 85(1):180–192.
- [43] Schmitz C, Born M, Dolezel P, Rutten BP, Saint-Georges L, Hof PR, Korr H, *Prenatal protracted irradiation at very low dose rate induces severe neuronal loss in rat hippocampus and cerebellum*, Neuroscience, 2005, 130(4):935–948.
- [44] Belka C, Budach W, Kortmann RD, Bamberg M, *Radiation induced CNS toxicity – molecular and cellular mechanisms*, Br J Cancer, 2001, 85(9):1233–1239.

Corresponding author

Olatunde Owoeye, Lecturer, MB, BS, MSc, PhD, Department of Anatomy, Faculty of Basic Medical Sciences, College of Medicine, University of Ibadan, P.O. Box 23722, Mapo Post Office, Ibadan, Nigeria; Phone +234–8033239973, Fax +234–2–8103043, e-mail: oowoeye2001@yahoo.com, o.owoeye@mail.ui.edu.ng

Received: May 7th, 2010

Accepted: January 5th, 2011