

ORIGINAL PAPER

The vasculogenesis – a possible histological identification criterion for the molar pregnancy

LILIANA NOVAC¹⁾, MIHAELA NICULESCU²⁾, MARIA MAGDALENA MANOLEA³⁾,
D. ILIESCU³⁾, CLAUDIA VALENTINA GEORGESCU⁴⁾, AL. COMĂNESCU¹⁾,
N. CERNEA¹⁾, ANDREEA ENACHE⁵⁾

¹⁾Department of Obstetrics and Gynecology

²⁾Department of Anatomy

³⁾Department of Obstetrics and Gynecology,
Faculty of Midwifery and Nursing

University of Medicine and Pharmacy of Craiova

⁴⁾Laboratory of Anatomical Pathology and Cytology,
Emergency County Hospital, Craiova

⁵⁾Physician, PhD candidate in Obstetrics and Gynecology,
University of Medicine and Pharmacy of Craiova

Abstract

The benign hydatidiform mole (partial and complete) practically represents an associated pathology of the first trimester miscarriage; it is considered that it represents the initial pathology, which, evolutionally, may be followed by the appearance of invasive mole and choriocarcinoma. The authors have studied clinical and cytogenetical 61 cases selected according to some specific criteria for the suspicion of molar pregnancy or hydropic abortion and 21 cases that represented the control group made by patients with normal pregnancy which have been presented for legal abortion. In all cases has been made a histological exam and has been studied the vasculogenesis by immunohistochemistry labeling for CD31 and CD34. Following-up the results has been established a number of histological and immunohistochemical criteria for the evaluation and differentiation of various molar pregnancy types and the vasculogenesis characteristics. The most important differential diagnosis criteria between partial and complete mole is represented by the trophoblast disposition and the atypical trophoblast in the complete mole.

Keywords: molar pregnancy, vasculogenesis, differential diagnosis.

Introduction

The hydatidiform mole represents a pathology associated with the first trimester miscarriage. It represents a phenotype with two different entities that have different histopathologic and cytogenetic criteria: complete hydatidiform mole and partial hydatidiform mole.

According to *WHO* recommendations, beginning with 1983, the benign hydatidiform mole (partial and complete) has been included in the larger category of the gestational trophoblastic disease (GTD) because it has been considered that it represents the initial pathology which, evolutionally, may be followed by the appearance of invasive mole and choriocarcinoma [1]. Our cytogenetic, epidemiologic, histologic understandings and also the clinical management of the hydatidiform mole have been considerably developed in the last four decades.

The hydatidiform mole appears during the fertilization and there are multiple theories regarding its appearance. In fact, the pathology consists in an abnormal development of the placenta, by the cystic degeneration of the chorial villous stroma with the hydropic transformation of some or all villousities and the trophoblastic hyperplasia [2, 3].

The clinician wishes a certainty diagnosis both for

establishing the prognosis and also for the management and the diagnosis of the case; the use of the molar pregnancy and the molar pregnancy suspicion terms are no longer enough. Unfortunately, the investigations begin when the infertility and the repeated miscarriage show up, and when the desire for having a baby of the couple is not accomplished.

Materials and Methods

We included in the present study the patients with a first trimester pregnancy, which presented in the 1st Obstetrics–Gynecology Clinic of “Filantropia” Hospital and the Emergency County Hospital from Craiova, between 2007–2009. The study was approved by the Ethics Committee of the University of Medicine and Pharmacy of Craiova. The cases that answered the next clinical and echographic criteria had been studied: ultrasound diagnosis of an empty gestation sac; stopping development pregnancy; first trimester bleeding pregnancy; ultrasound suspicion of molar pregnancy; cooperating patients regarding the further observation.

The final group was made by 72 cases of which 46 cases were diagnosed hydatidiform mole after a complete investigation, all of the cases being in the first trimester of pregnancy and 26 non-molar hydropic abortion.

In order to accomplish a complete study of the changes that appears in the molar pregnancy, we took in consideration also a control group made of 32 women with requested abortion, from whom the informed consent was obtained, showing normal evolution of first trimester pregnancy in clinical and ultrasound assessment.

For this purpose, the comparative study of the cases was made by dividing the patients in four groups: first group – of normal pregnancy ended by requested abortion; the second group – of spontaneous abortion with hydropic degeneration; the third – molar abortion in complete mole and the fourth group – with molar abortion in partial mole.

The exploration methods used were:

The anamnesis and clinical exam

We looked for: last menstruation period, the dimensions of the uterus in relation to the amenorrhea, the metrorrhagia, the subjective symptoms specific for the first trimester pregnancy (nausea, vomiting), the evaluation of the annexes (presence or absence of the luteal cysts).

The ultrasound examination

It has been made transabdominal and transvaginal echographic exam in all the cases. The ultrasound exam searched for specific echographic images for hydatidiform mole; the dominant image was an empty gestation sac or stopping development pregnancy. In three cases were seen ovarian luteal cysts bilateral, but in small dimensions.

The uterine curettage with histopathological and immunohistochemical exam

There has been made uterine curettage in all the cases after a complete preoperative evaluation and the obtained product was sent for histopathological and immunohistochemical evaluation. The immunohistochemical analysis was used to realize a correlation with the classic histological diagnosis; in the last period there is a tendency for the evaluation of each histological criterion in the immunohistochemical light. For this purpose, we used the HE stain for the histological analysis and for the immunohistochemical analysis we used the mouse anti-human CD34 monoclonal antibody and the mouse anti-human CD31 monoclonal antibody.

In the cases with recurrent miscarriage, we made also a cytogenetic exam with the karyotype.

The HCG determination

The molar pregnancy is associated with a high level over 100 000 mIU/mL in serum and over 1 000 000/24 hours in urine. We used in the present study only the serum β -HCG determination. We noticed that the values are much higher in the complete mole comparing to the partial mole. According to the protocol, we determined HCG weekly until the values became normal for three consecutive examinations.

The genetic analysis

We obtained the genetic analysis of the curettage product in 21 cases.

Results

The vaginal bleeding was found in 18 cases (39.13%), the uterus growing volume was not present and did not cause difficulties regarding the chronological gestational age; nine patients (19.56%) were presented nausea vomiting pregnancy in the first trimester that needed hospitalization for hydroelectrolytic rehabilitation. All the cases being in the first trimester of the pregnancy, we have booked up neither pathology of the thyroid gland nor cases of pre-eclampsia. Even if among the risk factors is mentioned the age over 35–40 years, in our cases the patients were aged between 28 and 36 years, with an average of 31.5 ± 2.69 years (medium \pm standard deviation).

In the group containing molar pregnancies, 10 of the cases were at the first pregnancy, 12 had recurrent miscarriage in the medical history and four patients had already one or two children; in eight cases without clinical semiology, the diagnosis was a histopathological one.

Regarding that the complete hydatidiform mole has a high risk (15–20%) for the association with the invasive mole or choriocarcinoma, beside the 5% risk in the partial mole, we considered necessary to establish a number of histological criteria in order to differentiate the complete and the partial hydatidiform mole, as a corollary of the subsequent monitoring, alongside with the β -HCG, cytogenetic criteria and clinic observation.

Nevertheless, the differential diagnosis between the two types of mole is a difficult histological one; a careful analysis of the described histological changes may suggest the histological diagnosis of the mole type, that we checked by the cytogenetic analysis in a part of the cases. We took in account the fact that the studies that have been made till today demonstrated that in the majority of the complete hydatidiform mole cases the karyotype 46XX is dominant and in the majority of the partial hydatidiform mole cases are found the diandric type of triploidy [4–6].

According to the clinic, histological and cytogenetic data we established a number of correlations regarding the clinic and cytogenetic aspect (Table 1), the entirety histological changes (Table 2), the histological changes of the trophoblast (Table 3) that we found in the lot with gestational trophoblastic disease and in the cases with hydropic abortion.

The uterine curettage made in 16 of the cases suggested a macroscopic aspect of molar pregnancy. Both in these cases and also in other 56 cases, the curettage product sent for histopatological exam noticed the presence of a hydropic degeneration (Figures 1 and 2) – that allowed the bordering in the non-molar hydropic abortion category, or in the category of an hydatidiform mole (Figure 3).

The histological study made from the products of the four groups that we studied, on series sections usually HE stained, globally and detail examined, distinguish in the first group – the normal pregnancy bitrophoblastic mesenchymal villousities with multiple vasculogenesis areas (Figure 3–I, A and B). In the sections of the second group, of non-molar hydropic abortions, it can be distinguished mesenchymal villousities with the

necrosis of the syncytiotrophoblast and the atrophy of the cytotrophoblast, pronounced hydropic dystrophy, absent vasculogenesis (Figure 3–II, A and B). In the sections of the third group (partial mole) on the usual stain can be distinguished mesenchymal villousities with polar trophoblastic proliferation, rare vessels in the villous stroma (Figure 3–III, A and B). In the fourth group (complete mole), sections can be distinguished mesenchymal villousities with intravillous cisterns, circumferential proliferation of the trophoblast with atypias, poorly differentiated vasculogenesis with collapsed stromal vessels (Figure 3–IV, A and B).

During the immunohistochemical study, we noticed that the CD34 immunolabeled demonstrate the abnormal development of the vasculosyncytial membrane in anembryonic pregnancy. CD34 is light positive in partial and complete molar pregnancy (Figures 3–III

and 3–IV, D), is absent in the spontaneous abortion with hydropic degeneration (Figure 3–II, D), comparing with the normal pregnancy ended by requested abortion where is highly positive (Figure 3–I, D). Because the vasculogenesis is directly modulated by the embryonic signal, the conclusion is that the embryonic structure was in the beginning.

Through the CD31 immunolabeling we found that the number of the mature blood vessels with distinguishing lumen was zero in the very early pregnancy (anembryonic pregnancy) but also in the spontaneous abortion with hydropic degeneration (Figure 3–II, C), in the molar abortion in partial mole and in the molar abortion in complete mole (Figure 3–III and 3–IV, C), comparing to the normal pregnancy (Figure 3–I, C), where is highly positive.

Table 1 – Comparative clinic and cytogenetic aspects between gestational trophoblastic disease and hydropic abortion

Criteria	Gestational trophoblastic disease		Hydropic abortion (26 cases)
	Complete mole (17 cases)	Partial mole (29 cases)	
Gestational age	8–13 weeks	8–14 weeks	6–14 weeks
Uterus dimensions	Normal for gestational age	Normal for gestational age	Often small for gestational age – 15 cases, 57.69%
Placental tissue quantity	High – 12 cases, 70.59% Normal – 5 cases, 29.42%	High – 16 cases, 55.18% Normal – 11 cases, 37.94% Low – 2 cases, 6.90%	High – 4 cases, 15.39% Normal – 5 cases, 19.23% Low – 17 cases, 65.39%
HCG level	High – 17 cases, 100%	High – 27 cases, 93.11% Normal – 2 cases, 6.90%	High – 3 cases, 11.54% Normal – 12 cases, 46.16% Low – 11 cases, 42.31%

Table 2 – Comparative histological aspects between gestational trophoblastic disease and hydropic abortion

Criteria	Gestational trophoblastic disease		Hydropic abortion (26 cases)
	Complete mole (17 cases)	Partial mole (29 cases)	
Hydropic villousities	Generalized – 14 cases, 82.32% Sclerosed – 3 cases, 17.68%	Partial – 29 cases, 100%	Generalized – 26 cases, 100%
Villousities' shape	Big, round – 17 cases, 100%	Irregular – 29 cases, 100%	Small, round – 26 cases, 100%
Intravillous cisterns	Present – 11 cases, 64.71% Absent – 6 cases, 35.29%	Present – 18 cases, 62.07% Absent – 11 cases, 37.93%	Usually absent – 19 cases, 73.08%
Vascular changes	Collapsed, with cellular detritus – 17 cases, 100%	Collapsed, rare – 29 cases, 100%	Absent – 26 cases, 100%
Implantation site	Exaggerated – 17 cases, 100%	Normal – 13 cases, 44.83% Exaggerated – 16 cases, 55.18%	Normal – 26 cases, 100%

Table 3 – Comparative histological aspects of the trophoblast between gestational trophoblastic disease and hydropic abortion

Criteria	Gestational trophoblastic disease		Hydropic abortion (26 cases)
	Complete mole (17 cases)	Partial mole (29 cases)	
Trophoblastic inclusion	Present – 9 cases, 52.94% Absent – 8 cases, 47.06%	Present – 22 cases, 75.86% Absent – 7 cases, 24.14%	Absent – 26 cases, 100%
Trophoblastic distribution	Circumferential – 14 cases, 82.35% Multifocal – 3 cases, 17.65%	Circumferential – 21 cases, 72.41% Zonal – 8 cases, 27.59%	Absent – 23 cases, 88.46% Polar – 3 cases, 11.54%
Trophoblastic proliferation	Pronounced – 17 cases, 100%	Focal – 21 cases, 72.41% Minimal – 8 cases, 27.59%	Limited to the mesenchymal villousities – 26 cases
Atypia	Present – 17 cases, 100%	Minimal – 11 cases, 37.93% Absent – 18 cases, 62.07%	Absent – 26 cases

Figure 1 – Monotrophoblastic villousities with strong edemas dystrophy, trophoblast with hemorrhagic necrosis (HE stain, ×40).

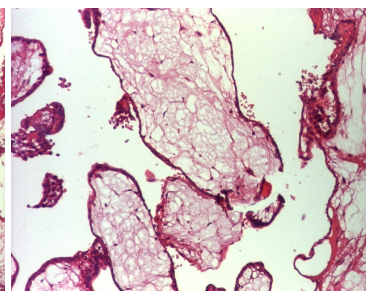
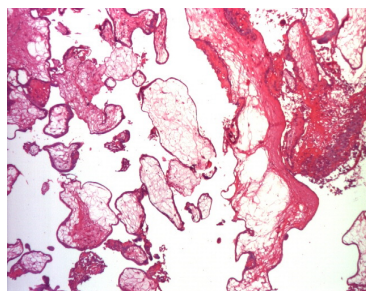


Figure 2 – Detail, hydropic dystrophy (HE stain, ×100).

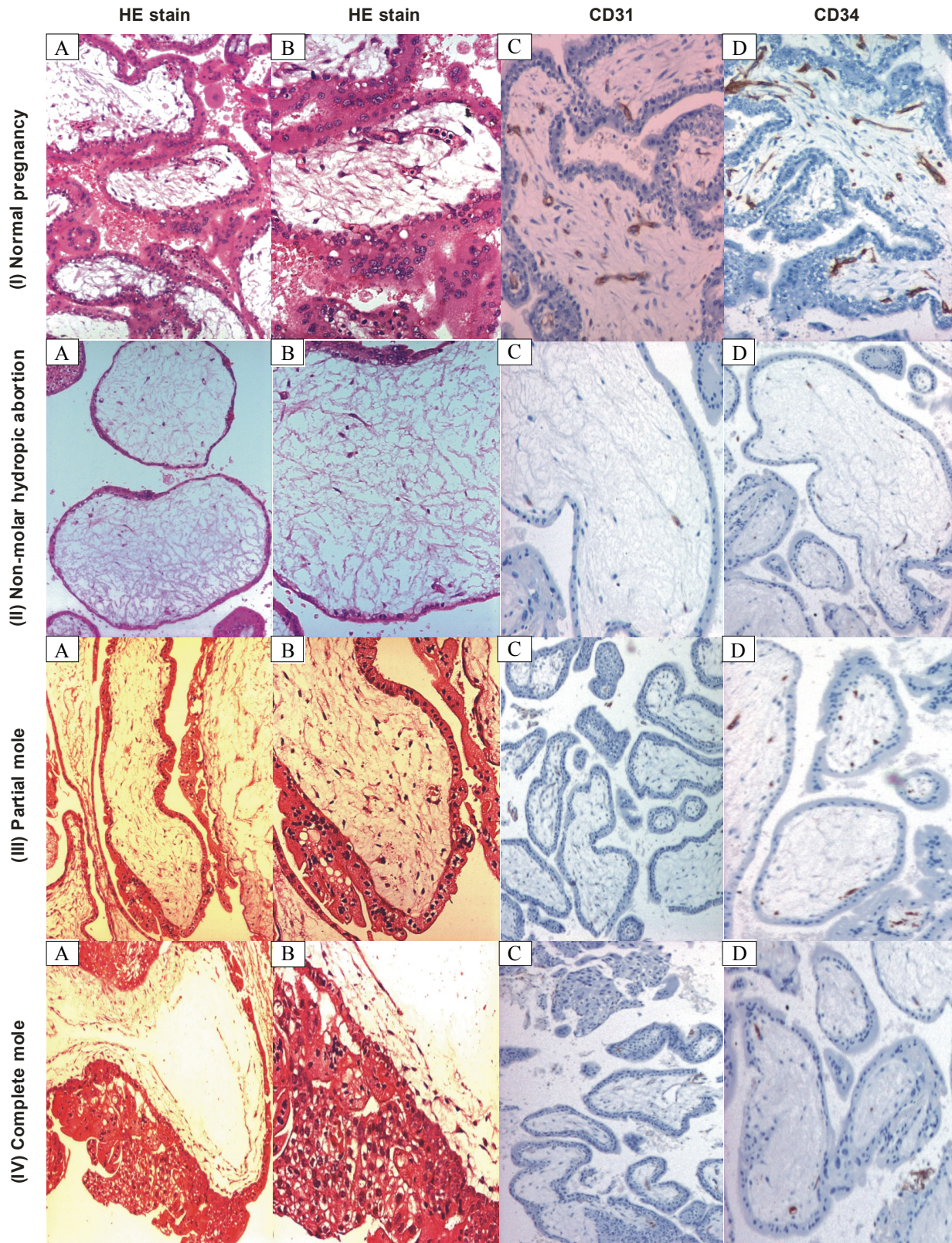


Figure 3 – Histological and immunohistochemical comparative aspects in normal pregnancy (I), hydronic abortion (II), partial mole (III) and complete mole (IV): I – (A and B) Mesenchymal villousities with differentiated vasculogenesis, $\times 100$ and $\times 200$; I – (C) Differentiated blood vessels, $\times 100$; I – (D) Highly-positive label, $\times 100$; II – (A and B) Mesenchymal villousities with hydronic dystrophy, absent vasculogenesis, $\times 100$ and $\times 200$; II – (C) Negative label, absent vasculogenesis, $\times 100$; II – (D) Negative label, absent vasculogenesis, $\times 100$; III – (A and B) Villousities with trophoblastic polar proliferation, low differentiated vasculogenesis, $\times 100$ and $\times 200$; III – (C) Negative label, absent vasculogenesis, $\times 100$; III – (D) Negative label, absent vasculogenesis, $\times 100$; IV – (A and B) Villousities with trophoblastic circumferential proliferation, with atypias, collapsed stromal vessels, $\times 100$ and $\times 200$; IV – (C) Low positive label, collapsed vessels, $\times 100$; IV – (D) Low positive label, collapsed vessels, $\times 100$. Hematoxylin–Eosin stain (A and B), immunohistochemical stain of CD31 and CD34 (C and D).

We obtained the cytogenetic analysis of the curettage product in 21 cases; in nine cases, the result was a triploidy with 69 chromosomes. The patients were prevented regarding the risks of a molar pregnancy/choriocarcinoma in the future pregnancies.

The monitoring was made according to the established protocol and showed a quickly decrease of the β -HCG level after the evacuation of the molar pregnancy even in the cases with complete mole, decreasing spontaneously to levels below 5 mIU/mL, the risk for choriocarcinoma being zero at these values [7, 8]. All the followed cases had a favorable evolution and in seven cases, the next pregnancies had a normal evolution.

Discussion

The molar pregnancy may occur during the fertilization, through a dispermic phenomenon when two different spermatozoa fertilize one ovule, when a spermatozoon with a diploid chromosomal set fertilize one ovule, when a spermatozoon with a haploid chromosomal set fertilize one ovule with diploid set, when an ovule is fertilized by a spermatozoon with two haploid chromosomal set, the result being a triploidy [9, 10]. The incidence is more reduced in the partial mole and presents adjacent values in the studies made until today – approximate 20% from the complete mole cases and 3.5% from the partial mole cases developed the gestational trophoblastic disease – choriocarcinoma [11–13].

There are two types of molar pregnancies:

The complete mole – is the result of the fertilization of oocytes with an absent or inactive pronucleus by two spermatozoa with a haploid chromosomal set (heterozygotes), or by a spermatozoon with a haploid chromosomal set (homozygotes). There is no embryo and the first echographic examination is rarely suggestive. The majority of the complete moles are androgenetic and diploid, prevailing the 46XX karyotype. The karyotype 46XY is less found and 46YY has never been found [14, 15]. Characteristic for the complete mole is the absence of the embryonic tissue (anembryonic pregnancy or clear egg), the stromal edema with vesicles formation, the trophoblastic diffuse hyperplasia, the fact that the villous stroma is avascular. Some vasculogenesis is in the majority of the complete moles [16–18], especially in the small villousities and without emphasized edema. It was suggested that the absence of the maternal contribution to the nuclear genome in the complete mole (paternal origin), causes the inability of the embryo formation. However, in the last decade have been found embryonic elements (blood-nucleated cells, the yolk sac, amniotic membranes) in the very early pregnancy period [19, 20].

The partial mole – is the result of the fertilization of a haploid oocytes by two spermatozoon (diandric triploidy) or by the fertilization of a diploid oocytes by one spermatozoa and the incorporation or the suppression of one polar body (digene), the phenotype being a diandric triploidy 69XXX/69XXY [21].

These two forms must be differentiated by the villous hydropic degeneration that appears in the case of the pregnancy stopped in evolution, so called the non-

molar placenta or the hydropic abortion. The hydropic degeneration, in these cases, is the result of losing the vascular villous support, the avascular villousities being unstrained. The microscopic villous changes shows that the hydropic transformation that affects the majority of the villousities is minimal, the appearance of the cisterns is rare and we do not have trophoblastic hyperplasia, which makes the difference with the mole [22–24].

However, the diagnosis may be immunohistochemical too, using specific antibodies and/or genetic.

The risk also varies taking in account the number of molar pregnancies. In a study made by Hancock BW and Tidy JA was noticed the following report of the gestational trophoblastic disease development [25]. Therefore, after one molar pregnancy the report of the gestational trophoblastic disease development is 1:50, after two molar pregnancies, the report is 1:6, and after three molar pregnancies, the report becomes 1:2.

In the present study, we have examined the utility of the classic histological criteria used for the diagnosis of the molar pregnancy, comparing it with the immunohistochemical examination and characterization.

CD31, an endothelial marker, was used for the study of the villous vascularization, for the visualization of the hemangioblastic cord and the primary vascular lumen formation. This marker was high positive in the requested abortion, therefore in the normal pregnancy, negative in the cases with spontaneous abortion with hydropic degeneration, and also negative in the complete and partial molar pregnancy.

CD34 showed the aspects of the villous heman-gioblastic cells incorporated in vasculogenesis. The immunohistochemical label with this marker was also high positive in the cases with requested abortion (normal pregnancy) and negative in the pregnancy with hydropic degeneration. In the molar abortion from the complete and partial mole was low positive detected.

The hydatidiform partial mole is histologically diagnosed as having four coexisting microscopic characteristics [26, 27]: (1) two types of villous populations, (2) big villousities (> or =3–4 mm), (3) irregular borders with trophoblastic inclusions and (4) trophoblastic hyperplasia (focal or in the syncytiotrophoblast).

The hydatidiform complete mole is histologically marked by an avascular villous stroma [28, 29], that is however not present in all the types of complete mole, in some cases noticing certain vasculogenesis, especially in the smaller villousities that do not present an obvious edema. Some authors [30] found vascular villousities in the cases with complete mole in 16%, and some other authors [31, 32] found it in 17%. In our study, the vasculogenesis in the cases with complete mole was much more reduced, noticed only in 9% from the cases.

In the partial mole, the majority of the studies [33–35], noticed a small number of vascular elements, an aspect that has also been showed in our study.

Regarding the group with normal pregnancies, our results are according to the results from the specialty literature [36–38]; in this last one it shows an intensive vasculogenesis with hemangioblastic cords with central and peripheral location in the mesenchymal villousities.

Some studies [39–41] showed however that even for the experienced histopathologists is sometimes difficult to certainly establish the differential diagnosis, in the atypical cases, the concordance rate between anatomopathologists being 55–75%. This disaccord may be assigned also to the absence of some morphological diagnosis criteria not strictly enough. In these conditions, the cytogenetical diagnosis may be of a real help regarding the differentiation of the mole type.

According to the results of the present study, we considered necessary to identify and establish some evaluation criteria in order to allow us to establish a certainty diagnosis.

Our study showed that following some histological criteria might be used for the differentiation between complete and partial mole and hydropic degeneration also; this is an important thing if we take in account the evolution of each of these entities. Also, the cytogenetic study represents a possibility to take in account, even if this one does not represent the first opportunity.

The immunohistochemistry did not represent in our study a conclusive method for the differentiation between the partial and complete mole, the only obvious difference being between the molar and non-molar pregnancy (the spontaneous abortion with hydropic degeneration).

The differentiation that can be made between the partial molar pregnancy and the complete molar pregnancy is showed by the presence of the trophoblastic atypia.

✉ Conclusions

Certain histological criteria may be followed in order to make a differential diagnosis between the types of molar pregnancy, the presence of the trophoblastic atypia being the most important element for the complete mole diagnosis. The immunohistochemical methods may be used for the differentiation between the molar and non-molar pregnancy.

The histopathological exam or at least an HCG determination in order to identify an eventual microscopic molar pregnancy are not offered to all the women that have an abortion. Therefore, is advisable, after the histological diagnosis of the molar pregnancy, a periodic evaluation of the next elements: β -HCG, an ultrasound examination at four weeks post-abortion for the evaluation of the endometrium, the blood counts and the hematocrit level, the evaluation of the bleeding, because an accurate exploration allows a complete and promptly diagnosis and a careful surveillance avoids conduct errors with important repercussions for the patients.

Of course, there are also cases with a difficult differential diagnosis, but probably in the future it will developed other techniques more specific that will solve this dilemma.

Acknowledgements

This work was supported by the PNII 41088/2007 Research Grant, coordinator University of Medicine and Pharmacy of Craiova, project manager Professor Liliana Novac, MD, PhD.

References

- [1] Berkowitz RS, Goldstein DP, The management of molar pregnancy and gestational trophoblastic tumors. In: Knapp RC, Berkowitz RS (eds), *Gynecologic Oncology*, 2nd edition, McGraw-Hill, New York, 1993, 328–338.
- [2] Fukunaga M, Katabuchi H, Nagasaka T, Mikami Y, Minamiguchi S, Lage JM, *Interobserver and intraobserver variability in the diagnosis of hydatidiform mole*, *Am J Surg Pathol*, 2005, 29(7):942–947.
- [3] Ishikawa N, Harada Y, Tokuyasu Y, Nagasaki M, Maruyama R, *Re-evaluation of the histological criteria for complete hydatidiform mole: comparison with the immuno-histochemical diagnosis using p57KIP2 and CD34*, *Biomed Res*, 2009, 30(3):141–147.
- [4] Paul M, Goodman S, Felix J, Lewis R, Hawkins M, Drey E, *Early molar pregnancy: experience in a large abortion service*, *Contraception*, 2010, 81(2):150–156.
- [5] Niemann I, Bolund L, Sunde L, *Twin pregnancies with diploid hydatidiform mole and co-existing normal fetus may originate from one oocyte*, *Hum Reprod*, 2008, 23(9):2031–2035.
- [6] Bifulco C, Johnson C, Hao L, Kermalli H, Bell S, Hui P, *Genotypic analysis of hydatidiform mole: an accurate and practical method of diagnosis*, *Am J Surg Pathol*, 2008, 32(3):445–455.
- [7] Dresang LT, *A molar pregnancy detected by following beta-human chorionic gonadotropin levels after a first trimester loss*, *J Am Board Fam Pract*, 2005, 18(6):570–573.
- [8] Feltmate CM, Batorfi J, Fulop V, Goldstein DP, Doszpod J, Berkowitz RS, *Human chorionic gonadotropin follow-up in patients with molar pregnancy: a time for reevaluation*, *Obstet Gynecol*, 2003, 101(4):732–736.
- [9] Rosenbusch B, *Co-existence of a diploid hydatidiform mole and a normal fetus: mysterious events at the pronuclear stage*, *Hum Reprod*, 2008, 23(12):2876–2877.
- [10] Lai CY, Chan KY, Khoo US, Ngan HY, Xue WC, Chiu PM, Tsao SW, Cheung AN, *Analysis of gestational trophoblastic disease by genotyping and chromosome in situ hybridization*, *Mod Pathol*, 2004, 17(1):40–48.
- [11] Garner EI, Goldstein DP, Feltmate CM, Berkowitz RS, *Gestational trophoblastic disease*, *Clin Obstet Gynecol*, 2007, 50(1):112–122.
- [12] Koc S, Ozdegirmenci O, Tulunay G, Ozgul N, Kose MF, Bulbul D, *Recurrent partial hydatidiform mole: a report of a patient with three consecutive molar pregnancies*, *Int J Gynecol Cancer*, 2006, 16(2):940–943.
- [13] Masterson L, Chan SB, Bluhm B, *Molar pregnancy in the emergency department*, *West J Emerg Med*, 2009, 10(4):295–296.
- [14] Maggiori MS, Peres LC, *Morphological, immunohistochemical and chromosome in situ hybridization in the differential diagnosis of Hydatidiform Mole and Hydropic Abortion*, *Eur J Obstet Gynecol Reprod Biol*, 2007, 135(2):170–176.
- [15] Seckl MJ, Gillmore R, Foskett M, Sebire NJ, Rees H, Newlands ES, *Routine terminations of pregnancy – should we screen for gestational trophoblastic neoplasia?*, *Lancet*, 2004, 364(9435):705–707.
- [16] Lisman BAM, Boer K, Bleker OP, van Wely M, Exalto N, *Vasculogenesis in complete and partial hydatidiform mole pregnancies studied with CD34 immunohistochemistry*, *Hum Reprod*, 2005, 20(8):2334–2339.
- [17] Kim MJ, Kim KR, Ro JY, Lage JM, Lee HI, *Diagnostic and pathogenetic significance of increased stromal apoptosis and incomplete vasculogenesis in complete hydatidiform moles in very early pregnancy periods*, *Am J Surg Pathol*, 2006, 30(3):362–369.
- [18] Wielsma S, Kerkmeijer L, Bekkers R, Pyman J, Tan J, Quinn M, *Persistent trophoblast disease following partial molar pregnancy*, *Aust N Z J Obstet Gynaecol*, 2006, 46(2):119–123.
- [19] Kim KR, Park BH, Hong YO, Kwon HC, Robboy SJ, *The villous stromal constituents of complete hydatidiform mole differ histologically in very early pregnancy from the normally developing placenta*, *Am J Surg Pathol*, 2009, 33(2):176–185.

- [20] LeGallo RD, Stelow EB, Ramirez NC, Atkins KA, *Diagnosis of hydatidiform moles using p57 immunohistochemistry and HER2 fluorescent in situ hybridization*, Am J Clin Pathol, 2008, 129(5):749–755.
- [21] Zaragoza MV, Surti U, Redline RW, Millie E, Chakravarti A, Hassold TJ, *Parental origin and phenotype of triploidy in spontaneous abortions: predominance of diandry and association with the partial hydatidiform mole*, Am J Hum Genet, 2000, 66(6):1807–1820.
- [22] Rosai J, *Pregnancy, trophoblastic disease, and placenta*. In: Rosai J (ed), *Rosai and Ackermann's Surgical Pathology*, 9th edition, Mosby Company, Edinburgh, 2004, 1737–1761.
- [23] Soper JT, *Gestational trophoblastic disease*, Obstet Gynecol, 2006, 108(1):176–187.
- [24] Wolfberg AJ, Feltmate C, Goldstein DP, Berkowitz RS, Lieberman E, *Low risk of relapse after achieving undetectable HCG levels in women with complete molar pregnancy*, Obstet Gynecol, 2004, 104(3):551–554.
- [25] Hancock BW, Tidy JA, *Current management of molar pregnancy*, J Reprod Med, 2002, 47(5):347–354.
- [26] Genest DR, *Partial hydatidiform mole: clinicopathological features, differential diagnosis, ploidy and molecular studies, and gold standards for diagnosis*, Int J Gynecol Pathol, 2001, 20(4):315–322.
- [27] Steigrad SJ, *Epidemiology of gestational trophoblastic diseases*, Best Pract Res Clin Obstet Gynaecol, 2003, 17(6):837–847.
- [28] Lisman BA, van den Hoff MJ, Boer K, Bleker OP, van Groningen K, Exalto N, *The architecture of first trimester chorionic villous vascularization: a confocal laser scanning microscopical study*, Hum Reprod, 2007, 22(8):2254–2260.
- [29] Sebire NJ, *Hydatidiform mole and medical management of miscarriage*, BMJ, 2006, 332(7555):1454.
- [30] Soma H, Osawa H, Oguro T, Yoshihama I, Fujita K, Mineo S, Kudo M, Tanaka K, Akita M, Urabe S, Kudo Y, *P57kip2 immunohistochemical expression and ultrastructural findings of gestational trophoblastic disease and related disorders*, Med Mol Morphol, 2007, 40(2):95–102.
- [31] Gerner O, Segal S, Kopmar A, Sassoon E, *The current clinical presentation of complete molar pregnancy*, Arch Gynecol Obstet, 2000, 264(1):33–34.
- [32] Sebire NJ, Fisher RA, Foskett M, Rees H, Seckl MJ, Newlands ES, *Risk of recurrent hydatidiform mole and subsequent pregnancy outcome following complete or partial hydatidiform molar pregnancy*, BJOG, 2003, 110(1):22–26.
- [33] Benirschke K, Spinosa JC, McGinniss MJ, Marchevsky A, Sanchez J, *Partial molar transformation of the placenta of presumably monozygotic twins*, Pediatr Dev Pathol, 2000, 3(1):95–100.
- [34] Merchant SH, Amin MB, Viswanatha DS, Malhotra RK, Moehlenkamp C, Joste NE, *p57KIP2 immunohistochemistry in early molar pregnancies: emphasis on its complementary role in the differential diagnosis of hydropic abortuses*, Hum Pathol, 2005, 36(2):180–186.
- [35] Kaufmann P, Mayhew TM, Charnock-Jones DS, *Aspects of human fetoplacental vasculogenesis and angiogenesis. II. Changes during normal pregnancy*, Placenta, 2004, 25(2–3):114–126.
- [36] Altieri A, Franceschi S, Ferlay J, Smith J, La Vecchia C, *Epidemiology and aetiology of gestational trophoblastic diseases*, Lancet Oncol, 2003, 4(11):670–678.
- [37] de Andrade JM, *Hydatidiform mole and gestational trophoblastic disease*, Rev Bras Ginecol Obstet, 2009, 31(2):94–101.
- [38] Petignat P, Billieux MH, Blouin JL, Dahoun S, Vassilakos P, *Is genetic analysis useful in the routine management of hydatidiform mole?*, Hum Reprod, 2003, 18(2):243–249.
- [39] McConnell TG, Murphy KM, Hafez M, Vang R, Ronnett BM, *Diagnosis and subclassification of hydatidiform moles using p57 immunohistochemistry and molecular genotyping: validation and prospective analysis in routine and consultation practice settings with development of an algorithmic approach*, Am J Surg Pathol, 2009, 33(6):805–817.
- [40] Hurteau JA, *Gestational trophoblastic disease: management of hydatidiform mole*, Clin Obstet Gynecol, 2003, 46(3):557–569.
- [41] Hustin J, Kadri R, Jauniaux E, *Spontaneous and habitual abortion – a pathologist's point of view*, Early Pregnancy, 1996, 2(2):85–95.

Corresponding author

Liliana Novac, Professor, MD, PhD, Department of Obstetrics and Gynecology, Faculty of Medicine, University of Medicine and Pharmacy of Craiova, 2–4 Petru Rareș Street, 200349 Craiova, Romania; Phone +40744–547 190, Fax +40251–502 179, e-mail: liliana.novac@gmail.com

Received: October 15th, 2010

Accepted: December 5th, 2010