

ORIGINAL PAPER

The modifications suffered by the peri-esophageal anatomical structures in the hiatal hernia disease: a qualitative and quantitative microanatomic study

V. ARDELEANU¹⁾, GICA-RUMINA CHEBAC²⁾, COSTINELA GEORGESCU³⁾,
DOINIȚA VESA⁴⁾, L. FRÂNCU⁵⁾, LUCIA DOINA FRÎNCU⁵⁾, D. PĂDURARU⁵⁾

¹⁾Department of Morphological Sciences

²⁾Clinical Department

Faculty of Medicine and Pharmacy, "Lower Danube" University, Galati

1st Surgery Clinic, "St. Andrew" Emergency Hospital, Galati

³⁾Department of Functional Sciences

⁴⁾ENT Clinic,

"St. Andrew" Emergency Hospital, Galati, Clinical Department

Faculty of Medicine and Pharmacy, "Lower Danube" University, Galati

⁵⁾Department of Anatomy,

"Grigore T. Popa" University of Medicine and Pharmacy, Iassy

Abstract

This paper presents the results of a surgical and histopathological study regarding the microanatomical modifications of the thoraco-abdominal diaphragm and of the peri-esophageal structures in the hiatal hernias, establishing a cause-effect relationship between these structural modifications and the hiatal hernia. The study was represented by two groups of patients: a control group and a group with hiatal hernia. The study method consisted in intraoperative biopsy of fragments from the diaphragm as well as from the tissue around the esophagus, which were studied from the histopathological viewpoint, using histological methods and quantitative microanatomy. In the end, the results obtained from the two groups were compared. The microscopic examination revealed the presence of an inflammatory infiltrate located between muscle fibers, especially near blood vessels, at the level of the diaphragm crura and the phreno-esophageal membrane. Also, they found red blood cell at this level, most likely due to pressure from the hernia at this level. From the quantitative micro-anatomical viewpoint, there has been noticed an increase in the percent of the vascular lumen (accentuated vasodilatation) as well as the interstices occupied with the edema and hemorrhage, to the detriment of the muscle fibers, the most significant modifications being met at the level of the crura.

Keywords: thoraco-abdominal diaphragm, hiatal hernias, anatomical modifications.

Introduction

In recent years, because of the introduction of new means of diagnosis, like the superior GI endoscopy, and the bringing up to date of the radiological examination, the number of cases of hiatal hernias discovered has increased. Even in these conditions it must be taken into account the fact that only one out of 10 symptomatic patients come to see the doctor and only one out of five of them is gets to be treaded surgically [1]. Also, it must be we must pin point the fact that the appearance of clinical manifestations in a hiatus hernia actually represents clinical expressions of hiatal hernia complications and of gastro-esophageal reflux, because most of the times they are manifested by heartburn and/or regurgitation. Rarely patients come with only a retro-sternal discomfort and end up, based on their symptoms, to be diagnosed with hiatal hernia.

However, in terms of histopathology, hiatal hernia, indirectly through determination of gastro-esophageal reflux induces changes in the esophageal mucus, namely

the transformation of normal esophageal epithelium floor into a cylindrical one layered one, the so-called Barrett's esophagus, thus increasing 30–40 times the risk of esophageal cancer [2].

The gross anatomical changes that occur in hiatal hernias, like the extending or abolishing of the His angle, the distance of the diaphragm cruras and the widening of the hiatal ring [3], have been already described in the literature so we will not insist on these issues any more. This study was intended so as to see if any structural changes occur in different parts of the thoraco-abdominal diaphragm or in the peri-esophageal anatomical structures and to establish a cause-effect relationship between these changes and hiatal hernia.

Material and Methods

The study was represented by two groups:

- A first group of 23 patients that were surgically treated for various conditions but did not have hiatal hernias. Biopsy fragments were collected from them

in order to standardize normal anatomical structures.

▪ A group consisting of a total of 28 patients admitted in “St. Andrew” Emergency Hospital from Galati, between January 1st, 2007 and December 30th, 2009, patients that were diagnosed with hiatal hernia and were surgically treated for this condition. The study method was the bioptical intra-operative collecting of fragments from the diaphragm and thoraco-abdominal tissues around the esophagus, a collecting which was done traditionally or celioscopically. Subsequently, these fragments were prepared histologically and submitted to a histological study, the first one being a qualitative histopathological interpretation of these slide, and then a quantitative study, which sought the stereological determination of the percentages of different structural components studied, and to compare them with normal anatomy. Hematoxylin–Eosin staining, Goldner–Szekely and Van Gieson were used in the process. The examination was done with objective of 10×, 20× and 40×.

Of the patients under investigation, 16 patients (57.14%) were aged between 51 and 60 years, five (17.85%) between 61 and 70 years, and seven (25%) between 41 and 50 years.

For the quantitative determination with the Weibel grid, the digital overlapping of the standard scale over the video image obtained from the histological slide was used. The scale was adapted by the observer in order to fit the parameters of the studied tissue and to achieve optimal conditions for quantification (Figures 1–3).

The main steps taken in the stereological measurement were:

- The determination of the reference structures from the anatomical formation studied:
 - the muscle fibers;
 - the lumen sanguine vessels;
 - the interstitial spaces;
 - the connective tissue that encompasses the other structures, except those listed above.
- The defining of the geometric grid superimposed on microscopic images Weibel;
- The defining of the specific characteristics of tissue;
- The establish of the total number of points to be quantified and their number obtained by pressing the keys which correspondent to the intersections reference structures selected;
 - The automatic calculation of the stereological ratio;
 - The statistical evaluation of the calculated parameters;
 - The graphical representation of the changes found;
 - The conclusions.

For each case, a 40×-objective was used in order to study a test area, which corresponded to 560 points, the grid test with Weibel parallels having a distance between two points equal to 19.39 μm .

During quantification, the orientation of the Weibel parallels has shifted to perform random quantification from different incidences.

The statistical report automatically considered the percentages selected above, for each case, and for groups, and the results, which were statistically checked, were graphically represented.




Figure 1 – The grid test with the Weibel parallels which helped interactively measure 560 test points, with $d = 19.39 \mu\text{m}$.

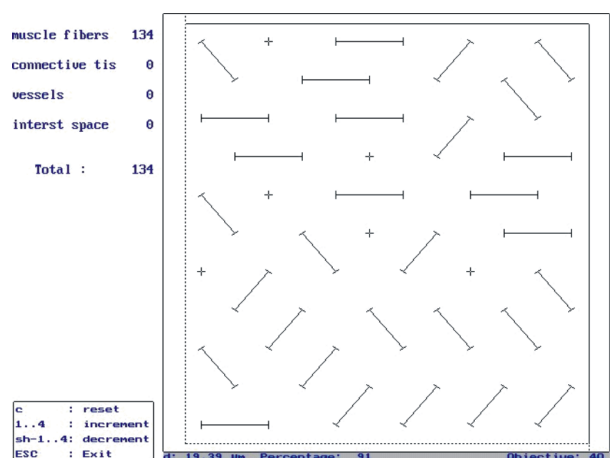


Figure 2 – The grid test with the Weibel parallels after the first change in the lines' orientation.

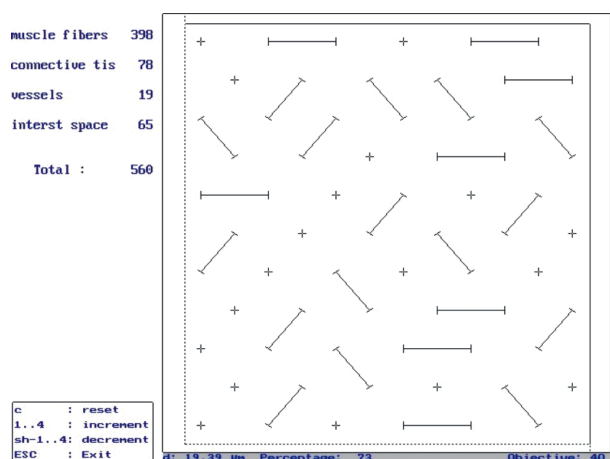


Figure 3 – The grid test with the Weibel parallels after the second change in the lines' orientation.

Results

The biopsy was taken from the cruras of the diaphragm, from the phreno-esophageal membrane, the esophageal hiatus and the tissue peri-esophageal.

The following results were gathered from the fragments harvested:

- In three cases (10.72%) we have noticed the pre-

sence of hemorrhagic infiltration (micro-hemorrhages) at the level of the two cruras of the diaphragm, but it was uncertain that these changes were prior to or were caused by the maneuvers used during biopsy; also we have noticed that there was a rarefaction of the muscle fibers which had also suffered small ruptures here and there, the interstitial tissue was well represented and blood vessels were dilated (Figures 4 and 5).

- In the case of six patients (21.42%), numerous inflammatory and hemorrhagic infiltrates and also rarefaction muscle fibers were found at the level of the phreno-esophageal membrane (Figure 6).

- In 13 cases, the peri-esophageal connective tissue presented sanguine micro-suffusions with inflammatory infiltrate of exsudative type, and in one case (3.57%) it presented an inflammatory infiltrate of fibrinous type (Figure 7).

The microscopic examination revealed the presence of an inflammatory infiltrate located between muscle fibers, especially near the blood vessels. There were also sanguine extravasations with red cells, most likely because of the pressure exerted by the hernia. The inflammatory infiltrate consisted of polymorphonuclear neutrophils, acidophilus and numerous macrophages. The macrophages are involved in the reabsorbing of the infiltrate and of the extravasated fluid.

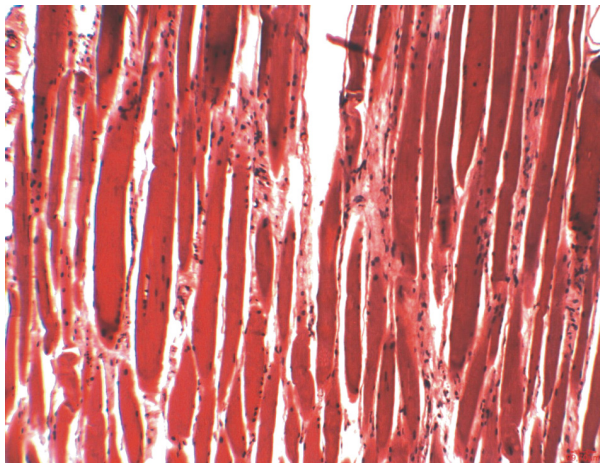


Figure 4 – A longitudinal section through the right diaphragm crura. Muscle tissue with edema, congestion, and interstitial hemorrhage (HE stain, ob. 10×).

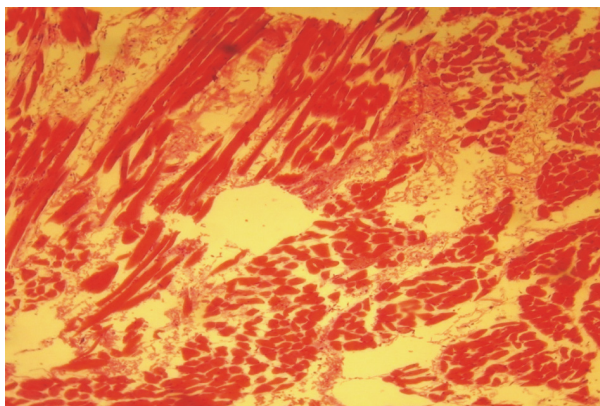


Figure 5 – A longitudinal section through the right diaphragm crura. Sanguine suffusions. Small ruptures of the muscle. Well represented interstitial tissue (HE stain, ob. 10×).

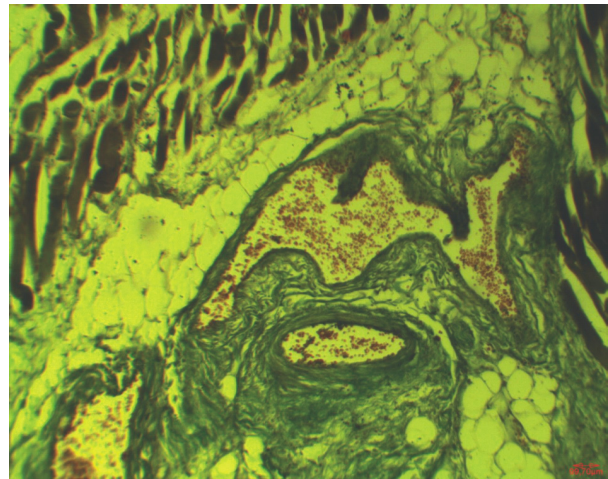


Figure 6 – A marked vasodilatation in fibro-adipose peri-esophageal tissue (a phreno-esophageal membrane). Small interstitial hemorrhage (Goldner-Szekely stain, ob. 10×).

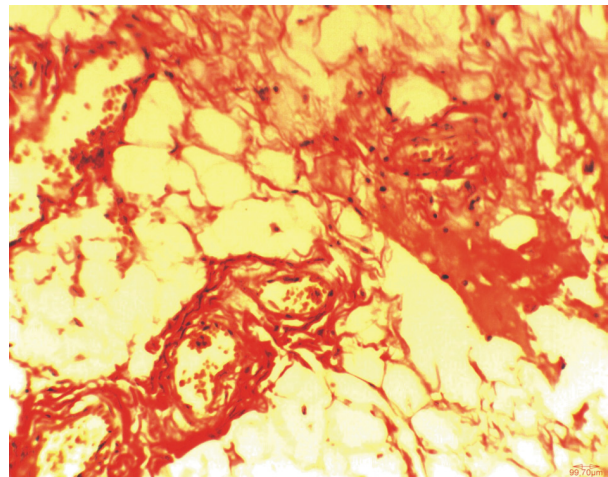


Figure 7 – Conjunctive-adipose peri-esophageal tissue with a moderate vasodilatation and with a discrete peri-vascular inflammatory infiltration and bleeding (Van Gieson stain, ob. 20×).

On closer analysis, we found that inflammatory infiltrate was becoming more significant as the distance from the hernia hole was smaller, the further it got from the hole, the smaller it got or it even was nonexistent. Hence, we have concluded that the inflammatory infiltrate resulted as a response to tissue aggression factors (pressure from the hernia hole) and the changes, which took place, can be reversed due to the absence of reorganization processes.

In the case of one patient, besides the changes mentioned above, we have discovered fibroblasts, which are involved in tissue reorganization. We have also noticed small areas of tissue necrosis, probably caused by the prolonged stasis and, especially, by the pressure exerted by the local microvascularization, which can be suppressed. Since areas of necrosis have been located, we can deduce the fact that the lesions are irreversible and will lead to the appearance of reorganization fibrosis.

Representative sections were evaluated quantitatively by means of stereology, with the help of the interactive digital program called PRODI 5.2. The volumes of the

main structures of the diaphragm muscle, which were collected from different places (the cruras, the muscle-tendinous junction, and the costal portion), were measured in percentages, and the results were statistically processed and graphically represented.

In the case of a normal adult's diaphragm, close values were obtained for each structure, from all four parts of the muscle, which was under analysis. The good representation of muscle fibers was quite obvious, especially in the case of muscular portion from the cruras. Almost all of the structures returned the same values and in all of them, they occupied over 70% of the tissue (Figure 8).

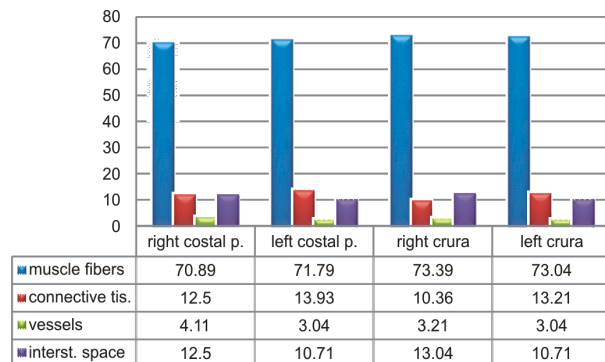


Figure 8 – Graphical representation of the percentages of the reference structures in a normal adults' diaphragm muscle.

In all the parts of the diaphragm of an adult with hiatal hernia (Figure 9), we had noticed a smaller number of muscle fibers, but to varying degrees: the smallest in the cruras, then the right costal portion and the largest, in the left costal portion.

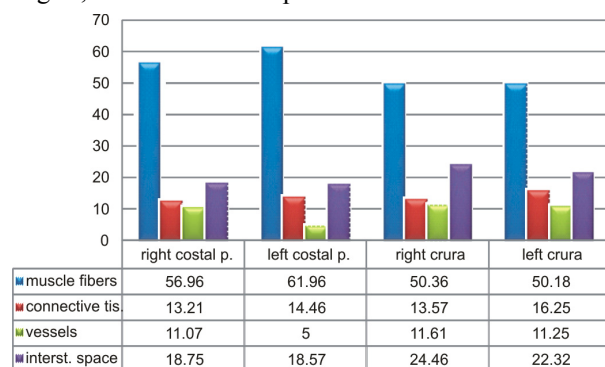


Figure 9 – Graphical representation of the percentages of the reference structures in the case of a diaphragm muscle affected by hiatal hernia.

We have also quantified the increase of the percentage of the interstitial spaces situated at the level of the cruras, which no longer have a compact structure, and the muscle fibers were dissociated by edema and micro-hemorrhages. The most affected one was the right crura. Both diaphragm cruras had suffered processes of fiber transformation in their muscular portions and have lost their elasticity and functional capacity.

On what concerns the vascular device, there has been an increase in the percentage of vascular lumens found at the level of the muscular portion of the cruras and of the right costal, while the left costal portion registered only minor changes.

Discussion

Diaphragmatic hernia is a common medical condition characterized by abdominal visceral protrusion directly with esophageal hiatal (95% of patients) or adjacent (5% of patients) [4]. People suffering from this disease can have symptoms such as regurgitation, heartburn, early satiety, and in extreme cases, respiratory or cardiac symptoms can present. These symptoms can become resistant to medication and require surgical correction [5, 6].

In the US, approximately 40 000 antireflux operations are performed each year [7].

Normal position of gastroesophageal sphincter serves to adjust the lower esophageal sphincter physiological function as an antireflux barrier. This mechanism is supported by surrounding connective structures: phrenoesophageal ligament, gastrohepatic ligament, gastrophrenic ligament. Although there was considerable interest in physiological mechanisms related to dysfunction of the lower esophageal sphincter in gastroesophageal reflux disease (GERD) with and without hiatal hernia (HH), little is known about the structural morphology of the ligaments that support the normal junction Gastroesophageal and diaphragm support structures [8, 9].

Recent studies have confirmed that phrenoesophageal ligament is composed of lax connective tissue and collagen fibers crossed well-formed elastic blades [10].

Knowledge of pathologic changes in ligaments supporting gastroesophageal junction may be of considerable importance in terms of literacy association between gastroesophageal reflux and hiatal hernia.

The scientific references regarding micro-structural changes of the peri-esophageal anatomical structures of the hiatal hernia are very poorly represented.

A recent electronic microscopy study conducted on a sample of 104 patients suffering from GERD, including 76 with hiatal hernia, in which biopsy fragments were taken from a crura of the diaphragm, revealed the following: the vacuolar degeneration of the infrasarcolemma areas, nuclear degeneration, twisted plasmalemma, the degeneration of the myofibrils with a torn Z-band, multiple cracked sarcomeric, the degeneration of the sarcomeric of the central area, the rupture and degeneration of the sarcomeric from the marginal areas, the growth of the spaces between the myofibril and the altered of the sarcotubes complexes. The same study states that there were no did no quantitative changes in the number of collagen fibers and interstitial tissue [11].

Another study examined the elastin and collagen fibers of ligaments, which support the eso-gastric junction in the case of the patients suffering from GERD and hiatal hernia vs. the patients with GERD but without hiatal hernia. The study was done on a group of 30 patients and has used biopsy samples from the gastro-hepatic, phreno-esophageal and gastro-phrenic ligaments. The results showed that in the case of patients with hiatal hernias the elastin fibers were fragmented and distorted, at least in two of the three ligaments analyzed, while in the case of the patients with reflux disease but without gastro-esophageal

hernia, the elastin from the gastrophrenic and phreno-esophageal ligaments has decreased at over 50% of the patients (a quantitative study) [10].

Although functional roles of ligaments and structure; periesophageal not yet well defined, it is shown that depletion of elastic fibers in the phrenoesophageal ligament (elastolizis) is an important aspect in developing hiatal incompetence. Highest elastin content was found in the phrenoesophageal ligament patients with uncomplicated GERD (31% of tissue area). It was also associated with a marked loss of elastic fibers in patients with hiatal hernia. The other two ligaments qualitative and quantitative changes were similar to those found in phrenoesophageal ligament [10].

These studies indicate that the number of patients we had chosen for our study is big enough to make the results valid, and secondly, the structural changes obtained by other researchers, by means of the electronic microscopy or by simple histological examination sustain the fact that micro-structural changes do occur in the hiatal hernia. However, there are still many things that need to be investigated especially in terms of the histopathological study of this disease. Neither we, nor the above-mentioned studies could not yet indicate a cause-effect relationship between these structural changes and the appearance of hiatal hernia.

Other studies [12] have shown that intermittent hypobaric hypoxia did not significantly alter the composition of diaphragm fibers that have contractile or oxidative properties, but significant differences were noted regarding the capillary and the fiber morphometry, other muscles being more sensitive. Many studies involve the changes caused by the administration of hormones such as thyroxin [13, 14] or anabolic steroids, extending the experimental results on people who use them to increase physical performance [15].

These results warn us of the possibility of a hiatal hernia in dystrophic persons who are on long hormonal treatments or who suffer from hypo-ventilator lung affections.

Recently studies have shown disordered matrix protein in patients with abdominal wall hernias, with collagen subtypes report changes, changes that have proven to be existing and mRNA level, with a decrease in type I collagen called "couple" important for resistance mechanical traction, and increased collagen type III, called "immature", a protein that appears temporarily during tissue remodeling. This change of collagen subtypes is thought to help decrease the mechanical strength of connective tissue, and may play a role in hernia development. In addition, matrix metalloproteinases are a family of zinc dependent proteases, which are crucial in wound healing, their ability to degrade and remodel in almost all protein structures 1 and 13 matrix metalloproteinases are known for degradation of collagen types I and III [16].

So far, the roles of elastin, collagen subtypes and matrix metalloproteinases are known in the development and recurrence of diaphragmatic hernia, but is known association between hiatal hernias and other hernias, which makes us think the possibility of such structural changes and hiatal hernia.

In terms influence of the size of the hiatus on the rate of reherniation after laparoscopic fundoplication and refundoplication with mesh hiatoplasty, have found that, in primary intervention, recurrence of hiatal hernia is more likely the larger the hiatal surface area is. The size of the hiatus is a major contributing factor to the possibility of reherniation. After failed primary hiatal closure, the size of the hiatal defect is no marker for the possibility of reherniation [17].

Regarding the presence of heterotopic gastric tissue in the esophageal mucosa, there are authors who claim that this has no relevance in terms of symptoms of hiatal hernia, or association with peptic esophagitis or Barrett esophagus. The presence of this gastric mucosa in the upper third of the esophagus seems to be rarely cause clinical symptoms and less prone to complications [18].

Experimental studies on dogs, about morphological and functional changes in the closing sphincter of the lower esophagus after experimentally-induced hiatal hernia showed that using a new method of pressure measurement, the authors succeeded in proving the distention of the esophageal "sphincter". Morphologic investigations demonstrated that in hernia the muscle fiber is no longer an apolar helical fiber, but runs nearly horizontally. The reduced susceptibility to pentagastrin is caused by diminished tension of the muscle fiber. The distal esophageal closing mechanism consequently seems to be a function of the whole organ and not of a hormonally regulated sphincter [19].

☐ Conclusions

Both the thoraco-abdominal diaphragm, the crura of the diaphragm and the peri-esophageal anatomical tissues suffers some structural qualitative changes in hiatal hernias. The most common pathological aspects were: the rarefaction and micro-rupture of the muscle fibers, the presence of the hemorrhagic and inflammatory infiltrate vasodilatation.

The quantitative evaluations have supported the qualitative changes observed in most cases. In the adult's diaphragm with hiatus hernia, the percentage of vascular lumens (pronounced vasodilatation), of the interstices occupied by edema and hemorrhage has increased, the most significant changes being seen in the area of the crura.

Comparing the percentages of the structures of a normal diaphragm with those of a diaphragm invaded by hiatal hernia, the following significant changes have been noticed: the decrease in percentage of the muscle fibers from the cruras of the diaphragm, but to varying degrees, the increase in percentage of the vascular lumens at the level of the muscle portion of the cruras, and of interstitial spaces between the cruras. The changes in percentage regarding the conjunctive tissue were smaller, both cruras suffering from fibrous transformation of the portions of muscle fiber and from losing elasticity and functional capacity.

The quantitative assessments made support objectively the qualitative clinical, surgical and histological observations according to which the incidence of injury is high on the right side of the muscle.

The quantifications performed on various parts of the diaphragm muscle reveal the existence of changes which affect the intimate structure of the muscle and which become significant only after quantitative assessment, often not being noticed by means of the qualitative routine examination. The decrease of muscle fibers and the dividing processes of fibrous transformation precede or at least occur simultaneously with the installation hiatal hernia.

References

- [1] ANGELESCU N (ed), *Treaty of surgical pathology*, vol. 1, 2, Medical Publishing House, Bucharest, 2003, 1381–1391.
- [2] STREITZ JM JR, ELLIS FH JR, GIBB SP, BALOGH K, WATKINS E JR, *Adenocarcinoma in Barrett's esophagus. A clinicopathologic study of 65 cases*, *Ann Surg*, 1991, 213(2):122–125.
- [3] TÂRCOVEANU E, BRADEA C, MOLDOVANU R, VASILESCU A, *Laparoscopic anatomy of eso-gastric region*, *Jurnalul de Chirurgie (Journal of Surgery)*, 2008, 4(2):114–126.
- [4] EUBANKS T, PELLEGRINI S, Hiatal hernia and gastroesophageal reflux disease. In: TOWNSEND CM, MATTOX KL, EVERS BM, BEAUCHAMP D (eds), *Sabiston Textbook of Surgery: the biological basis of modern surgical practice*, 16th edition, W.B. Saunders, 2002.
- [5] FIRESCU D, REBEGEA L, MAFTEI O, BACALBAŞA N, NECHITA A, *Elements of surgical pathology*, Medical Publishing House, Bucharest, 2005.
- [6] LUNDELL L, MIETTINEN P, MYRVOLD HE, HATLEBAKK JG, WALLIN L, MALM A, SUTHERLAND I, WALAN A; NORDIC GORD STUDY GROUP, *Seven-year follow-up of a randomized clinical trial comparing proton-pump inhibition with surgical therapy for reflux oesophagitis*, *Br J Surg*, 2007, 94(2):198–203.
- [7] GANGOPADHYAY N, PERRONE JM, SOPER NJ, MATTHEWS BD, EAGON JC, KLINGENSMITH ME, FRISELLA MM, BRUNT LM, *Outcomes of laparoscopic paraesophageal hernia repair in elderly and high-risk patients*, *Surgery*, 2006, 140(4):491–498; discussion 498–499.
- [8] JANSEN PL, MERTENS PR P, KLINGE U, SCHUMPELICK V, *The biology of hernia formation*, *Surgery*, 2004, 136(1):1–4.
- [9] BOGART BI, ORT V, *Elsevier's Integrated Anatomy and Embryology*, Saunders, 2007.
- [10] CURCI JA, MELMAN LM, THOMPSON RW, SOPER NJ, MATTHEWS BD, *Elastic fiber depletion in the supporting ligaments of the gastroesophageal junction: a structural basis for the development of hiatal hernia*, *J Am Coll Surg*, 2008, 207(2):191–196.
- [11] FEI L, DEL GENIO G, BRUSCIANO L, ESPOSITO V, CUTTITTA D, PIZZA F, ROSSETTI G, TRAPANI V, FILIPPONE G, MOCCIA F, DEL GENIO A, *Crura ultrastructural alterations in patients with hiatal hernia: a pilot study*, *Surg Endosc*, 2007, 21(6):907–911.
- [12] PANISELLO P, TORRELLA JR, ESTEVA S, PAGÉS T, VISCOR G, *Capillary supply, fiber types and fiber morphometry in rat tibialis anterior and diaphragm muscles after intermittent exposure to hypobaric hypoxia*, *Eur J Appl Physiol*, 2008, 103(2):203–213.
- [13] SCHLENKER EH, BURBACH JA, *Thyroxine affects ventilation, lung morphometry, and necrosis of diaphragm in dystrophic hamsters*, *Am J Physiol*, 1995, 268(3 Pt 2):R779–R785.
- [14] SINGH YN, SCHLENKER EH, SINGH BN, BURBACH JA, *Consequences of thyroxine treatment on diaphragm and EDL of normal and dystrophic hamsters*, *Can J Physiol Pharmacol*, 2004, 82(5):345–352.
- [15] SATOH K, GOTOH T, YAMASHITA K, *Morphological effects of an anabolic steroid on muscle fibres of the diaphragm in mice*, *J Electron Microsc* (Tokyo), 2000, 49(4):531–538.
- [16] ZHENG H, SI Z, KASPERK R, BHARDWAJ RS, SCHUMPELICK V, KLINGE U, KLOSTERHALFEN B, *Recurrent inguinal hernia: disease of the collagen matrix?*, *World J Surg*, 2002, 26(4):401–408.
- [17] KOCH OO, ASCHE KU, BERGER J, WEBER E, GRANDERATH FA, POINTNER R, *Influence of the size of the hiatus on the rate of reherniation after laparoscopic fundoplication and refundoplication with mesh hiatoplasty*, *Surg Endosc*, 2010, Aug 24 [Epub ahead of print].
- [18] WEICKERT U, WOLF A, SCHRÖDER C, AUTSCHBACH F, VOLLMER H, *Frequency, histopathological findings, and clinical significance of cervical heterotopic gastric mucosa (gastric inlet patch): a prospective study in 300 patients*, *Dis Esophagus*, 2010, Jul 8 [Epub ahead of print].
- [19] KUNATH U, STELZNER F, *Morphological and functional changes in the closing sphincter of the lower esophagus after experimentally-induced hiatal hernia*, *Langenbecks Arch Chir*, 1976, Suppl:173–178.

Corresponding author

Valeriu Ardeleanu, MD, 1st Surgery Clinic, “St. Andrew” Emergency Hospital, Department of Morphological Sciences, Faculty of Medicine and Pharmacy, “Lower Danube” University, 35 Alexandru Ioan Cuza Street, 800010 Galați, Romania; Phone +40722–566 386, e-mail: valeriu_ar@yahoo.com

Received: June 30th, 2010

Accepted: October 25th, 2010