

ORIGINAL PAPER

Histological and ultrasonographical study of the human superficial branch of the radial nerve at distal forearm and its clinical implications

CHAKRAVARTHY MARX S¹⁾, PRAMOD KUMAR²⁾, DHALAPATHY S³⁾,
ANITHA MARX C⁴⁾, SATISH BABU M⁵⁾, KUMAR M BHAT¹⁾

¹⁾Department of Anatomy

²⁾Department of Plastic Surgery

Kasturba Medical College, Manipal, Karnataka, India

³⁾Department of Endocrine Surgery,

Sanjay Gandhi Post Graduate Institute of Medical
Sciences (SGPGI), Lucknow, Uttar Pradesh, India

⁴⁾Department of Computer Science,

Manipal Institute of Technology, Manipal, Karnataka, India

⁵⁾Department of Radiology,

Kasturba Hospital, Manipal University, Manipal, Karnataka, India

Abstract

Purpose: Age as poor prognostic factor following nerve repair may be due to change in intraneural anatomy with age. The purpose of this study is to find out the cross sectional microanatomy of the superficial branch of radial nerve (SBRN) at distal part of forearm for changes in the fascicular, non-fascicular components with respect to age and also to find cross section area of SBRN in healthy volunteers. **Material and Methods:** Sixty fresh human (37–88-year-old) cadaveric SBRN were collected from the distal part of forearm and studied at different magnifications after histological processing for morphometric analysis – total cross-sectional (Asc), fascicular (Af) and non-fascicular area (Anonf). Fifteen volunteers SBRN cross sectional area was measured by ultrasonography (US). **Results:** The SBRN was found to have 6–12 fascicles. Morphometric and correlation analysis confirmed that there was a significant increase of total cross section area, with significant increase of interfascicular adipose tissue in relation to advancing age. Ultrasonographic cross-sectional area ranged from 2 to 3.3 mm². **Conclusions:** Our study revealed comparatively more adipose tissue in human SBRN with advancing age. These findings may help to explain poor prognosis with advancing age following repair. SBRN ultrasonographical Asc was comparable to histological Asc. Further, it is possible to find Asc of SBRN by non-invasive US study and calculate the fascicular and non-fascicular area using our histological findings.

Keywords: superficial radial nerve, histology, age changes, adipose tissue, ultrasonography.

☐ Introduction

Peripheral nerve injury treatment often leads to functional recovery but is mostly incomplete or unpredictable, despite the regular use of sophisticated repair techniques [1]. Even entrapment of the peripheral nerves in restricted spaces and scars poses a therapeutic challenge difficult to deal with. Many factors can influence the functional recovery after injury to the nerve. The length of nerve defect, duration of pre-operative interval and age of the patients influence the nerve repair outcome. Age is an important factor as reflected by a much better regeneration capacity in children [2]. It is the experience of many surgeons that, early repair of the nerve, taking care of the proper alignment and topographical anatomy definitely results in better outcome. Therefore, the morphologists started implementing fascicularisation, as a recovery of nerve lesions mainly focusing on the nerve, as they are important especially in the elderly due to alterations

with increase in age [3]. We focused on the connective tissue that also undergoes change during the aging process, which is also important in nerve repair.

The superficial branch of the radial nerve (SBRN) is the terminal sensory branch of the radial nerve that runs under the cover of brachioradialis, passes straight downward along the antero-lateral aspect of forearm to supply the skin on the dorsal aspect of proximal parts of the lateral three and a half digits including the lateral two-thirds of the dorsum of the hand. Superficial branch of the radial nerve injuries can result from direct nerve trauma, compressive neuropathies, neuritis or due to neuromas [4–8]. The SBRN is mostly composed of sensory and sympathetic fibers in its fascicles. SBRN entrapment (Wartenberg's disease) can occur beneath the edge of brachioradialis (BR) tendon about 6 cm proximal to the radial styloid, pinched by scissoring effect of BR and extensor carpi radialis brevis (ECRB) [6, 9]. A complete knowledge of the superficial branch

of the radial nerve (SBRN) fascicular and non-fascicular morphology is necessary for the diagnostic application of ultrasound, computed tomography (CT) scan and magnetic resonance imaging (MRI) as well as for its successful surgical nerve repair [6–8, 10–12]. Ultrasound is an emerging technique for facilitating the localization and block of peripheral nerves [8, 10]. The management of these nerve injuries depends upon a thorough understanding of peripheral nerve anatomy.

Age as poor prognostic factor following nerve repair may be due to change in intraneural anatomy with age. The SBRN is important in microsurgical procedures [12, 13]. In nerve repair, axonal regeneration depends upon the amount of intervening perineurial tissue [14].

The purpose of this study is to find out the cross sectional microanatomy of the superficial branch of radial nerve (SBRN) at distal part of forearm for changes in the fascicular, non-fascicular components (adipose and non-adipose tissue) with respect to age and also to find cross section area of SBRN in healthy volunteers.

Material and Methods

Anatomical dissection and sampling

Sixty fresh human cadaveric SBRN were collected for the study from 30 cadavers (24 males and six females) from about 5 to 6 cm above the wrist, behind the brachioradialis tendon, immediately after piercing the deep fascia. These cadavers were donated to the Department of Anatomy, Kasturba Medical College, Manipal, India, between the years 2006 and 2009. During their lifetime, these individuals had neither neurologic nor metabolic disorders, nor any other kind of SBRN damage. The ethical clearance was obtained from Kasturba Hospital, Manipal University, India. Two centimeters of SBRN was obtained under the cover of brachioradialis at about 5 to 6 cm above the wrist (Figure 1). These nerve tissues were collected within 12 hours after death.

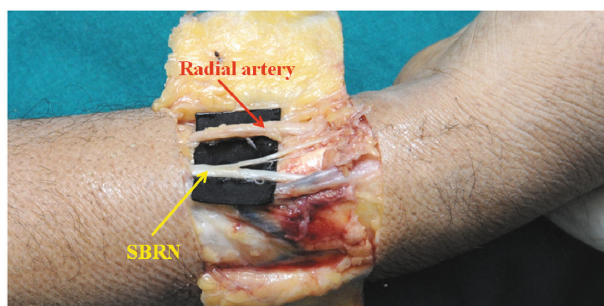


Figure 1 – Distal forearm shows the site of right SBRN sample collection. SBRN: superficial branch of the radial nerve above wrist.

Tissue processing

The obtained SBRN tissues were fixed immediately with 4% paraformaldehyde solution and embedded in paraffin. Nerve tissue was processed for histology (paraffin sections). Serial six-micron thick paraffin sections were taken approximately at mid-region of each nerve sample by using Rotary microtome (Leica

RM2125RT, Leica Biosystems Nussloch GmbH, Deutschland). In each nerve sample, every 100th section was selected, in such a way consecutive three sections were selected. The morphometric analysis was performed under the light microscope on these stained sections and the obtained mean values were used.

Histological Hematoxylin and Eosin (HE) staining

Six-micron thick paraffin sections were placed on gelatin-coated slides and dried. Nerve sections were hydrated in graded alcohol and brought to distilled water. These sections were stained with Hematoxylin stain for 2 minutes and Eosin stain for 30 seconds. Then the sections were dehydrated in a graded series of alcohol, cleared with xylene and mounted with cover-slips [15].

Masson's trichrome staining for connective tissue

Another set of sections were stained with Masson's trichrome using 1% Ponceau-fuchsin in 1% acetic acid, 1% phosphomolybdic acid in distilled water and 2% light green in 2% acetic acid. The nerve sections were hydrated in graded alcohol, brought to distilled water, and stained with Celestine blue-haemalum for 20 minutes. Decolorized with 1% acid alcohol for 20 seconds. The sections were washed with distilled water, stained with the Ponceau-fuchsin solution for 5 minutes. Sections were quickly rinsed in distilled water and placed in phosphomolybdic acid for 10 minutes. Sections were drained and stained with light green for 5 minutes, and treated with 1% acetic acid for 2 minutes to remove excess staining. Sections were dehydrated in a graded series of alcohol, cleared with xylene and mounted with coverslips [16].

Finally, HE, Masson's trichrome stained sections were observed under binocular light microscope and photographed with Motic live image program (Version 2.0, Motic China Group Co., Ltd.) for morphometric analysis.

Ultrasonography of the SBRN

Fifteen volunteers (from our staff members, 10 males and five females) were recruited for the study. They were healthy and older than 18 years. An exclusion criterion was injury to the upper extremity that caused immobility. After written informed consent was obtained, ultrasound scanning of both SBRN (under the cover of brachioradialis at about 5 to 6 cm above the wrist) was performed by use of a linear 5–17 MHz high resolution transducer (PHILIPS IU 22) ultrasound machine in the Radiology Department, Kasturba Hospital, Manipal.

Volunteers were examined. The upper limb was positioned with elbow flexion and forearm supination. The ultrasound probe was placed transverse to the course of radial nerve in the distal and lateral part of arm. The SBRN was identified in the proximal third of the forearm based on its location between the brachioradialis and the radial artery and scanned under the cover of brachioradialis at about 5 to 6 cm above the

wrist. Initially the nerve was examined in the gray scale and its circumference (by tracing the transversal borders of the nerve) was measured using continuous tracing method. For study measurements, the SBRN was scanned in short axis (transversal) view. Images were stored digitally. Each SBRN was scanned three times and the obtained mean values were used. Color Doppler was also used to identify the radial vessels and establishing the relation of the nerve and vessels (Figure 2).

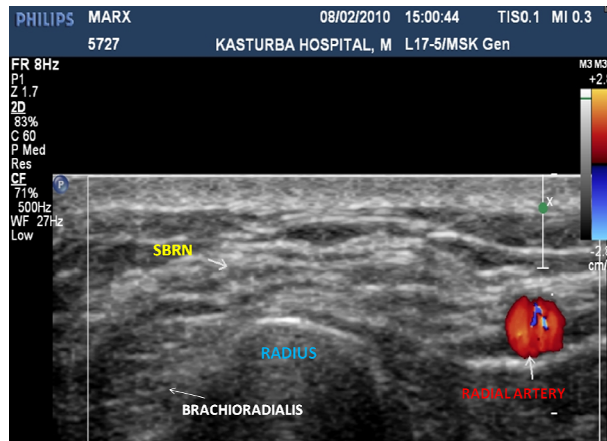


Figure 2 – Transversal (short axis) ultrasound image demonstrating the right SBRN and surrounding structures in healthy individual (above wrist). Color Doppler was used to identify the radial vessels (blue and red colored area). SBRN: superficial branch of the radial nerve above wrist.

Morphometric analysis

The morphometric analysis was performed using light microscope with a projection screen at a magnification of 50 \times . The images were analyzed using the in house developed software named “Tissue Quant” (TQ, Version 1.0), which is designed for color quantification in Manipal Centre for Information Science (MCIS), Manipal. This software provides the facility to choose a color for selectively measuring the areas in the image with a particular color.

For evaluating fascicle areas, circles were drawn manually around each of the fascicles in all the images. The circle was segmented out of the image by appropriately adjusting the color settings. The same setting was used for all the images. The area covered by the circle was then calculated by the software in terms of number of pixels. In the same way the total cross section, connective tissue (green and red color) were also selectively segmented out of the images by appropriately adjusting the color settings. The areas occupied by these tissues were then obtained in terms of number of pixels.

Micrometer scale was photographed under the same

(50 \times) magnification for the calibration purpose. Number of pixels representing a length of 1 mm was calculated for both horizontal and vertical arrangements. This provided the calibration for the number of pixels representing one mm² of area. The non-fascicular area was obtained by calculating the difference between the total cross section area and fascicular area.

The first part of the study (Hematoxylin and Eosin staining) included the estimation of the total number of fascicles (total Nf), the measurement of total cross-sectional area (Asc), individual and total fascicular area (Af) and non-fascicular area (Anonf). The number of SBRN fascicles per square millimeter (Nf 1/mm²) was obtained by total number of fascicles (total Nf) in SBRN divided by total cross-sectional area (Asc) of the SBRN (Nf = Total Nf/Asc).

The second part of the study (Masson’s trichrome staining) included the measurement of the non-adipose area (nFAT) in the non-fascicular area of the SBRN. The adipose tissue area (FAT) in the SBRN non-fascicular area (Anonf) was calculated by taking the difference between non-fascicular area (Anonf) and non-adipose area (nFAT) (FAT = Anonf - nFAT).

Statistical analysis

Data was analyzed using “SPSS” (Version 11.5) statistical packages. Summary was reported in terms of range, mean and SEM (standard mean of error). Pearson’s correlation coefficient was carried out between the age and SBRN adipose (FAT), non-adipose (nFAT) tissue (collagen fibers) area. Wherever correlation was significant, linear regression lines were drawn (Age-Independent sample, FAT-Dependent sample). Right and left side SBRNs were compared by using “paired *t*-test”.

Results

Sixty fresh human cadaveric SBRN were collected for the study from 30 cadavers (24 males and six females). The cadavers’ age ranged from 37 to 88-year-old, the mean age and standard deviation (SD) was found to be 60.97 (15.11).

Histology

The study of the SBRN cross-section showed the difference in number, size and distribution of the fascicles in all individual 60-nerve samples. In all cases, SBRN fascicular pattern belong to the polyfascicular type.

The Nf, Asc, Af, Anonf, FAT, nFAT, and Nf 1/mm² of SBRN were obtained during morphometric analysis and range, mean and SEM were calculated (Tables 1 and 2).

Table 1 – Descriptive statistics of all evaluated cases SBRN (right side) morphometric parameters

	Age [years]	Total Nf	Asc [mm ²]	Af [mm ²]	Anonf [mm ²]	FAT [mm ²]	nFAT [mm ²]	Nf 1/mm ²
Mean	60.97	9.57	2.87	0.91	1.96	0.86	1.1	3.29
SEM	2.71	0.26	0.09	0.03	0.08	0.08	0.09	0.11
Minimum	37	7	1.99	0.66	1.25	0.09	0.35	2
Maximum	88	12	3.57	1.28	2.73	1.95	2.35	5

	Age [years]	Total Nf	Asc [mm ²]	Af [mm ²]	Anonf [mm ²]	FAT [mm ²]	nFAT [mm ²]	Nf 1/mm ²
95% LCL	55.43	9.03	2.69	0.85	1.79	0.7	0.92	3.05
95% UCL	66.51	10.11	3.05	0.96	2.12	1.01	1.28	3.52
Count	30	30	30	30	30	30	30	30

SBRN – superficial branch of radial nerve above wrist; Total Nf – total number of fascicles; Asc – total cross sectional area; Af – fascicular area; Anonf – non-fascicular area; FAT – adipose tissue area; nFAT – non-adipose tissue area; Nf 1/mm² – number of fascicles per mm²; SEM – standard error of mean; LCL – lower confidence level; UCL – upper confidence level.

Table 2 – Descriptive statistics of all evaluated cases SBRN (left side) morphometric parameters

	Age [years]	Total Nf	Asc [mm ²]	Af [mm ²]	Anonf [mm ²]	FAT [mm ²]	nFAT [mm ²]	Nf 1/mm ²
Mean	60.97	9.29	2.85	0.9	1.96	0.96	1	3.32
SEM	2.71	0.29	0.08	0.03	0.07	0.07	0.08	0.13
Minimum	37	6	2.15	0.42	1.24	0.4	0.09	2
Maximum	88	12	3.6	1.12	2.72	2.15	1.95	5
95% LCL	55.43	8.69	2.69	0.84	1.81	0.82	0.84	3.07
95% UCL	66.51	9.89	3.02	0.95	2.1	1.11	1.15	3.58
Count	30	30	30	30	30	30	30	30

SBRN – superficial branch of radial nerve above wrist; Total Nf – total number of fascicles; Asc – total cross sectional area; Af – fascicular area; Anonf – non-fascicular area; FAT – adipose tissue area; nFAT – non-adipose tissue area; Nf 1/mm² – number of fascicles per mm²; SEM – standard error of mean; LCL – lower confidence level; UCL – upper confidence level.

The non-fascicular area (Anonf) was well developed in all the SBRN studied. The non-fascicular area (Anonf) was more when compared to fascicular area (Af) due to adipose (FAT) or non-adipose (nFAT) tissue deposition in it. In the SBRN studied from younger individuals showed less amount of adipose tissue (FAT) deposition in the epifascicular and interfascicular connective tissue region (Figures 3 and 4).

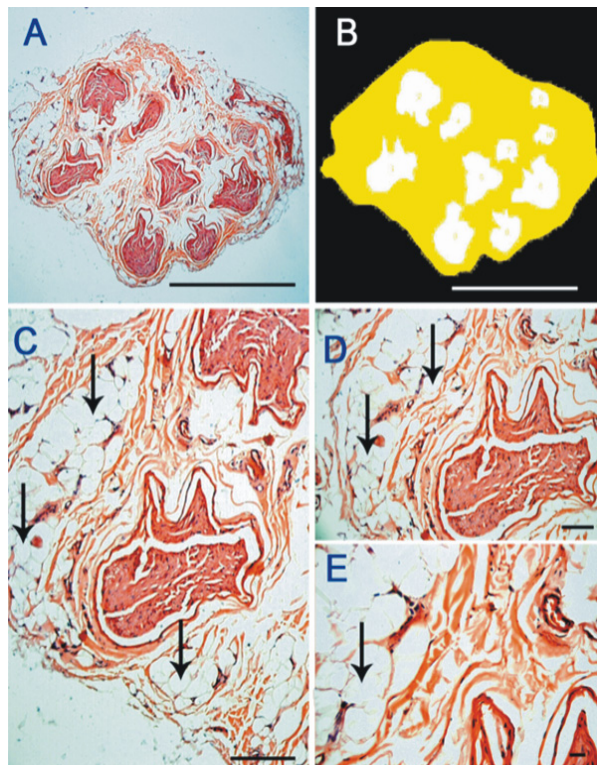


Figure 3 – Photomicrograph of the superficial branch of the radial nerve (SBRN) from a 71-year-old male: (A) shows large amount of adipose tissue in the epifascicular area, $\times 50$; (C) $\times 100$; (D) $\times 200$; (E) $\times 400$ are enlarged part of A ($\times 50$). Hematoxylin and Eosin (HE) stain. Arrows indicate the adipose tissue. (B) Automated measurement of the fascicular area (white), non-fascicular area (yellow). Scale bar = 100 μ m, valid for all the images.

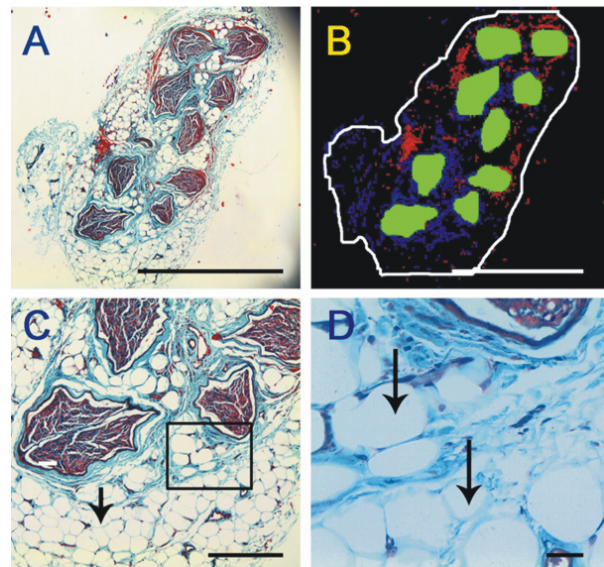


Figure 4 – Photomicrograph of the superficial branch of the radial nerve (SBRN) from an 81-year-old male: (A) shows large amount of adipose tissue in the epifascicular area ($\times 50$). Area marked by box in (C) $\times 100$ is enlarged in (D) $\times 400$. Masson's trichrome stain. Arrows indicate the adipose tissue. (B) Automated measurement of the total fascicular area (white), fascicular area (green), non-fascicular area (connective tissue – collagen fibers) (red and blue). Scale bar = 100 μ m, valid for all the images.

Whereas, in elderly individuals showed more amount of adipose tissue (FAT) deposition in the epifascicular and interfascicular connective tissue region. Finally, the total nerve cross section area (Asc) was found to be more in elderly individuals when compared to younger individuals (Figures 5 and 6). There was not much change in the amount of non-adipose tissue (nFAT) in the non-fascicular area (Anonf) with age.

All the above parameters were compared between right and left side by using “paired *t*-test”. There was no significant statistical difference between right and left side. Therefore, we treated them as independent sample for Pearson's correlation and linear regression tests.

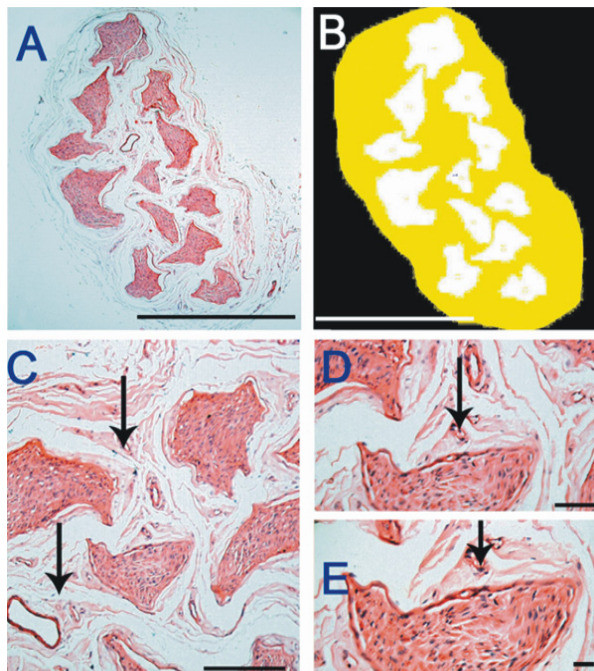


Figure 5 – Photomicrograph of the superficial branch of the radial nerve (SBRN) from a 42-year-old female: (A) shows very less amount of adipose tissue in the epifascicular area ($\times 50$); (C) $\times 100$; (D) $\times 200$; (E) $\times 400$ are enlarged part of A ($\times 50$). Hematoxylin and Eosin (HE) stain. Arrows indicate the collagen fibers. (B) Automated measurement of the fascicular area (white), non-fascicular area (yellow). Scale bar = 100 μm , valid for all the images.

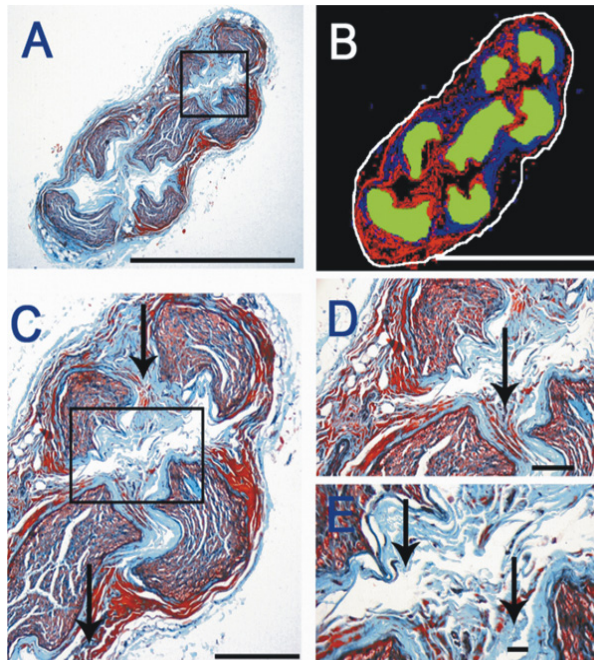


Figure 6 – Photomicrograph of the superficial branch of the radial nerve (SBRN) 40-year-old male: (A) shows very less amount of adipose tissue in the epifascicular area ($\times 50$); (C) $\times 100$; (D) $\times 200$; (E) $\times 400$ are enlarged part of A ($\times 50$). Masson's trichrome stain. Arrows indicate the collagen fibers. (B) Automated measurement of the total fascicular area (white), fascicular area (green), non-fascicular area (connective tissue – collagen fibers) (red and blue). Scale bar = 100 μm , valid for all the images.

Pearson's correlation result

Pearson's correlation coefficient was carried out between the age and SBRN adipose (FAT), non-adipose (nFAT) tissue (collagen fibers) area. In SBRN, adipose tissue (FAT) ($r=0.956$, $p<0.001$) showed significant positive correlation with age (Figure 7) and non-adipose tissue (nFAT) ($r=0.303$, $p=0.103$) did not show significant correlation with age (Figure 8).

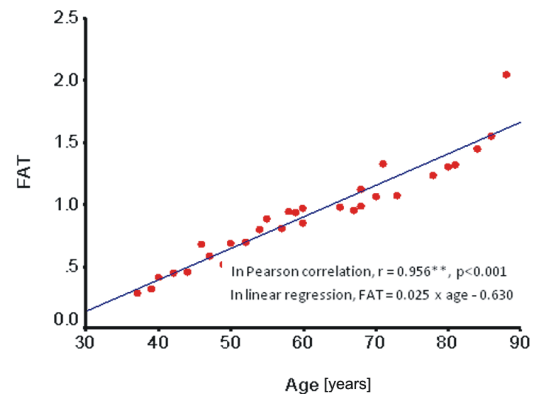


Figure 7 – Superficial branch of the radial nerve (SBRN) adipose tissue (FAT) deposition during aging process.

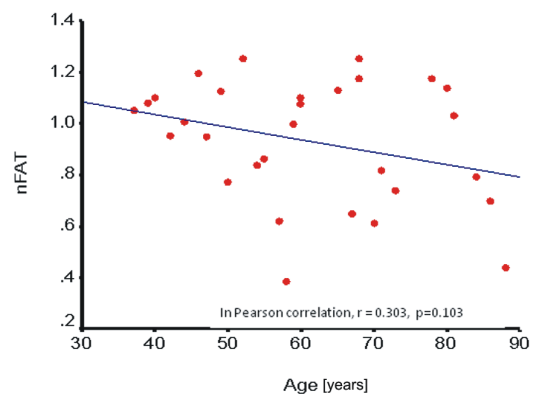


Figure 8 – Superficial branch of the radial nerve (SBRN) non-adipose tissue (nFAT) deposition during aging process.

Linear regression test

Since SBRN adipose tissue (FAT) showed significant positive correlation with age, linear regression line was drawn (Age-Independent sample, FAT-Dependent sample). We can predict the amount of adipose tissue present in an individual's SBRN non-fascicular area by using the formula ($\text{FAT} = 0.025 \times \text{age} - 0.630$) (Table 3).

Table 3 – SBRN's linear regression between age and adipose tissue (FAT)

Model	Predictors	Unstandardized coefficients		t	Significance
		B	Standard error		
1	(Constant)	-0.631	0.092	-6.819	$p<0.001$
	Age	0.025	0.001	17.265	

Dependent variable: FAT.

In all cases, the size of the individual fascicles was from 0.004 to 0.470 mm^2 (0.102 ± 0.003). In the majority of instances, the fascicular size (95%) was below 0.3 mm^2 .

Ultrasonography

We scanned 30 SBRN about 5 to 6 cm above the wrist, behind the brachioradialis tendon from 15 volunteers. The volunteers' age ranged from 21 to 56 years, the mean age and standard deviation (SD) were found to be 37.73 ± 11.31 . The SBRN's ultrasound total cross-sectional area ranged from 2 to 3.3 mm^2 (2.35 ± 0.09 , mean \pm SEM) on the right side and 2.1 to 3.1 mm^2 (2.41 ± 0.08) on the left side. There was no significant statistical difference between right and left side. Radial artery and accompanying veins lies deep and medial to SBRN (Figure 2). The SBRN shapes were subjectively assessed as flattened in all 15 cases. The transverse nerve size in females was smaller than in males. The SBRN had a bright echogenic texture with hypoechoic fascicles as other peripheral nerves (Figure 2). The number of visualized fascicles on US was comparable to those fascicles identified on histological sections.

Discussion

The fascicular organization of the peripheral nerve was one of the areas focused by morphologists during twentieth century [17]. Soon after, the neurosurgeons and the orthopedicians, who usually perform microsurgical interventions on peripheral nerves, realized its significance in the diagnosis and treatment of the nerve lesions [3]. Clinicians utilized the knowledge of fascicularisation, because of its importance in nerve repair after injury, especially in the elderly individuals.

Present study was focused on the non-fascicular connective tissue of the nerve and its changes during the aging process. Study on human sural nerve by Jacobs JM and Love S [18] has shown axonal degeneration and an increase in endoneurial collagen in the older age groups. Studies on rat tibial nerve and sciatic nerve have shown an accumulation of collagen, lipid droplets in the perineurium and increase nerve cross sectional area with aging [19, 20]. Studies on human sciatic nerve and radial nerve have revealed increased connective tissue and adipose tissue in older individuals [21, 22].

Various studies have shown that the amount of connective tissue varies in different peripheral nerves, even in different parts of the same nerve. The studies on dog recurrent laryngeal nerve and rat sciatic nerve showed a significant increase in non-fascicular cross sectional areas with increase in adipose tissue content [23, 24]. In the human facial nerve, the number of fascicles and the amount of connective tissue increased in the proximo-distal direction along its length, especially in the extratemporal part [25].

In the present study, the number of fascicles in SBRN ranged from 6 to 12. Folberg CR *et al.* [26] have reported the fascicle count of the SBRN at wrist showed an average of 6.6. Sunderland S [27] reported three 'funiculi' in the proximal 1.5 cm of the SBRN. Campero M *et al.* [28] have reported by microneurography that SBRN at the forearm is composed of only three fascicles.

The size of the individual fascicles of the SBRN ranged from 0.004 to 0.470 mm^2 (0.102 ± 0.003). In the majority of instances, the fascicular size (95%) was

below 0.3 mm^2 . Chakravarthy Marx S *et al.* [21] have reported the fascicular size of the radial nerve ranged from 0.01 to 0.92 mm^2 (0.22 ± 0.01) and (95%) of the fascicular size was below 0.6 mm^2 . O'Sullivan DJ and Swallow M [29] have reported the individual fascicles of the SBRN at distal forearm varied from 0.075 mm^2 to 0.690 mm^2 . On comparing these studies with the present study, the fascicle size reduces gradually from proximal to distal part of the peripheral nerve. Chakravarthy Marx S *et al.* [30] have reported the number of fascicles in SBRN ranged from 7 to 12. The present study's result regarding the number of fascicles (Nf) in SBRN above wrist confirms the findings of the previous study.

In the present study, SBRN's non-fascicular area was well developed in all cases. In elderly cases, the adipose tissue area was more in the non-fascicular area. In young cases, there was less adipose tissue in the non-fascicular area. However, we could not trace the data for the same parameter in the available literature for comparison. This may be the cause of poor outcome following nerve repair in elderly cases. The SBRN is mostly composed of sensory and sympathetic fibers in its fascicles. SBRN entrapment (Wartenberg's disease) can occur beneath the edge of brachioradialis (BR) tendon about 6 cm proximal to the radial styloid, pinched by scissoring effect of BR and extensor carpi radialis brevis (ECRB) [6, 9]. Mackinnon SE *et al.* [6] made a histologic assessment of SBRN from a patient with nerve compression. Histologic changes were confined to the region of the nerve compression. Connective tissue changes consisted of an increased thickness of the epineurium and perineurium. Nerve fiber changes consisted of Schwann cell pathology with marked thinning of the myelin noted in the myelinated fibers and evidence of degeneration and regeneration noted in the unmyelinated fiber population. Nerve fiber pathology was not uniform but varied from fascicle to fascicle in the compressed area. Visser LH [8] observed two patients with SBRN neuropathy in which one patient had an enlarged nerve; probably a neuroma and the other patient had a histologically proven Schwannoma.

A complete knowledge of the nerve fascicular and non-fascicular morphology is necessary for the diagnostic application of ultrasound, computed tomography (CT) scan and magnetic resonance imaging (MRI) as well as for its successful surgical nerve repair [8, 10]. Various authors have used ultrasound (US), computed tomography (CT) scan and magnetic resonance imaging (MRI) to diagnose the SBRN injury [7, 8, 10, 11].

Though various authors have commented on cross-sectional and fascicular areas of the SBRN, the exact anatomical reference value is scanty. The present data can be extrapolated for clinical use.

The study represents Indian population, which differs in physical build from the west. In very few cases, there was less adipose tissue in the non-fascicular area by histology. Some variation, which is not correlated with age or gender, however it may be correlated to Body Mass Index (BMI). In our study, we did not have measurements on BMI of these cadavers.

The SBRN (as vascularized nerve graft) and sural nerve grafts were used as the interposition grafts

between the two branches of the medial antebrachial cutaneous nerve and the median nerve. Histological evaluation demonstrated better regeneration across the SBRN (vascularized nerve graft) when compared to sural nerve [6]. Authors have also used SBRN for the nerve grafting in the upper limb [8, 13]. Misdirected axonal growth at the nerve repair site is a major reason for poor functional outcome usually seen after peripheral nerve transaction and repair. Abundant perineurial and epineurial tissue can lead to delay in revascularization of the graft tissue [14]. In peripheral nervous system (PNS), there is a variable amount of adipose tissue deposition in the interfascicular area along with collagen fibers. A larger amount of fat tissue makes microsurgical reparation of injured nerve more difficult and reduces the chance of nerve fiber regeneration. In nerve repair, axonal regeneration from distal segment to proximal segment was observed only when gaps between the fat cells were available [31, 32]. There are no published studies on this aspect of the SBRN. The information on cross sectional area, fascicular area and fascicular pattern may be of use during selection of this nerve as nerve graft for a particular nerve with definite fascicular area and pattern. The presence of adipose tissue can also be considered as one of the factor for preventing nerve fiber regeneration. The increased interfascicular area with adipose tissue of SBRN associated with advancing age may lead to poor outcome after surgery due to obstacle for nerve fiber regeneration.

Dumanian GA *et al.* [31] have discussed the total cross-sectional area of the superficial branch of the radial nerve at distal forearm by ultrasonography showed 1 to 3 mm² (2±0.5, mean ± SD) in healthy individuals and our ultrasonography showed 2 to 3.3 mm² is comparable to this. The SBRN shapes were subjectively assessed as flattened in US was comparable to those shapes identified on histological sections. The SBRN had a bright echogenic texture with hypoechoic fascicles as other peripheral nerves.

☐ Conclusions

With advancing age, the changes in SBRN intra-neural anatomy was noticed in form of increased amount of adipose tissue in the interfascicular domains. These findings may help to explain poor prognosis with advancing age following repair. The number of visualized fascicles on US was comparable to those fascicles identified on histological sections. We could not measure the fascicular and non-fascicular areas (adipose and non-adipose area) of the SBRN by using US. Since, in histological study, we found that the cross section of SBRN non-fascicular area (Anonf) and the fascicular area (Af). Once we get the cross sectional area of the SBRN by US, we can calculate the cross sectional fascicular (Af) and non-fascicular area (Anonf) using the results of our histological study.

Acknowledgements

The authors thank K. Ramachandra Bhat, Professor of Anatomy, Kasturba Medical College, Manipal, Karnataka, India, for his valuable suggestions and guidance.

References

- [1] RIGAUD P, LAPIERRE F, *Review of the peripheral nerve*, Neurochirurgie, 2009, 55(4–5):360–374.
- [2] DAHLIN LB, *Nerve injuries*, Current Orthopaedics, 2008, 22(1):9–16.
- [3] GOLDBERG SH, JOBIN CM, HAYES AG, GARDNER T, ROSENWASSER MP, STRAUCH RJ, *Biomechanics and histology of intact and repaired digital nerves: an in vitro study*, J Hand Surg Am, 2007, 32(4):474–482.
- [4] CALFEE RP, SHIN SS, WEISS APC, *Neurolysis of the distal superficial radial nerve for dysaesthesia due to nerve tethering*, J Hand Surg Eur Vol, 2008, 33(2):152–154.
- [5] KANDENWEIN JA, RICHTER HP, ANTONIADIS G, *Is surgery likely to be successful as a treatment for traumatic lesions of the superficial radial nerve?*, Nervenarzt, 2006, 77(2):175–176, 179–180.
- [6] MACKINNON SE, DELLON AL, HUDSON AR, HUNTER DA, *Histopathology of compression of the superficial radial nerve in the forearm*, J Hand Surg Am, 1986, 11(2):206–210.
- [7] STUART RM, KOH ES, BREIDAHN WH, *Sonography of peripheral nerve pathology*, AJR Am J Roentgenol, 2004, 182(1):123–129.
- [8] VISSER LH, *High-resolution sonography of the superficial radial nerve with two case reports*, Muscle Nerve, 2009, 39(3):392–395.
- [9] STANDRING S (ed), *Gray's Anatomy: the anatomical basis of clinical practice*, 40th edition, Churchill Livingstone, Philadelphia, 2008, 829–856.
- [10] FORNAGE BD, *Sonography of peripheral nerves of the extremities*, Radiol Med, 1993, 85(5 Suppl 1):162–167.
- [11] MCCARTNEY CJ, XU D, CONSTANTINESCU C, ABBAS S, CHAN VW, *Ultrasound examination of peripheral nerves in the forearm*, Reg Anesth Pain Med, 2007, 32(5):434–439.
- [12] TUBIANA R, GILBERT A, *Surgery of disorders of the hand and upper extremity*. In: TUBIANA R (ed), *Tendon, nerve and other disorders, illustrated*, Taylor & Francis Press, London –New York, 2005, 105–124.
- [13] BOLSTER MAJ, BAKKER XR, *Radial tunnel syndrome: emphasis on the superficial branch of the radial nerve*, J Hand Surg Eur Vol, 2009, 34(3):343–347.
- [14] SUNDERLAND S, *Nerve injuries and their repair: a critical appraisal*, Churchill Livingstone, New York, 1991, 396.
- [15] GAMBLE M, WILSON I, *The Hematoxylin and Eosin*. In: BANCROFT JD, GAMBLE M (ed), *Theory and practice of histological techniques*, Churchill Livingstone, New York, 2002, 125–138.
- [16] JONES ML, *Connective tissues and stains*. In: BANCROFT JD, GAMBLE M (ed), *Theory and practice of histological techniques*, 5th edition, Churchill Livingstone, New York, 2002, 149–153.
- [17] DJORDJEVIĆ-CAMBA V, MRVALJEVIĆ D, *Fascicularization of peripheral nerves*, Srp Arh Celok Lek, 1973, 100(4):547–555.
- [18] JACOBS JM, LOVE S, *Qualitative and quantitative morphology of human sural nerve at different ages*, Brain, 1985, 108(Pt 4):897–924.
- [19] AZCOITIA I, LEONELLI E, MAGNAGHI V, VEIGA S, GARCIA-SEGURA LM, MELCANGI RC, *Progesterone and its derivatives dihydroprogesterone and tetrahydroprogesterone reduce myelin fiber morphological abnormalities and myelin fiber loss in the sciatic nerve of aged rats*, Neurobiol Aging, 2003, 24(6):853–860.
- [20] CEBALLOS D, CUADRAS J, VERDÚ E, NAVARRO X, *Morphometric and ultrastructural changes with ageing in mouse peripheral nerve*, J Anat, 1999, 195(Pt 4):563–576.
- [21] CHAKRAVARTHY MARX S, KUMAR P, DHALAPATHY S, PRASAD K, ANITHA MARX C, *Microanatomical and immunohistochemical study of the human radial nerve at the antecubital fossa*, Ann Anat, 2009, 191(4):389–398.
- [22] SLADJANA UZ, IVAN JD, BRATISLAV SD, *Microanatomical structure of the human sciatic nerve*, Surg Radiol Anat, 2008, 30(8):619–626.
- [23] BARKMEIER JM, LUSCHEI ES, *Quantitative analysis of the anatomy of the epineurium of the canine recurrent laryngeal nerve*, J Anat, 2000, 196(Pt 1):85–101.
- [24] TILLET RL, AFOKE A, HALL SM, BROWN RA, PHILLIPS JB, *Investigating mechanical behaviour at a core-sheath interface in peripheral nerve*, J Peripher Nerv Syst, 2004, 9(4):255–262.

- [25] CAPTIER G, CANOVAS F, BONNEL F, SEIGNARBIEUX F, *Organization and microscopic anatomy of the adult human facial nerve: anatomical and histological basis for surgery*, *Plast Reconstr Surg*, 2005, 115(6):1457–1465.
- [26] FOLBERG CR, ULSON H JR, SCHEIDT RB, *The superficial branch of the radial nerve: a morphologic study*, *Res Bras Ortop*, 2009, 44(1):69–74.
- [27] SUNDERLAND S, *Nerve and nerve injuries*, 2nd edition, Churchill Livingstone, Edinburgh, 1978, 827–828.
- [28] CAMPERO M, SERRA J, OCHOA JL, *Peripheral projections of sensory fascicles in the human superficial radial nerve*, *Brain*, 2005, 128(Pt 4):892–895.
- [29] O'SULLIVAN DJ, SWALLOW M, *The fiber size and content of the radial and sural nerves*, *J Neurol Neurosurg Psychiatry*, 1968, 31(5):464–470.
- [30] CHAKRAVARTHY MARX S, KUMAR P, DHALAPATHY S, ANITHA MARX C, D'SOUZA AS, *Distribution of sympathetic fiber areas of radial nerve in the forearm: an immunohistochemical study in cadavers*, *Surg Radiol Anat*, 2010 Mar 14 [Epub ahead of print].
- [31] DUMANIAN GA, MCCLINTON MA, BRUSHART TM, *The effects of free fat grafts on the stiffness of the rat sciatic nerve and perineural scar*, *J Hand Surg Am*, 1999, 24(1):30–36.
- [32] LUTZ BS, MA SF, CHUANG DC, CHAN KH, WEI FC, *Interposition of a pedicle fat flap significantly improves specificity of reinnervation and motor recovery after repair of transected nerves in adjacency in rats*, *Plast Reconstr Surg*, 2001, 107(1):116–123.

Corresponding author

Chakravarthy Marx S, PhD, Department of Anatomy, Kasturba Medical College, Manipal, 576104 Karnataka, India; Phone +91 9739867221, e-mail: marxmanipal@gmail.com

Received: March 27th, 2010

Accepted: September 25th, 2010