

CASE REPORT

Anomalous branching pattern of the external carotid artery: a case report

MAMATHA T, RAJALAKSHMI RAI, LATHA V. PRABHU,
GAVISHIDDAPPA A. HADIMANI, JIJI PJ, PRAMEELA MD

*Department of Anatomy,
Kasturba Medical College (Manipal University),
Mangalore, Karnataka, India*

Abstract

Variations in the branching pattern of the external carotid artery (ECA) are well known and documented. The variation in the present case was compared with those reported before. An anomalous unilateral variation in the branching pattern of the left ECA was observed in a male embalmed cadaver. In this case, the ECA gives a direct branch directly to the submandibular salivary gland, a thyrolingual trunk, an auriculo-occipital trunk and a facial artery with an unusual course. The embryogenesis of such a combination of anomalies is not clear, but the anatomic consequences may have important clinical implications. Anatomical knowledge of the origin, course, and branching pattern of the external carotid artery will be useful to surgeons when ligating the vessels during head and neck surgeries.

Keywords: external carotid artery, thyrolingual trunk, occipitoauricular trunk, facial artery, glandular branch, submandibular salivary gland.

Introduction

External carotid artery (ECA) is the chief artery of head and neck region. It begins lateral to upper border of thyroid cartilage, in level with disc between the third and fourth cervical vertebrae [1]. It has eight named branches distributed to the head and neck [1].

The branches of the ECA may arise irregularly or be diminished or increased in number. When increased in number (by two or more), they arise as a common stem, or by the addition of branches not usually derived from this artery, such as the sterno-mastoid branch of the superior thyroid or occipital artery [2].

Variations in some of the branches of the external carotid are as follows: the lingual arises from a common trunk with the facial (linguofacial trunk) in 10–20% of cases; a rare combination branch of the external carotid is a thyro-linguo-facial trunk [3].

Zümre Ö *et al.*, report about the presence of linguofacial trunk, thyro-lingual trunk, thyro-linguo-facial trunk, and occipito-auricular trunk in the human fetuses [4].

In a case report by Gluncic V *et al.*, the right ECA branched directly at its origin into the superior thyroid, lingual and occipital arteries, and the distal part of the external carotid artery [5].

Unusual branches of the facial artery have also been reported by Bergmann RA *et al.* [3].

In a case report by Nayak S, facial artery originated as high as in the parotid [6].

The present case reports about variation in the branching pattern of ECA, high origin of facial artery as well as direct origin of glandular branch to the submandibular gland from the external carotid artery instead of facial artery.

Material, Methods and Results

During routine dissection for undergraduate students in the Department of Anatomy, Kasturba Medical College, Mangalore, affiliated to Manipal University, an unusual branching pattern of the left external carotid artery was observed in a male cadaver.

It was noted that bifurcation of the CCA was 2.2 cm above the superior border of the lamina of the thyroid cartilage. Both superior thyroid artery and the lingual artery were arising from a common trunk at the level of bifurcation of CCA. An anomalous glandular branch (Figure 1) was seen arising directly from the ECA, on the medial aspect, 1.2 cm above the bifurcation of CCA. It exclusively supplied the submandibular salivary gland. Posteriorly, at the same level another auriculo-occipital trunk (*) bifurcated into posterior auricular and the occipital arteries. The length of this trunk was 0.9 cm. Facial artery was given off at the angle of the mandible from the anterior aspect of ECA above the glandular branch.

All the above-mentioned branches were superior to the level of posterior belly of digastric suggesting that these are the contents of digastric triangle. The origin of facial artery was 2.9 cm above the bifurcation of CCA and 1.5 cm superior to the posterior belly of digastric. The artery coursed along the inferior border of the mandible. During its course, it did not make its usual characteristic loop around the submandibular gland and did not give any branches to the gland. It directly passed upwards to enter the face at the antero-inferior angle of the masseter.

At the antero-inferior angle of the masseter, submental artery (Figure 1) was given off. Further course of the ECA was as documented in classical textbooks.

It terminated by dividing into the maxillary artery and the superficial temporal artery behind the neck of the mandible.

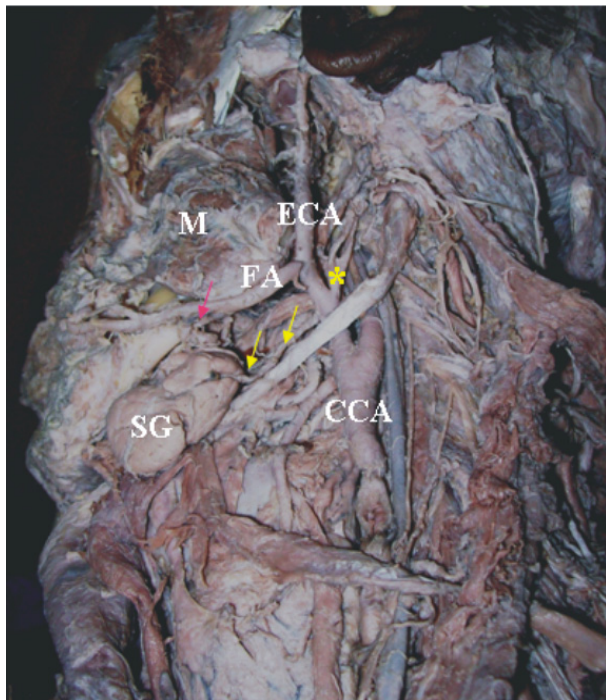


Figure 1 – Dissection of the left side of head and neck showing the branching pattern of external carotid artery. Facial artery (FA) is arising at the level of angle of mandible. Yellow arrows indicating the glandular branch to submandibular gland directly from ECA. Pink arrows indicating submental branch of facial artery. ECA: External carotid artery; FA: Facial artery; M: Masseter; SG: Submandibular gland; CCA: Common carotid artery; * – Auriculo-occipital trunk.

Discussion

Variations in the branching pattern of the external carotid artery have been reported earlier by several authors. Zümre Ö *et al.* observed a linguo-facial trunk in 20% of the cases, a thyro-lingual trunk in 2.5%, a thyro-linguo-facial trunk in 2.5%, and an occipito-auricular trunk in 12.5% of the cases in the human fetuses studied by them [4].

Anil A *et al.* reported a case where the occipital and the posterior auricular arteries arose from a short common trunk [7].

Gluncic V *et al.* have observed a right external carotid artery, which branched directly at its origin into the superior thyroid, lingual and occipital arteries and the distal part of the external carotid artery [5].

The distal part gave rise to the right facial artery and finally bifurcated into the maxillary and superficial temporal arteries. The right posterior auricular artery arose from the right occipital artery. Anu VR *et al.* have found glandular branches directly given off from the ECA to the parotid salivary gland [8]. They also report about unusual origin and course of the right facial artery which arose from the ECA just above the angle of the mandible and passed directly on to the face crossing the In the present case, the left ECA had a thyro-lingual

trunk, an auriculo-occipito trunk, facial artery with an unusual course, and an anomalous direct glandular branch to the submandibular salivary gland posterior border of the mandibular ramus, which is similar to the present case.

Unusual branches of the facial artery include an ascending pharyngeal, superior laryngeal, tonsillar, sternocleidomastoid, maxillary, or sublingual. The facial artery may replace the lingual artery and supply the sublingual gland [3].

Unilateral agenesis of facial artery, which was compensated by the giant transverse facial artery, is reported by Tubbs RS *et al.* [9].

Mohandas RKG *et al.* report about a similar case of direct glandular branches from the ECA to the submandibular gland [10].

Li L *et al.* reveal that branches to submandibular gland could also be derived from external carotid artery [11].

The awareness of direct glandular branch to the submandibular gland from the external carotid artery may prove to be of paramount importance for surgeons while performing submandibulectomy.

Conclusions

Anatomical knowledge of variations in the branching pattern of the external carotid artery will be useful in angiographic studies, transcatheter embolization procedures and in surgical procedures of the head and neck region. Additionally, course of the normal and variant facial artery is important in surgeries involving facial flaps.

References

- [1] STANDRING SUSAN, JOHNSON D, ELLIS H, COLLINS P (eds), *Gray's Anatomy*, 39th edition, Churchill Livingstone, London, 2005, 543–544.
- [2] BERGMAN RA, THOMPSON SA, AFIFI AK, SAADEH FA, *Compendium of human anatomic variations*, Urban and Schwarzenberg, Baltimore, 1988, 65.
- [3] BERGMAN RA, AFIFI AK, MIYAUCHI R, *Illustrated encyclopedia of human anatomic variation. Opus II. Cardiovascular system: arteries: head, neck, and thorax*, <http://www.anatomyatlases.org/>, Accessed 2009.
- [4] ZÜMRE Ö, SALBACAK A, ÇIÇEKÇİBAŞI AE, TUNCER I, SEKER M, *Investigation of the bifurcation level of the common carotid artery and variations of the branches of the external carotid artery in human fetuses*, *Ann Anat*, 2005, 187(4):361–369.
- [5] GLUNCIC V, PETANJEK Z, MARUSIC A, GLUNCIC I, *High bifurcation of common carotid artery, anomalous origin of ascending pharyngeal artery and anomalous branching pattern of external carotid artery*, *Surg Radiol Anat*, 2001, 23(2):123–125.
- [6] NAYAK S, *Abnormal intra-parotid origin of the facial artery*, *Saudi Med J*, 2006, 27(10):1602.
- [7] ANIL A, TURGUT HB, PEKER T, PELIN C, *Variations of the branches of the external carotid artery*, *Gazi Med J*, 2000, 11(2):81–83.
- [8] ANU VR, PAIMM, RAJALAKSHMI R, LATHA VP, RAJANIGANDHAV, D'COSTA S, *Clinically-relevant variations of the carotid arterial system*, *Singapore Med J*, 2007, 48(6):566–569.
- [9] TUBBS RS, SALTER EG, OAKES WJ, *Unilateral agenesis of the facial artery with compensation by a giant transverse facial artery*, *Folia Morphol (Warsz)*, 2005, 64(3):226–228.

- [10] MOHANDAS RKG, RODRIGUES V, SHAJAN K, KRISHNASAMY N, RADHAKRISHNAN AM, *Unilateral high origin of facial artery associated with a variant origin of the glandular branch to the submandibular gland*, International Journal of Anatomical Variations, 2009, 2:136–137.
- [11] LI L, GAO XL, SONG YZ, XU H, YU GY, ZHU ZH, LIU JM, *Anatomy of arteries and veins of submandibular glands*, Chin Med J (Engl), 2007, 120(13):1179–1182.

Corresponding author

Rajalakshmi Rai, Department of Anatomy, Kasturba Medical College, 575004 Mangalore, Karnataka, India; Fax 08242428183, e-mail: rajalakshmi.rai@manipal.edu

Received: August 14th, 2009

Accepted: June 28th, 2010