

ORIGINAL PAPER

Morphology of the medial meniscus of the knee in human fetuses

B. V. MURLIMANJU¹⁾, NARGA NAIR²⁾, MANGALA M. PAI¹⁾,
A. KRISHNAMURTHY¹⁾, X. CHANDRA PHILIP²⁾

¹⁾Department of Anatomy,
Kasturba Medical College, Manipal University, Mangalore, India

²⁾Department of Anatomy,
Kasturba Medical College, Manipal University, Manipal, India

Abstract

Objectives: The objectives were to study the morphology of the medial menisci in human fetal knee joints and to verify the developmental etiology of the discoid meniscus. **Material and Methods:** The study was carried out on 106 fetal knee joints and the morphological variants of the shapes of the medial menisci were macroscopically noted and classified. **Results:** From our observations, 46.2% of the medial menisci were crescentic shaped, 23.6% were sided V-shaped, 13.2% had sided U-shape, 9.4% of them were sickle shaped, and 7.5% were C-shaped. In 54.71% of the cases, the medial meniscus shape was different on either side knees of the fetuses. No discoid medial menisci were seen. **Conclusions:** The majority of the knees were having crescentic or semi lunar shaped medial menisci and the shape of the medial meniscus was different on right and left side knee joint of the fetuses in more than fifty percent of the cases. The observations favor Kaplan's theory, as there were no discoid medial menisci observed from the fetuses of various gestational ages. Even the youngest fetus (CRL 88 mm, 14 weeks of gestation) exhibited the medial tibial plateau incompletely covered by the menisci, which did not exhibit the discoid shape. The discoid meniscus must be an abnormal finding and is due to abnormal morphogenesis.

Keywords: knee, medial menisci, shape, side, fetus.

Introduction

The frequency and severity of knee injuries in organized and recreational sports and in industry are well documented. In American football, knee is the most commonly injured joint. Stocker B *et al.*, in 1997, reported that meniscal injuries accounted for 12% of all football knee injuries in a recent high school injury survey [1]. The snapping knee syndrome is usually related with the type of the meniscus or to the presence of a tear of the meniscus. This syndrome appears more often in children and young adolescents [2–5].

The menisci are two crescentic lamellae, which serve to deepen the surfaces of the articular fossae of the head of the tibia for reception of the condyles of the femur [6–8]. The menisci load-share and reduce contact stresses across the joint. The medial meniscus (MM) has a role in joint stability. In an ACL-deficient knee, the posterior horn of the medial meniscus provides passive stability, and medial meniscectomy leads to a 58% increase in anterior translation at 90° of flexion [9, 10]. There are many studies on general anatomy of the menisci of the adults [11, 12]. Although anomalous shapes of the menisci of the adults have been reported before [13–19], the gross morphology of the menisci of the newborns have been poorly studied.

The anatomic abnormalities and variations of the intra articular structures of the knee joint have recently become significant because of the new imaging techniques such as computed tomography and magnetic resonance imaging. Textbooks of surgery all note that

injuries are sustained more often by the medial than by the lateral meniscus and they give the proportion variously as 4:1, 5:1 or even up to 20:1 [20]. Also, the investigation of these variants is important in order to define the morphological features for clinical diagnosis and for surgical procedures [21].

To clarify the possible developmental origin of the etiology, sequential observations and quantitative analyses of normal development of the knee joint morphology in the prenatal periods are necessary; however, such studies are limited regarding human fetuses.

The aim of the present paper is to study the gross morphology of the medial menisci in human fetuses and to verify the developmental etiology of the discoid meniscus.

Material and Methods

To carry out this study, human fetal cadavers, which were available in the Anatomy Laboratory, were utilized. The study included a total number of 106 fetal knee joints. All specimens were preserved in 10% formaldehyde solution and they had no musculoskeletal system anomalies. The knee joints included 53 right and 53 left specimens (from 27 female and 26 male fetuses). The age of the fetuses (Table 1), ranged from 14 to 34 weeks of gestation (88 to 259 mm in crown-rump length). Each knee was taken as a separate sample and not as one of a pair of samples in a fetus. This therefore gave 106 knees for the analysis.

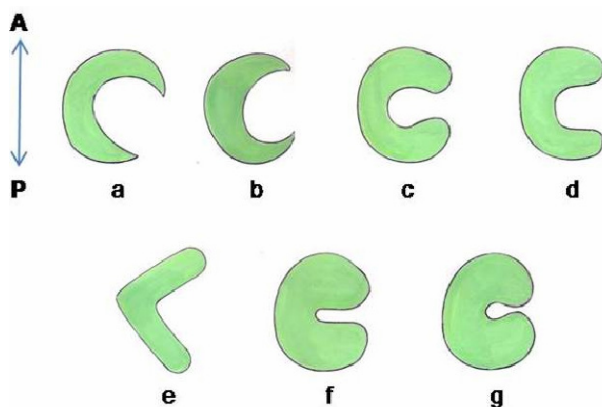
Table 1 – Showing the different gestational ages of the fetuses used in the present study (n=53)

Age [week]	≤15	16–20	21–25	26–30
CRL [mm]	≤125	126–152	153–199	≥200
No. of fetuses	2	7	24	20

CRL – crown rump length.

After the dissection of skin and muscles, the approach to the menisci was performed, opening anteriorly by a longitudinal incision on each side of the joint capsule, cutting the patellar ligament and the collateral ligaments transversely. In order to expose the menisci clearly, the joint capsule and the intra articular ligaments were cut, and the condyles were circumferentially detached from their soft tissue attachments and removed, exposing the tibial plateau. All dissections were performed in a systematic fashion and data were recorded on a standardized collection sheet.

Morphological variants of the shapes of the menisci were macroscopically noted and classified. The medial menisci (MMs) were sub grouped as sickle shaped, sided U shaped, sided V-shaped, crescentic shaped and C-shaped (Figure 1, a–g).

**Figure 1 – Diagram showing the various shapes of the menisci in fetuses: (a) crescentic-shaped; (b) sickle-shaped; (c) C-shaped; (d) sided U-shaped; (e) sided V-shaped; (f) incomplete discoid; (g) complete discoid (A – anterior, P – posterior).**

When the meniscus covers the tibial plateau circularly, the meniscus is said to be discoid type. The menisci, which had thin anterior and posterior horns and a thin body, were defined as the crescentic (semilunar) type. The menisci, which had thick anterior and posterior horns and a thick body, were named as the discoid type. The menisci, which had thin anterior and posterior horns and a thick body, were defined as the sickle-shaped type. The menisci, which resembled as sided U, sided V and C were named as side U, sided V and C-shaped, respectively.

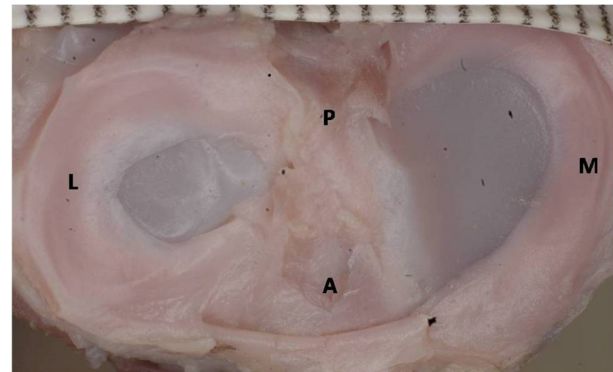
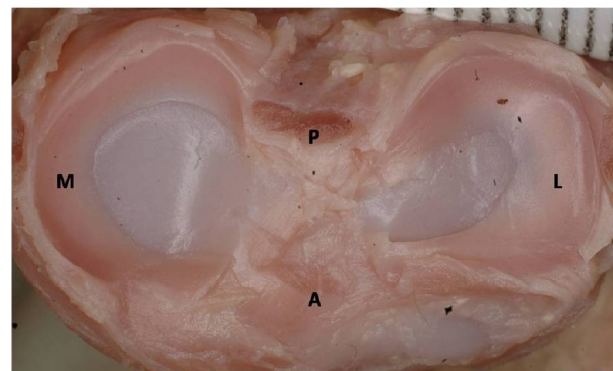
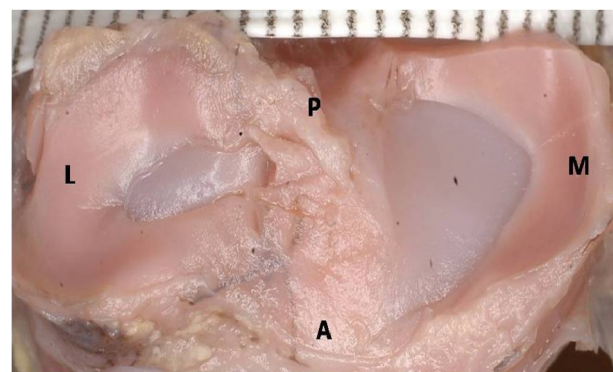
Results

Five morphological types of the shape of menisci were determined. From our observations, 46.2% of the MM were crescentic-shaped, 23.6% of the MM were sided V-shaped, 13.2% of the MM had sided U-shape, 9.4% of the MM were sickle-shaped and 7.5% of

the MM were C-shaped (Table 2, and Figures 2–6). In 54.71% of the cases, the medial meniscus shape was different on either side knees. No discoid medial menisci were seen.

Table 2 – Showing the incidence of different shapes of medial menisci (n=106)

Shape	Total no. (percentage)
Crescentic	49 (46.2%)
Sided V	25 (23.6%)
Sided U	14 (13.2%)
Sickle	10 (9.4%)
C-shaped	8 (7.5%)
Discoid	Nil

**Figure 2 – Right tibial plateau showing crescentic-shaped medial meniscus of the fetus (M – medial meniscus, L – lateral meniscus, A – anterior, P – posterior).****Figure 3 – Left tibial plateau showing C-shaped medial meniscus of the fetus (M – medial meniscus, L – lateral meniscus, A – anterior, P – posterior).****Figure 4 – Right tibial plateau showing sickle-shaped medial meniscus of the fetus (M – medial meniscus, L – lateral meniscus, A – anterior, P – posterior).**

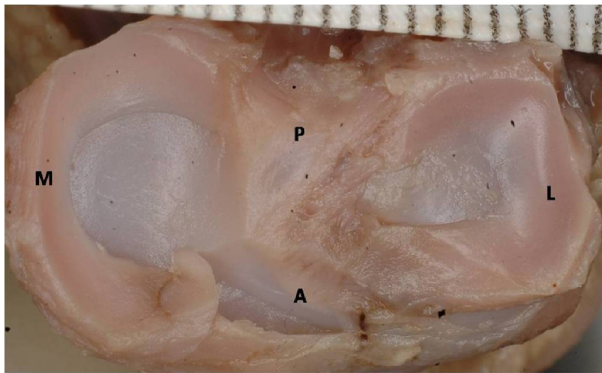


Figure 5 – Left tibial plateau showing sided U-shaped medial meniscus of the fetus (M – medial meniscus, L – lateral meniscus, A – anterior, P – posterior).

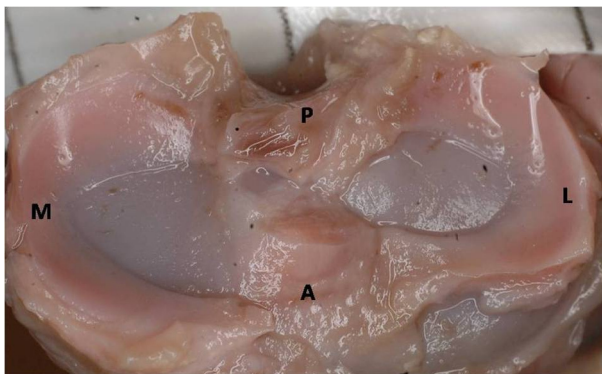


Figure 6 – Left tibial plateau showing sided V-shaped medial meniscus of the fetus (M – medial meniscus, L – lateral meniscus, A – anterior, P – posterior).

Discussion

Meniscal injuries in children and adolescents are being seen with increased frequency [21]. Meniscal tears are typically traumatic injuries in adolescents. The surgeries are done more for the medial meniscus than its counterpart since medial meniscal tears are more common than lateral. In meniscal allograft transplantation, it has been stated that providing a meniscal allograft that matches the size and shape of the meniscus to the recipient's knee is the responsibility of the tissue bank providing the graft [11]. Injuries to the meniscus are common in work, sports and everyday activities and can be disabling. Another pathological finding of the menisci of the children is discoid meniscus [14]. In primates, Parsons FG [22] noted that the medial meniscus always has a crescentic shape but that the lateral meniscus may have either a crescentic or a disc shape. Vallois H [23] confirmed this observation and studied the whole morphology of the knee joint in primates. Since then, numerous papers on the variations in the morphological characteristics of the human knee menisci have been published, revealing fundamental elements [16]. Fick R [24] described the medial meniscus as a half, two thirds or three-fourths ellipse, and stated that the lateral could be compared to an almost complete circle. In contrast, Charles CM [12] classified medial menisci both based on the relative size of the anterior and posterior cornua, and also on the degree of curvature.

In the present morphological study from 106 fetal knee joints, we observed that 46.2% of the MM had crescent-shape, 23.6% had sided V-shape, 13.2% of them had sided U-shape, 9.4% had sickle-shape and 7.5% of the MM had C-shape (Table 2). Also, we observed that, in majority of the knees the shape of the medial meniscus differs on right and left side of the individual fetus. Of all the fetuses, only 45.29% cases had the same shape on both sides. In the remaining 54.71% of the cases, the meniscus shape was different on either side. This gives the impression that the shape of the medial menisci on both side knee joints of the individual may not be the same. Other studies have also demonstrated considerable anatomic variability between right and left knees of the same person [25]. This difference of the shape may be due to the mesenchymal differentiation or variability of the vasculature early in embryonic life.

The discoid meniscus is the most common abnormal meniscal variant in children [2, 14, 26]. Additional anomalies of the meniscal shape have been classified as hypoplasia or hyperplasia. There are only a small number of reports have been published regarding the morphological changes of the meniscus during development in humans and it remains unclear how the discoid shape is established. Thus, the descriptive study on the normal development of the meniscus is necessary to better understand the abnormal morphology of the meniscus. The vast majority of discoid menisci are lateral, the discoid medial meniscus is extremely rare [16, 27]. The rare cases of it have been reported by the researchers as case reports [16, 27–29]. Le Minor JM [16] reported that the frequency of a discoid MM was estimated to be 0.009%. In the present study, from fetuses of different gestational ages, the discoid shaped medial meniscus was not observed in any of the specimens. The youngest fetus (CRL 88 mm, 14 weeks of gestation) exhibited the medial tibial plateau incompletely covered by the menisci, which did not exhibit the discoid shape.

There are not many studies available in the literature regarding the fetal anatomy of knee joint. Kale A *et al.* [21] studied 22 fetal knee joints, reports that 73% of the cadavers they studied had the same shape of menisci on each side. They also did not determine any discoid medial menisci. According to their observations, 18.18% of the MM were crescentic-shaped, 22.72% of the MM were sided V-shaped, 9.09% of the MM had sided U-shape, 36.36% of the MM were sickle-shaped and 13.63% of the MM were C-shaped. These observations are different from our findings and it might be because the racial variations do exist.

The variations of the shape of the menisci are explained by embryological meniscal development [16, 19]. The meniscus arises from the differentiation of mesenchymal tissue within the limb bud and it becomes a clearly defined structure by the eighth week of fetal development [13, 18, 30]. The menisci arise from the eccentric portions of the articular interzone during O'Rahilly stage 22, however until week 9 of development, they are not easily distinguishable [15].

On the other hand, during embryologic development, the blood supply of the meniscus enters from the periphery and extends throughout the entire width. However, by the ninth month of life, the central third will be avascular and by adulthood, only the peripheral one third will receive any blood supply [31]. At nine week's development, they are already perfectly formed. From that point on, the menisci grow at the same rate as the rest of the intra articular structures without undergoing any macroscopic structural changes [13] and assume the normal adult relationships with the rest of the knee by the 14th week [2, 32].

It has been speculated that the residual prenatal morphology of the meniscus may result in discoid meniscus after birth [13], although direct evidence has not been reported for this hypothesis. However, another report [5] stated that at no time in the development of the human fetus does medial meniscus assume a discoid form. In the present study from fetuses of different gestational ages, the discoid medial meniscus is not observed. This follows the report of Kaplan EB [5] and the discoid morphology may be an abnormality in the development of the fetus.

☞ Conclusions

The majority of the knees were having crescentic or semi lunar shaped medial menisci and the shape of the medial meniscus was different on right and left side knee joint of the fetuses in more than fifty percent of the cases. The observations favor Kaplan's theory, as there were no discoid medial menisci observed from the fetuses of various gestational ages. Even the youngest fetus (CRL 88 mm, 14 weeks of gestation) exhibited the medial tibial plateau incompletely covered by the menisci, which did not exhibit the discoid shape. The discoid meniscus must be an abnormal finding and is due to abnormal morphogenesis. We believe that our study will provide support to the neonatal medial meniscal anatomy, concerning with the surgical procedures and arthroscopy of the knee joint.

Acknowledgements

We gratefully acknowledge the contribution made to our knowledge of the meniscus morphology by Professor Shakuntala R. Pai and collaborators. Our thanks also to Mr. Ganesh Kini for typing this manuscript.

References

- [1] BRINDLE T, NYLAND J, JOHNSON DL, *The meniscus: review of basic principles with application to surgery and rehabilitation*, J Athl Train, 2001, 36(2):160–169.
- [2] KELLY BT, GREEN DW, *Discoid lateral meniscus in children*, Curr Opin Pediatr, 2002, 14(1):54–61.
- [3] WOODS GW, WHELAN JM, *Discoid meniscus*, Clin Sports Med, 1990, 9(3):695–706.
- [4] WATANABE M, TAKEDA S, IKEUCHI H, *Atlas of arthroscopy*, Igaku Shoin, Tokyo, 1969.
- [5] KAPLAN EB, *Discoid lateral meniscus of the knee joint*, Bull Hosp Joint Dis, 1955, 16(2):111–124.
- [6] SNELL RS, *Clinical anatomy by regions*, 8th edition, Lippincott, Williams & Wilkins, Philadelphia, 2008, 629–634.
- [7] STANDRING S (ed), *Gray's Anatomy. The anatomical basis of clinical practice*, 39th edition, Elsevier, London, 2006, 1476–1487.
- [8] MOORE KL, DALLEY AF, *Clinically oriented anatomy*, 4th edition, Lippincott, Williams & Wilkins, Philadelphia, 1999, 690–699.
- [9] LEVY IM, TORZILLI PA, WARREN RF, *The effect of medial meniscectomy on anterior-posterior motion of the knee*, J Bone Joint Surg Am, 1982, 64(6):883–888.
- [10] SHOEMAKER SC, MARKOLF KL, *The role of the meniscus in the anterior-posterior stability of the loaded cruciate-deficient knee. Effect of partial versus total excision*, J Bone Joint Surg Am, 1986, 68(1):71–79.
- [11] HAUT TL, HULL ML, HOWELL SM, *Use of roentgenography and magnetic resonance imaging to predict meniscal geometry determined with a three-dimensional coordinate digitizing system*, J Orthop Res, 2000, 18(2):228–237.
- [12] CHARLES CM, *On the menisci of the knee joint in American whites and negroes*, Anat Rec, 1935, 63:355–364.
- [13] TENA-ARREGUI J, BARRIO-ASENSIO C, VIEJO-TIRADO F, PUERTA-FONOLLÁ J, MURILLO-GONZÁLEZ J, *Arthroscopic study of the knee joint in fetuses*, Arthroscopy, 2003, 19(8):862–868.
- [14] KOCHER MS, KLINGELE K, RASSMAN SO, *Meniscal disorders: normal, discoid and cysts*, Orthop Clin North Am, 2003, 34(3):329–340.
- [15] MÉRIDA-VELASCO JA, SÁNCHEZ-MONTESINOS I, ESPIN-FERRA J, RODRÍGUEZ-VÁZQUEZ JF, MÉRIDA-VELASCO JR, JIMÉNEZ-COLLADO J, *Development of the human knee joint*, Anat Rec, 1997, 248(2):269–278.
- [16] LE MINOR JM, *Comparative morphology of the lateral meniscus of the knee in primates*, J Anat, 1990, 170:161–171.
- [17] IKEUCHI H, *Arthroscopic treatment of the discoid lateral meniscus. Technique and long-term results*, Clin Orthop Relat Res, 1982, 167:19–28.
- [18] KAPLAN EB, *Discoid lateral meniscus of the knee joint; nature, mechanism, and operative treatment*, J Bone Joint Surg Am, 1957, 39-A(1):77–87.
- [19] SMILLIE IS, *The congenital discoid meniscus*, J Bone Joint Surg Br, 1948, 30B:671–682.
- [20] LAST RJ, *The popliteus muscle and the lateral meniscus with a note on the attachment of the medial meniscus*, J Bone Joint Surg, 1950, 32B(1):93–99.
- [21] KALE A, KOPUZ C, EDÝZER M, AYDIN ME, DEMÝR M, YNCE Y, *Anatomic variations of the shape of the menisci: a neonatal cadaver study*, Knee Surg Sports Traumatol Arthrosc, 2006, 14(10):975–981.
- [22] PARSONS FG, *The external semilunar cartilage of the knee in the primates*, J Anat, 1900, 34:32.
- [23] VALLOIS H, *Etude anatomique d'articulation du genou chez les primates*, L'Abeille, Montpellier, 1914.
- [24] FICK R., *Handbuch der Anatomie und Mechanik der Gelenke unter Berücksichtigung der bewegenden Muskeln*. In: VON BARDELEBEN K (ed), *Handbuch der Anatomie des Menschen*, II Band, Teil I und III, Gustav Fischer Verlag, Jena, 1904, 354–358.
- [25] KOHN D, MORENO B, *Meniscus insertion anatomy as a basis for meniscus replacement: a morphological cadaveric study*, Arthroscopy, 1995, 11(1):96–103.
- [26] DAVIDSON D, LETTS M, GLASGOW R, *Discoid meniscus in children: treatment and outcome*, Can J Surg, 2003, 46(5):350–358.
- [27] TACHIBANA Y, YAMAZAKI YY, NINOMIYA S, *Discoid medial meniscus*, Arthroscopy, 2003, 19(7):E12–E18.
- [28] KIM SJ, KIM DW, MIN BH, *Discoid lateral meniscus associated with anomalous insertion of the medial meniscus*, Clin Orthop Relat Res, 1995, 315:234–237.
- [29] PINAR H, AKSEKI D, KARAOĞLAN O, OZKAN M, ULUÇ E, *Bilateral discoid medial menisci*, Arthroscopy, 2000, 16(1):96–101.
- [30] ANDRISH JT, *Meniscal injuries in children and adolescents: diagnosis and management*, J Am Acad Orthop Surg, 1996, 4(5):231–237.

- [31] CLARK CR, OGDEN JA, *Development of the menisci of the human knee joint. Morphological changes and their potential role in childhood meniscal injury*, J Bone Joint Surg Am, 1983, 65(4):538–547.
- [32] GEBHARDT MR, ROSENTHAL RK, *Bilateral lateral discoid meniscus in identical twins*, J Bone Joint Surg Am, 1979, 61(7):1110–1111.

Corresponding author

B. V. Murlimanju, Assistant Professor, MD, Department of Anatomy, Kasturba Medical College, Manipal University, Mangalore–575004, India; Phone +91 824 2211746, Fax +91 824 2421283, e-mail: flutesnowmm@gmail.com

Received: October 10th, 2009

Accepted: March 9th, 2010