

ORIGINAL PAPER

Retrieval analysis on dental implants biointegration phases

L. T. CIOCAN¹⁾, F. MICULESCU²⁾, M. MICULESCU²⁾, I. PĂTRAȘCU¹⁾

¹⁾*Prosthetic Technology and Dental Materials Department,
Faculty of Dental Medicine,
"Carol Davila" University of Medicine and Pharmacy, Bucharest*

²⁾*Material Science and Engineering Faculty,
Polytechnic University, Bucharest*

Abstract

This study was developed for evaluating the possible causes of losing primary stability of dental implants and to find possible associations between implant designs or implant surface treatment and the quality of surrounding bone tissue. There have been evaluated five CP (Commercial Products) titanium dental implants having different shapes and surface morphology. All the implants have been extracted between three and six month from insertion time due to the loosening of primary stability. The lost during three to six months of the primary stability for the dental implants evaluated at the interface was attributed to blood supply deficiency of the surrounding bone in case of the implants inserted in the anterior–lateral and lateral mandible bone, on implant surrounding bone with consecutive necrosis without leaving the possibility of normal healing both for the maxilla and the mandible, or to prosthetic load deficiency by applying forces out of the implant axis.

Keywords: dental implants, retrieval analysis, biointegration, ESEM.

Introduction

Prosthetic rehabilitation of different types of edentulous cases can be achieved by two types of dental prosthesis [1]:

- fixed, that assures a good comfort and quality of life for the patient;
- removable (hanged to the remaining dental and periodontal tissues).

The indication for one or another type of prosthetic restorations is made according to the number and topography of teeth and corresponding roots remained on the arch. The only possibility for assuring a clinical success of a fixed prosthetic restoration in the case of extended edentulous is elevating endosseous support by insertion of dental implants [2]. They have as aim the functional substitution of lost roots for assuring the functional endo-bone transmission of masticatory loads by the fixed prosthesis attached.

In order to be loaded (meaning their connection to a dental prosthesis that supports mastication loads) it is necessary for the implants to be biointegrated in the bone tissue, process that usually last for three to six month after implant insertion [3].

Wright during insertion it is necessary to assure an intimate contact in between receiving bone tissue and implant surface, this contact determining in the same time a certain stability named primary stability for the implant that can be measured using special devices. Due to the bone integration, the stability of the implant grows progressively, in six month (the period of healing and maturation of the bone tissue) reaching the maximum value (secondary stability due to new bone formation) when the implant can be safely loaded [4].

This study was developed for evaluating the possible causes of losing primary stability of dental implants and to find possible associations between implant designs or implant surface treatment and the quality of surrounding bone tissue.

Material and Methods

Five CP (Commercial Products) titanium dental implants having different shapes and surface morphologies have been evaluated:

1. One-piece blade-shape implant, having the surface prepared by machining (Figure 1).
2. One-piece screw-shape implant, having trapezoidal threads with high and long step, surface prepared by machining (Figure 2).
3. Two-pieces screw-shape implant, having trapezoidal threads with low and long step, surface prepared by machining and sandblasting (Figure 3).
4. Two-pieces screw-shape implant, having round threads with short step, surface prepared by machining and sandblasting (Figure 4).
5. Two-pieces screw-shape implant, having trapezoidal threads with short step, surface prepared by machining, sandblasting and acid etching (Figure 5).

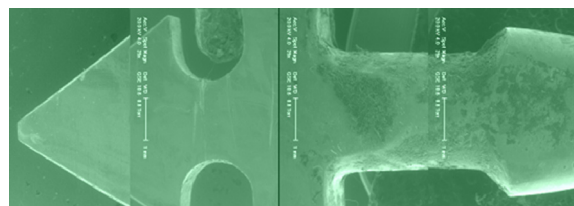


Figure 1 – One-piece blade-shape dental implant, with machined prepared surface.



Figure 2 – One-piece screw-shape dental implant, having trapezoidal threads with high and long step and machined prepared surface.



Figure 3 – Two-pieces screw-shape dental implant, having trapezoidal threads with low and long step, surface prepared by machining and sandblasting.




Figure 4 – Two-pieces screw-shape dental implant, having round threads with short step, surface prepared by machining and sandblasting.




Figure 5 – Two-pieces screw-shape dental implant, having trapezoidal threads with short step, surface prepared by machining, sandblasting and etched.

All the implants have been extracted between three and six month from insertion time due to the loosening of primary stability.

After explants extraction, each biological sample (couple implant–tissue) has been analyzed at the implant–bone tissue interface using ESEM electronic microscopy by using the secondary electron detector in water vapors (GSED). The use of ESEM-type scanning electron microscope offers the possibility of studying biomaterial tissue couples without special sample preparation and without damaging the interface between coupled elements [5].

Results

The “one-piece” blade-shape dental implant with machine-prepared surface has been inserted and maintained to the posterior region of the mandible for

four months. The macrographs obtained by scanning electron microscopy (Figure 6, left side), successively taken frame by frame starting with upper part of the implant, at 25× magnification, indicates that only a small part from the implant surface (located to the implant end) is covered by tissue. The right side of Figure 6 is represented by micrographs of a side image and represents a morphologic analysis obtained by secondary electrons detector in water vapor medium at 100× and 1000× magnification depending on detail dimensions (biologic elements: dental implant–tissue interface). In these micrographs, it can be noticed a decreased mitotic activity to the tip of blade implant.

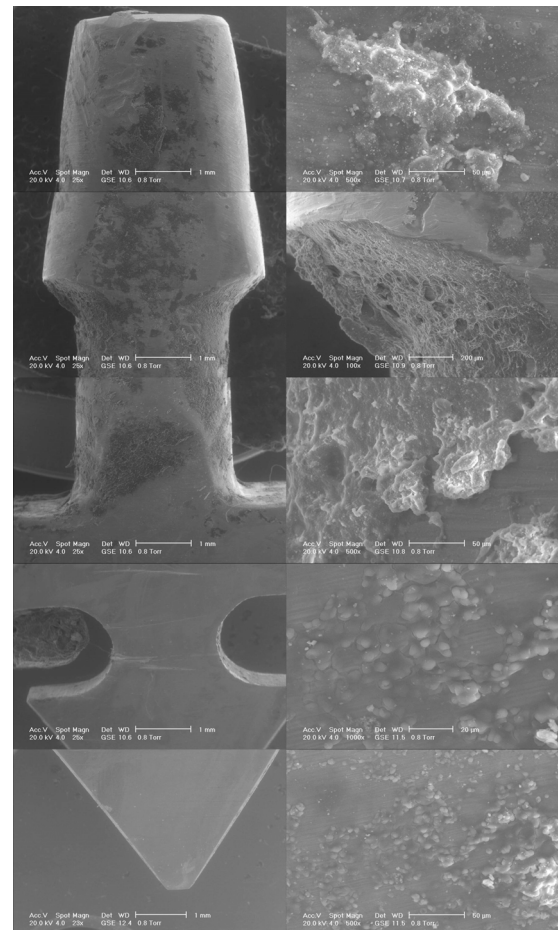


Figure 6 – SEM images of one-piece blade-shape dental implant, with machined prepared surface.

The one-piece screw shape dental implant, having trapezoidal threads with high and long step and machined-prepared surface (Figure 7) has been inserted and maintained in the anterior side of alveolar bone for three months. The macrographs obtained using scanning electron microscopy (Figure 7, left side); successively taken frame-by-frame starting with upper part of the implant, at 25× magnification, indicate a large surface of the implant covered by bone tissue in intimate contact with implant threads. The nearby images obtained using secondary electrons detector in water vaporous medium (Figure 7, right side), are indicating new bone and matured bone in intimate contact with the implant.

The two-pieces screw-shape dental implant (Figure 8) having trapezoidal threads with low and long step,

surface prepared by machining and sandblasting has been inserted, immediately loaded and maintained to the anterior level of maxillary bone for a six months period. The macrographs obtained by SEM (Figure 8, left side), successively taken frame-by-frame starting with upper part of the implant at 21× magnification indicate an implant surface uniformly covered by bone tissue. The nearby images obtained using secondary electron detector in water vaporous environment (Figure 8, right side) indicate a new-bone tissue with a high-grade of maturation well-fitted on implant surface.




Figure 7 – SEM images of one-piece screw-shaped dental implant, having trapezoidal threads with high and long step and machined prepared surface.

The two-pieces screw-shaped dental implant, having round threads with short step and surface prepared by machining and sandblasting have been inserted and maintained under the gum to the lateral level of the mandible bone for a four-month period.

The macrographs obtained by SEM (Figure 9, left side), successively taken frame by frame starting with upper part of the implant at 11×, 25× and 100× magnification indicate an implant surface covered by bone only to the top of the implant at level of the discharging channels.

The nearby images (Figure 9, right side) obtained using secondary electrons detector in water vapors environment, indicate a new bone formation with a low differentiation and maturation. The slow-cell metabolic activity suggests that the cause of failure in primary stability of this implant is the deficiency of irrigation and blood supply of the surrounding bone.

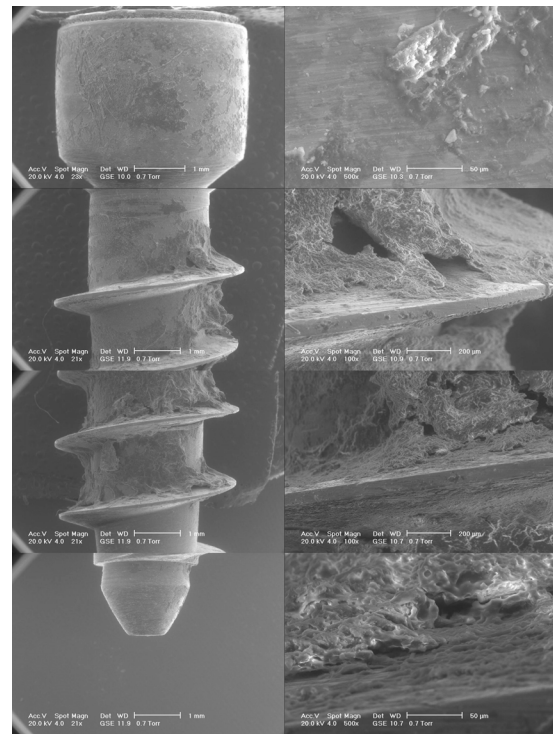


Figure 8 – SEM images of two-pieces screw-shaped dental implant, having trapezoidal threads with low and long step, surface prepared by machining and sandblasting.




Figure 9 – SEM images of two-pieces screw-shaped dental implant, having round threads with short step and surface prepared by machining and sandblasting.

The two-pieces screw-shape dental implant, having trapezoidal threads with short step and a surface prepared by machining, sandblasting and acid etch (Figure 10), has been inserted and maintained under the gum at the anterior-lateral region of the mandible bone for a nine-week period.

The macrographs obtained by scanning electron microscopy (Figure 10, left side), successively taken frame-by-frame starting with upper part of the implant at 25 \times magnification indicate a clean implant surface, uncovered by bone tissue.

The nearby images (Figure 10, right side) obtained using secondary electrons detector in water vaporous environment, shows cells islands that are groping to the tip of the implant, cells that have a moderate metabolic activity.




Figure 10 – SEM images of two-pieces screw-shape dental implant, having trapezoidal threads with short step and a surface prepared by machining, sandblasting and acid etched.

Discussion

The one-piece blade shape dental implant, with machined prepared surface (Figure 1) is indicated for being used in the posterior region of the mandible where the morphology of the alveolar bone is in majority of cases a narrow shape [6]. At this level, the value of bone density is elevated due to the high quantity of cortical bone present, less irrigated through Havers channels, and having a slower metabolism [7, 8].

The surgical technique used for insertion of blade

implant is percussion, with previous longitudinal osteotomy at the level of alveolar ridge. The technique of insertion by percussion does not permit a rigorous check of the compression force between implant and surrounding bone [9]. To the upper part of the implant, where the surface was machine-prepared, there are remains of the new formatted bone, but with low degree of maturation, and in the lower part, where the implant was prepared by plastic deformation, there is a lack of new formatted tissue. At this level, the low density of mesenchymal cells on the surface unit indicates a low metabolic activity [10] (Figure 6). It appears that failure in retention of this implant was only due to the compression and to the lack of irrigation of the cortical bone where it was inserted. Similar results were obtained in other studies [11].

The one-piece screw-shape dental implant, having trapezoidal threads with high and long step and machined prepared surface (Figure 2) is indicated for insertion in a bone that has a lower density value, as maxillary bone has [12]. This type of bone has marrow-bone consistency, has more blood vessels than the mandible, more cells and a higher metabolic activity [13]. The two-pieces implant is usually loaded immediately after insertion by a crown settled upon it. For aesthetic reasons it is indicated for the anterior side of the maxillary alveolar ridge [14].

The surgical technique for insertion of this shape of implant is by screwing, after realizing in the bone a channel with the same diameter as the inner side of implant threads [15]. In the case of screw implant, having long step it is not necessary to taper the walls of artificial alveoli, due to the indication for insertion in a spongy bone that has a low density [16]. The compression force value on the bone can be easily controlled using a dynamometric wrench [17].

The new bone formatted and matured in intimate contact with the implant (Figure 7) suggests a bio-mechanical failure for this implant (due to deficient load applied on it). Another reason for this failure could be the insufficient preparation of the implant surface [18, 19] made only by machining, although the quality of the new formatted bone and the high-metabolic activity of the cells around the implant are opposite factors of this presumption.

The two-pieces screw-shape dental implant, having trapezoidal threads with low and long step, surface prepared by machining and sandblasting (Figure 3), is also indicated for being inserted in maxillary bone that has lower density value. Being composed from two-pieces, it is first indicated to be used in lateral side of maxillae, where, due to intense mechanical loads, prosthetic appliances are made only after six months from insertion [20].

The surgical technique for insertion of screw-shape implant is, of course, by screwing after realizing in the bone a channel with the same diameter as the inner side of implant threads [15]. Even for this case, the bone tapering it is not necessary and the compression force can be measured.

The high-grade of differentiation and the morphology

of the covering bone tissue from the upper part of the implant and also the radical reduction of these transformations from the lower part of the implant would indicate a technique deficiency (over compression) for the lack of bone integration of this implant [21].

The two-pieces screw-shape dental implant, having round threads with short step (Figure 4) is adequate to be inserted in a high-density bone as mandible bone is, that has predominantly a cortical consistency, less irrigated by blood vessels and with rare cells and reduced metabolic activity [22]. In this respect, it usually has two components, in order to avoid the incipient load, because this mechanical compression will be negatively added to the vascular deficiency.

The surgical technique for insertion is also by screwing, after realizing by drilling and tapering a cylindrical hole with the same diameter as the implant, the whole way to the bottom. The implant insertion is without any pressure on the bone walls to the end when the compression force is growing suddenly on the dynamometric measurements [23].

The "two-pieces" screw-shape dental implant, having trapezoidal threads with short step (Figure 5) is indicated to be used, as the previous one, in a high-density bone, as mandible bone is [3]. The surgical technique of insertion is also by screwing, after realizing by drilling and tapering a cylindrical hole with the same diameter as the implant [15].

The cell islands that are growing to the tip of the implant, with a moderate metabolic activity, are related with the phosphorus-calcium precipitates at the implant interface without any tendency for maturing and bone transformation. All these microscopic images (Figure 10) are suggesting a necrosis by over compression of the surrounding bone [24].

✉ Conclusions

After this study, it is possible to establish a direct correlation between the shape of the implant and the loosening of the primary stability, even that for blade-shape implant, from the point of view of the surgical technique, the compression on the bone is not predictable.

Regardless the type of implant, there is a direct proportionality between the level of the surface preparation (machining, sandblasting, acid etching) and the surrounding healing speed through mature bone tissue (inflammation tissue with vascular plexus, fibrous tissue, new bone tissue formation).

The loss during three to six months of the primary stability for the dental implants evaluated at the interface was attributed to blood supply deficiency of the surrounding bone in case of the implants inserted in the anterior-lateral and lateral mandible bone (see the implants from Figures 6 and 9), was caused by over compression of the bone around the implant with consecutive necrosis without leaving the possibility of normal healing both for the maxilla and the mandible (see the implants from Figures 8 and 10) or because of prosthetic load deficiency by applying forces out of the implant axis (see the implant from Figure 7).

References

- [1] BRATU D, NUSSBAUM R, *Bazele clinice și tehnice ale protezării fixe*, Ed. Signata, Timișoara, 2001, 28–30.
- [2] GROSSMANN Y, NISSAN J, LEVIN L, *Clinical effectiveness of implant-supported removable partial dentures: a review of the literature and retrospective case evaluation*, J Oral Maxillofac Surg, 2009, 67(9):1941–1946.
- [3] MISCH CE, *Contemporary Implant Dentistry*, 2nd edition, Mosby Inc., St. Louis, 1999, 490–493.
- [4] CRESPI R, CAPPARÉ P, GHERLONE E, ROMANOS GE, *Immediate versus delayed loading of dental implants placed in fresh extraction sockets in the maxillary esthetic zone: a clinical comparative study*, Int J Oral Maxillofac Implants, 2008, 23(4):753–758.
- [5] MICULESCU F, BOJIN D, CIOCAN LT, ANTONIAC I, MICULESCU M, MICULESCU N, *Experimental researches on biomaterial-tissue interface interactions*, J Optoelectron Adv Mater, 2007, 9(11):3303–3306.
- [6] HEIDELBACH G, *Blade implants and its indication limits*, Zahnärztl Prax, 1982, 33(1):10, 13–18.
- [7] PAPILIAN V, *Anatomia omului. I. Aparatul locomotor*, ediția a V-a, Ed. Didactică și Pedagogică, București, 1974, Osteologia, 15–18.
- [8] GRAY H, *Gray's Anatomy*, The Classic First Edition, Promotional Reprint Co. Limited, London, 1991, Osteology, 1–4.
- [9] ROBERTS R, *Placement of plate-form implants using osteotomes*, J Oral Implantol, 2002, 28(6):283–289.
- [10] ALVES SF, WASSALL T, *In vitro evaluation of osteoblastic cell adhesion on machined osseointegrated implants*, Braz Oral Res, 2009, 23(2):131–136.
- [11] SATO N, KUBO K, YAMADA M, HORI N, SUZUKI T, MAEDA H, OGAWA T, *Osteoblast mechanoresponses on Ti with different surface topographies*, J Dent Res, 2009, 88(9):812–816.
- [12] CAVALLARO J JR, GREENSTEIN B, GREENSTEIN G, *Clinical methodologies for achieving primary dental implant stability: the effects of alveolar bone density*, J Am Dent Assoc, 2009, 140(11):1366–1372.
- [13] WONG M, EULENBERGER J, SCHENK R, HUNZIKER E, *Effect of surface topology on the osseointegration of implant materials in trabecular bone*, J Biomed Mater Res, 1995, 29(12):1567–1575.
- [14] BAKAEEN L, QUINLAN P, SCHOOLFIELD J, LANG NP, COCHRAN DL, *The biologic width around titanium implants: histometric analysis of the implantogingival junction around immediately and early loaded implants*, Int J Periodontics Restorative Dent, 2009, 29(3):297–305.
- [15] ABUHUSSEIN H, PAGNI G, REBAUDI A, WANG HL, *The effect of thread pattern upon implant osseointegration*, Clin Oral Implants Res, 2010, 21(2):129–136.
- [16] BAGAMBISA FB, KAPPERT HF, SCHILLI W, *Cellular and molecular biological events at the implant interface*, J Craniomaxillofac Surg, 1994, 22(1):12–17.
- [17] KANAWATI A, RICHARDS MW, BECKER JJ, MONACO NE, *Measurement of clinicians' ability to hand torque dental implant components*, J Oral Implantol, 2009, 35(4):185–188.
- [18] ERICSSON I, JOHANSSON CB, BYSTEDT H, NORTON MR, *A histomorphometric evaluation of bone-to-implant contact on machine-prepared roughened titanium and dental implants. A pilot study in the dog*, Clin Oral Implants Res, 1994, 5(4):202–206.
- [19] ESPOSITO M, LAUSMAA J, HIRSCH JM, THOMSEN P, *Surface analysis of failed oral titanium implants*, J Biomed Mater Res, 1999, 48(4):559–568.
- [20] TURKYILMAZ I, TÖZÜM TF, TUMER C, *Early versus delayed loading of mandibular implant-supported overdentures: 5-year results*, Clin Implant Dent Relat Res, 2009, Aug 5 [Epub ahead of print].
- [21] JAARDA MJ, LANG BR, KAIGLER D, WANG RF, *Early detection of osseointegration using scanning electron microscopy and the interfacial biopsy chamber: a pilot study*, Implant Dent, 1992, 1(1):84–87.

- [22] MATSUO M, NAKAMURA T, KISHI Y, TAKAHASHI K, *Micro-vascular changes after placement of titanium implants: scanning electron microscopy observations of machined and titanium plasma-sprayed implants in dogs*, J Periodontol, 1999, 70(11):1330–1338.
- [23] HRUSKA A, BORELLI P, BORDANARO AC, MARZADURI E, HRUSKA KL, *Immediate loading implants: a clinical report of 1301 implants*, J Oral Implantol, 2002, 28(4):200–209.
- [24] BASHUTSKI JD, D'SILVA NJ, WANG HL, *Implant compression necrosis: current understanding and case report*, J Periodontol, 2009, 80(4):700–704. Erratum in: J Periodontol, 2009, 80(6):1018.

Corresponding author

Lucian Toma Ciocan, Assistant Professor, Prosthetic Technology and Dental Materials Department, Faculty of Dental Medicine, "Carol Davila" University of Medicine and Pharmacy, 4–6 Eforiei Street, 4th Floor, Off. 31, 6th Sector, 050037 Bucharest, Romania; Phone +40724–902 400, Fax +4021–313 53 77, e-mail: tciocan@yahoo.com

Received: December 15th, 2009

Accepted: February 10th, 2010