

## ORIGINAL PAPER

# Anatomy of the reflected ligament of the inguinal region

R. SHANE TUBBS<sup>1)</sup>, JENNY GOBER MCDANIEL<sup>2)</sup>, AMANDA M. BURNS<sup>2)</sup>,  
ANJALI KUMBLA<sup>2)</sup>, TIFFANY D. COSSEY<sup>2)</sup>, NIHAL APAYDIN<sup>3)</sup>, A. COMERT<sup>3)</sup>,  
H. I. ACAR<sup>3)</sup>, I. TEKDEMIR<sup>3)</sup>, M. M. SHOJA<sup>4)</sup>, M. LOUKAS<sup>5)</sup>

<sup>1)</sup>Section of Pediatric Neurosurgery,  
Children's Hospital, Birmingham, Alabama, USA

<sup>2)</sup>University of Alabama at Birmingham School of Medicine

<sup>3)</sup>Department of Anatomy, Faculty of Medicine,  
Ankara University, Ankara, Turkey

<sup>4)</sup>Tuberculosis and Lung Disease Research Center,  
Tabriz University of Medical Sciences, Tabriz, Iran

<sup>5)</sup>Department of Anatomical Sciences,  
"St. George's" University, Grenada

### Abstract

**Background:** There is a paucity in the literature regarding the reflected ligament. Therefore, the present study was performed in order to further elucidate this anatomy. **Material and Methods:** Eighteen formalin-fixed adult cadavers (35 sides) underwent dissection of the medial inguinal region. The reflected ligament was observed for and when identified, its dimensions were measured. **Results:** 83% of sides were found to have a reflected ligament. These were identified in 16 male and 13 female bodies. The size and shape for the reflected ligaments were variable but overall, triangular in nature. In general, the reflected ligament was found to extend from the lacunar and medial inguinal ligaments and extended obliquely toward the midline at an approximate 45° angle to insert near the linea alba. Two ligaments (6.9 %) were identified that interdigitated with the contralateral reflected ligament. The medial and lateral lengths of the ligament had a mean measurement of 2.28 and 2.58 cm. The base of the reflected ligament had a mean of 2.52 cm and the height of this ligament was found to have a mean of 2.56 cm. The mean area of the reflected ligament was calculated as 2.93 cm<sup>2</sup>. There was no statistically significant difference between right or left sides or between genders. **Conclusions:** The reflected ligament was identified in the majority of our specimens and this structure usually contributed to the formation of the posteromedial wall of the external inguinal ring. Therefore, this fact should be included in future descriptions of this ligament.

**Keywords:** anatomy, inguinal region, hernia, conjoined tendon, falx inguinalis.

### ☞ Introduction

While inguinal anatomy is fairly well described in the literature [1, 2], there is a tremendous scarcity of information regarding the reflected inguinal ligament and its potential clinical application. Occasionally, the reflected ligament is depicted in anatomy texts but further comments about its morphology are almost unanimously omitted. Other names for this structure include Colles' ligament, triangular fascia, and reflex ligament [1]. In the French anatomical literature, it is known as the posterior crus [3].

The reflected inguinal ligament has been described in some anatomy textbooks as a triangular ligament formed from an expansion of the lacunar ligament joining the linea alba [4]. Hollinshead WH [5, 6] stated that this ligament is derived from the inferior crus of the external ring and the lacunar ligament. Medially, it is found posterior to the spermatic cord and superior crus of the superficial inguinal ring. Skandalakis JE [3] included the reflected ligament in his definition of the conjoined tendon (falx inguinalis).

The occurrence rate of the reflected ligament is

varied among anatomy texts, with incidences ranging from 1 to 3% of the population [1]. Anson BJ and McVay CB [7] reported it bilaterally in less than 1% and unilaterally in 3%. These authors identified the ligament in 65 body halves and suggested that in 12 of these 65 (18.5%) halves that the ligament actually serves some support in the infero-medial part of the superficial inguinal ring [1, 2]. However, Hollinshead WH [5] stated that this ligament is of "no practical importance". Additionally, the dimensions and functions of the ligament have not been addressed prior to this paper.

The intent of this study was to investigate the occurrence rate of the ligament, establish a morphological description of the ligament, and to postulate the function of the reflected ligament in inguinal anatomy.

### ☞ Material and Methods

Following internal review board approval, eighteen formalin-fixed adult cadavers (35 sides) aged 54 to 92 years (mean 73 years) underwent dissection of the medial inguinal region.

Cadavers were derived from a local Caucasian stock and were more or less in appropriate nutritional status. Twenty specimens were male and 15 were female. No cadaver was identified with pathology or evidence of past surgical intervention in the area studied.

All measurements were made using calipers and rulers and were performed by all authors.

The dimensions of the ligaments were measured, including the medial and inferior attachments, the lateral free edge, and the height, which was the distance from the mid-point of the inferior attachment to the point at which the lateral free edge and the medial attachment intersected. Additionally, the area of each ligament was calculated.

Statistical analysis was made using SPSS version 10 for Windows. Statistical significance was set at  $p < 0.05$ .

## Results

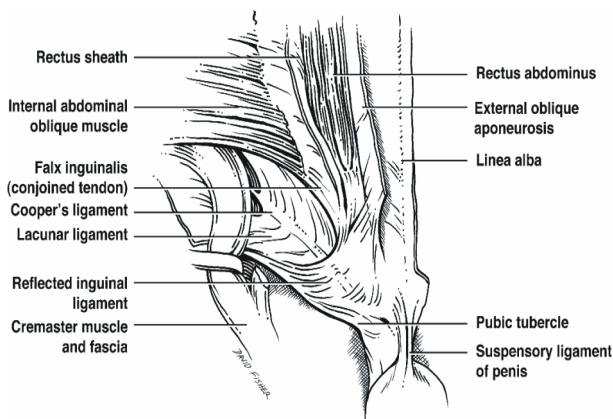
In our study, 29 of 35 sides (83%) were found to have a reflected ligament. These were identified in 16 male and 13 female bodies. The results were highly variable in both size and shape for the reflected ligaments examined.

One cadaver had the ligament cut on one side, and therefore the measurements for that ligament could not be made.

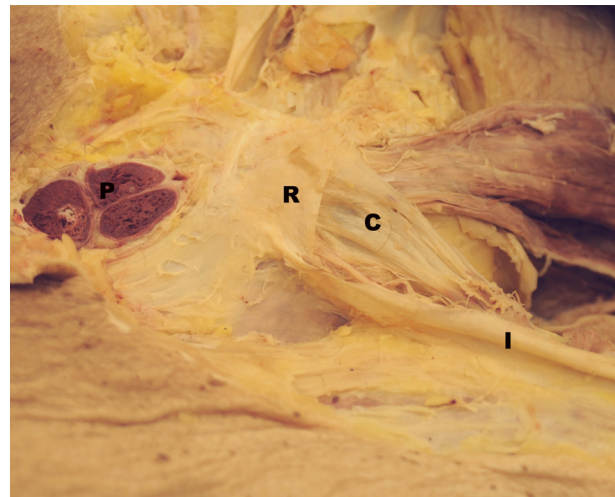
In general, the reflected ligament was found to extend from the lacunar and medial inguinal ligaments obliquely toward the midline at an approximate  $45^\circ$  angle to insert into the linea alba just anterior to the pyramidalis muscle if present within the anterior rectus sheath.

If the pyramidalis muscle was not present, this ligament simply inserted just anterior to the anterior rectus sheath or more rarely, into the contralateral reflected ligament.

The lateral edge of the reflected ligament was more or less free and the medial and inferior edges were attached. Two ligaments (6.9%) were identified that interdigitated with the contralateral reflected ligament. Each ligament was found in a consistent location and with consistent attachments to both the inguinal and lacunar ligaments (Figures 1 and 2).



**Figure 1** – Schematic rendition of the reflected ligament and surrounding anatomical structures. The triangular nature of this ligament lent itself to measuring the length of its medial, lateral and inferior sides.



**Figure 2** – Cadaveric specimen demonstrating the left reflected ligament (R). For reference, note transected penis (P), inguinal ligament (I) and conjoined tendon (C).

The medial and lateral lengths of the ligament had a mean measurement of 2.28 and 2.58 cm, range (1.3–3.3 cm and 1–3.3 cm, respectively). The base of the reflected ligament ranged in length from 1.4–3.5 cm (mean 2.52 cm). The height of this ligament ranged from 1.5–3.4 cm with a mean of 2.56 cm. Based on these measurements, the area of each reflected ligament was calculated and ranged from 1.05–5.61  $\text{cm}^2$  with a mean of (2.93  $\text{cm}^2$ ).

Ligaments were analyzed in two groups based on side and gender (Tables 1 and 2). When the ligaments were compared between males and females, there was no statistical significance found among any of the parameters measured (Table 1). Likewise, there was no statistically significant difference between right or left reflected ligaments (Table 2).

**Table 1** – Mean measurements of reflected ligament in male/female specimens

	Male	Female	<i>p</i>
Medial attachment [cm]	2.26	2.3	0.802
Lateral free edge [cm]	2.58	2.56	0.918
Inferior attachment [cm]	2.59	2.42	0.422
Height [cm]	2.3	2.21	0.611
Area [ $\text{cm}^2$ ]	3.07	2.76	0.451

**Table 2** – Mean measurements of reflected ligaments from right and left sides

	Right	Left	<i>p</i>
Medial attachment [cm]	2.29	2.27	0.913
Lateral free edge [cm]	2.59	2.56	0.893
Inferior attachment [cm]	2.50	2.53	0.897
Height [cm]	2.24	2.87	0.759
Area [ $\text{cm}^2$ ]	2.86	2.99	0.745

## Discussion

Many previous texts opined that the reflected ligament is of little importance; however, there is no experimental evidence to prove this. We postulated that the reflected inguinal ligament plays a role in support of the inguinal and lacunar ligaments. Its presence in most

of our specimens suggests its significance. It is a ligament that could be seemingly important clinically when considering inguinal hernias as it not only appears to aid in supporting adjacent ligaments with its oblique orientation but that it also contributed to the conjoined tendon in the majority of our specimens.

In our study, the location of the ligament was found just anterior to the pyramidalis muscle, when present, which may be of importance in relation to surgical anatomy. Morphologically, we confirmed the opposite direction of fibers, its triangular shape, its insertion onto the pubic tubercle and crest, and its posterior location to the spermatic cord.

One of the more detailed assessments of the reflected ligament is found in *Clemente's Gray's Anatomy* [8]. This author stated that the reflected ligament is approximately 2 to 3 cm wide and is frequently lacking. Statistical analysis of the results in this study suggests that the reflected ligament plays an equal role in men and women – a role that needs further investigation. In addition, the ligament proved to be roughly symmetrical in dimension and area when comparing both right and left sides of cadavers.

### ☒ Conclusions

The reflected ligament was identified in the majority of our specimens and contributed to the formation of the posteromedial wall of the external inguinal ring.

### Corresponding author

Richard Shane Tubbs, MD, PhD, Section of Pediatric Neurosurgery, Children's Hospital, 1600 7<sup>th</sup> Avenue South ACC 400, Birmingham, Alabama 35233, USA; Phone 205-939-9914, Fax 205-939-9972, e-mail: rstubbs@uab.edu

Received: November 21<sup>st</sup>, 2008

Accepted: September 25<sup>th</sup>, 2009

Future studies may correlate the area of this structure and its contribution to the external ring to the incidence of inguinal hernia (i.e. if not present, could this predispose one to herniation through the postero-medial wall of the external ring?).

Using this structure for better hernia repair may be warranted.

### References

- [1] LYTLE W. J., *Inguinal anatomy*, J Anat, 1979, 128(Pt 3):581–594.
- [2] LYTLE W. J., *The inguinal and lacunar ligaments*, J Anat, 1974, 118(Pt 2):241–251.
- [3] SKANDALAKIS J. E., *Skandalakis' surgical anatomy. The embryologic and anatomic basis of modern surgery*, Pachalidis Medical Publications, Athens, 2004, 1113.
- [4] ROMANES G. J., *Cunningham's Textbook of Anatomy*, 11<sup>th</sup> edition, Oxford University Press, London, 1972, 345.
- [5] HOLLINSHEAD W. H., *Anatomy for surgeons: the thorax, abdomen, and pelvis*, 2<sup>nd</sup> edition, Hoeber-Harper Press, New York, 1971, 457.
- [6] HOLLINSHEAD W. H., *Anatomy for surgeons: the thorax, abdomen, and pelvis*, 1<sup>st</sup> edition, Hoeber-Harper Press, New York, 1956, 567.
- [7] ANSON B. J., MCVAY C. B., *Inguinal hernia. I. The anatomy of the region*, Surg Gynecol Obst, 1938, 66:186.
- [8] CLEMENTE C. D., *Anatomy of the human body by Henry Gray*, Williams & Wilkins, Baltimore, 1985, 1345.