

ORIGINAL PAPER

Alveolar bone dehiscences and fenestrations: an anatomical study and review

VANDA ROXANA NIMIGEAN¹⁾, V. NIMIGEAN²⁾, MARIA ANGELICA BENCZE¹⁾,
NICOLETA DIMCEVICI-POESINA³⁾, R. CERGAN⁴⁾, SIMONA MORARU¹⁾

¹⁾Department of Oral Rehabilitation

²⁾Department of Clinical and Topographical Anatomy

³⁾Department of Applied Mathematics and Biostatistics

⁴⁾Department of Descriptive Anatomy

Faculty of Dental Medicine,

"Carol Davila" University of Medicine and Pharmacy, Bucharest

Abstract

Aim: To determine the prevalence and distribution of fenestrations and dehiscences of the jaw bones among the Caucasian population, to find if any correlations can be established between their occurrence and certain teeth characteristics and to discuss the clinical implications the defects of alveolar process could have. **Material and Methods:** 138 skulls of specimens ranging from 21 to 54 years of age, having either complete dentition or reduced number of missing teeth were studied. Teeth found to have one of the two defects were examined for signs of faceting (attrition) that was considered an indicative for excessive occlusal forces and were submitted (except for the case of the third molars) to an analysis concerning their bucco-lingual inclination in the jaw. **Results:** High-prevalence rates for both osseous entities were found. Fenestrations were present in 69.565% of the skulls and dehiscences were present in 53.623% of the skulls. More fenestrations were found in the maxilla: 74.679% and more dehiscences were found in the mandible: 71.613%. No correlations could be established between the presence of dehiscences and fenestrations and the development of high-occlusal forces, whereas all teeth affected either by dehiscences or by fenestrations were found to have modifications of the normal bucco-lingual inclination angle's values ($p < 0.05$). **Discussion:** The interest regarding the correlation between the alveolar processes morphology and the teeth dates back to 1963. The published studies are somewhat consistent with regard to prevalence and distribution of dehiscences and fenestrations, while opinions concerning their etiology are heterogenous. According to our study and the data provided by the specialized literature references, dehiscences and fenestrations are common findings related to the presence of the teeth. **Conclusions:** The potential of developing fenestrations and dehiscences must be carefully evaluated through oral surgery procedures. With regard to implant placement, this study aims to help the clinician design and manage treatment, in order to clinically correct the conditions and identify the principles of bone augmentation, so that endo-osseous implants can be properly placed.

Keywords: human skull, maxilla, mandible, periodontium, CT-scan, oral implantology.

Introduction

The alveolar processes represent an extension of the body of the maxilla and of the body of the mandible, and are considered one of the four major anatomic components of the periodontium (teeth investing and supporting apparatus).

Among all bones, the alveolar process structure and morphology are considered "unique" due to their lability and dependence on the teeth, which are housed in the osseous crypts called alveoli [1]. This teeth-dependence commonly results in two encountered situations: dehiscences and fenestrations, which represent interruptions of the cortical plate contour. Traditional textbooks of anatomy lack in information on dehiscences and fenestrations [2], while famous periodontists considered them important anatomic entities when related to periodontal surgery, affecting 20% of the teeth, more commonly placed on the anterior, than on the posterior region of the jaws [3]. Even other studies regarding the defects of the alveolar bone have been performed on human skulls [4–11],

dehiscences and fenestrations have yet to be fully clarified as regards both etiology and clinical relevance. The present study was designed to determine the prevalence of dehiscences and fenestrations on white South-East European population and to identify some etiologic factors for their occurrence. Although dehiscences and fenestrations are considered non-pathological conditions, a variation within the range of periodontal normalcy, their undiagnosed or unexpected presence may complicate periodontal surgical procedures or require changes in implant placement protocols. In order to achieve a satisfactory and stable esthetic result, dentists and periodontists must be aware of the normal bone anatomy.

Material and Methods

The study was performed on dried adult human skulls belonging to the white South-East European population, selected from a collection of over 4000 human skulls of the "Francisc Rainer" Institute of Anthropology in Bucharest, an institution affiliated to

the Romanian Academy. The age of the exhibited specimens varied from 16 to 67, with the date of death placed in the interval 1920–1940. The first inclusion principle we followed was that the skulls should be dentate ones, with complete dentition or a reduced number of missing teeth. The teeth having either a dehiscence or a fenestration that had secondary tilting or extrusion, due to edentulism of adjacent teeth or of correspondent antagonists respectively, were excluded from the study. The second principle was to include only the specimens that showed no evident signs of periodontal disease. In order to consider the periodontium healthy, the crest of the interproximal bone had to be placed no more than 2 mm apical from the cemento-enamel junction of the correspondent tooth.

Recognition of dehiscences and fenestrations was done using the identification criteria first mentioned by Davies RM *et al.* [5]: Dehiscence was registered as lack of cortical bone at the level of a dental root, at least 4 mm apical to the margin of the inter-proximal bone (Figure 1a). The measurements were performed with a graduated periodontal probe. Fenestration was identified as a localized defect in the alveolar bone that exposed the root surface, usually the apical or the medium third, but did not involve the alveolar margin (Figure 1b). Fenestrations were classified based on their apico-coronal location in relation to root length, into four categories: at the level of the apical third, at the level of the middle third, at the level of the coronal third, or extending from the apical to the middle third of the dental root.

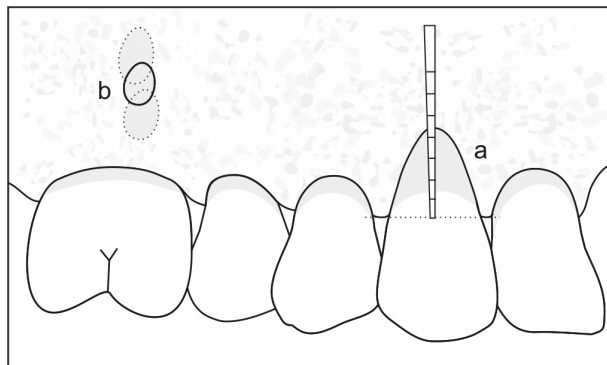


Figure 1 – Schematic representation of what is considered a dehiscence (a) and a fenestration (b).

The crowns of all the teeth of the specimens having either dehiscences or fenestrations were examined for signs of faceting, which was considered indicative of possible excessive occlusal forces. The degree of faceting was not classified.

The teeth found to have one of the two defects, except for the case of the third molars were submitted to the analysis regarding their bucco-lingual inclination in the jaws. For this purpose, CT-images of the affected skulls were performed. Sagittal scans for the anterior sites and frontal scans for the posterior sites were constructed, permitting the individual imaging of the teeth and their alveolar process. The angle between the long axis and a perpendicular to a horizontal line that materialized the occlusal plane was measured for each tooth affected either by dehiscences or by fenestrations.

Results

A number of 138 skulls met the requirements of this study totalizing 3646 examined teeth, with a mean number of 26.420 teeth per skull. Specimens were between 21 to 54 years of age.

Prevalence of dehiscences and fenestrations

A number of 124 skulls showed alveolar defects, representing 89.855% of the investigated skulls. Fenestrations were present in 69.565% of the skulls, while dehiscences were present in 53.623% of the skulls. 98.387% of the affected specimens had two or more defects, as shown in Table 1 and Figure 2.

Table 1 – Percentage of affected skulls with different number of defects

No. of defects per skull	No. of affected skulls	% of affected skulls
1	2	1.613
2	18	14.516
3	29	23.387
4	40	32.258
5	29	23.387
6	5	4.032
7	1	0.807
Total	124	100.000

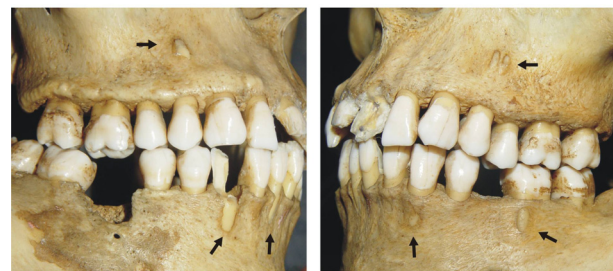


Figure 2 – Skull with six alveolar defects (right and left views).

Alveolar bone defects were associated with 467 teeth, representing 12.808% of all examined teeth. Dehiscences were present in 4.251% and fenestrations in 8.557% of all examined teeth. The distribution of alveolar defects by age groups is listed in Table 2.

Table 2 – Distribution of alveolar defects by age groups

Age group [years]	21–34	35–44	45–54	Total
No. of skulls	72	48	18	138
No. of examined teeth	1978	1233	435	3646
Mean teeth/skull	27.472	25.685	24.167	26.420
No. of teeth with dehiscences	71	64	20	155
% teeth with dehiscences	3.589	5.191	4.598	4.251
No. of teeth with fenestrations	184	99	29	312
% teeth with fenestrations	9.302	8.029	6.667	8.557

Fenestrations were found exclusively on the buccal bone plate, while dehiscences were mostly found on the buccal bone plate and very seldom on the palatal bone plate: it was the case of two maxillary first molars, representing 1.290% of all teeth with dehiscences.

Incidence and distribution of dehiscences and fenestrations in the two jaw bones

Fenestrations and dehiscences occurred in both the maxilla and mandible, but the distribution differed for each jaw bone, as can be seen in Table 3. Fenestrations were most prevalent in the maxilla: 74.679% (Table 3), while dehiscences were mostly found in the mandible: 71.613% (Table 4).

Table 3 – Distribution and percentage of individual teeth affected by fenestrations in the two jaw bones

	Maxilla		Mandible		Total	
	No.	%	No.	%	No.	%
Third molar	2	0.641	0	0	2	0.641
Second molar	30	9.615	4	1.281	34	10.896
First molar	133	42.628	50	16.026	183	58.654
Second premolar	19	6.090	0	0	19	6.090
First premolar	45	14.423	1	0.321	46	14.744
Canine	4	1.282	17	5.449	21	6.731
Lateral incisor	0	0	7	2.244	7	2.244
Central incisor	0	0	0	0	0	0
Total	233	74.679	79	25.321	312	100

Table 4– Distribution and percentage of individual teeth affected by dehiscences in the two jaw bones

	Maxilla		Mandible		Total	
	No.	%	No.	%	No.	%
Third molar	0	0	0	0	0	0
Second molar	0	0	1	0.645	1	0.645
First molar	7	4.516	8	5.162	15	9.678
Second premolar	0	0	1	0.645	1	0.645
First premolar	3	1.936	28	18.064	31	20
Canine	27	17.419	63	40.645	90	58.064
Lateral incisor	7	4.516	4	2.581	11	7.097
Central incisor	0	0	6	3.871	6	3.871
Total	44	28.387	111	71.613	155	100

Regarding the repartition of alveolar defects, it can be said that fenestrations are more frequently encountered in the posterior region of the maxilla (49.036% of the all affected teeth), while dehiscences are more frequently encountered in the anterior region of the mandible (15.631% of the all affected teeth), data being listed in Table 5, a and b.

The teeth most often affected by fenestration were the maxillary first molar (42.628%), followed by the mandibular first molar (16.026%) and maxillary first premolar (14.423%), as shown in Table 3; the teeth most often affected by dehiscence were the mandibular canine (40.645%), the mandibular first premolar (18.064%) and maxillary canine (17.419%), as shown in Table 4.

Table 5 – (a) Distribution of alveolar defects in the two regions of the jaws

		Maxilla	Mandible	Total
		No.	No.	No.
No. of teeth with dehiscences	Anterior	34	73	107
	Posterior	10	38	48
No. of teeth with fenestrations	Anterior	4	24	28
	Posterior	229	55	284
No. of teeth with defects	Anterior	38	97	135
	Posterior	239	93	332
Total		277	190	467

Table 5 – (b) Percentage of alveolar defects in the two regions of the jaws

		Maxilla	Mandible	Total
		%	%	%
% of teeth with dehiscences	Anterior	7.281	15.631	22.912
	Posterior	2.141	8.137	10.278
% of teeth with fenestrations	Anterior	0.857	5.139	5.996
	Posterior	49.036	11.777	60.813
% of teeth with defects	Anterior	8.137	20.771	28.908
	Posterior	51.178	19.914	71.092
Total		59.315	40.685	100

Apico-coronal location of fenestrations

With regard to apico-coronal location in relation to root length, fenestrations were found as follows:

- in the apical third of the dental root – 48.563%, all of them being placed in the maxilla;
- in the middle third of the dental root in 28.161% of the cases, 65.305% being situated in the maxilla and 34.695% in the mandible;
- in the coronal third of the dental root: 18.966% – all in the mandible;
- extending from the apical to the middle third of the dental root: 4.310%, all of them located in the maxilla.

Correlations between the presence of alveolar bone defects and teeth' features

Lack of faceting (occlusal attrition) was a common finding in all the affected teeth and for the entire dentition of the investigated specimens, except for three affected skulls, that had a minor randomized degree of faceting. Comparing the values of the angles between the long axes of the teeth and a perpendicular line to the occlusal plane, found through CT-examination, with the ones described by Dempster WT *et al.* for teeth with normal arrangement in the dental arch [12], a decrease of the bucco-lingual inclination was noticed in all teeth affected either by dehiscences or by fenestrations ($p < 0.05$), as can be observed in Table 6 and Figures 3–5.

Table 6 – Bucco-lingual inclination of the most affected teeth (values of the angles between the long axes of the teeth and a perpendicular line to the occlusal plane assessed through CT-examination) compared to the normal ones (*for the palatal root; **for the buccal root)

Sites	Type of defect	Range of values (°)	Normal values (°), after Dempster WT <i>et al.</i>
Mandibular canine	Dehiscence	5–7	12
Mandibular first premolar		4–5	9
Maxillary canine		8–10	16
Maxillary first molar		9–16	20*
Mandibular first molar	Fenestration	12–15	20
Maxillary first premolar		1–2	5**
Maxillary second molar		11–15	20

Signs of osteolysis due to an endodontic pathosis can be observed at the level of the upper second premolar (the decrease of the compactness degree, even

a spongy bone aspect and the thick bone margins that enclose the exposed root). In case of the mentioned fenestrations, the compact aspect of the external bone plate and the thin bone margins that surround the root exposure can be noticed.

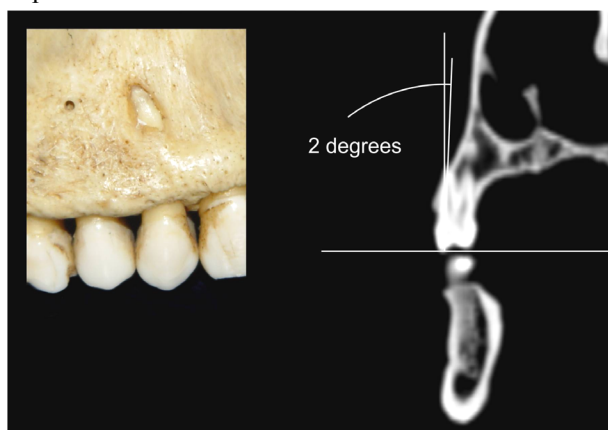


Figure 3 – Bucco-lingual inclination of a maxillary first premolar with a fenestration that involves the apical third of the root.

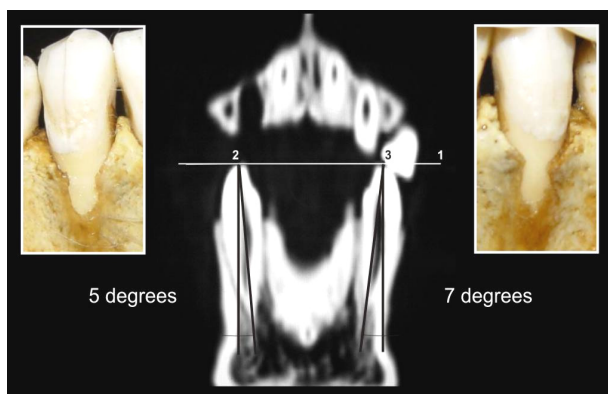


Figure 4 – Bucco-lingual inclination of mandibular canines, both affected by dehiscences.

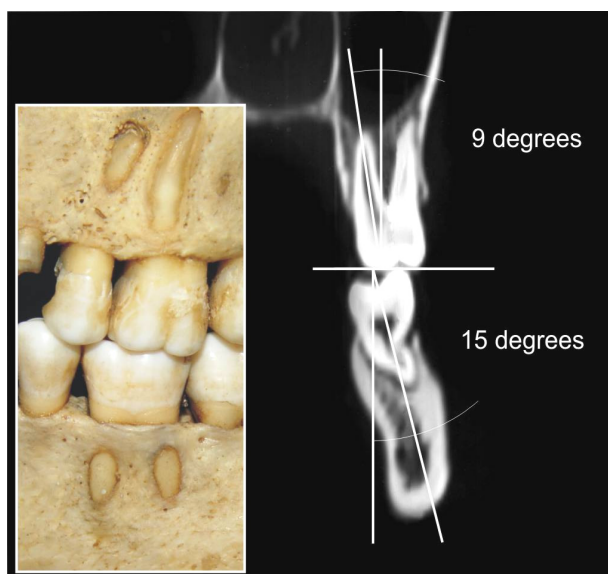


Figure 5 – Bucco-lingual inclination of a maxillary first molar with a fenestration that involves almost the entire length of the root and of a mandibular first molar with a fenestration placed in the middle third of the root.

Discussion

The maxilla and mandible consist of the basal bone, which is the portion of the jaw located apically, unrelated to the teeth, and the alveolar process, the portion of the jaw bones that forms and supports teeth sockets (alveoli).

The alveolar bone is formed during fetal growth by membranous calcification and consists of a calcified matrix with osteocytes enclosed within spaces called lacunae. Osteoblasts and bone tissue of the mandibular and maxillary alveolar processes substantially differ from osteoblasts and bone in other parts of the skeleton [3, 13]. These differences are apparent during embryonic development, maturation, and aging of such bones. The cellular and molecular basis for these differences is still not clear, but it is unfolding at record speed [14].

The alveolar process consists of the following:

- an external plate of cortical bone;
- the inner socket wall formed by a compact bone called *the alveolar bone proper*, which is seen as *the lamina dura* on radiographs;
- the supporting bone which lies between these two compact layers and is represented by cancellous trabeculae.

Alveolar bone architecture may vary from patient to patient in point of thickness, contour and configuration, and all these variations may be both normal and healthy [3]. The cause of these differences is the unique dependence between the morphology of the alveolar process and the teeth. The bone contour normally conforms to the prominence of the roots with intervening vertical depressions that taper toward the margin.

In a healthy periodontium, the position of the bone margin mimics the contour of the cemento-enamel junction and lies approximately 1–2 mm apical to it, resulting that the inter-proximal bone is more coronal in height than the labial and lingual/palatal bones. This ‘scalloping’ of the bone on the facial and lingual/palatal areas is related to the tooth, the root form and the tooth position in the alveolus. The bony architecture varies from the anterior to the posterior regions, the molar teeth showing less scalloping and a more significantly flat profile as compared to the bicusps and the incisors [3, 15].

Within harmonious dental arches, there is congruence between the size of the teeth and the size of their bone housing. In the maxilla, the long axes of the teeth converge toward the apex, while in the mandible they diverge toward the apex. Virtually prolonging the axes of all the teeth, a cone is obtained having the centre at the level of the *Crista Galli* apophysis of the ethmoid (Figure 6) [16].

Early evidence on the interest regarding the correlation between the alveolar processes morphology and the teeth dates back to 1963, when O’Connor TW studied the relationship of teeth with the inter-proximal bone, tooth anatomy, the presence of fenestrations and bony wedges [17]. Elliot JR and Bowers GM work that described dehiscences and fenestrations, and Stahl S *et al.* study, which focused exclusively on the prevalence

of fenestrations, also date from 1963 [7, 10]. Since then, studies concerning the prevalence of dehiscences and fenestrations have been performed on various ethnic groups: Egyptians [4], Britons [5], Beduins [6], Mexican Indians [8], South African Blacks [11], etc., and the most diverse and comprehensive population set investigated in point of anthropological morphotypes is the one analyzed by Rupprecht RD *et al.* [9].

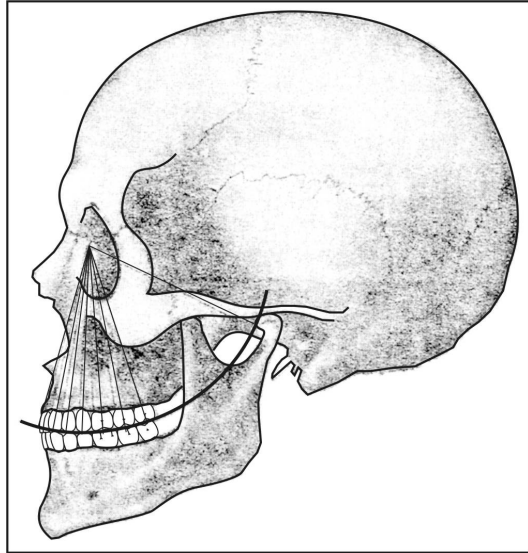


Figure 6 – The virtual convergence of teeth' axes toward a point placed on Crista Galli apophysis of the ethmoid.

Dehiscences and fenestrations reflect anatomical variations concerning the shape and the morphology of the alveolar bone. Isolated areas in which the root is denuded of bone and the root surface is covered only by the periosteum and the overlying gingiva are termed fenestrations. In this instance, the marginal bone is intact. When the denuded areas extend through the marginal bone, the defect is called a dehiscence.

Prevalence of the two entities found in our study (dehiscences in 4.251% and fenestrations in 8.557% of all examined teeth) is similar with that of previous reports. Davies RM *et al.* [5] found dehiscences and fenestrations in 5.36% and 8.45%, respectively, of all evaluated teeth. Edel A [6] found dehiscences and fenestrations in 4.40% and 9.70%, respectively, from 990 examined teeth, while Rupprecht RD *et al.* [9] found dehiscences in 4.1% and fenestrations in 9.0% of the examined teeth. A higher percent of skulls were affected both by fenestrations (69.565%) and by dehiscences (53.623%) in our study as compared to other articles (61.6% and 40.4%, respectively – Rupprecht RD *et al.* [9]).

Distribution of dehiscences and fenestrations in the two jaw bones shown in our study was consistent with that of other reports, where fenestrations were more commonly found in the maxilla, while dehiscences were more commonly found in the mandible. Alveolar bone defects were more frequent in the posterior region of the maxilla and equally distributed between anterior and posterior region of the mandible.

Almost all of the defects in our study involved the buccal alveolar plate (99.571%) and few (only two

dehiscences) involved the palatal bone plate (0.429%), Elliot JR and Bowers GM [7] found two palatal dehiscences with the same location like we did (maxillary first molars), while Rupprecht RD *et al.* [9] found dehiscences on palatal (1.6%) and mandibular lingual (3.9%) aspects of the jaws. Fenestrations were more frequently placed in the apical third of the dental root in the maxilla and in the coronal third of the dental root in the mandible. As compared to other papers, we did not find fenestrations involving the apical third of the dental root in the mandible, while Rupprecht RD *et al.* [9] reported mandibular fenestrations evenly distributed between the apical and middle thirds of the dental roots (46.0% and 46.8%, respectively).

Previous studies reported repartition of fenestrations by teeth as follows (decreased order): maxillary first molars, maxillary second molars, maxillary canines, mandibular canines and lateral incisors [5, 6], and maxillary first molars, maxillary canines and mandibular canines [9]. In our study, we found fenestrations more common associated with maxillary first molars, followed by mandibular first molars and maxillary first premolars.

Dehiscences were more frequently associated in previous reports (decreased order) with mandibular canines and first premolars and maxillary canines and first molars [5, 6] and mandibular cuspids and left maxillary first molars [9]. In our study, we found dehiscences most prevalent in mandibular canines followed by mandibular first bicuspid and maxillary canines.

Previous studies reported a decrease with age in the prevalence of teeth with either a dehiscence or a fenestration, or with only a fenestration [5, 9]. The explanation found for this observation was that increase in tooth loss with age resulted in fewer teeth being at risk, although the teeth most frequently affected by fenestrations and dehiscences, were mainly among the teeth least suspected to loss. The prevalence of teeth affected by dehiscences in our study remains somewhat constant through age (3.589–4.598%). We registered a decrease with age only for the prevalence of fenestrations (from 9.302% in the younger age to 6.667% in the oldest group) but in a smaller rate than other reports (13.6% to 6.2% – Rupprecht RD *et al.* [9]), in the circumstances that the most affected teeth by fenestrations (maxillary first molars and mandibular first molars) were not frequently lost. Although specimens that met the requirements for this study were only up to 54 years of age and the oldest group (45–54 years) comprised a small number that could not be statistically significant, nevertheless the question rises if the decreased prevalence of fenestrations with age, was not due to the continuing remodeling of the alveolar bone. Further investigations need to be done to support this hypothesis. Compared to other studies, the superior limit of age of the examined specimens was lower (54 compared to 87 – Rupprecht RD *et al.* [9]). We did not make this choice on purpose, but older specimens could not meet the inclusion criteria of the study, an explanation to it being the rapid evolution towards the “edentulous state” of the stomatognathic system of that period.

Possible etiologic factors for the existence of the two situations have been pointed out and taken into account in previous studies, especially the prominent roots in combination with a thin alveolar bone plate. In the present study we did not take these factors into consideration, as we agreed there were no objective criteria of defining normalcy with regard the thickness of the alveolar plate; furthermore, we appreciated that a 'thin plate' could be a *post-mortem* artifact. Great interest also exists in previous anatomical and clinical studies regarding the influence that the occlusal forces could have on the morphology of the alveolar bone. More than three decades ago, it was thought that an important etiologic factor for the development of fenestrations and dehiscences was an excessive occlusal force [18]. In 1963, Stahl S *et al.* [10] found attrition (indicative of excessive occlusal forces) present in all the teeth identified as having fenestrations. Edel A could find no clear relationship between the presence of occlusal wear and the presence of dehiscences and fenestrations [6]. The results of our study are consistent with those of Rupprecht RD *et al.* study [9]: the affected teeth and the entire dentition of the affected skulls lack attrition in a high percentage, and this is the reason why we could consider lack of attrition as a *predictor* for the presence of dehiscences and fenestrations. Furthermore, nowadays it is well documented that excessive occlusal forces can determine buccal alveolar bone ledges and exostosis, rather than cortical wedges [19].

Depiction of dehiscences and fenestrations through CT-examinations was beyond the purpose of this study; still the investigation was performed in order to find out if it was possible to correlate the presence of alveolar bone defects with teeth arrangement in the jaws. The results of our investigations point to the hypothesis issued by Schroeder HE [20] and abandoned in later research, that dehiscences were a consequence of teeth malalignment. Our findings enable us to extend the etiology suggested by Schroeder HE to both types of cortical wedges, fenestrations and dehiscences. The more the deviation from the normal bucco-lingual inclination of the tooth, the more the defect (it is the case of the first maxillary molar in Figure 5).

The high percentage of examined skulls (89.855%) and associated teeth that presented dehiscences and fenestrations (12.808%) confirm that both situations are common findings related to the presence of the teeth. The high incidence of dehiscences and fenestrations in younger ages, together with the exclusion of specimens that had periodontal and endodontic pathosis, or secondary tilting due to edentulism, lead us to believe that *dehiscences and fenestrations are primary non-pathological conditions that develop through the circumstances of a closed teeth-supporting bone relationship*. We agree that fenestrations and dehiscences occur right after the conclusion of tooth eruption because of the prominence of the tooth position in relation to the dental arch. Variation in teeth positioning in the arch (such as buccoversion, linguoversion, supereruption, intrusion, etc.) appears to be the major determinant factor of cortical plate thickness and contour.

An alveolar bone dehiscence is considered to be a prerequisite for the development of a gingival recession (displacement of the soft tissue margin apical to the cemento-enamel junction with exposure of the root surface) [21, 22]. Towards the teeth apices, the facial bone plate becomes thicker and spongy bone fills the interval between the facial and the lingual cortical plates. In these thicker areas, recession generally stops spontaneously. With his study performed at the time of periodontal flap surgery of 50 recession sites, which included 113 affected teeth, Löst C determined that a recession depth of 1 mm was exceeded by an average of 2.8 mm towards the apex by the alveolar bone dehiscence, and each 1 mm increase in recession depth involved an average increase of 0.98 mm in the alveolar bone dehiscence [21].

While dehiscences could be made *in vivo* evident through the above described mechanism, not the same can be said regarding fenestrations: their existence is usually clinically unexpected. There are rare situations in which an endodontic pathosis superimposed some anatomic data, thus contributing to the clinical exposure of the apical third of the dental root (one situation encountered in our practice – Figure 7). Of clinical importance is that fenestrations and dehiscences cannot be evaluated on conventional dental radiographs. Also, through modern high-resolution computer tomography the identification opportunity is reduced and depends on the existence of a large periodontal ligament [23, 24].

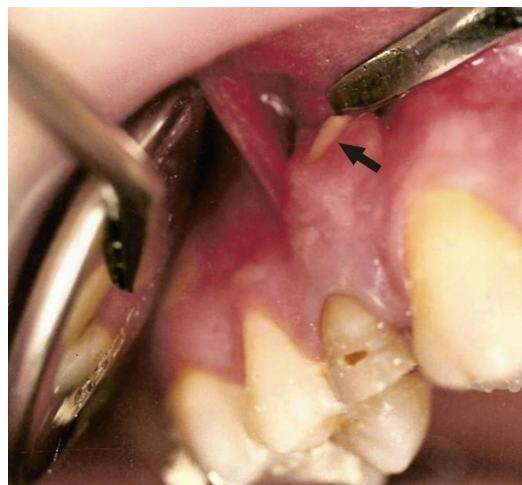

Figure 7 – *Exposure of the dental root in the oral cavity due to an endodontic pathosis that superimposed a fenestration at the level of the maxillary first premolar.*

Exposure of alveolar bone commonly occurs during periodontal and oral surgery, and the presence of fenestrations and dehiscences is of great importance as they may complicate the outcome during the healing process [25]. Special considerations must be taken into account as regards the current trend in oral implantology – *the flapless approach* [26]; through this procedure, one may not always be aware of the presence of fenestrations and dehiscences, a situation that can negatively affect both osseointegration and the aesthetic result [27]. Further research needs to be done related to the influence of dehiscences and fenestrations on the rate and pattern of bone loss and on alveolar bone healing.

High-risk sites, the maxillary first molar, the mandibular first molar, the mandibular canine and first bicuspid, must be carefully evaluated through oral surgery procedures. *The great possibility of developing multiple associated defects in the two jaws must be taken into account.* With regard to oral implantology, bone augmentation has to be implemented, so that dehiscences and fenestrations will be covered during endo-osseous implant placement and the alveolar bone integrity during tooth extraction could be maintained as much as possible.

Conclusions

The potential of developing fenestrations and dehiscences must be carefully evaluated through oral surgery procedures. With regard to implant placement, this study aims to help the clinician design and manage treatment, in order to clinically correct the conditions and identify the principles of bone augmentation, so that endo-osseous implants can be properly placed.

Acknowledgements

This research was sustained by VIASAN Research Grant No. 101/2006.

References

- [1] HASSELL T. M., *Tissues and cells of the periodontium*, Periodontol 2000, 1993, 3:9–38.
- [2] BRAND R. W., ISSELHARD D. E., *Anatomy of orofacial structures*, 7th edition, Mosby, St. Louis, 2003.
- [3] CARRANZA F. A., BERNARD G. W., The tooth supporting structures. In: NEWMAN M. G., TAKEI H. H., CARRANZA F. A. (eds), *Carranza's Clinical Periodontology*, 9th edition, W. B. Saunders & Co., Philadelphia, 2002, 36–57.
- [4] ABDELMALEK R. G., BISSADA N. F., *Incidence and distribution of alveolar bony dehiscence and fenestration in dry human Egyptian jaws*, J Periodontol, 1973, 44(9):586–588.
- [5] DAVIES R. M., DOWNER M. C., HULL P. S., LENNON M. A., *Alveolar defects in human skulls*, J Clin Periodontol, 1974, 1(2):107–111.
- [6] EDEL A., *Alveolar bone fenestrations and dehiscences in dry Bedouin jaws*, J Clin Periodontol, 1981, 8(6):491–499.
- [7] ELLIOT J. R., BOWERS G. M., *Alveolar dehiscence and fenestration*, Periodontics, 1963, 1:245–248.
- [8] LARATO D. C., *Alveolar plate fenestrations and dehiscences of human skull*, Oral Surg Oral Med Oral Pathol, 1970, 29(6):816–819.
- [9] RUPPRECHT R. D., HORNING G. M., NICOLL B. K., COHEN M. E., *Prevalence of dehiscences and fenestrations in modern American skulls*, J Periodontol, 2001, 72(6):722–729.
- [10] STAHL S., CANTOR M., ZWIG F., *Fenestrations of the labial alveolar plate in human skulls*, Periodontics, 1963, 1:99–102.
- [11] TAL H., *Alveolar dehiscence and fenestrae in dried South African Negro mandibles*, Am J Phys Anthropol, 1983, 61:173–179.
- [12] DEMPSTER W. T., ADAMS W. J., DUDDLES R. A., *Arrangement in the jaws of the roots of the teeth*, J Am Dent Assoc, 1963, 67:779–797.
- [13] TEN CATE A. R., Hard tissue formation and destruction. In: TEN CATE A. R. (ed), *Oral histology: development, structure and function*, 5th edition, Mosby, St. Louis, 1998.
- [14] ZERNIK J. H., NOWROOZI N., LIU Y. H., MAXSON R., *Development, maturation, and aging of the alveolar bone. New insights*, Dent Clin North Am, 1997, 41(1):1–15.
- [15] BECKER W., OCHSENBEIN C., TIBBETTS L., BECKER B. E., *Alveolar bone anatomic profiles as measured from dry skulls. Clinical ramifications*, J Clin Periodontol, 1997, 24(10):727–731.
- [16] ASH M. M. JR., *Wheeler's dental anatomy, physiology and occlusion*, 8th edition, W. B. Saunders, Philadelphia, 1992.
- [17] O'CONNOR T. W., *Alveolar bony contours. A thesis submitted to the Faculty of Baylor University Dallas, Texas*, 1963.
- [18] GLICKMAN I., *Clinical periodontology*, 4th edition, W. B. Saunders, Philadelphia–London, 1972.
- [19] HORNING G. M., COHEN M. E., NEILS T. A., *Buccal alveolar exostoses: prevalence, characteristics, and evidence for buttressing bone formation*, J Periodontol, 2000, 71(6):1032–1042.
- [20] SCHROEDER H. E., *Orale Strukturbilogie*, Thieme, Stuttgart, 1976.
- [21] LÖST C., *Depth of alveolar bone dehiscences in relation to gingival recessions*, J Clin Periodontol, 1984, 11(9):583–589.
- [22] WOLF H. F., RATEITSCHAK E. M., RATEITSCHAK K. H., *Color atlas of dental medicine. Periodontology*, Thieme, Stuttgart, 2004.
- [23] FUHRMANN R. A., WEHRBEIN H., LANGEN H. J., DIEDRICH P. R., *Assessment of the dentate alveolar process with high resolution computed tomography*, Dentomaxillofac Radiol, 1995, 24(1):50–54.
- [24] FUHRMANN R. A., *Three-dimensional interpretation of alveolar bone dehiscences. An anatomical-radiological study – Part I*, J Orofac Orthop, 1996, 57(2):62–74.
- [25] POLIMENI G., KOO K. T., QAHASH M., XIROPAIDIS A. V., ALBANDAR J. M., WIKESJÖ U. M., *Prognostic factors for alveolar regeneration: bone formation at teeth and titanium implants*, J Clin Periodontol, 2004, 31(11):927–932.
- [26] CAMPELO L. D., CAMARA J. R., *Flapless implant surgery: a 10-year clinical retrospective analysis*, Int J Oral Maxillofac Implants, 2002, 17(2):271–276.
- [27] SAMMARTINO G., MARENZI G., DI LAURO A. E., PAOLANTONI G., *Anesthetics in oral implantology: biological, clinical, surgical, and prosthetic aspects*, Implant Dent, 2007, 16(1):54–65.

Corresponding author

Vanda Roxana Nimigean, Associate Professor, DMD, DDS, PhD, Department of Oral Rehabilitation, Faculty of Dental Medicine, "Carol Davila" University of Medicine and Pharmacy, 17–21 Calea Plevnei Street, 010221 Bucharest, Romania; Phone +40721–561 848, e-mail: vandanimigean@yahoo.com

Received: April 15th, 2009

Accepted: August 5th, 2009