

## CASE REPORT

# Unusual communication between the lingual nerve and mylohyoid nerves in a South Indian male cadaver: its clinical significance

BHAGATH KUMAR POTU<sup>1)</sup>, THEJODHAR PULAKUNTA<sup>2)</sup>, BISWABINA RAY<sup>1)</sup>,  
MUDDANNA S. RAO<sup>1)</sup>, K. M. R. BHAT<sup>1)</sup>, SUHANI SUMALATHA D'SILVA<sup>1)</sup>,  
S. R. NAYAK<sup>3)</sup>

<sup>1)</sup>Department of Anatomy, Centre for Basic Sciences,  
Kasturba Medical College, Manipal University, Manipal, Karnataka, India

<sup>2)</sup>Department of Anatomical Sciences, St. Matthew's University School of Medicine,  
Grand Cayman, Cayman Islands, British West Indies

<sup>3)</sup>Department of Anatomy, Centre for Basic Sciences,  
Kasturba Medical College, Manipal University, Mangalore, Karnataka, India

### Abstract

It is well known that variations in the branching pattern of the mandibular nerve frequently account for the failure to obtain adequate local anesthesia in routine oral and dental procedures, and also for the unexpected injury to branches of the nerves during surgery. During our routine dissection, we found the presence of a communicating branch between the mylohyoid and lingual nerves in a middle aged male cadaver. We also discussed its clinical and surgical implications in this report.

**Keywords:** mylohyoid nerve, lingual nerve, communicating branch.

### Introduction

The mylohyoid nerve (MHN) is a branch of the inferior alveolar nerve (IAN), which arises above the mandibular foramen. The nerve then passes downward and anteriorly within the mylohyoid groove on the medial surface of the mandible. The nerve courses anteriorly and parallel to the mylohyoid muscle and giving branches that provide motor innervation to the mylohyoid and anterior belly of the digastric muscles [1].

The mylohyoid muscle plays an important role in chewing, swallowing, respiration and phonation [2]. It has been analyzed that the MHN might have a role in the sensory innervation of the chin [3]. The role of the MHN in the mandibular posterior tooth sensation is still a controversial issue [1]. In the present case, we report an abnormal communication between mylohyoid and lingual nerves.

### Materials and Methods

During routine dissection in the Department of Anatomy, Kasturba Medical College, Manipal University, an abnormal communication between the mylohyoid and lingual nerves of a middle-aged male cadaver was noted. This variation was found only in one of 15 cadavers studied.

### Results

In the present case, immediately after the inferior alveolar nerve (IAN) entered the inferior alveolar canal,

the MHN appeared thicker than usual. Approximately, at the level of the intermediate tendon of the digastric muscle, the MHN gave off a thick branch that joined the Lingual nerve (LN). Thereafter, the MHN followed its normal course and branching pattern (Figure 1). No other anatomical variations were found in the origin of inferior alveolar or the lingual nerves. In addition, no communicating branches between these two nerves were found. The LN, after receiving this communicating branch from the MHN, was observed taking its normal course and branching pattern.

### Discussion

The communicating branches between the IAN and the LN were well described in literature [4] and these communications have been identified as a possible explanation for the inefficiency of mandibular anesthesia [5].

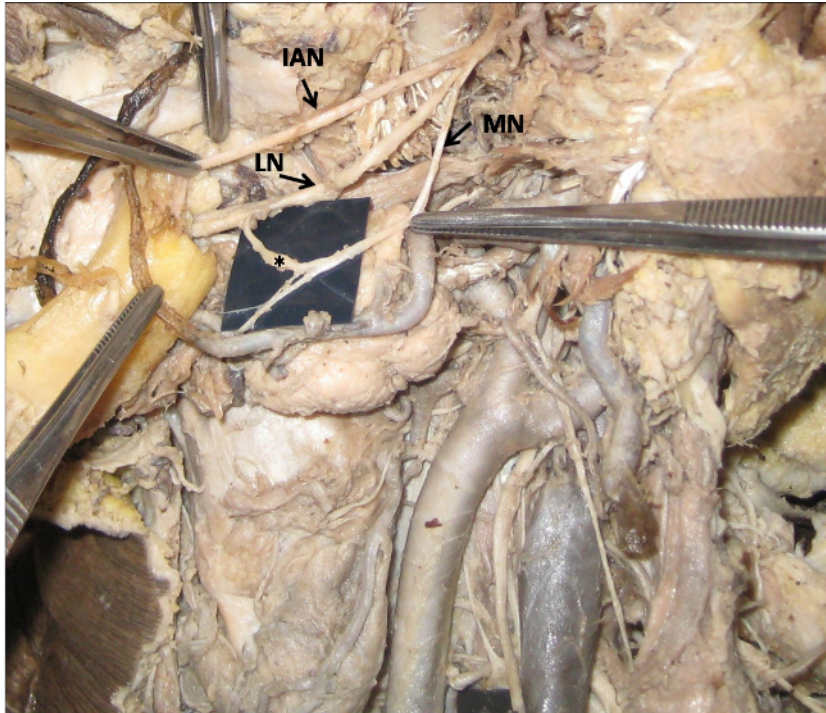
The presence of communicating branches between the inferior alveolar and lingual nerves is very commonly mentioned in most of the anatomical textbooks. Nevertheless, a communicating branch between the mylohyoid and lingual nerves is seldom described in literature and also not regularly mentioned in the anatomical textbooks.

The communication between the mylohyoid and lingual nerves in this case was found to occur after the LN passes in close relation to the third molar tooth. Since this close relationship of the LN and the third molar tooth makes it susceptible to injury during the third molar extraction [6], the presence of a nerve

communication like the one described in this case would help in the LN function recovery [7].

The communicating branch between the MHN and

LN might also innervate the tongue and surgeons should be aware of this variation to avoid unexpected findings after oral nerve surgeries.



**Figure 1 – Photograph showing the abnormal communication between the lingual and mylohyoid nerves. Abbreviations: IAN – Inferior alveolar nerve; LN – Lingual nerve; MHN – Mylohyoid nerve. Asterisks showing the communication between the two nerves.**

## ☒ Conclusions

The abnormal communication between the MHN and LN should be kept in mind during radical neck dissection and in dental practice to avoid unnecessary complications.

## Acknowledgements

Authors sincerely thank Dr. Narga Nair, Professor and Head of Department of Anatomy for her support and co-operation.

## References

- [1] CLARK S., READER A., BECK M., MEYERS W. J., *Anesthetic efficacy of the mylohyoid nerve block and combination inferior alveolar nerve block/mylohyoid nerve block*, Oral Surg Oral Med Oral Pathol Oral Radiol Endod, 1999, 87(5):557–563.
- [2] REN M., MU L., *Intrinsic properties of the adult human mylohyoid muscle: neural organization, fiber-type distribution, and myosin heavy chain expression*, Dysphagia, 2005, 20(3):182–194.
- [3] GUYOT L., LAYOUN W., RICHARD O., CHEYNET F., GOLA R., *Alteration of chin sensibility due to damage of the cutaneous branch of the mylohyoid nerve during genioplasty*, J Oral Maxillofac Surg, 2002, 60(11):1371–1373.
- [4] SAKAMOTO Y., AKITA K., *Spatial relationships between masticatory muscles and their innervating nerves in man with special reference to the medial pterygoid muscle and its accessory muscle bundle*, Surg Radiol Anat, 2004, 26(2):122–127.
- [5] RÁCZ V. L., MAROS T., SERES-STURM L., *Anatomical variations of the nervus alveolaris inferior and their importance for the practice*, Anat Anz, 1981, 149(4):239–332.
- [6] BEHNIA H., KHERADVAR A., SHAHROKHI M., *An anatomic study of the lingual nerve in the third molar region*, J Oral Maxillofac Surg, 2000, 58(6):649–651; discussion 652–653.
- [7] SASSOLI FAZAN V. P., RODRIGUES FILHO O. A., MATAMATA F., *Communication between the mylohyoid and lingual nerves: clinical implications*, Int J Morphol, 2007, 25(3):561–564.

## Corresponding author

Bhagath Kumar Potu, Lecturer, Department of Anatomy, Centre for Basic Sciences, Kasturba Medical College, Manipal University, 576104 Manipal, Karnataka, India; Phone 91–820–2922327, Fax 91–820–2570061, e-mail: potukumar2000@gmail.com

Received: May 10<sup>th</sup>, 2008

Accepted: January 20<sup>th</sup>, 2009