

CASE REPORT

Superficial peroneal nerve lipoma

J. TERRENCE JOSE JEROME

*Department of Orthopedics,
St. Stephen's Hospital, Tiz Hazari, Delhi, India*

Abstract

Lipoma is one of the most common benign soft tissue tumors. The most common location of lipomas is in areas of abundant adipose tissue. Lipomas arising in the peripheral nerves are rare tumors, with most arising in the forearm and wrist, and most have occurred within the median nerve. This report describes a case with lipoma arising in the superficial peroneal nerve.

Keywords: superficial, peroneal nerve, lipoma, rare, diagnosis.

☞ Introduction

Intraneural lipomas are well encapsulated and have more predominance in the upper limb. There is paucity of literature for intraneural lipoma involving superficial peroneal nerve. Total resection of symptomatic intraneural lipomas is possible and apparently curative. Recurrence and malignant changes are exceedingly rare complications.

☞ Patient, Methods and Results

A 25-year-old man came to our outpatient clinic with painless progressive swelling in the right foot for 12 months duration. There was no history of trauma and constitutional symptoms. His blood parameters were normal. His motor and sensory examination was normal. He came for the swelling to be examined and treated.

There was an oval shaped swelling in the dorsal aspect of the right foot over the superficial peroneal nerve measuring 6×3 cm. It was soft, non-tender, mobile in side-to-side direction only and free from skin and underlying structures. The radiographs were normal except for a small radiolucency in the soft tissues of dorsum of foot. The preoperative impression was that the mass was a subcutaneous lipoma.

Excision of the mass was planned under spinal anesthesia. The superficial peroneal nerve was located in the proximal part of the ankle and followed distally. Intra-operative findings witnessed a spindle shaped, lobulated, and homogeneously firm in appearance and consistent mass along the nerve (Figure 1, a and b).

The nerve was found enlarged from infiltration by lipomatous tissue. Under magnification, the entire lipoma and the nerve were visualized. The portion of the nerve involved by the infiltrating lipoma measured 6 cm in length and was 3 cm at its widest point.

Intra-neural excision of the lipoma was done under magnification without damaging the nerve. Patient was given below knee slab. Patient had no neurological deficit in the post-operative period.

The histological sections shows well-encapsulated benign mature adipose tissue composed of predominantly polygonal adipocytes enveloping and dissecting through intact nerve fascicles. Numerous capillaries were also present. Occasional nerves were noted within the fields of the fibro-fatty tissue. There was no malignancy. There were no cysts, hemorrhage, and necrosis seen (Figure 2, a and b).

The sutures were removed at the end of two weeks. Patient is comfortable at the end of two years and doing his normal activities.

☞ Discussion

Adipose tissue is a normal constituent of peripheral nerves, usually located within the perineurium and epineurium. There are adipose cells in the interfascial tissues of nerves, more prominently in the lower extremities and in proximal (larger) nerves [1].

Intraneural lipomatous tumors are believed to arise from these normally occurring intraneural adipose cells. It is found infiltrating between the nerve bundles. It may also arise from the nerve sheath. The term is used to include all of the nerve without regard to combinations with other tissues [2]. It most commonly occurs in the upper extremity in infants and children, usually affecting the median nerve [3–6].

Reports of a lipoma in the foot exist, but the occurrence of the tumor in this location is very rare [6]. Rydholm A and Berg NO reported a 2.5% total incidence of lipomas occurring in the legs and feet in a 428-patient series without precise locations [7].

In 1978, Terzis JK *et al.* classified benign fatty tumors of the peripheral nerves into three types: well-encapsulated intraneural lipomas, diffusely infiltrating fibro-fatty tumors (lipofibromatous hamartomas) and macrodystrophia lipomatosa (an infiltrating fibro-fatty lesion with associated focal macrodactyly [8]).

Significant differences were noted between the well-encapsulated and the diffusely infiltrative lipofibromatous hamartoma types of intraneural lipomas.

The average age at the time of appearance of the well-encapsulated type is 45 years, with female predominance, while the infiltrative type arises in a younger age group (average age, eight years) with no sexual predominance [9–11].

Chiao HC *et al.* reviewed the literature from 1932 to 1985 and found five cases of well-encapsulated lipomas arising from peripheral nerves to which they added their own patient. Intraneural lipomas are usually painless or cause only minimal discomfort [10, 11].

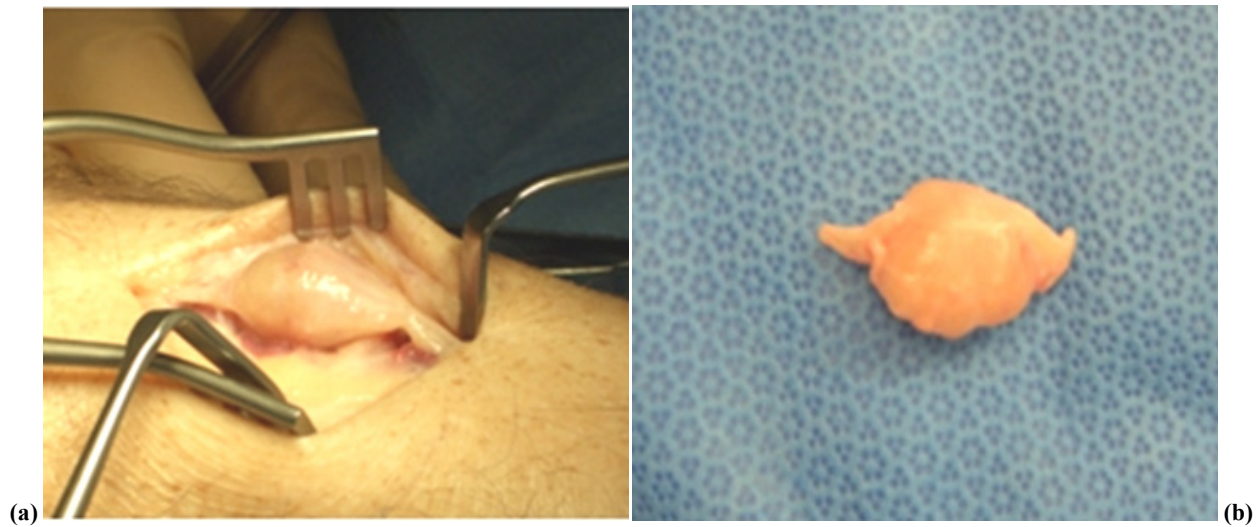


Figure 1 – (a), (b). Oval shaped lobulated, and homogeneously firm superficial peroneal lipoma.

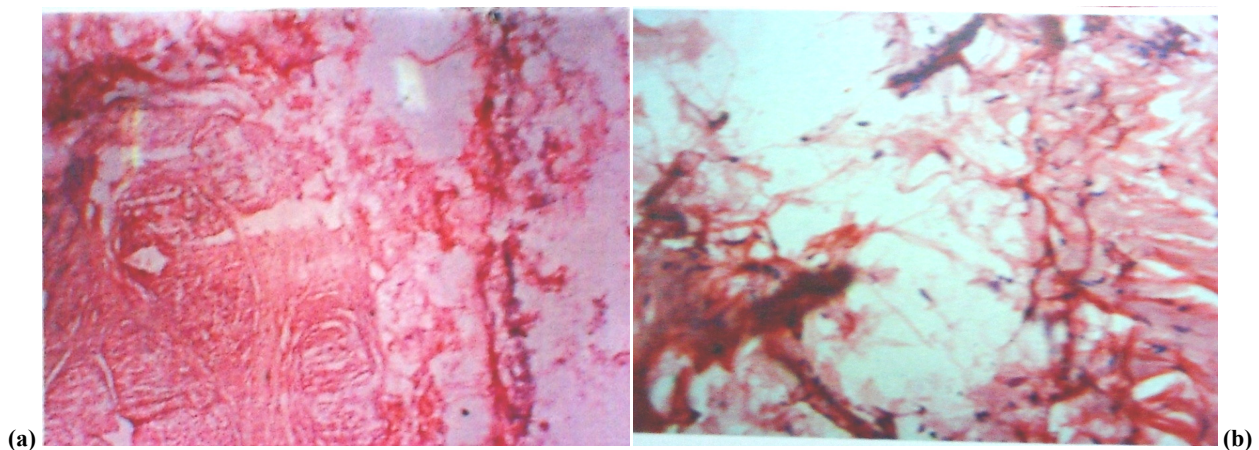


Figure 2 – (a), (b). Photomicrographs of the intraneural lipoma showing a homogeneous population of mature adipocytes with delicate connective tissue septations.

Sensory symptoms usually occur in the late stages of this condition. Wardle stated that there is general agreement that tumors of the nerve sheath grow very slowly and rarely produce neurological symptoms. They cause symptoms by pressure on adjacent nerves. This occurs only in the late stages of an intraneural lipoma [12–14].

The tumors arose from the median nerve, the sciatic nerve, or the brachial plexus. All patients were women between the ages of 34 and 63 years (mean 46 years) at presentation. In five of six patients, the mass had first been noticed within five years of presentation; however one patient had been aware of its presence since childhood. Compressive neuropathic symptoms of the involved nerve were found in most cases. There was no clear origin or correlation with trauma, although a remote fall on the affected hand was noted in the medical history of one patient [1].

As with all neoplasms, the etiology of lipomata is

unknown [10–14]. Bloom W and Fawcett DW have substantiated the presence of fat cells in the nerve sheath with microscopic findings of lipomatous infiltration of the epineurium with a plane of cleavage between the sheath and the nerve proper [12].

Excision of the lipoma in most cases is possible with magnification, and attempts should be taken to remove it carefully. Total excision is recommended in cases of the well-encapsulated type. Attempts to excise the diffusely infiltrative type are likely to fail [11, 12]. Lipomas may recur locally, but after local excision, the recurrence rate is less than 5% of all tumors. Malignant changes in a lipoma are exceedingly rare, and only a few examples have been reported in the literature [13–16].

A differential diagnosis of lipomas from sarcomas must be performed. Patient age, sex, and duration of symptoms are of minor value for clinical differentiation of lipoma and sarcoma. Deep-seated tumors larger

than 5 cm are relatively more likely to be sarcomas. This assessment is useful for the selection of patients with soft tissue lesions who should be referred to a tumor center before any operation [7].

Although we currently have only limited knowledge of their origin and optimal management because of the paucity of reported cases with prolonged follow-up, a few suggestions may be derived from the available literature. Intra-neural lipomas are well-encapsulated, and can usually be resected completely while preserving the involved nerve. Gross-total resection appears to be curative.

Our patient came with a painless progressive swelling over the dorsum of the foot. It was a well-encapsulated intra-neural lipoma. Complete excision was possible under magnification. The patient was very happy after the surgery and had no neurological deficit.

☐ Conclusions

Intra-neural lipoma of the superficial peroneal nerve is a rare entity. They are slow growing asymptomatic tumors. Microsurgical complete excision of the tumor is the treatment of choice. Reports of such rare intra-neural lipomas need publication and the treatment protocol shared among the surgeons.

References

- [1] CHÂTILLON C. E., GUIOT M. C., JACQUES L., *Lipomatous, vascular, and chondromatous benign tumors of the peripheral nerves: representative cases and review of the literature*, Neurosurg Focus, 2007, 22(6):E18.
- [2] FRIEDLANDER H. L., ROSENBERG N. J., GRAUBARD D. J., *Intra-neural lipoma of the median nerve. Report of two cases and review of literature*, J Bone Joint Surg Am, 1969, 51(2):352–362.
- [3] PHALEN G. S., KENDRIK J. I., RODRIGUEZ J. M., *Lipomas of the upper extremity. A series of fifteen tumors in the hand and wrist and six tumors causing nerve compression*, Am J Surg, 1971, 121(3):298–306.
- [4] PASSARETTI U., MESSORE L., LANZA F., *A 2d case of intra-neural lipoma of the median nerve at the wrist (case reports)*, Chir Organi Mov, 1978, 64(4):435–438.
- [5] MATSUO T., SUGITA T., SHIMOSE S., KUBO T., YASUNAGA Y., OCHI M., *Intra-neural lipoma of the posterior interosseous nerve*, J Hand Surg [Am], 2007, 32(10):1530–1532.
- [6] DONLEY B. G., NEEL M., MITIAS H. M., *Neural fibrolipoma of the foot: a case report*, Foot Ankle Int, 1996, 17(11):712–713.
- [7] RYDHOLM A., BERG N. O., *Size, site and clinical incidence of lipoma. Factors in the differential diagnosis of lipoma and sarcoma*, Acta Orthop Scand, 1983, 54(6):929–934.
- [8] TERZIS J. K., DANIEL R. K., WILLIAMS H. B., SPENCER P. S., *Benign fatty tumors of the peripheral nerves*, Ann Plast Surg, 1978, 1(2):193–216.
- [9] BICK E. M., *Lipoma of the extremities*, Ann Surg, 1936, 104(1):139–143.
- [10] GESCHICKTER C. F., *Lipoid tumors*, Am J Cancer, 1934, 21:617–641.
- [11] CHIAO H. C., MARKS K. E., BAUER T. W., PFLANZE W., *Intra-neural lipoma of the sciatic nerve*, Clin Orthop Relat Res, 1987, (221):267–271.
- [12] BLOOM W., FAWCETT D. W.: *A Textbook of Histology*, 8th edition, W. B. Saunders Co., Philadelphia, 1962, 230.
- [13] WARDLE E. N., *Nerve-sheath tumours*, Br J Surg, 1957, 45(189):58–61.
- [14] AKISUE T., MATSUMOTO K., YAMAMOTO T., KIZAKI T., FUJITA I., YOSHIYA S., KUROSAKA M., *Neural fibrolipoma of the superficial peroneal nerve in the ankle: a case report with immunohistochemical analysis*, Pathol Int, 2002, 52(11):730–733.
- [15] PONTIUS J., ZIELASKOWSKI L. A., KING G., *Extensive lipoma of the foot*, J Am Podiatr Med Assoc, 2003, 93(5):402–405.
- [16] KARAÇAL N., AMBARCOĞLU O., KUTLU N., *Neural fibrolipoma of the foot*, Plast Reconstr Surg, 2004, 114(7):1985.

Corresponding author

J. Terrence Jose Jerome, MD, MBBS, DNB (Ortho), MNAMS (Ortho) FNB (Hand & Microsurgery), Reconstructive Orthopedics, Hand and Micro surgeon, Department of Orthopedics, St Stephen's Hospital, Tiz Hazari, Delhi 54, India; Phone 911–09868086916, e-mail: terrencejose@gmail.com

Received: May 10th, 2008

Accepted: January 25th, 2009