CASE REPORT

A case report on accessory brachialis muscle

RAJANIGANDHA VADGAONKAR, RAJALAKSHMI RAI, ANU V. RANADE, S. R. NAYAK, MANGALA M. PAI, R. LAKSHMI

Department of Anatomy, Kasturba Medical College, Mangalore, Karnataka, India

Abstract

Supernumerary heads or slips of brachialis (anticus) muscle is one among the most striking variations, described and encountered in the dissection routine. Very few studies are quoted in the list of its anomalies. We present a unique occurrence of an accessory brachialis muscle (acBr) that formed a fibro-muscular tunnel after blending with the medial intermuscular septum in the lower part of the arm. This tunnel contained the median nerve, the brachial artery and few additional twigs that innervated the neighboring muscles. Because of its intimate topographical relation with the neurovascular bundle, there is no doubt about its role, in the etiogenesis of various compression syndromes. Also, the brachial flexors received innervation from the median nerve, due to the absence of the musculo-cutaneous nerve. We discuss in this report the possible embryogenesis and the clinical application of this variation that can aid the physicians in their approach and required treatment.

***Keywords*:** brachialis, median nerve entrapment, variation, vascular compression.

Introduction

There are three well-described entrapment syndromes involving the median nerve or its branches, namely carpal tunnel syndrome, pronator teres syndrome and anterior interosseous syndrome [1].

The most commonly reported and documented entrapment syndromes is that of median nerve in carpal tunnel, nevertheless it is also subjected to compression from a number of clinical and other anatomic entities and at different sites. The brachialis muscle arises from the distal half of the anterior humerus, starting on either side of the insertion of the deltoid and extending distally to the cubital articular surface. It also arises from the medial intermuscular septum and inserted into the coronoid process of ulna [2].

Median nerve and brachial artery form the anterior relation of brachialis muscle as they descend towards the cubital fossa running parallel along with it. The most frequent varieties of the brachialis muscle consist of its subdivision into two or more parts, and the distal insertions being irregular and variable. The parts may be attached to the coronoid process of the ulna, radius on or below the tuberosity, fascia of the forearm (brachio-fascialis of Wood), or muscles of the forearm arising from the medial epicondyle [3].

We report a case of possible entrapment of the median nerve and brachial artery due to additional fasciculi of brachialis muscle, which formed an abnormal fibro muscular tunnel above the cubital fossa. Hypertrophy of the muscle fibers related to excessive use is an important factor in the development of isolated vascular, neural, or combined neurovascular lesions.

Material and Methods

In the course of routine dissection for undergraduates at Kasturba Medical College, an anomalous tunnel in the distal part of the flexor compartment of arm in was detected in 56-year-old formalin embalmed female cadaver.

Results

The anomalous tunnel in the distal part of the flexor compartment of arm in was formed by accessory brachialis muscle and was located about 4 cm above the elbow joint (Figure 1).

Some additional fibers from the medial aspect of the anterior surface of brachialis descended downwards and laterally in the form of a distinct belly crossing and forming one of the content of cubital fossa, beneath the bicipital aponeurosis and enter the forearm.

In forearm, it unites with the fibers of pronator teres muscle from radial side forming a common tendon that inserts to the middle of the lateral surface of the shaft of the radius (Figure 1).

This muscular bundle termed as accessory brachialis (acBr), measured 13.8 cm in length and 2.4 cm in width (measured at the midpoint of muscle belly) from proximal to distal attachment.

Proximally, the tendinous fibers fused with the medial intermusular septum of the brachium forming a fibromuscular tunnel, beneath which traversed the median nerve along with the brachial artery (Figure 1).

In the cubital fossa, the relations from medial to lateral side are acBr, median nerve and brachial artery. Immediately deep to acBr are tendon of biceps and the

radial nerve. This muscle belly was innervated by the median nerve from its deeper surface within the tunnel. Along with the innervation to acBr, branches to pronator teres and flexor digitorum superficialis were also given from median nerve within the tunnel. Due to the absence of the musculo-cutaneous nerve, innervation to the brachial flexors was solely shouldered by the median nerve (Figure 1).

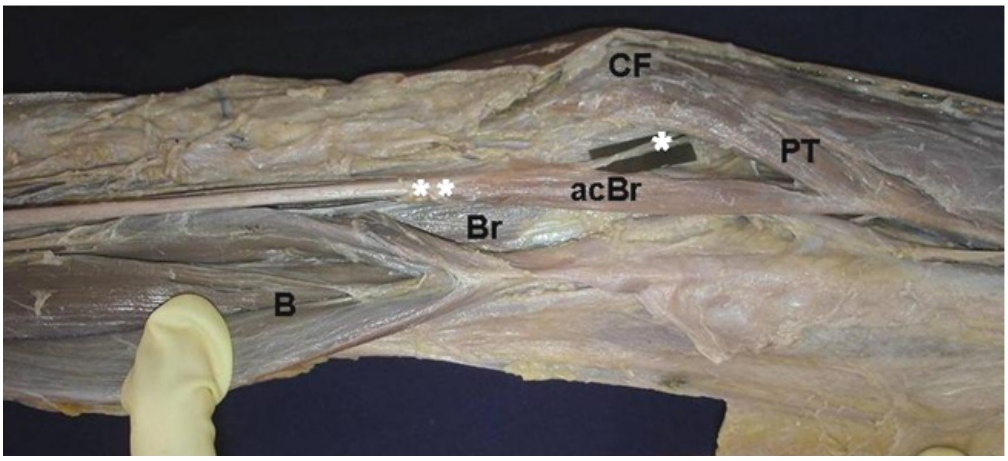

Figure 1 – ***Dissection of the right arm showing accessory brachialis muscle (acBr) forming fibromuscular tunnel (**): B – biceps; Br – brachialis; acBr – accessory brachialis; CF – common flexor origin; PT – pronator teres; * – nerve supply to pronator teres***

Discussion

Variations of brachialis are relatively uncommon when compared with other brachial flexors. Also, there is scanty literature in view of its anomalous presentations. Brachialis may be divided into two or more parts. It may be fused with brachio-radialis, pronator teres or biceps. In some cases, it sends a tendinous slip to the radius or bicipital aponeurosis [2].

Loukas M *et al.* (2006) reported a case of an acBr that took origin from mid shaft of humerus and the medial intermuscular septum [4]. During its course medially, toward the elbow, the acBr crossed both the brachial artery and the median nerve. The distal tendon split to surround the median nerve before inserting into the common tendon of the antebrachial flexor compartment muscles.

In the present case, we have considered acBr as a different muscle entirely due to its well-defined belly and a distinctly separate insertion from those of brachialis muscle itself. The acBr arose proximally from the medial aspect of the brachialis muscle in the lower anterior region of arm and distally, was attached on to the radial shaft in common with the tendon of pronator teres. Due to the above attachment, the acBr muscle will contract in both pronation and flexion. This may predispose to entrapment syndromes, as the above variation may bring closeness of the median nerve and acBr during the movement of the forearm. Embryologically, the precursor of musculoskeletal lineage is derived from the myotome of the somites. Cells in the proximal limb bud secrete several growth factors that stimulate the myoblasts to migrate into the developing limb buds. These pre-muscle cells express adhesion molecules that are important in properly distributing them through out the limb [5].

Loukas M *et al.* opined that presence of an acBr might indicate alterations in the formation and structure of the myotome or somite [4].

Wadhwa S *et al.* (2004) reported a similar case of a musculo-aponeurotic band that originates as the ligament of Struthers but terminates as the brachio-fascialis muscle of Wood and in the process may have entrapped both the median nerve and brachial artery, with the nerve to pronator teres arising from the median nerve within this tunnel [6].

A case report by El-Naggar MM and Al-Saggaf S (2004) describes about a variation in the mode of insertion of coraco-brachialis muscle. Here, in addition to the normal insertion, an additional slender tendon passes inferiorly, crossing anterior to the median nerve and brachial artery before attaching to the medial epicondyle of the humerus [7].

The median nerve and brachial artery traversed a tunnel bounded by the additional tendon and aponeurotic expansion as well as the usual humeral insertion of the coraco-brachialis muscle. Another case by Nakatani T *et al.* (1998) describes an accessory head of biceps brachii that formed a tunnel over the median nerve and the brachial artery, where the nerve and artery seemed to be compressed [8].

Compression of the median nerve at the elbow can result from ligament of Struthers, an anomalous head of triceps or pressure from pronator teres and compression in the forearm can occur in the proximal arch of the flexor digitorum superficialis including compression by the lacertus fibrosus with or without trauma and with partial or complete rupture of the distal biceps insertion [9].

Conclusions

The tunnel formed by the acBr muscle is very important in median nerve entrapment at the level of elbow. In addition, the posterior aspect of the whole length of muscle fibers of acBr was in direct contact with the median nerve. Hence, there would be irritation to the median nerve and exacerbation of the

compression syndrome as the muscle contracts. Another possible clinical symptomatology would be the claudication compression of the brachial artery, which may manifest as irregularities of blood pressure due to its coexistence with the median nerve in the tunnel. Additionally, when doing differential diagnosis of tumors in the brachium by advanced radiological examination, one should not forget about the presence supernumerary or aberrant fasciculi.

References

[1] McNamara B., *Clinical anatomy of the median nerve*, ACNR, 2003, 2(6):19–20.

[2] Williams P. L., Bannister L. H., Berry M. M., Collins P., Dyson M., Dussek J. E., Ferguson M. W. J. (eds), *Gray's Anatomy*, 38th edition, Churchill Livingstone, Edinburgh, 2005, 843–844.

[3] Bergman R. A., Afifi A. K., Miyauchi R., Part I: Muscular system. In: Bergman R. A., Afifi A. K., Miyauchi R., *Illustrated encyclopedia of human anatomic variation*, 2000.

[4] Loukas M., Louis R. G. Jr., South G., Alsheik E., Christopherson C., *A case of an accessory brachialis muscle*, Clin Anat, 2006, 19(6):550–553.

[5] Carlson B. M., *Human embryology and developmental biology*, 3rd edition, Mosby, St. Louis, 2004, 224–225.

[6] Wadhwa S., Mehra S., Khan R. Q., Kapur V., *Abnormal musculoaponeurotic tunnel in the arm: possible entrapment of the median nerve and brachial artery with high origin of nerve to pronator teres within tunnel*, Clin Anat, 2004, 17(4):360–363.

[7] El-Naggar M. M., Al-Saggaf S., *Variant of the coracobrachialis muscle with a tunnel for the median nerve and brachial artery*, Clin Anat, 2004, 17(2):139–143.

[8] Nakatani T., Tanaka S., Mizukami S., *Bilateral four-headed biceps brachii muscles: the median nerve and brachial artery passing through a tunnel formed by a muscle slip from the accessory head*, Clin Anat, 1998, 11(3):209–212.

[9] Seitz W. H. Jr., Matsuoka H., McAdoo J., Sherman G., Stickney D. P., *Acute compression of the median nerve at the elbow by the lacertus fibrosus*, J Shoulder Elbow Surg, 2007, 16(1):91–94.

Corresponding author

Rajalakshmi Rai, Senior Grade Lecturer, Department of Anatomy, Kasturba Medical College, Mangalore–575 004, Karnataka, India; +91 824 2211746, Fax +91 824 2428183, E-mail: rajalakshmirai@yahoo.co.in

Received: April 8th, 2008

Accepted: September 12th, 2008