

CASE REPORT

Multiple muscular anomalies of upper extremity: a cadaveric study

S. R. NAYAK, A. KRISHNAMURTHY, LAKSHMI A. RAMANATHAN,
LATHA V. PRABHU, C. GANESH KUMAR,
DINIT K. TOM, TERESA JOY

*Department of Anatomy, Centre for Basic Sciences,
Kasturba Medical College, Bejai, Mangalore, Karnataka, India*

Abstract

During routine cadaveric dissection, we encountered multiple muscular anomalies in a 58-year-old embalmed male cadaver. All the variations were encountered on the flexor compartment of right upper limb. The anomalies include an axillary arch (Aa) in the axilla, a third head of biceps brachii (Thb) in the arm, a reverse palmaris longus (Rpl) and a Gantzer's muscle (Gm) in the forearm and an unusually large palmaris brevis muscle (Pbm) in the palm. Anatomical description is achieved by measuring the length, width and attachments of the above-mentioned variants. The morphological and clinical significance of the anomalous muscles are discussed.

Keywords: anomalous muscles, axillary arch, third head of biceps brachii, reverse palmaris longus, palmaris brevis.

☞ Introduction

Anomalous muscles usually do not cause symptoms but are of academic interest. They become a surgical problem when they produce symptoms or are difficult to differentiate from soft-tissue tumors. In the present study there are multiple muscular anomalies found in the flexor compartments of right upper limb. Variable muscle slips such as chondro-epitrochlearis, dorso-epitrochlearis, costo-coracoideus or axillary arches (Aa) are occasionally encountered in the axilla [1]. It measures 7–10 cm in length and 0.5–1.5 cm in breadth, and extends from the edge of latissimus dorsi to the pectoralis major, or coracobrachialis or to the fascia covering the biceps brachii [2].

The occurrence of Aa arches varies in different races, as low as 0.25% in British to 10% in Belgian subjects [3, 4]. In Japanese and South Indian population, it is 7% and 1.47% respectively [5, 6].

The biceps brachii muscle is classically described as a two-headed muscle that originates proximally, with a long head from the supraglenoid tubercle and short head from the coracoid process of the scapula. Distally these heads join to form a common tendon, that gets inserted to the posterior aspect of the radial tuberosity [7], mainly contributing to the flexion and supination of the forearm. Some aponeurotic and tendinous fibers gain insertion into the bicipital aponeurosis. Occasionally, humans possess a third head of biceps brachii [8].

Testut L (1902) has described the biceps brachii muscle as one of the muscles with most frequent anatomic variations [9].

In the human, the occasional presence of the third head has been reported with varying frequency according to the population; i.e., Chinese 8%, European white 10%, African black 12%, Japanese 18%,

South African blacks 20.5%, South African whites 8.3%, and Colombian 37.5% [10–12].

Palmaris longus is a slender, fusiform muscle medial to flexor carpi radialis. It springs from the medial epicondyle by the common tendon, and from adjacent intermuscular septa and deep fascia. It converges on a long tendon, which passes anterior (superficial) to the flexor retinaculum, as the tendon crosses the retinaculum it broadens out to become a flat sheet which becomes incorporated into the palmar aponeurosis. Palmaris longus is often absent on one or both sides [13]. The muscle may have a proximal tendon or be reduced to a tendinous strand. It may be digastric or reduplicated. It may also end in antebrachial fascia, tendon of flexor carpi ulnaris, pisiform, scaphoid etc. [14].

The palmaris longus muscle that is tendinous in its upper part and muscular in its lower part as found in the present case was named as “reversed palmaris longus” by Still JM Jr and Kleinert HE (1973) [15]. The existence of a three-headed palmaris longus muscle was also reported in the literature twice [16, 17].

In 1813, Gantzer described two accessory muscles in the human forearm which bear his name [18]. Frequently a slip connects flexor digitorum superficialis (Fds) muscle with the long flexor of the thumb {flexor pollicis longus (Fpl)} or flexor digitorum profundus (Fdp) as muscular slips occasionally pass between superficialis and deep flexors of the fingers. Sometimes a muscular slip derived, but separated from superficialis, or on a tendon that joins one of the tendons of the deep flexor (accessorius profundus digitorum [Gantzer]) is found [19].

The shape of the Gantzer's muscle has been described as fleshy and fusiform [18] or either fusiform (50%) or a flat slip (50%) [20].

The most common singular point of origin of Gantzer's muscle was found under the surface of the Fds, same as in the present case [21]. The palmaris brevis muscle (Pbm) and other hypothenar muscles play major role in the grasping mechanism. The Pbm is a thin, quadrilateral muscle, lying beneath the skin of the ulnar side of the palm. It arises from the flexor retinaculum and the medial border of the central part of the palmar aponeurosis, and is attached to the dermis on the ulnar border of the hand [22].

Unlike other hypothenar muscles the Pbm variation in literature is vague. Accessory Pbm and The palmaris brevis profundus muscle has been reported in literature [23, 24]. The Pbm may be doubled and may simulate a soft-tissue tumor of the hand (Lipscomb PR, 1960) [25].

☞ Material and methods

During routine cadaveric dissection in the department of Anatomy, KMC, Mangalore, India, we dissected 15 male and five female cadavers' upper limbs for the academic year 2005–2006. Out of the 40 upper limbs, one of the right upper limb belonging to a 58-year-old male cadaver, found to have five different muscular anomalies involving all the flexor compartments of right upper limb. Anatomical description is achieved by measuring the length, width and attachments of the anomalous muscles.

☞ Results

Variation I

In the axilla, we came across an anomalous axillary arch muscle from the upper part of the latissimus dorsi muscle, 7.8 cm before its insertion and ran below the pectoralis major, crossed over the axillary neuro-vascular structures and was very closely related to the intercosto-brachial nerve, to be inserted into the fascia covering the common tendon of short head of biceps brachii and coracobrachialis. The length of the axillary arch (Aa) was 8.6 cm and was running in the mid-axillary region (Figure 1).

Variation II

In the arm, there was a third head of the biceps brachii originated from the antero-medial aspect of the humerus, from the middle of the shaft of the humerus. The tendon of third head joined the tendon of biceps brachii to be inserted to the radial tuberosity. The length and breadth of additional biceps brachii was 13.1 cm and 1.9 cm respectively. The bicep with its third head was innervated by the musculocutaneous nerve (Figure 2).

Variation III

In the forearm, the palmaris longus took origin from the medial epicondyle by the common flexor tendon and from the ante-brachial fascia. However, the origin instead of being by a muscle belly was found to be by a long thin tendon (15.2 cm). The tendon was replaced by a muscle belly around the distal 2/3rd of the forearm. Just proximal to the wrist joint the muscle fibers ended

and a tendon continued into the palmar aponeurosis. The length and breadth of the distal muscle belly was 8.9 cm and 1.6 cm respectively (Figure 3).

Variation IV

In the forearm from the under surface of the Fds muscle, 2.4 cm distal to its origin from the medial epicondyle, there was an accessory muscle (Gm) took origin as a slender muscular belly (length, 5.5 cm and breadth, 0.3 cm). The muscle then converted into a tendon (9.7 cm) and ran on the ulnar side of the median nerve and below the Fds muscle to be inserted into the tendon of Fdp to the middle finger (Figure 4).

Variation V

In the palm, an anomalous Pbm muscle took origin from the flexor retinaculum and central part of the palmar aponeurosis as expected but the muscle was inserted to the deep fascia covering the hypothenar muscles and the tendon of the flexor carpi ulnaris muscle at its insertion to the pisiform bone, instead of attaching to the dermis of the skin. The muscle was 2.6 cm in length and 4.9 cm in width at its insertion. Along with the above variation the ulnar artery and ulnar nerve was passing below the anomalous muscle on its way to the palm (Figure 5).

☞ Discussion

The anatomical variations and abnormalities of the muscles of the upper limb have become significant because of new imaging techniques, such as computed tomography and magnetic resonance imaging. Also, these variations are important in order to define the anatomical features of each in relation to clinical diagnosis and for surgical procedures [26].

As the Aa crosses over the axillary neuro-vascular structures in the axilla, it may compress the above structures, especially during abduction and lateral rotation of the shoulder joint, particularly the axillary vein [27].

The Aa should be recognized and excised to expose the axillary artery and vein in patients with trauma and to perform axillary lymphadenectomy or axillary bypass surgery [28]. It should also be considered in differential diagnosis of axillary swellings and the construction of latissimus dorsi flaps [3].

Petrasek AJ *et al.* (1997) mentioned, if an axillary arch is encountered during axillary lymphadenectomy, the lymph nodes posterior and lateral to the arch should be excised [29]. The knowledge of the anatomical variations in the axilla along with Aa is therefore, important in surgical interventions. In the arm, we encountered an anomalous Thb. When the Thb originate from the medial aspect of the humerus it may contribute to the pronation of the forearm irrespective of shoulder joint position, as found in the present case [30]. It is not known yet whether the extra head of biceps brachii means a specific functional adaptation of populations characterized for continuous moderate physical activity [12]. Kopuz C *et al.* (1999) attribute the appearance of Thb to evolutionary and/or racial trends [31].

Figure 1 – Anterior view of the right axillary region: A, axillary artery; AV, axillary vein; CB, coraco-brachialis muscle; D, deltoid muscle; ICBN, intercosto-brachial nerve; M, median nerve; SB, short head of biceps brachii muscle; TPM, tendon of pectoralis major. Note the axillary arch took origin from the upper border of the latissimus dorsi muscle and inserted into the deep fascia covering the common origin of coracobrachialis and short head of biceps brachii muscles and was closely related to the intercosto-brachial nerve and other neuro-vascular structures in the axilla

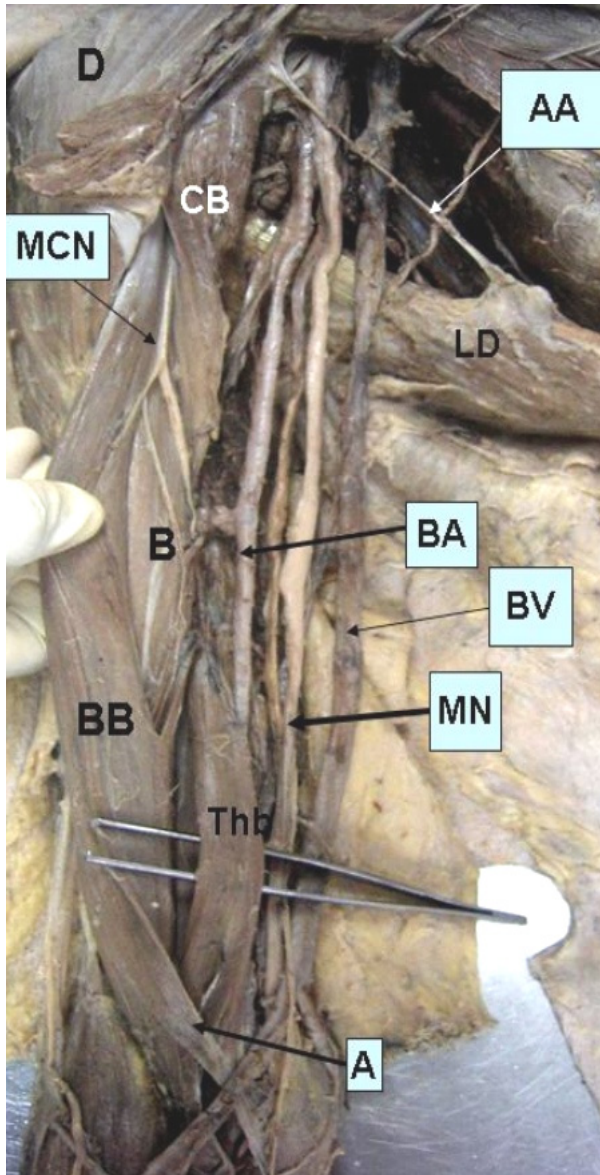
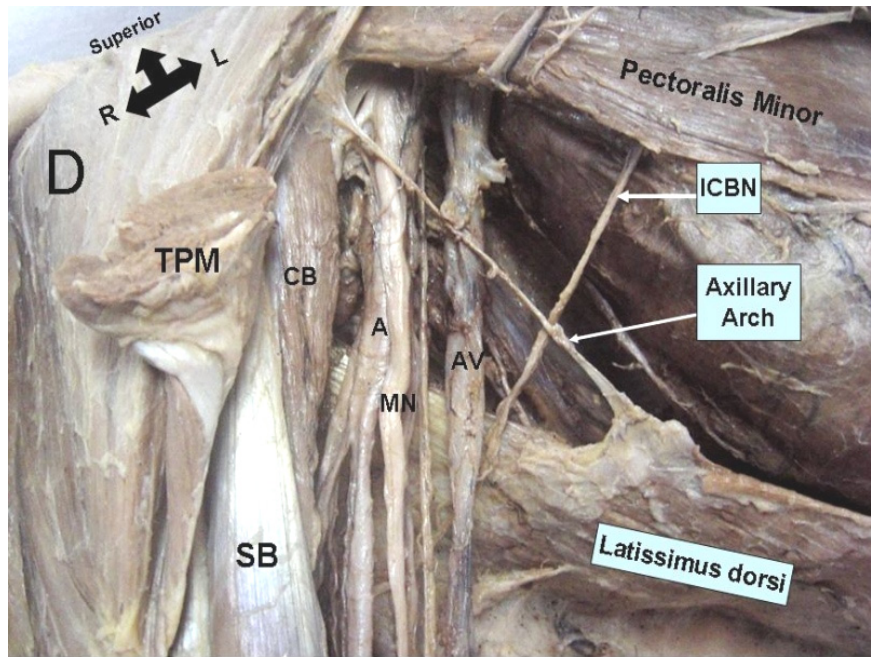


Figure 2 – Anterior medial view of the right axilla and arm region: A, bicipital aponeurosis; AA, axillary arch; B, brachialis muscle; BA, brachial artery; BB, biceps brachii muscle; BV, brachial vein; CB, coracobrachialis muscle; D, deltoid muscle; LD, latissimus dorsi muscle; MCN, musculocutaneous nerve; MN, median nerve; Thb, third head of biceps brachii. Note the Thb took origin from the antero-medial aspect of the shaft of humerus and joined the biceps tendon

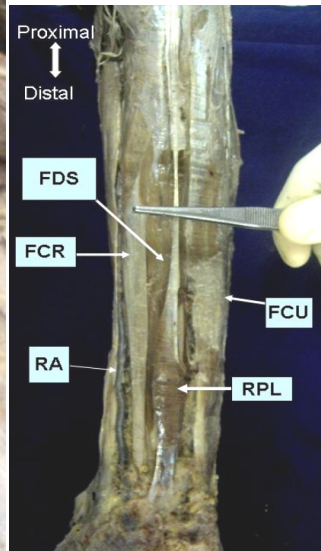


Figure 3 – Anterior view of the right forearm: FCR, flexor carpi radialis; FCU, flexor carpi ulnaris; FDS, flexor digitorum superficialis; RA, radial artery; RPL, reverse palmaris longus muscle

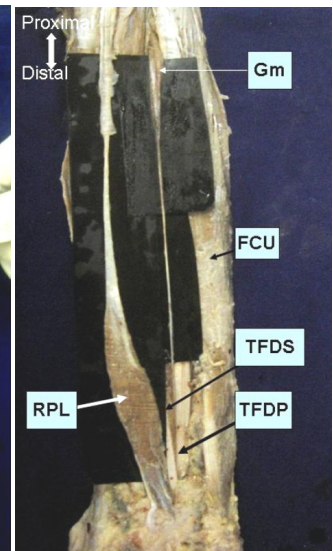


Figure 4 – Anterior view of the right forearm: Gm, Gantzer's muscle; FCU, flexor carpi ulnaris; RPL, reverse palmaris longus muscle; TFDS, tendon of flexor digitorum superficialis; TFDP, tendon of flexor digitorum profundus. Note that the Gantzer's muscle has been pulled above for better view

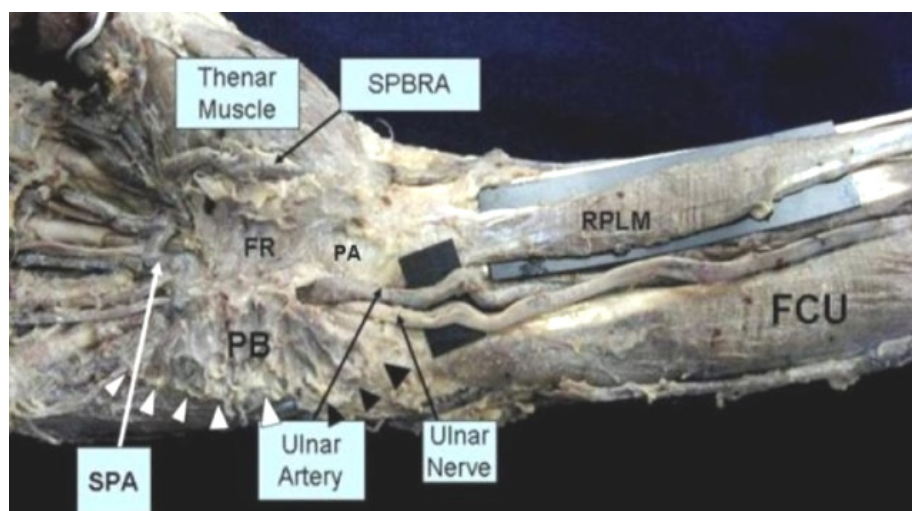


Figure 5 – Ventral aspect of the lower part of the right forearm and hand: FCU, flexor carpi ulnaris muscle tendon; FR, flexor retinaculum; PA, palmar aponeurosis; PB, palmaris brevis muscle; RPLM, reverse palmaris longus muscle; SPA, superficial palmar arch; SPBRA, superficial palmar branch of radial artery. Note the insertion of the palmaris brevis muscle is noted by white triangles to the deep fascia over the hypothenar muscles and black triangles to the tendon of flexor carpi ulnaris muscle

In the forearm we also found an Rpl and a Gm. Palmaris longus has been suggested to be phylogenetically degenerate metacarpophalangeal flexor [32]. McMinn RMH (1997) described that the palmaris longus muscle once existed as a flexor of the proximal phalanges, with its tendons lying in the palm superficial of those of flexor digitorum superficialis and splitting around them to be attached to proximal phalanges [33]. Many authors have reported cases of reversed palmaris longus muscle either as an anatomical variation or as a surgical finding [16, 34–37].

In the present case, the palmaris longus muscle took origin as a long thin tendon and it get replaced by a muscle belly in its lower 2/3, at the region of the wrist, the muscle fibers became membranous and it was found to be continuous with the palmar aponeurosis. The knowledge of the above variation is useful to orthopedic surgeons, as the existence of a mass in the wrist's palmar surface together with symptoms of the median or the ulnar nerve compression, that aggravate during hand movements, should lead to the suspicion of a reversed palmaris longus muscle's existence.

The radiologists should also bear this variation in mind, as its diagnosis is difficult due to the plethora of the forearm muscles [17]. Variations of the palmaris longus muscle is useful not only to the plastic surgeon, as its tendon is often used as a graft, but also to every surgeon who deals with the area, as the tendon of the palmaris longus muscle is a significant anatomical landmark for surgical approaches.

The accessory heads of the flexor muscles have been described in primates and other mammals (pigs, foxes and marmots) as a muscle belly that connects the medial epicondyle origin of the Fds with the more or less differentiated deep flexors [38–40].

The flexor muscles of the forearm that develops from the flexor mass divide into two layers, superficial and deep. The Fds, Flexor digitorum profundus (Fdp) and Fpl originate from the deep layer [41].

The existence of accessory muscles connecting the flexor muscles could be explained by the incomplete cleavage of the deep layer of the flexor mass during development, which represents an 'atavistic' character [21].

The compression of median nerve and anterior interosseous nerve by Gantzer's muscle has been reported in literature [42–44]. The morphology and relations of the 'occasional belly' (i.e., Gantzer's muscle) of the flexor muscles of the forearm, are of great interest from the clinical and surgical point of view.

In palm, we encountered an unusually large Pbm and the ulnar nerve and artery was passing below the anomalous muscle on its way to the palm. Robinson D *et al.* (1989) described a variant of Pbm, which caused ulnar tunnel syndrome at wrist [23]. More ever Pbm flap has been used in recurrent carpal tunnel syndrome secondary to mucopolidosis [45]. The surgeons should be aware of Pbm variation while performing such operation. The Pbm may be doubled and may simulate a soft-tissue tumor of the hand [25]. In the present case, the anomalous Pbm may cause ulnar nerve neuropathy and ulnar artery thrombosis nearing Guyon's canal.

☒ Conclusions

The presence of multiple (five) muscular variation involving all the flexor compartment of the upper limb in the literature is vague. Above all the mentioned variations are encountered in the ipsilateral upper limb. The present variations are not only will be of interest to anatomist, but also for the clinicians and surgeons dealing with the area.

References

- [1] BRASH J. C., *Cunningham's Textbook of Anatomy*, 9th edition, Oxford University Press, London, 1951, 479.
- [2] SALMONS S., Muscle. In: GRAY H., *Grays' Anatomy. The Anatomical Basis of Medicine & Surgery*, 38th edition, Churchill Livingstone, London, 1995, 836–837.
- [3] KASAI T., CHIBA S., *True nature of the muscular arch of the axilla and its nerve supply*, Kaibogaku Zasshi, 1977, 52(5):309–336.
- [4] CLARYS J. P., BARBAIX E., VAN ROMPAEY H., CABOOR D., VAN ROY P., *The muscular arch of the axilla revisited: its possible role in the thoracic outlet and shoulder instability syndromes*, Man Ther, 1996, 1(3):133–139.
- [5] SERPELL J. W., BAUM M., *Significance of 'Langer's axillary arch' in axillary dissection*, Aust N Z J Surg, 1991, 61(4):310–312.

- [6] PAI M. M., RAJANIGANDHA, PRABHU L. V., SHETTY P., NARAYANA K., *Axillary arch (of Langer): incidence, innervation, importance*, Online J Health Allied Scs, 2006, 5(1):1-4.
- [7] GRAY H., *Anatomy of Human Body*, 29th American edition, Lea and Febiger, Philadelphia, 1973, 488-499.
- [8] SONNTAG C. F., *On the anatomy, physiology and pathology of the chimpanzee*, Proc Zool Soc London, 1923, 23:323-429.
- [9] TESTUT L., *Tretado de Anatomica Humana*, Salvat, Barcelona, 1902, 1022.
- [10] BERGMAN R. A., THOMPSON S. A., AFIFI A. K., *Catalogue of human variation*, Urban and Schwarzenberg, Munich, 1984, 27-30.
- [11] ASVAT R., CANDLER P., SARMIENTO E. E., *High incidence of third head of biceps brachii in South African populations*, J Anat, 1993, 182(Pt 1):101-104.
- [12] RINCÓN F., RODRÍQUEZ Z. I., SÁNCHEZ A., LÉON A., GONZÁLEZ L. F., *The anatomic characteristics of the third head of biceps brachii muscle in Colombian population*, Rev Chil Anat, 2002, 20(2):197-200.
- [13] JOHNSON D., ELLIS H., Forearm. In: STANDRING S. (ed), *Gray's Anatomy. The Anatomical Basis of Clinical Practice*, 39th edition, Elsevier-Churchill Livingstone, Edinburgh, 2005, 876-877.
- [14] SALMONS S., Muscle. In: GRAY H., *Grays' Anatomy. The Anatomical Basis of Medicine & Surgery*, 38th edition, Churchill Livingstone, London, 1995, 846.
- [15] STILL J. M. JR., KLEINERT H. E., *Anomalous muscles of nerve entrapment in the wrist and hand*, Plast Reconstruct Surg, 1973, 52(4):394-400.
- [16] YILDIZ M., SENER M., AYNACI O., *Three-headed reversed palmaris longus muscle: a case report and review of the literature*, Surg Radiol Anat, 2000, 22(3-4):217-219.
- [17] NATSIS K., LEVVA S., TOTLIS T., ANASTASOPOULOS N., PARASKEVAS G., *Three-headed reversed palmaris longus muscle and its clinical significance*, Ann Anat, 2007, 189(1):97-101.
- [18] WOOD J., *Variations in human myology*, Proc Royal Soc London, 1868, 16:483-525.
- [19] BERGMAN R. A., AFIFI A. K., MIYAUCHI R., *Illustrated Encyclopedia of Human Anatomic Variation: Opus I: Muscular System: Alphabetical listing of muscles: Flexor digitorum superficialis*, <http://www.anatomyatlases.org/Anato-micvariants/MuscularSystem/Text/F17Flexor.shtml>. (accessed in June, 2007).
- [20] MARTIN B. F., *The oblique cord of the forearm*, J Anat, 1958, 92(4):609-615.
- [21] JONES M., ABRAHAMS P. H., SAÑUDO J. R., CAMPILLO M., *Incidence and morphology of accessory heads of flexor pollicis longus and flexor digitorum profundus (Gantzer's muscles)*, J Anat, 1997, 191(Pt 3):451-455.
- [22] JOHNSON D., ELLIS H., Wrist and hand. In: STANDRING S. (ed), *Gray's Anatomy. The Anatomical Basis of Clinical Practice*, 39th edition, Elsevier-Churchill Livingstone, Edinburgh, 2005, 919.
- [23] ROBINSON D., AGHASI M. K., HALPERIN N., *Ulnar tunnel syndrome caused by an accessory palmaris muscle*, Orthop Rev, 1989, 18(3):345-347.
- [24] TONKIN M. A., LISTER G. D., *The palmaris brevis profundus. An anomalous muscle associated with ulnar nerve compression at the wrist*, J Hand Surg [Am], 1985, 10(6 Pt 1):862-864.
- [25] LIPSCOMB P. R., *Duplication of hypothenar muscles simulating soft-tissue tumor of the hand: report of a case*, J Bone Joint Surg [Am], 1960, 42A:1058-1061.
- [26] KOPUZ C., FIDAN B., ISLAM A., *An unusually distal and complete additional flexor profundus muscle to the index finger*, J Anat, 1997, 191(Pt 3):465-467.
- [27] SACHATELLO C. R., *The axillopectoral muscle (Langer's axillary arch): a cause of axillary vein obstruction*, Surgery, 1977, 81(5):610-612.
- [28] MIGUEL M., LLUSÁ M., ORTIZ J. C., PORTA N., LORENTE M., GÖTZENS V., *The axillopectoral muscle (of Langer): report of three cases*, Surg Radiol Anat, 2001, 23(5):341-343.
- [29] PETRASEK A. J., SEMPLE J. L., MCCREARY D. R., *The surgical and oncologic significance of the axillary arch during axillary lymphadenectomy*, Can J Surg, 1997, 40(1):44-47.
- [30] SWIETER M. G., CARMICHAEL S. W., *Bilateral three headed biceps brachii muscle*, Anat Anz, 1980, 148(4):346-349.
- [31] KOPUZ C., SANCAK B., OZBENLI S., *On the incidence of third head of biceps brachii in Turkish neonates and adults*, Kaibogaku Zasshi, 1999, 74(3):301-305.
- [32] WILLIAMS P. L., BANNISTER L. H., DYSON M., BERRY M. M., COLLINS P., DUSSEK J. E., FERGUSON M. W. J., *The muscular system*. In: GRAY H., *Gray's Anatomy. The Anatomical Basis of Medicine & Surgery*, 38th edition, Churchill Livingstone, London, 1995, 846.
- [33] McMINN R. M. H. (ed), *Last's Anatomy. Regional and Applied*, 9th edition, Churchill Livingstone, London, 1994, 89.
- [34] SAADEH F. A., BERGMAN R. A., *An unusual accessory flexor (opponens) digiti minimi muscle*, Anat Anzeiger, 1988, 165(4):327-329.
- [35] GIUNTA R., BRUNNER U., WILHELM K., *Bilateral reversed palmaris longus muscle – a rare cause of peripheral median nerve compression syndrome. Case report*, Unfallchirurg, 1993, 96(10):538-540.
- [36] DEPUYDT K. H., SCHUURMAN A. H., KON M., *Reversed palmaris longus muscle causing effort-related median nerve compression*, J Hand Surg [Br], 1998, 23(1):117-119.
- [37] BENCTEUX P., SIMONET J., EL AYOUBI L., RENARD M., ATTIGNON I., DACHER J. N., THIEBOT J., *Symptomatic palmaris longus muscle variation with MRI and surgical correlation: report of a single case*, Surg Radiol Anat, 2001, 23(4):273-275.
- [38] TESTUT L., *Les anomalies musculaires chez l'homme*, Masson, Paris, 1884.
- [39] PARSONS F. G., *The muscles of mammals, with special relation to human mycology: a course of lectures delivered at the Royal College of Surgeons of England*, J Anat Physiol, 1898, 32(Pt 4):721-752.
- [40] LE DOUBLE A. F., *Traité des variations du système musculaire de l'homme et de leur signification au point de vue de l'anthropologie zoologique*, vol. 2, Schleicher Frères, Paris, 1897, 99-107.
- [41] LEWIS W. H., *The development of the muscular system*. In: KEIBEL F., MALL F. P. (ed.), *Manual of Embryology*, vol. 2, J. B. Lippincott Company, Philadelphia, 1910, 455-522.
- [42] AL-QATTAN M. M., *Gantzer's muscle. An anatomical study of the accessory head of the flexor pollicis longus muscle*, J Hand Surg [Br], 1996, 21(2):269-270.
- [43] TABIB W., ABOUFARAH F., ASSELINEAU A., *Compression of the anterior interosseous nerve by Gantzer's muscle*, Chir Main, 2001, 20(3):241-246.
- [44] DEGREEF I., DE SMET L., *Anterior interosseous nerve paralysis due to Gantzer's muscle*, Acta Orthop Belg, 2004, 70(5):482-484.
- [45] ROSE E. H., *The use of the palmaris brevis flap in recurrent carpal tunnel syndrome*, Hand Clin, 1996, 12(2):389-395.

Corresponding author

Soubhagya Ranjan Nayak, Lecturer, MSc, Department of Anatomy, Centre for Basic Sciences, Kasturba Medical College, Bejai, Mangalore-575004, Karnataka, India; Phone +91 824 2211746, Fax +91 824 2421283, Email: ranjanbhatana@gmail.com

Received: August 24th, 2007

Accepted: September 5th, 2007