

ORIGINAL PAPER

Immunohistological correlation in different stages of squamous cell carcinoma

MARIA BĂLĂȘOIU¹⁾, ADRIANA TURCULEANU¹⁾, CL. MĂRGĂRITESCU²⁾,
CARMEN SILVIA AVRĂMESCU¹⁾, A. T. BĂLĂȘOIU³⁾

¹⁾Department of Microbiology–Immunology

²⁾Department of Pathology

³⁾student

University of Medicine and Pharmacy of Craiova

Abstract

Squamous cell carcinoma is one of the most frequent cutaneous carcinomas, this neoplastic process inducing cellular and umoral immune response modifications. Our study refers at 60 patients, squamous cell carcinoma diagnosed, at whom we determined IL-2, IL-6 and TNF- α , using ELISA technique. The discovered results were different, depending on the differentiation form. The cellular immune response presented important modifications only in poor differentiated form of the disease.

Keywords: squamous cell carcinoma, cytokines, immunohistological correlation.

Introduction

Squamous cell carcinoma is one of the most frequent cutaneous carcinomas. It has a quick evolution, increased local multiplication and increased metastasis potential. Usually appears at persons aged between 55 and 70, especially males [1]. The persons frequently affected are the ones exposed to solar ultraviolet radiation, blonde and blue-eyed persons and also the ones not with hairy skin.

Ultraviolet radiation exposure determines DNA mutations with cancer potential, gene p53 for example [2]. Ultraviolet radiation plays an important role in tumoral progress process, affecting both the function of the cells, which present antigen and T-lymphocytes activation.

More factors implicated in spinocellular carcinoma are represented by the former plagues: xeroderma pigmentosum, cutaneous scars, X-rays exposure or chemical substances exposure [1, 2].

Clinically, spinocellular epidermal carcinoma can appear anywhere on skin, especially on face (lower lip, ears, mouth), but it can also appear on the inferior members and external genital organs. It is believed that over 80% of the spinocellular carcinomas are situated cephalically [1, 2].

Plagues have one of these aspects:

- ulcerovegetative form;
- gigantic cauliflower form;
- nodular vegetative form;
- keratinic form;
- ulcerous form.

Histopathologically, the tumor is made out of islands and strings of carcinoma cells. Malign cells are polygonal shaped and present a big amount of cytoplasm and different sized and colored nuclei.

Atypical mitosis is frequent. In differentiated forms of the tumors, in the center of tumor islands, malign cells reach maturity and keratinization.

Broders histopathological classification correlates tumoral differentiation grade with invasion depth in four grades.

Objectives

Spinocellular epidermal carcinoma is one of the most frequent cutaneous carcinomas. It evolves quickly, with increased local multiplication and high metastasis potential.

Starting from the important role, played by the immune system in antitumoral defense, especially cellular immunity (N-cells, activated macrophages, cytokines with immunomodulator role and T-lymphocytes), we have settled the objective to determine levels of cytokines at patients suffering from spinocellular carcinoma.

Material and methods

The group we have studied numbered 60 patients, clinically and pathologically diagnosed with spinocellular epidermal carcinoma. The patients were aged between 49 and 65.

They were traced out in the Oncology Clinic and Pathology Laboratory of Craiova Emergency County Hospital.

In most cases, the tumor appeared on the lower lip and oral mucosa.

Twenty-nine of all patients presented well-differentiated form of spinocellular carcinoma, 10 of them presenting muscular invasion, 15 moderately differentiated, and 16 poor differentiated (Figure 1).

Before administrating any therapy, at this group of 60 patients we have determined the following cytokines: IL-2, IL-6 and TNF- α . We used the sandwich quantitative indirect ELISA technique.

The pieces were prepared using standard paraffin including method and stained using Hematoxylin–Eosin usual staining.

The normal values for each interleukin were the following: IL-6 <10 pg/mL, TNF- α <13 pg/mL, IL-2 5–15 pg/mL.

☞ Results

IL-2 values

IL-2 values at our group were different, depending on the tumoral differentiation grade, in comparison to the witness group (average 18.27 pg/mL) (Figure 2):

- in well differentiated spinocellular carcinoma the IL-2 values were normal (average 32.77 pg/mL);
- in moderately differentiated spinocellular carcinoma the IL-2 values were decreased, but in normal limits (average 18.97 pg/ml);
- in poor differentiated spinocellular carcinoma the IL-2 values were low (average 1.17 pg/ml).

TNF- α values

TNF- α value at our patients were different, depending on the tumoral differentiation grade, in comparison to the witness group (average 8.43 pg/mL) (Figure 3):

- in well-differentiated spinocellular carcinoma the TNF- α values were close to normal (average 8.48 pg/mL);
- in moderately differentiated spinocellular carcinoma the TNF- α values were increased (average 18.75 pg/mL);
- in poor differentiated spinocellular carcinoma the TNF- α values were also increased (30.04 pg/mL).

IL-6 values

IL-6 values at our patients were different, depending on the tumoral differentiation grade, in comparison to the witness group (average 5.97 pg/mL) (Figure 4):

- in well differentiated spinocellular carcinoma the IL-6 values were close to normal (average 8.53 pg/mL);
- in both moderately and poor differentiated spinocellular carcinoma the IL-6 values were increased (average 11.16 pg/mL and 11.12 pg/mL).

☞ Discussions

IL-2

IL-2 is a glycoprotein with a molecular weight of 15–17 kD, made out of 133 amino-acids and it is produced by Th1-lymphocytes and also by cytotoxic T-lymphocytes after antigenic stimulation, with an effect on proliferation and activation of some other T-lymphocytes and NK-cells, these having the capacity of lyses several types of cells, including the tumoral ones [3–7].

IL-2 antitumoral effect was supposed to follow the generation of macrophage-dependent suppression, neoprotein increasing, the level of IL-2 soluble receptors and cortisol production [4, 7].

IL-2 values correlate more with the tumor's differentiation grade and less with the invasion grade. The least values were determined in poor differentiated squamous cell carcinoma, while the values determined in well-differentiated carcinoma were normal.

This is why in spinocellular carcinoma it is recommended local treatment in either perilymphatic infections or intratumoral, at patients presenting any level of differentiation [10–12].

TNF- α

TNF- α is a 17-kD protein secreted by cells such as monocytes/macrophages, T-, B- and NK-lymphocytes, neutrophils, astrocytes, endothelial cells, and smooth muscle cells. The protein proved to be an important antitumoral agent with cytotoxic, cytostatic and immuno-modulating effects. TNF- α is an acute phase reactant by participating into the vascular phases of the inflammation [3, 4].

TNF- α produces tumoral necrosis; its action is not due to direct cytotoxic effect on the malign cell but to both the hemorrhage hypoxia at the level of the tumor. It happened by destroying the capillary endothelium, releasing the local coagulation, fibrin forming and sanguine vessels stopping up [8, 9].

TNF- α values do not correlate with the invasion grade of the tumor, in well-differentiated carcinoma with muscular invasion the values were normal. Most increased values were determined at patients with poor differentiated squamous cell carcinoma.

Increased TNF- α in poor differentiated spinocellular carcinoma do not bring any positive effects of this cytokine, it rather means an increased production of TNF- α in the peritumoral zone.

IL-6

IL-6 is a protein having a molecular weight between 21–45 kD, made out of 184 amino-acids synthesized inside the body by different cells: fibroblasts, monocytes, macrophages, T- and B-lymphocytes, osteoblasts, hepatocytes, mesangial cells, tumoral clones – sarcoma, glioblastoma, melanoma, renal carcinoma, and urinary gallbladder [3, 4].

Together with IL-2 and IFN- γ it activates T-lymphocytes and changes the MK into LAK-lymphocytes. It also has the capacity to induce acute phase reactants of the inflammation, being considered an acute phase protein just like TNF- α [3, 4].

Increased IL-6 in both moderately and poor differentiated spinocellular carcinoma can be explained by the fact that malign tumoral cells can synthesize cytokines such as IL-4 and even IL-6 [5, 6].

IL-6 values correlate only with the differentiation grade of the tumor, being moderately increased in poor and moderate differentiated carcinoma and normal in well-differentiated carcinoma and invasive well-differentiated carcinoma.

Figure 1 – Number and percent of different histological degree of squamous cell carcinoma

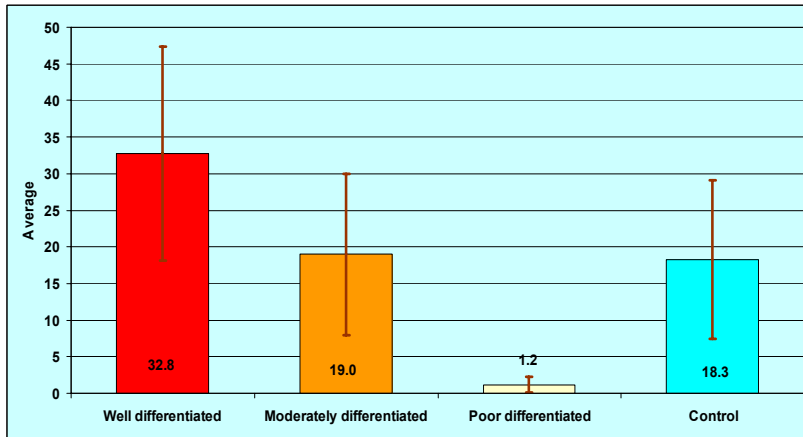
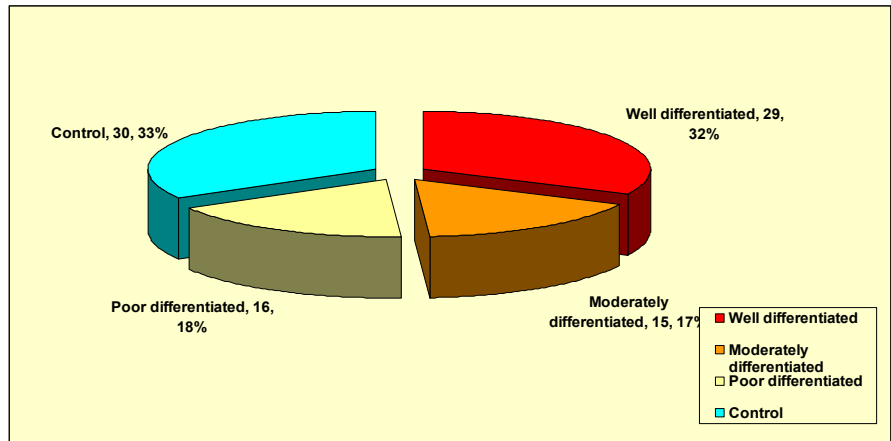


Figure 2 – Average and standard deviation of IL-2 values in different histological degree of squamous cell carcinoma

Figure 3 – Average and standard deviation of TNF-α values in different histological degree of squamous cell carcinoma

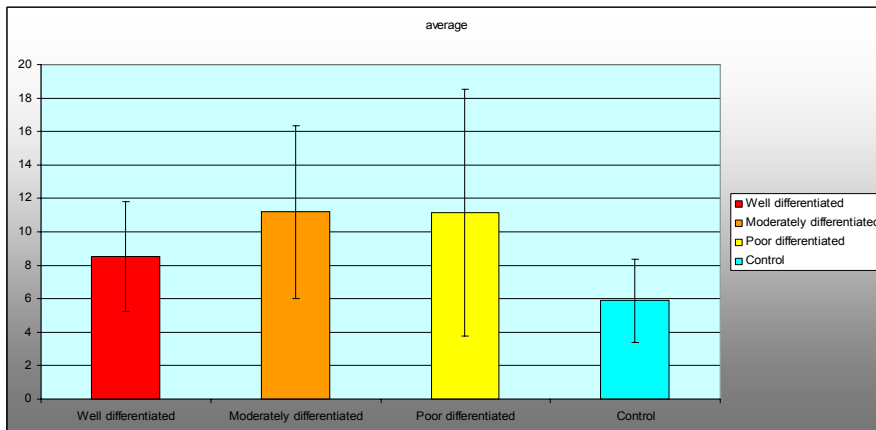
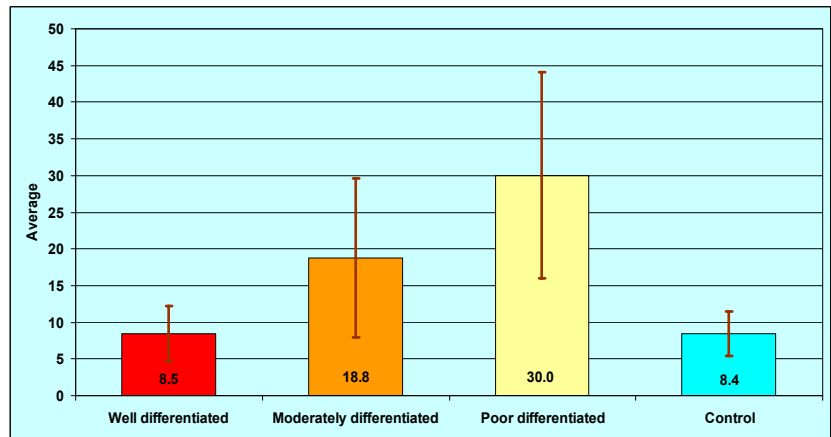


Figure 4 – Average and standard deviation of IL-6 values in all stages of differentiation

☐ Conclusions

In spinocellular carcinoma, we could notice an important immune deficit at only a few patients – the ones presenting poor differentiated spinocellular carcinoma. These patients have presented cytokine modifications. Patients presenting well-differentiated carcinoma with muscular invasion did not present increased values of any of the interleukins.

IL-2 is the most important interleukin with immunomodulator role, which makes active cytotoxic elements against tumoral cells. In our study, IL-2 has presented normal values at well and moderately differentiated spinocellular carcinoma patients and decreased values at poor differentiated spinocellular carcinoma patients.

The IL-6 values, which we discovered, were in normal limits at well and moderately differentiated spinocellular carcinoma patients. Patients with poor differentiated spinocellular carcinoma presented increased values of IL-6, because the tumoral cells can produce IL-6, fact that explains its increased plasmatic level.

TNF- α value were normal at well and moderately differentiated spinocellular carcinoma patients and increased at poor differentiated spinocellular carcinoma patients. In this stage, the peritumoral inflammation grade was increased, fact that explains the plasmatic level of TNF- α at poor differentiated spinocellular carcinoma patients.

References

- [1] CHIRICUȚĂ I., *Cancerologie generală*, vol. II, Ed. Medicală, București, 1988.
- [2] FRIEDMAN R. J., RIGEL D., KOPF A. W., HARRIS M. N., BAKER D. (eds), *Cancer of the skin*, WB Saunders, Philadelphia, 2004.
- [3] HEBERMAN R. B., Principles of Tumor Immunology. In: HOLLEB A. I., FINK D. J., MURPHY G. P. (eds), *American Cancer Society Textbook of Clinical Oncology*, A.C.S. Inc., Atlanta, 1991.
- [4] MALIK S., WAXMAN J., *Cytokines and cancer*, BMJ, 1992, 305(6848):265–267.
- [5] PĂUNESCU V., TATU C., *Imunologie. Concepte fundamentale și aplicative*, Ed. Helicon, Timișoara, 1996.
- [6] PEREȚIANU D., SARAGEA M., *Imunologia în teoria și practica medicinei*, vol. II, Ed. All, București, 1998.
- [7] TURSZ T., *L'interleukine 2: place actuelle et avenir en cancérologie*, Presse Médicale, 1991, 20(6):241–243.
- [8] ECONOMU J. S., Tumor necrosis factor. In: HOLLAND J. F., FREI E. III, BAST R. C. JR., KUFEL D. W., MORTON D. L., WEICHELBAUM R. R. (eds), *Cancer Medicine*, 3rd edition, Lea & Febiger, Philadelphia, 1993.
- [9] SIDHU R. S., BOLLON A. P., *Tumor necrosis factor activities and cancer therapy – a perspective*, Pharmacol Ther, 1993, 57(1):79–128.
- [10] CRUSE J. M., LEWIS R. E. JR., *Cellular and cytokine immunotherapy of cancer*, Prog Exp Tumor Res, 1988, 32:1–16.
- [11] FAHEY J. L., SARNA G., GALE R. P., SEEGER R., *Immune interventions in disease*, Ann Intern Med, 1987, 106(2):257–274.
- [12] KRADIN R., DUBINETT S., MULLIN J., BOYLE L., STRAUSS H. W., BOURGOIN P. M., PREFFER F. I., KURNICK J., *Treatment of patients with advanced cancer using tumor-infiltrating lymphocytes and interleukin 2*, Transplant Proc, 1988, 20(2):336–338.

Corresponding author

Maria Bălăşoiu, Associate Professor, MD, PhD, Department of Microbiology–Immunology, University of Medicine and Pharmacy of Craiova, 66 1 May Avenue, 200 638 Craiova, Romania; Phone +40251–524 442, E-mail: turculeanu_balasoiu@yahoo.com

Received: October 25th, 2007

Accepted: November 21st, 2007