

## ORIGINAL PAPER

# The study of E-cadherine and CD44 immunoeexpression in oral squamous cell carcinoma

CRISTIANA SIMIONESCU<sup>1)</sup>, CL. MĂRGĂRITESCU<sup>1)</sup>, M. SURPĂȚEANU<sup>2)</sup>,  
L. MOGOANTĂ<sup>3)</sup>, ROXANA ZĂVOI<sup>4)</sup>, RALUCA CIUREA<sup>1)</sup>,  
PETRA ȘURLIN<sup>5)</sup>, A. STEPAN<sup>1)</sup>

<sup>1)</sup>Department of Pathology

<sup>2)</sup>Department of Oral and Maxillofacial Surgery

<sup>3)</sup>Department of Histology

<sup>4)</sup>Department of Forensic Medicine

<sup>5)</sup>Department of Parodontology

University of Medicine and Pharmacy of Craiova

### Abstract

In spite of the progresses achieved in surgical treatment, radiotherapy and chemotherapy, the survival rate in oral squamous cell carcinoma (OSCC) remain unchanged among past three decades, which made this neoplasia a major problem of health in the entire world. There were investigated 42 cases of OSCC with different sites and various grades of differentiation, by histological and immunohistochemical techniques (by LSAB/HRP method), using E-cadherine and CD44. Considering the differentiation grade, the cases were histopathologically classified as 9 cases of well-differentiated squamous carcinoma, 14 cases of moderately differentiated squamous carcinoma, and 19 cases of poorly differentiated squamous carcinoma. The E-cadherine immunoeexpression study indicated an immunostaining degree 3 in well-differentiated squamous carcinoma, 2 in moderately differentiated squamous carcinoma, and 1 in poorly differentiated squamous carcinoma. The results of CD44 immunostaining indicated in most of the cases an immunostaining degree 2, especially in moderately differentiated OSCC. The immunostaining degree 3 corresponded to nine cases of well-differentiated OSCC, and other two cases of moderately differentiated OSCC. Immunostaining degree 1 corresponded to poorly differentiated OSCC. The results indicate the possibility of using the two-immunohistochemical markers as prognostic factors in OSCC.

**Keywords:** oral squamous cell carcinoma, E-cadherine, CD44.

### Introduction

The oral cancers represent a major health problem; the five years survival rate is unchanged among the past three decades, being about 50–55%, in spite of the progresses achieved in surgical treatment, radio- and chemotherapy [1–3]. Oral carcinogenesis is a unique model for the study of the multistadial nature of oral squamous cell carcinoma (OSCC), premalignant lesions and malignant invasive lesions, coexisting at the same patient. This reflects the progression of the phenotypic and genotypic alterations associated to the disease [4, 5]. Most of the molecular mechanisms of invasion and tissular destruction are unknown, as well as in metastatic spread in OSCC. From the phenotypic alterations, we mention the reduction or loss of cellular adhesion, which is an essential step for the progression of the cancer to metastases.

\*Report of GR15/9.05.2007, National University Research Council (NURC, CNCSIS) code 954.

### Material and methods

We studied a number of 42 cases of OSCC with different sites (tongue, lips, palate, and gums) and

different grades of differentiation and we investigated the immunoeexpression of adhesion molecules. We performed the immunohistochemical study by the LSAB/HRP method, using E-cadherine (Clone DF1485, Isotype IgG1, kappa) and CD44 (Clone DF1485, Isotype IgG1, kappa).

First of all, we followed the evidention of the chromogene at the level of the antigen targets and for the quantitative appreciation of the antibodies immunohistochemical expression, we used the following score:

- 0 degree: under 10% positive cells;
- 1 degree: between 10–25% positive cells;
- 2 degrees: between 25–50% positive cells;
- 3 degrees: between 50–75% positive cells;
- 4 degrees: over 75% positive cells.

### Results

The histopathological study of the 42 cases of OSCC classified them as nine cases of well-differentiated squamous carcinoma, 14 cases of moderately differentiated squamous carcinoma, and 19 cases of poorly differentiated squamous carcinoma.

The E-cadherine immunoeexpression study for investigated, OSCC indicated positivity in 25 cases (59.5%).

The negative cases corresponded to poorly differentiated carcinoma (14 cases) and moderately differentiated OSCC (two cases).

According to the proportion of E-cadherine positive cells, the OSCC and using the grading system presented before we obtained the following results (Table 1):

**Table 1 – Immunostaining for E-cadherine according to immunoexpression degree**

Immunostaining distribution	1 <sup>st</sup> degree	2 <sup>nd</sup> degree	3 <sup>rd</sup> degree
No. of cases	7	9	9
%	28	36	36

Analyzing the immunostaining grade, according to the differentiation grade of the tumors, we observed that all well differentiated OSCC corresponded to 3<sup>rd</sup> degree. In these cases, we noticed the staining of the entire cellular membrane at a proportion between 25–50% from the tumoral cells (Figure 1).

The moderately differentiated OSCC presented 2<sup>nd</sup> degree of immunostaining, the proportion of positive cells being noticed between 10–25%. The immunostaining was present for the entire cellular membrane or only for a part of it with a lower intensity (Figure 2).

Poorly differentiated forms corresponded to the 1<sup>st</sup> degree of immunostaining. In these cases, the marking was present only for a part of the cellular membrane with low intensity (Figure 3).

The study of CD44 immunoexpression indicated positivism in 29 cases (69%).

The cases with negative immunostaining corresponded to some poorly differentiated OSCC (five cases) and moderately differentiated OSCC (one case). We have not noticed any case of 4<sup>th</sup> degree immunostaining. According to the proportion of CD44 positive cells, using the grading system presented before we have this results (Table 2).

**Table 2 – Immunostaining for CD44 according to immunoexpression degree**

Immunostaining distribution	1 <sup>st</sup> degree	2 <sup>nd</sup> degree	3 <sup>rd</sup> degree
No. of cases	8	12	9
%	25.8	38.7	35.5

The majority of cases corresponded to the 2<sup>nd</sup> degree of immunostaining, which includes moderately differentiated forms of OSCC (Figure 4).

The 3<sup>rd</sup> degree of immunostaining corresponded in nine cases of well-differentiated OSCC and the 1<sup>st</sup> degree of immunostaining corresponded to the poorly differentiated OSCC (Figures 5 and 6).

The OSCC included in the 3<sup>rd</sup> degree presented positivism in the majority of tumoral islands with complete staining of the cytoplasmic membrane.

The OSCC corresponding to the 2<sup>nd</sup> degree of immunostaining presented a continuous or a discontinuous positivity of the cytoplasmic membrane with lower intensity.

For the 1<sup>st</sup> degree neoplasm, the membrane positivism was discontinuous with low intensity.

## Discussions

OSCC is a common neoplasm of oral cavity, with an uncertain prognostic. The reduction or loss of cells adhesion represents an important step in the progression of the neoplasm to metastases. In the study we have performed, we followed the immunoexpression of the adhesion molecules E-cadherin and CD44, for OSCC with various grades of differentiation.

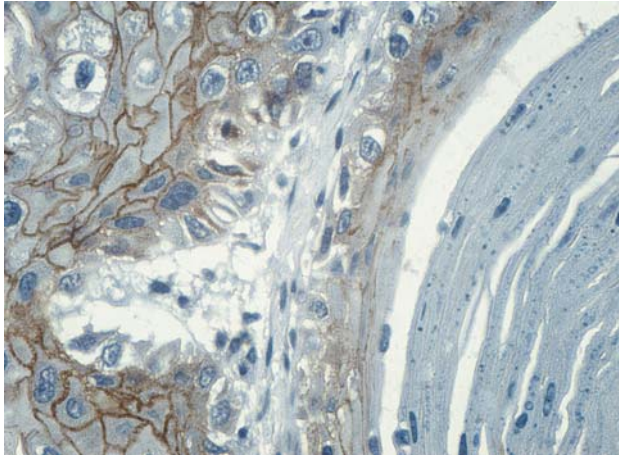
For the 24 cases we studied, we observed the diminution of immunostaining degree for E-cadherin in comparison with the diminution of the differentiation grade of OSCC. All cases of well-differentiated carcinomas presented the highest immunostaining degree, the moderately ones presented a lower immunostaining degree and the poorly differentiated were negative or presented lowest immunostaining degree. We can assert that the absence of immunostaining or the 1<sup>st</sup> degree immunostaining, is associated with the undifferentiated forms of OSCC, so with an unpredictable prognostic.

Massareli E *et al.* [6], after immunohistochemically investigation of 46 cases of preneoplastic lesions in oral mucosa and larynx, confined that 50% of lesions marked with CD44 were negative. The authors confined that the lost of expression for E-cadherine is consecutive to the progression of this kind of lesions. That way, 20% of hyperkeratotic lesions, 46% of lesions with moderate dysplasia and 58% of severe dysplasia presented the lost of E-cadherine expression. The loss of expression was more frequent in larynx lesions in comparison with those from oral mucosa (45%). The authors concluded that the loss of E-cadherine expression does not represent an independent prognostic factor of carcinogenesis, but they had noticed a significant decrease in progression time of the neoplastic disease in association with p27 protein loss expression.

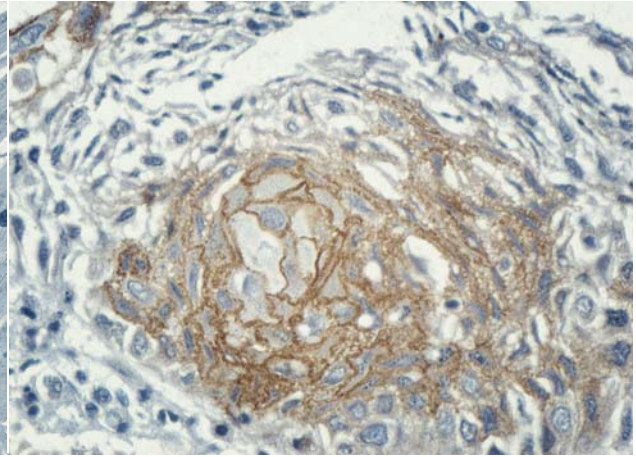
Santos Garcia A *et al.* [7] obtained similar results, so the authors concluded a loss of E-cadherin expression in 20% of low and moderately dysplasias in oral mucosa, in 73% of *in situ* carcinoma and microcarcinoma with the same location, in 90% of OSCC and in 100% of their lymph metastases.

Lin YC *et al.* [8] investigated 62 cases of esophageal squamous carcinoma and concluded a loss of E-cadherine expression in 88.7% of all cases. In addition, the authors also concluded a significant positive correlation between the intensity of E-cadherin expression and  $\alpha$ -catenine ( $r = 0.279$ ,  $p < 0.05$ ). They also concluded a significant correlation between E-cadherine expression and histological differentiation grade, poorly differentiated lesions being associated with the loss of immunoexpression for this marker, and the global survival rate for these patients correlated inversely proportional to E-cadherine expression.

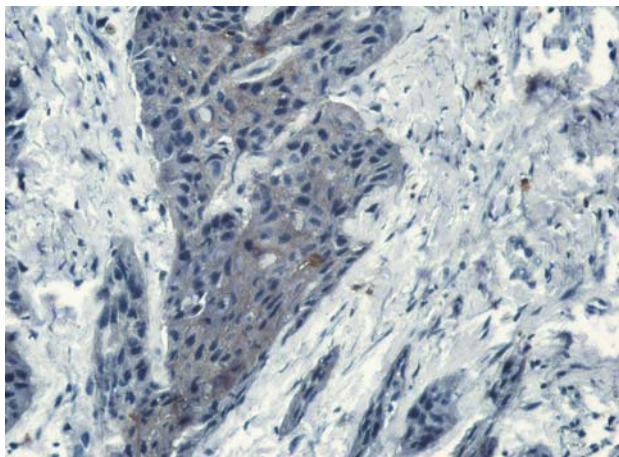
E-cadherine has an essential role in cellular adhesion, the alteration of cadherines expression being associated to the loss of cell differentiation, to acquisition of invasive phenotype and to the unfavorable prognostic in many types of carcinomas.



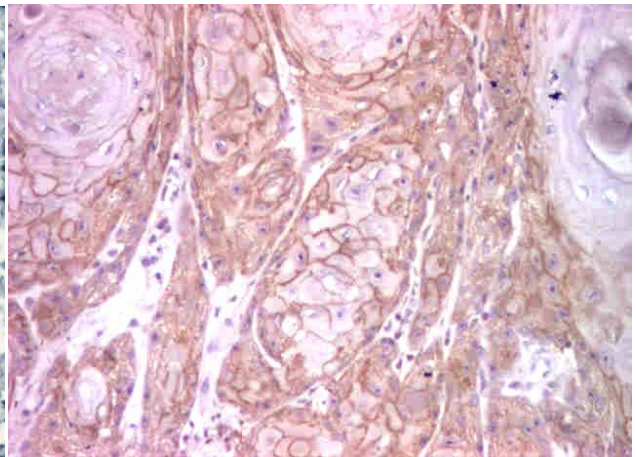
**Figure 1 – Well-differentiated squamous carcinoma, E-cadherine degree 3, ob. 40×**



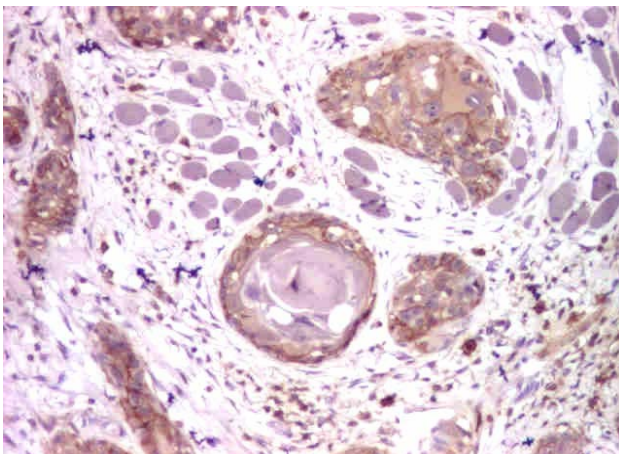
**Figure 2 – Moderately differentiated squamous carcinoma, E-cadherine degree 2, ob. 40×**



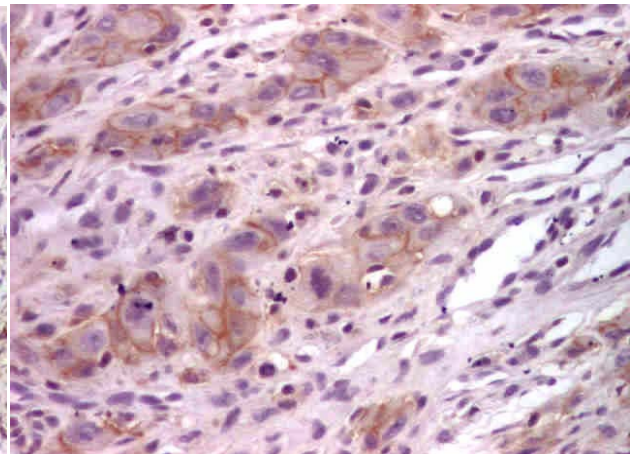
**Figure 3 – Poorly differentiated squamous carcinoma, E-cadherine degree 1, ob. 20×**



**Figure 4 – Well-differentiated squamous carcinoma, CD44 degree 3, ob. 10×**



**Figure 5 – Moderately differentiated squamous carcinoma, CD44 degree 2, ob. 10×**



**Figure 6 – Poorly differentiated squamous carcinoma, CD44 degree 1, ob. 20×**

It is considered that the loss of cadherines expression in OSCC has an essential role in the disease development and metastases [9, 10]. The loss of cadherines expression was observed in many types of carcinomas and usually it is associated to late stages of the disease and to the progression of malignant epithelial neoplasias. We can say that the

immunoexpression of cervical lymph nodes metastases and especially micrometastase, was rarely reported, the decrease of its expression being correlated to an unfavorable prognostic of OSCC patients. The detecting of E-cadherine expression can be useful in confirming the lymph nodes metastases and micrometastases [11].

Many studies suggest a correlation between decrease or loss of E-cadherine and beta-catenine expression and the low grade of tumoral differentiation, being possible to use them as markers for lymph nodes metastases in OSCC [12, 13].

The study of CD44 immunoexpression indicated positivity in 69% of all investigated cases. The immunostaining degree, as in E-cadherine case, was proportional to the differentiation grade of the investigated squamous carcinomas, the highest degree corresponding to well-differentiated carcinomas, but there were no more than 75% positive cells.

Kanke M *et al.* [14] investigated by immunohistochemistry the expression of CD44v6 in 89 cases of head and neck squamous carcinomas (35 cases resulting from tongue and oral floor). The expression ratio of CD44v6 was 96%, but did not correlate to tumor stage. More of that the authors confine a significant correlation between the decrease of CD44v6 expression and histological differentiation grade of those tumors, but also a significant increase of lymph node metastases at the same time with the decrease of this immunomarker expression.

Gonzales-Moles MA *et al.* [15] investigated by immunohistochemistry, the CD44 expression in 32 cases of lingual and adjacent mucosa squamous carcinoma. That way 9.4% of cases presented the loss of CD44 expression in normal or dysplastic mucosa adjacent of squamous carcinoma; this loss of expression being more frequent in the vicinity tumors with a low percent of CD44 positive cancerous cells. The authors concluded that the loss of CD44 expression might be considered an early process in oral carcinogenesis.

Bánkfalvi A *et al.* [16] immunohistochemically investigated a number of 93 cases of OSCC, 30 associated metastases and 12 recidives for CD44s, -v3, -v4, -v5, -v6, -v7, -v9, E-cadherine and beta-catenine. In most of the cases, associated dysplastic lesions showed an increased immunoreactivity for all adhesion molecules except few cases in which it was confined a limited loss of CD44s, E-cadherine and beta-catenine expression. In carcinomas, at the level of invasion border, it was noticed a significant increase of CD44s, -v3, -v4, -v9 expression and loss of E-cadherine and beta-catenine expression. In metastases and tumoral recidives, it was confined a loss of expression for CD44s, -v4, -v7 and E-cadherine, a significant increase of v9 expression and an unchanged expression for CD44v5 and v6. This way, the decrease of CD44v3 and E-cadherine expression and the changes of CD44v9 phenotype in the primitive tumor were significant correlated to an unfavorable prognostic and the decrease of beta-catenine expression was a prognostic marker for lymph node metastases. The authors concluded that in the process of oral carcinogenesis, and during the progression of those tumors, take place disturbances of adhesion molecule expression. Some of those are associated with an unfavorable prognosis and others with an increased probability of developing metastases.

CD44 is a surface molecule playing an important role in metastases. In OSCC, the decreasing of immunoexpression is associated with the increasing of

invasive potential of tumors and the presence of metastases. Studies concerning the correlation of CD44 expression with survival rate indicate that the decrease of CD44 immunostaining correlates to long-term survival. The loss of cell adhesion is connected to the decreasing of CD44 expression, which can be one of the prognostic parameters [17, 18]. In conclusion, the regulation of CD44 expression can be considered the future target of the treatment [18, 19].

## ☒ Conclusions

The study indicated the decreasing degree of immunostaining for E-cadherine parallel with decreasing of OSC differentiation grade. If the differentiated types of the tumors presented entirely the highest degree of immunostaining (3<sup>rd</sup> degree), moderately differentiated once indicated a medium degree of immunostaining (2<sup>nd</sup> degree) and the poorly differentiated were negative or they had the lowest degree of immunostaining (1<sup>st</sup> degree).

The immunostaining degree for CD44 was correlated to the differentiation grade of investigated squamous carcinoma, the highest grade corresponding to well-differentiated types, but there were no more than 75% positive cells. In conclusion, the loss of cell adhesion is correlated to the decrease of CD44 and E-cadherine expression, which can be prognostic factors in OSCC evolution.

## References

- [1] SILVERMAN S. JR., *Demographics and occurrence of oral and pharyngeal cancers. The outcomes, the trends, the challenge*, J Am Dent Assoc, 2001, 132 Suppl:7S–11S.
- [2] LANDIS S. H., MURRAY T., BOLDEN S., WINGO P. A., *Cancer statistics, 1999*, CA Cancer J Clin, 1999, 49(1):8–31.
- [3] RIES L. A. G., HANKEY B. F., MILLER B. A., HARTMAN A. M., EDWARDS B. K., *Cancer Statistics Review, 1973–1988*, National Cancer Institute, NIH Publication No. 91–2789, Bethesda, 1991.
- [4] MITHANI S. K., MYDLARZ W. K., GRUMBINE F. L., SMITH I. M., CALIFANO J. A., *Molecular genetics of premalignant oral lesions*, Oral Dis, 2007, 13(2):126–133.
- [5] MEHROTRA R., GUPTA A., SINGH M., IBRAHIM R., *Application of cytology and molecular biology in diagnosing premalignant or malignant oral lesions*, Mol Cancer, 2006, 5:11.
- [6] MASSARELLI E., BROWN E., TRAN N. K., LIU D. D., IZZO J. G., LEE J. J., EL-NAGGAR A. K., HONG W. K., PAPADIMITRAKOPOULOU V. A., *Loss of E-cadherin and p27 expression is associated with head and neck squamous tumorigenesis*, Cancer, 2005, 103(5):952–959.
- [7] SANTOS-GARCÍA A., ABAD-HERNÁNDEZ M. M., FONSECA-SÁNCHEZ E., JULIÁN-GONZÁLEZ R., GALINDO-VILLARDÓN P., CRUZ-HERNÁNDEZ J. J., BULLÓN-SOPELANA A., *E-cadherin, laminin and collagen IV expression in the evolution from dysplasia to oral squamous cell carcinoma*, Med Oral Patol Oral Cir Bucal, 2006, 11(2):E100–E105.
- [8] LIN Y. C., WU M. Y., LI D. R., WU X. Y., ZHENG R. M., *Prognostic and clinicopathological features of E-cadherin, alpha-catenin, beta-catenin, gamma-catenin and cyclin D1 expression in human esophageal squamous cell carcinoma*, World J Gastroenterol, 2004, 10(22):3235–3239.
- [9] PYO S. W., HASHIMOTO M., KIM Y. S., KIM C. H., LEE S. H., JOHNSON K. R., WHEELOCK M. J., PARK J. U., *Expression of E-cadherin, P-cadherin and N-cadherin in oral squamous cell carcinoma: correlation with the clinicopathologic features and patient outcome*, J Craniomaxillofac Surg, 2007, 35(1):1–9.

- [10] HUNG K. F., CHANG C. S., LIU C. J., LUI M. T., CHENG C. Y., KAO S. Y., *Differential expression of E-cadherin in metastatic lesions comparing to primary oral squamous cell carcinoma*, J Oral Pathol Med, 2006, 35(10):589–594.
- [11] ZHONG L. P., LI J., ZHANG C. P., ZHU H. G., SUN J., ZHANG Z. Y., *Expression of E-cadherin in cervical lymph nodes from primary oral squamous cell carcinoma patients*, Arch Oral Biol, 2007, 52(8):740–747.
- [12] MAHOMED F., ALTINI M., MEER S., *Altered E-cadherin/beta-catenin expression in oral squamous carcinoma with and without nodal metastasis*, Oral Dis, 2007, 13(4):386–392.
- [13] SAKAKI T., WATO M., KAJI R., MUSHIMOTO K., SHIRASU R., TANAKA A., *Correlation of E- and P-cadherin expression with differentiation grade and mode of invasion in gingival carcinoma*, Pathol Int, 1994, 44(4):280–286.
- [14] KANKE M., FUJII M., KAMEYAMA K., KANZAKI J., TOKUMARU Y., IMANISHI Y., TOMITA T., MATSUMURA Y., *Role of CD44 variant exon 6 in invasion of head and neck squamous cell carcinoma*, Arch Otolaryngol Head Neck Surg, 2000, 126(10):1217–1223.
- [15] GONZÁLEZ-MOLES M. A., BRAVO M., RUIZ-ÁVILA I., ESTEBAN F., BASCONES-MARTÍNEZ A., GONZÁLEZ-MOLES S., *Adhesion molecule CD44 expression in non-tumour epithelium adjacent to tongue cancer*, Oral Oncol, 2004, 40(3):281–286.
- [16] BÁNKFALVI A., KRASSORT M., BUCHWALOW I. B., VÉGH A., FELSZEGHY E., PIFFKÓ J., *Gains and losses of adhesion molecules (CD44, E-cadherin, and beta-catenin) during oral carcinogenesis and tumour progression*, J Pathol, 2002, 198(3):343–351.
- [17] CARINCI F., STABELLINI G., CALVITTI M., PELUCCHI S., TARGA L., FARINA A., PEZZETTI F., PASTORE A., *CD44 as prognostic factor in oral and oropharyngeal squamous cell carcinoma*, J Craniofac Surg, 2002, 13(1):85–89.
- [18] SATO S., MIYAUCHI M., KATO M., KITAJIMA S., KITAGAWA S., HIRAOKA M., KUDO Y., OGAWA I., TAKATA T., *Upregulated CD44v9 expression inhibits the invasion of oral squamous cell carcinoma cells*, Pathobiology, 2004, 71(4):171–175.
- [19] FONSECA I., PEREIRA T., ROSA-SANTOS J., SOARES J., *Expression of CD44 isoforms in squamous cell carcinoma of the border of the tongue: A correlation with histological grade, pattern of stromal invasion, and cell differentiation*, J Surg Oncol, 2001, 76(2):115–120.

#### **Corresponding author**

Cristiana Simionescu, Professor, MD, PhD, Department of Pathology, University of Medicine and Pharmacy of Craiova, 66 1 May Avenue, 200 628 Craiova, Romania; Phone/Fax +40251–599 228, E-mail: csimionescu2004@yahoo.com

*Received: January 15<sup>th</sup>, 2008*

*Accepted: March 10<sup>th</sup>, 2008*