

CASE REPORTS

Dermatofibrosarcoma protuberans is CD117 negative even after extreme antigen retrieval conditions

A. FERNANDEZ-FLORES

*Service of Anatomic Pathology, Hospital El Bierzo
Service of Cellular Pathology, Clinica Ponferrada,
Ponferrada, Spain*

Abstract

Dermatofibrosarcoma protuberans (DFSP) is a malignant cutaneous tumor with a high rate of recurrence. Nevertheless, it responds to the drug Imatinib. The pathogenic mechanism why this drug works seems to be different to the inhibition of the Kit receptor of tyrosine kinase, since DFSP has repeatedly failed to express CD117 when immunohistochemically tested. Due to previous reports that claimed the presence of CD117 in DFSP, we designed a model of antigen retrieval under extreme conditions with two cases of DFSP from our archives. The slides were kept in the pressure cooker during 15 minutes (pH9). Moreover, the tissue was incubated with the primary antibody for 60 minutes. Three negative controls were also used. Even after the “over-retrieval” process, no convincing positivity was shown, although high background staining notably increased. We also discuss several alternatives that have been given in literature to explain the mechanism of how Imatinib works in DFSP.

Keywords: CD117, Imatinib, dermatofibrosarcoma protuberans, c-kit, antigen retrieval.

Introduction

Dermatofibrosarcoma protuberans (DFSP) is a cutaneous malignant tumor which presents a high recurrence rate, but in which the drug Imatinib (STI571) can be successfully used to control recurrence. The mechanism about how Imatinib works with DFSP does not seem to be the same as in other malignant tumors, i.e., the inhibition of the Kit receptor of tyrosine kinase. The reason in believing so is that DFSP hardly ever expresses CD117 in literature when immunohistochemically studied. Since some controversial studies have previously demonstrated expression of the marker by DFSP, and due to the good response that the tumor shows to Imatinib, we studied to see if any kind of expression could be found when the tissue was treated under extreme conditions for antigen retrieval.

Material and methods

We recovered two cases of DFSP from our archives. Immunohistochemistry was performed with the Dako REAL EnVision detection system, peroxidase/DAB+, rabbit/mouse, and with heat induced epitope retrieval (HIER) using Dakocytomation target retrieval solution (code S2367). The latter process lasted 5 minutes in a pressure cooker, pH 9.

Endogen peroxidase was blocked with DakoCytomation peroxidase-blocking reagent (code S2021). We used the wash buffer DakoCytomation (code 53006). This process was used for vimentin (DakoCytomation, monoclonal mouse anti-swine, clone V9, code N1521), CD34 (DakoCytomation, monoclonal mouse anti-human,

class II, clone QBEnd-10, code M7165), and CD117 (Polyclonal rabbit anti-human c-kit, code A4502, dilution 1/50).

We designed a model of “over-retrieval” of the antigen CD117, with a longer time of heating retrieval than the one which is normally followed. We also designed an exposure of the tissue to the primary antibody for longer than usual. For that, the slides were kept in the pressure cooker during 15 minutes (pH 9). Moreover, the tissue was incubated with the primary antibody for 60 minutes. The rest of the conditions of the process did not vary. Three negative-controls for CD117 were used under the same procedure: hyperplastic prostate, infiltrating breast cancer and colonic adenocarcinoma.

Results

Case no. 1 corresponded to a 61-year-old woman who presented a nodule on the dorsal side of the left foot. The lesion was 3 cm in its maximum diameter.

Case no. 2 corresponded to a 50-year-old man who presented with a suprapubic nodule of 2.8 cm in its maximum diameter.

The two cases showed typical morphology of DFSP (Figure 1). Both cases expressed vimentin and CD34, but they failed to express CD117. Even after the “over-retrieval” process, no convincing positivity was shown, although high background staining notably increased. Moreover, mast cells were used as an internal control, and they were very helpful in evaluating real positivity (Figure 2). The same results were obtained with the negativity controls.

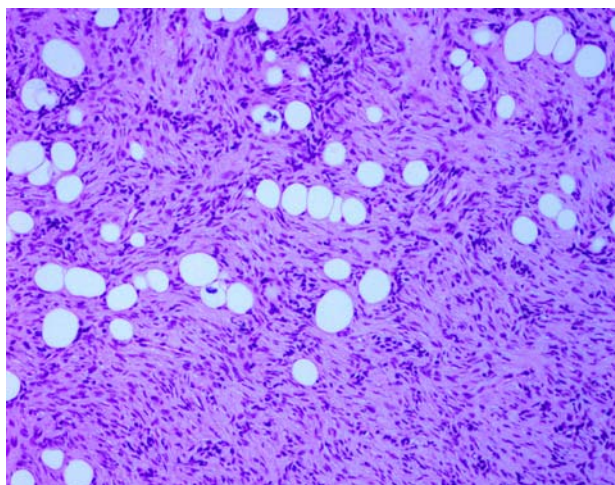


Figure 1 – Biopsy from case no. 2, showing typical morphology of a dermatofibrosarcoma protuberans infiltrating the subcutaneous tissue

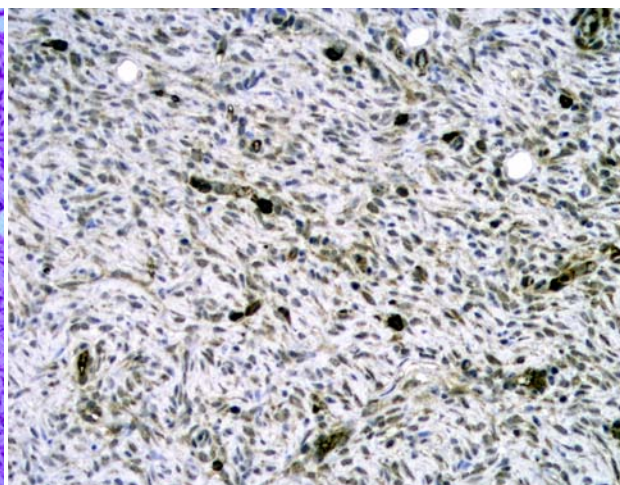


Figure 2 – Immunostaining for CD117 after antigen-retrieval under extreme conditions. Although the background staining was stronger than usual, no convincing positive expression was observed in the tumor. Moreover, mast cells were a useful comparative internal positive control

☐ Discussions

Dermatofibrosarcoma protuberans (DFSP) is a cutaneous malignant tumor with a high rate of recurrence. Recently, Imatinib (STI571) has been successfully used in many cases of DFSP (Buchdunger E *et al.*, 2002) [1], although not all cases respond to the drug (Maki RG *et al.*, 2002) [2].

In other tumors, such as gastrointestinal stromal tumor, Imatinib works through the inhibition of the Kit receptor of tyrosine kinase. Nevertheless, this mechanism seems little plausible in the case of DFSP, since the latter has been constantly negative for CD117 in immunohistochemical studies (Hornick JL and Fletcher CD, 2002), with rare exceptions (Sarlomo-Rikala M *et al.*, 2004; Seo IS *et al.*, 2003) [3–5].

CD117 is the antibody that recognizes the membrane receptor of tyrosine kinase, which is involved in the therapeutic mechanism explained above.

When the antibody CD117 was tested in several tumors in literature, different (and sometimes paradoxical) results were obtained by different groups. This has sometimes been attributed to the antigen-retrieval system (Hornick JL and Fletcher CD, 2002) [3].

Heat-based antigen retrieval has been used in the immunostaining of DFSP by CD117 antibody with negative results in all four cases studied (Barisella M *et al.*, 2002) [6].

Others have found focal expression of CD117 by DFSP in three out of 20 cases (15%) when using microwave-based epitope retrieval with two successive 5 minutes heating periods on high setting (Sarlomo-Rikala M *et al.*, 1998) [4].

Our results seem to corroborate previous findings on the negativity of DFSP for CD117. Since CD117 does not seem to be a plausible mechanism why Imatinib works in DFSP, other explanations have been argued as responsible for its therapeutic properties.

It is well known that Imatinib is able to inhibit the Bcr-Abl protein tyrosine kinase and also, it has

antiangiogenic effects by inhibiting the platelet derived growth factor (PDGF), the vascular endothelial growth factor and the basic fibroblast growth factor (Buchdunger E *et al.*, 2002) [1].

The translocation t (17;22) is present in many (but not in all) DFSPs. Because of this, the collagen type I alpha-1 gene fuses with the PDGF B-chain gene (Saeki H *et al.*, 2005) [7]. That way, the second gene is ruled by the promoter of the first one (McArthur GA *et al.*, 2005) [8], and the outcome is the overproduction of a transforming protein that is indistinguishable from the wild type (Shimizu A *et al.*, 1999) [9].

Since Imatinib inhibits the PDGF and since PDGF is overexpressed in DFSP with the translocation, it is tempting to admit that this would be the pathologic explanatory model. The presence of activated PDGF receptors in primary cultures from DFSP was demonstrated in the past (Sjöblom T *et al.*, 2001) [10]. Moreover, there is, at least, one reported case of a DFSP lacking translocation, and which did not respond to the drug (McArthur GA *et al.*, 2005) [8].

☐ Conclusions

Dermatofibrosarcoma protuberans does not express CD117 even after extreme antigen-retrieval conditions. If background stain increases under such conditions, mast cells can be used as an internal positive control.

References

- [1] BUCHDUNGER E., O'REILLY T., WOOD J., *Pharmacology of Imatinib (STI571)*, Eur J Cancer, 2002, 38(Suppl 5):S28–S36.
- [2] MAKI R. G., AWAN R. A., DIXON R. H., JHANWAR S., ANTONESCU C. R., *Differential sensitivity to imatinib of 2 patients with metastatic sarcoma arising from dermatofibrosarcoma protuberans*, Int J Cancer, 2002, 100(6):623–626.
- [3] HORNICK J. L., FLETCHER C. D., *Immunohistochemical staining for KIT (CD117) in soft tissue sarcomas is very limited in distribution*, Am J Clin Pathol, 2002, 117(2):188–193.

- [4] SARLOMO-RIKALA M., KOVATICH A. J., BARUSEVICIUS A., MIETTINEN M., *CD117: a sensitive marker for gastrointestinal stromal tumors that is more specific than CD34*, *Mod Pathol*, 1998, 11(8):728–734.
- [5] SEO I. S., GOHEEN M., MIN K. W., *Bednar tumor: report of a case with immunohistochemical and ultrastructural study*, *Ultrastruct Pathol*, 2003, 27(3):205–210.
- [6] BARISELLA M., ANDREOLA S., ROSAI J., *CD117 in soft tissue sarcomas*, *Am J Clin Pathol*, 2002, 118(3):470–471; author reply 472.
- [7] SAEKI H., TSUNEMI Y., OHTSUKI M., KIKUCHI K., TAMAKI K., *Gene mutation analysis in five cases of dermatofibrosarcoma protuberans using formalin-fixed, paraffin-embedded tissues*, *Acta Derm Venereol*, 2005, 85(3):221–224.
- [8] MCARTHUR G. A., DEMETRI G. D., VAN OOSTEROM A., HEINRICH M. C., DEBIEC-RYCHTER M., CORLESS C. L., NIKOLOVA Z., DIMITRIJEVIC S., FLETCHER J. A., *Molecular and clinical analysis of locally advanced dermatofibrosarcoma protuberans treated with Imatinib: Imatinib Target Exploration Consortium Study B2225*, *J Clin Oncol*, 2005, 23(4):866–873.
- [9] SHIMIZU A., O'BRIEN K. P., SJÖBLOM T., PIETRAS K., BUCHDUNGER E., COLLINS V. P., HELDIN C.-H., DUMANSKI J. P., ÖSTMAN A., *The dermatofibrosarcoma protuberans-associated collagen type I α 1/platelet derived growth factor (PDGF) B-chain fusion gene generates a transforming protein that is processed to functional PDGF-BB*, *Cancer Res*, 1999, 59(15):3719–3723.
- [10] SJÖBLOM T., SHIMIZU A., O'BRIEN K. P., PIETRAS K., DAL CIN P., BUCHDUNGER E., DUMANSKI J. P., ÖSTMAN A., HELDIN C.-H., *Growth inhibition of dermatofibrosarcoma protuberans tumors by the platelet-derived growth factor receptor antagonist STI571 through induction of apoptosis*, *Cancer Res*, 2001, 61(15):5778–5783.

Corresponding author

Angel Fernandez-Flores, MD, PhD, Servicio de Patología Celular, Clinica Ponferrada, Avenida Galicia 1, 24400 Ponferrada, Spain; Phone (0034) 987 42 37 32, Fax (0034) 987 42 91 02, E-mail: gpyauflowerlion@terra.es

Received: September 10th, 2007

Accepted: September 20th, 2007