

## ORIGINAL PAPER

# The venous system of the lower limbs

F. CALOTĂ<sup>1,2)</sup>, S. MOGOANTĂ<sup>2)</sup>, M. ÎNTORCACIU<sup>2)</sup>,  
M. PAŞALEGA<sup>1,2)</sup>, CARMEN FLORINA POPESCU<sup>3)</sup>,  
I. VASILE<sup>1,2)</sup>, C. MEŞINĂ<sup>1,2)</sup>

<sup>1)</sup>General Surgery Department

<sup>2)</sup>II<sup>nd</sup> General Surgery Clinic,  
Emergency County Hospital of Craiova

<sup>3)</sup>Morphopathology Department  
University of Medicine and Pharmacy of Craiova

### Abstract

The venous system anatomy of the lower limbs and especially its functionality still presents half-lighted areas, fact easily qualified as incredible for the third millennium. Our dissections on fresh amputation segments, methylene blue injected in superficial veins or in deeper veins pointed out that venous circulation is much more complex than it seemed, that there are subdermal collectors connected to the saphene trunks which permit bidirectional transfer of blood mass to saphene venous roots or to derm. The dermal plexus has also a complex connection with the deep venous system by Delater perforators, by perforators, which drain saphene systems after having previously received dermal affluents, and by Delater equivalences (submillimetric perforators) that provide blood mass transfer from deep to surface under the conditions of a moderate and temporary venous hypertension. High- and long-term venous hypertension determines the valvular device deterioration of classical perforators making possible a pathological bi-directional flow.

**Keywords:** superficial veins, deep veins, “compartment”, perforators, Delater-like.

### Introduction

The venous system anatomy of the lower limbs and especially its functionality still presents lacunae, phenomenon that can be easily considered incredible for the III<sup>rd</sup> millennium.

Clinical and intraoperator remarks made us pay more attention to the venous anatomy of the pelvic members dissecting traumatic and therapeutic amputation segments.

The goal was to answer some older questions concerning the anatomy and physiology of the lower limbs venous system whose answer was intuitively formulated a few years ago [1].

### Material and methods

Sixteen pieces of traumatic and therapeutic amputation were used from the thighs level for obstructive chronic arteriopathy, Fontaine IV stage.

The dissections made on eight pieces aimed at pointing out ISV and ESV trunks in the calf course and at the knee level with possibility of revealing confluence with popliteal vein.

We also aimed at pointing out the perforators. We used methylene blue injection, initially retrograde, then anterograde in saphene trunks.

For the other eight cases, we discovered posterior tibial vein where, on catheter, we injected 10–15 ml methylene blue, ISV and SFV trunks being ligatured. All the remarks were stocked on digital photos deep venous system (DVS).

### Results

The images were repeatedly analyzed. Images in dynamics revealed precocious dye filling of the *subdermal collector vein* at retrograde injection (Figure 1), but also anterograde of the internal saphenous vein (ISV) trunk. Dermal segmental filling and dense primary filling of the dermal system when injecting the dye in the posterior tibial vein were also obvious.

Retrograde injections with methylene blue in the internal saphenous vein (ISV), under knee level, colors the afferent subdermal venous sections, from which dye passes also in the intradermal space (Figure 1) suggesting valvules absence at these levels. The drainage was so massive that the dye releases abundantly by the skin incision (Figure 2). Dermal system drainage was relatively reduced in saphene veins trunks (Figure 3).

Deep venous system (DVS) injecting with methylene blue points out long venulae going up from the transaponevrotic musculature, oriented almost perpendicular on derm, which fill inversely, strong argument for valvules absence (Figure 5). Through these perforators more or less extended areas from the derm are injected, staining the skin with dye similar to the *livedo reticularis* aspect, but with other zonal distribution.

We noticed an extended diffusion of the distal, circumferential and proximal dye in dermal system (Figure 4). Dermal circumferential diffusion was more obvious in the calf's distal third part.

The drainage of the skin areas is realized in the deep venous system by direct perforators but also in the saphenian system by short segments (Figure 7).

It is interesting to notify that dermal areas filled with dye are actively drained towards collector veins, the stained aspect shading off step by step, as collateral and saphene trunks fill. These considerations make us take into account a spontaneous drainage activity of dermal capillaries still present at short time from amputation. Intra-arterial colorant injecting is followed by a much more intense and more extended derm coloring than injecting in the deep venous system with the clear pointing out of the subdermal veins. Cutaneous and subcutaneous network emptying is made in a more reduced ratio in saphene veins, drainage being preferential towards deep veins which affluents are well colored. Lymphatic network from calf fascia (Figure 8) and periosteum is also injected.

## ☞ Discussions

Venous system of the lower limbs have a stratified disposal, the limit being realized by the saphene surface fascia and the muscular fascia of the limbs [2, 3] that structurally and anatomically makes a dense, fibrous cover anchored in the osteo-muscular relief of the pelvis, thigh, knee, shank and feet. Three anatomic compartments are thus distinguished, noted as a result of the established accord to the 14<sup>th</sup> International UIP Congress in Rio de Janeiro, in 2005 as: deep (AC1), saphene (AC2) and superficial (AC3) [4].

In AC1 compartment delimited outside by the muscular fascia, there is the deep venous system symbolized by N1. Axial veins are disposed between the muscular lodges, in a conjunctive atmosphere and they are approached by muscular affluents (they can have also perforator veins in their basin) and interstitial affluents (frequently, directly perforator veins of great size). The deep system N1 features are the following [5]:

- main venous trunks are placed between muscular lodges, in a conjunctive atmosphere beside the homonym arteries and covered in a vascular sheath made of a dense conjunctive tissue. Often, venous and arterial nutritive branches (*vasa vasorum*) have a common trunk. The vascular sheath can be interested in the inflammatory processes with venous or arterial starting point after turning into a real shell;
- the structure of the veins is mostly fibrous;
- disposal is convergent;
- deep veins are a main constituent of the musculo-venous pump;
- they are not submitted to thermal variations;
- on the whole, they represents *the passive component* of the musculo-venous pump system of the lower limbs.

The extrafascial venous drainage of the lower limbs is provided by a rich system composed of the following elements, more or less delimited as an anatomic drainage area:

- the network of the internal saphene system;
- the network of the external saphene system;

- extrasaphenian network.

Both saphene systems were placed in the “saphene compartment”, AC 2. N2 network is situated here, being represented by the trunks of *saphene venae* and Giacomini vein. In the compartment, we believe logical to place also the accessory saphene veins, collateral of the 1<sup>st</sup> order of ISV, all of them being surrounded by a discrete fibrous condensation, extension of saphene fascia. Saphene trunks and their major affluents have direct relations with the muscular fascia of which they are anchored. The trunk of the external saphene vein has in its proximal half an intrafascial course (saphenian tunnel) and sometimes almost completely subfascial [5].

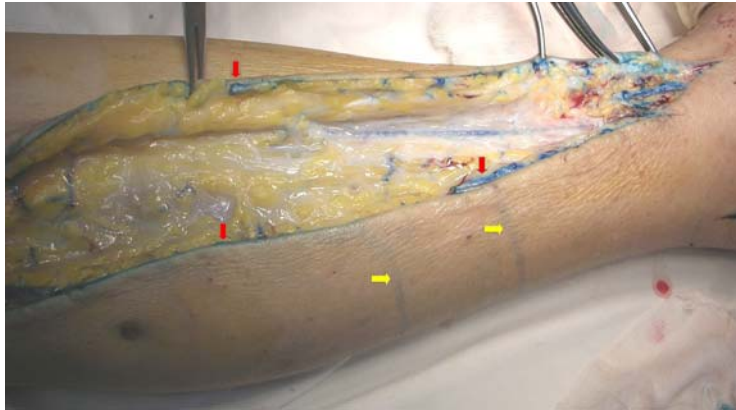
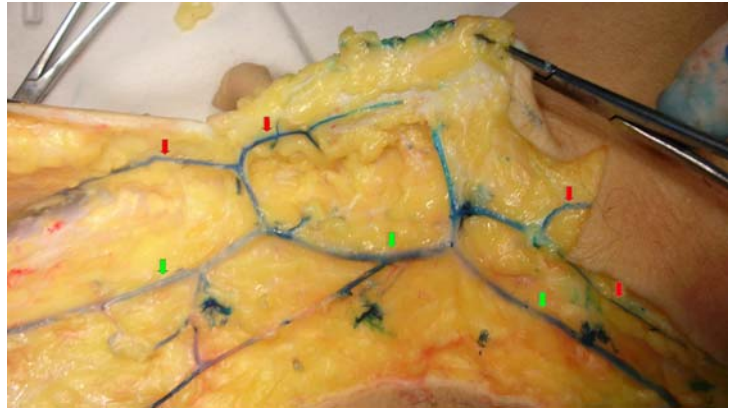
Giacomini vein has segmentary and variably a subfascial disposal, attracting a false perforator reputation. Saphene vein sticks approach deep venous system (DVS) in areas of great mobility, on flexion side of the knee and coxo-femoral articulation. In these areas, the frequent course changes with acute angulations and section deformations, determine temporary perturbations of the flowing conditions.

In the “surface compartment” AC 3, there is the N3 network. This network represents, the lake, which can be more or less delimited, of “saphene compartment” and insular, inserted, of the deep system in which drains directly “the extrasaphenian network”. It is the most complex network and the less accessible to direct observation also due to a lively, specific dynamics. Constituted of the venous side of dermic circulation (microvenulae – diameter < 0.01mm and venulae drainage of 0.01–0.1 mm diameter), it is often an avalvulate network.

Dermic vascularization, as a component of the surface compartment, acts like a real vascular sponge very reactive to environmental temperature variations and to vegetative venous stimuli. In the compartment there is also a venulae network with large eyes placed in direct contact to the derm, avalvulate, by which reflux is possible from saphene collaterals or from saphene trunks when connection is made with saphene system. Subdermic network allows longitudinal circulation in surface when caloric dissipation is necessary.

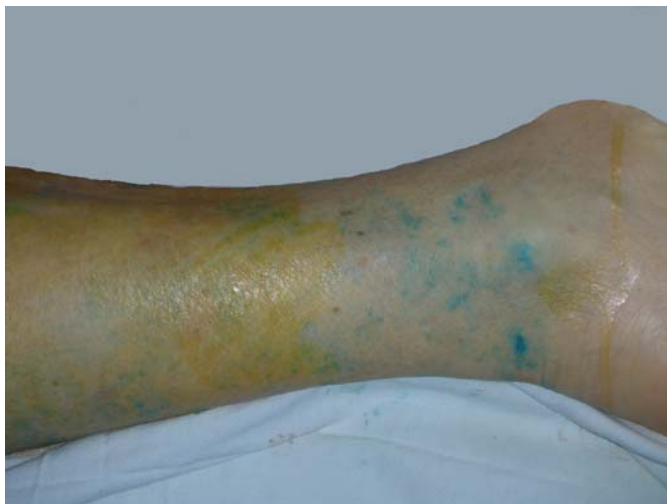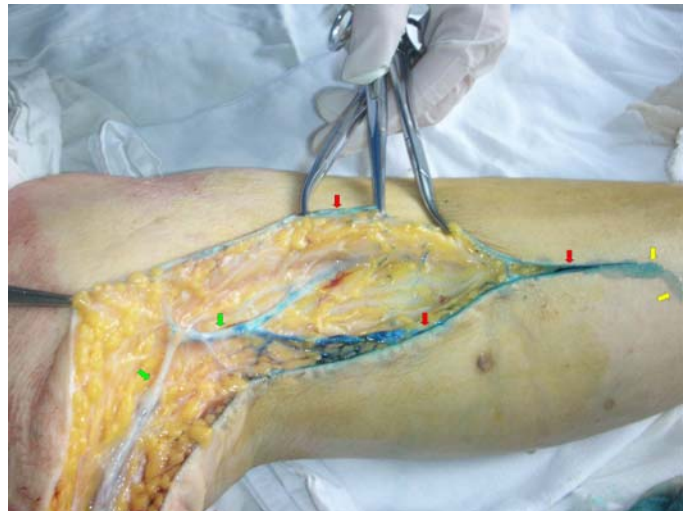
The appearance of the dye in afferent subdermal venous segments and then in the intradermal space at retrograde injections in the internal saphenous vein (ISV) (Figure 1), is an argument for valvules absence at these levels. This network receives also many affluents from the surface derm, but especially deep and drains either in N2 network, and then in N1 or directly in N1 or simultaneously in N2 through interposed collaterals and in N1 through direct perforators – Delater diving veins (Figure 5) or *Delater-like veins* (Figure 6) – thin veins with the section surface diameter less than 1 mm, which permit a bidirectional flux. Much more ample, but also much more complex connection of N3 network to the other venous layers (N2 and N1) can be explained by its participation in thermolyse and conservation of endogen heat. Precocious skin staining (*livedo reticularis* like) when injecting DVS with methylene blue, pointed out long venulae going up from the transaponevrotic musculature, oriented almost perpendicular on derm which fill inversely (Figure 5).

**Figure 1 – Precocious dye filling of the subdermal collector vein at retrograde injection of ISV:**  
 → subdermal collectors; → saphene compartment (ISV and afluent)



**Figure 2 – The dye injected in the posterior tibial vein results in:** → dense primary filling of the dermal system; → traces marking the flow of the dye released by skin incision

**Figure 3 – The dye injected in the posterior tibial vein results in:** → dense primary filling of the dermal system; → reduced drainage in saphene veins trunks; → traces marking the flow of the dye released by skin incision



**Figure 4 – Dermal circumferential diffusion more obvious in the calf's distal third part**

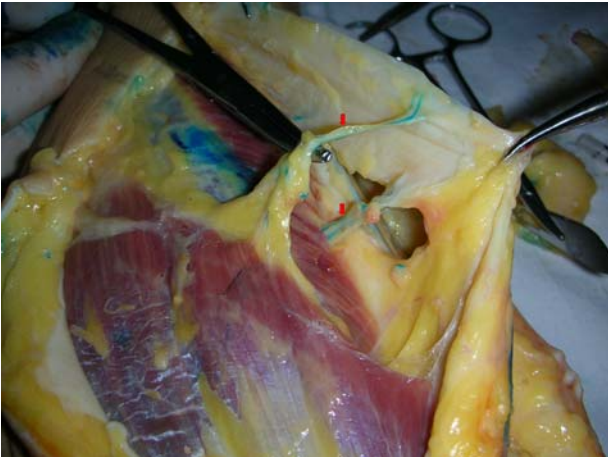

Figure 5 – *Delater diving veins*

Figure 6 – *Small veins ( $\Phi \leq 1$  mm) with a bidirectional flux that we called Delater-like veins*

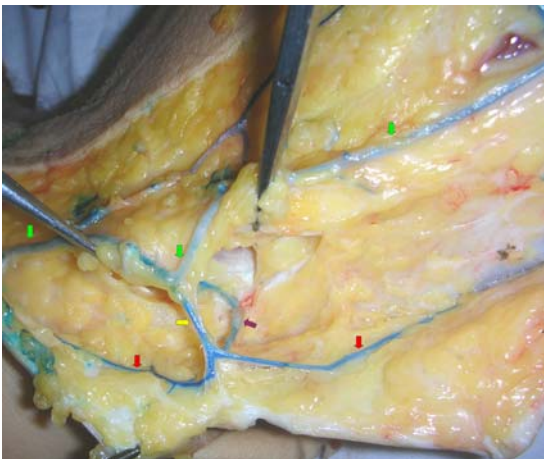
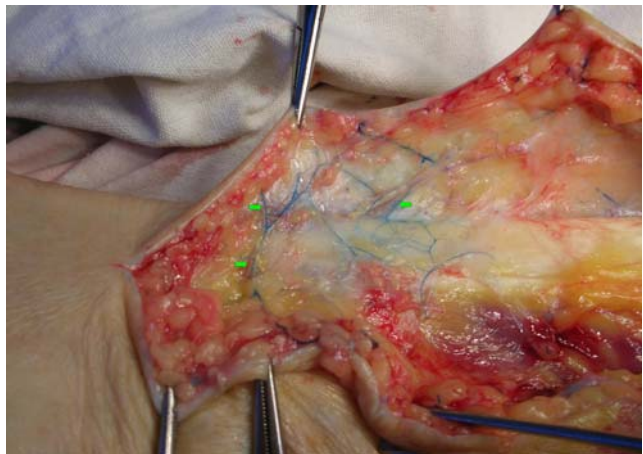
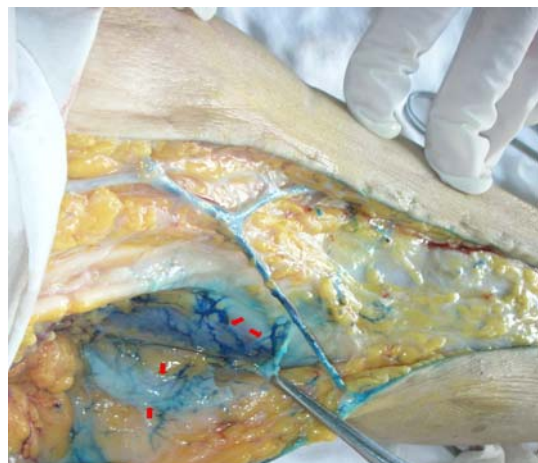

Figure 7 – *Derm drainage pathways: → subdermal collectors; → saphene compartment (ISV and affluents); → short venous segment linking the subdermal collectors with saphene system; → perforating vein linking the subdermal collectors with the profound venous system*

Figure 8 – *Lymphatic network from calf fascia and periosteum represents an interesting drainage system*



This phenomenon occurred when injecting a small quantity of dye (10–15 ml) in the presence of popliteal vein ligation. In other words, because of a moderate venous hypertension in DVS, there is a precocious mass transfer in the dermic venous space by an avalvulate venulae system, which perforates the muscular fascia. Preferentially, the most affected part is the skin of the calf distal half, place of favorite occurrence of ulcers in chronic venous insufficiency (CVI) context. Capillary, microvenular and dermic venular network abundance, on the whole realize a big section surface (total resistance at very small flowing, result of canceling the adrenergic impulses due to the interruption of the nervous pathways, because of the amputation) making possible a large circumferential diffusion both proximal and distal of the dye until to the external side of the leg (Figure 4), even if injecting occurred only in the posterior tibial vein, retromaleolary.

These elements plead for anatomofunctional continuity of superficial venous network. The great variability of flowing resistance in the skin circulation makes this act permissively or restrictively at filling. The phenomenon of derm blood loading is realized, physiologically, not only through arterial way, but also venous. It is known that at leg's level, there are a lot of avalvulate perforators. Our remarks because of colorant injections in deep veins and its occurrence in the calf's skin plead for some avalvulate perforators presence at this level that we called *Delater-like veins*. During the musculo-venous "systole" from orthodynamism, it is possible to use, some of these ways in order to prevent considerable increases of venous pressure from the segments situated upstream the pump.

Arterio-venous shunts are motion elements of the regulator *feed-back* of dermal loading on the arterial side. Primary insufficiency or deterioration of the veno-arterial reflux perturbs the mechanisms of N3 network emptying, compartmental congestion having as clinical expression the painful tension and edema. Saphene network (trunks and collaterals) spatially placed between the deep compartment – AC1 and the surface one – AC3, represents an *accessory network* with functions of unloading, swab and immediate massic volume taking over. Thus, the minor effect of surgical removal, more or less restrained, of some trunk segments and/or collaterals belonging to saphene systems, can be also explained functionally.

Alternative drainage of skin areas in deep veins by direct perforators or Delater diving veins realizes by an intermediate segment, usually short, which leads in saphene trunks or in saphenian collaterals. It is a prompter unidirectional mechanism of unloading debits from the surface compartment (Figure 7).

Total resistance decrease at dermal vascular network level leads to a real blood "absorption", especially of the venous one from the subfascial compartment, the derm becoming a vascular lake fed by deep sources almost perpendicular. The great variability of the total resistance at flowing of dermic circulation generated by thermal, venous vegetative, cytokine stimuli, reflects in a richer or poorer blood "extraction" from the deep compartment.

This phenomenon represents also a protection for the arterial circulation, for the whole cardioarterial segment, which can offer to the skin only "economic" debits, the venous system having to keep a certain degree of filling mainly correlated with environment requirements. Increased resistance at flow in deep veins opens the functional locks of Delater-like veins (in cases of venous stasis) or forces until destroys the anatomic locks (valvules) of direct perforators (in cases of high gravity venous hypertension or in the context of ambulatory hypertension peaks, of pump). After injecting the deep system with a relatively reduced volume of methylene blue (10–15 ml) the skin's incision lets the dye from derm to fill-out, while veins within the hypoderm fill segmentary with dye from derm (Figure 2).

Extrafascial venous network composed of the saphene and surface compartments has the following features [5]:

- disposal is reticular in three layers;
- subcutaneous layers are placed in a lax conjunctive-adipocitary background;
- it is exposed to traumatism (spatial disorganization) and to external compressions (spatial deformation and by clothing items);
- it is exposed to big thermal variations;
- musculoelastic structures are well represented in venous walls;
- it is an additional component of the muculo-venous pump of lower limbs;
- complex representation of a 2-adrenergic, purinergic receptors and of receptors for progesterone in smooth muscular cells of ISV. The presence of estrogenic receptors is debatable;
- it represents *the active, dynamic component* of the lower limbs venous system.

Extrasaphenian network drains relatively extended skin areas from the external and internal side of leg and thigh postero-external side. Sometimes, even inside areas drained by the two-saphene systems there can be insular skin areas, which are directly drained in the deep system. Thus, on the leg's internal side there were described, for the first time by Delater, direct perforating veins that he called diving. These drain a certain skin surface through several venulae "in bunch" that then converge in a single trunk at some millimeters under derm. The route is perpendicular on deep veins similarly to calf perforators important for pathology. Extrasaphenian network can be constituted, sometimes, by all the collaterals that drain in a vestigial embryonic vein represented by the external marginal vein. Blood is drained in calf's deep system, in peronier vein through perforators of the proximal peronier epiphysis; in geniculate segment there can be connections with the venous circle of the knee made from veins that drain, some in popliteal or peronier vein, others in ISV collaterals. At thigh level, drainage towards deep femoral vein is carried out through some indirect perforators. Skin area of the posterior thigh under the buttocks ditch often drains ascending towards ischiadic, big and middle buttocks or lower hemorrhoidal venous pedicles.

The connections of the extrasaphene venous areas of thigh are also usual made by communicating veins with the posterior saphene vena of the thigh.

Perforating veins that drain the surface network in DVS are usually of small size. Under certain circumstances (pelvic varicocele, pelvic venous thrombosis, postpartum) through sub-buttocks perforators, vestigial embryological veins are reactivated from the postero-external side of thigh which turns into varicose vein.

### ☒ Conclusions

The venous system of the lower limbs has a compartmental disposal, the venous circulation sense being that described classically from distal to proximal and from surface to depth. We notice the anatomic-functional continuity of the surface network.

The great variability of resistances at flowing from the surface compartment, determined by the receptivity at the action of a large range of stimuli make the dermal venous network balance the loading debit with the deep veins.

Saphene systems achieve in these conditions an accessory network role, sometimes with interface function between the other two components.

The venulae named by us Delater-like veins allow, due to the valvules absence, a blood mass transfer towards the dermal network when the venous pressure from the deep system register moderate increases and, probably, also in thermolyse conditions.

### References

- [1] CALOTĂ F., *Varicele hidrostatice – o nouă concepție patogenică*, Teză de doctorat, U.M.F. "Iuliu Hațieganu", Cluj-Napoca, 1999.
- [2] CAGGIATI A., *The saphenous veins compartments*, Surg Radiol Anat, 1999, 21(1):29–34.
- [3] CAGGIATI A., *The nomenclature of the veins of the lower limbs, based on their planar anatomy and fascial relationships*, Acta Chir Belg, 2004, 104(3):272–275.
- [4] CAGGIATI A., BERGAN J. J., GLOVICZKI P., EKLOF B., ALLEGRA C., PARTSCH H., *International Interdisciplinary Consensus Committee on Venous Anatomical Terminology. Nomenclature of the veins of the lower limb: extensions, refinements, and clinical application*, J Vasc Surg, 2005, 41(4):719–724.
- [5] CALOTĂ F., CAMEN D., *Atlas of vascular endoscopy of the lower limbs*, Ed. Sitech, Craiova, 2006.

### Corresponding author

Firmilian Calotă, Associate Professor, MD, PhD, II<sup>nd</sup> General Surgery Clinic, Emergency County Hospital of Craiova, 1 Tabaci Street, 200 642 Craiova, Romania; Phone +40723–612 999, +40251–502 366, E-mail: ssmogo@yahoo.com

*Received: October 22<sup>nd</sup>, 2007*

*Accepted: November 25<sup>th</sup>, 2007*