

ORIGINAL PAPER

Clinico-imagistic and anatomopathologic correlations in sarcomas of maxilla

DANIELA DUMITRESCU¹⁾, PETRA ȘURLIN²⁾, CRISTIANA SIMIONESCU³⁾,
MIHAELA MITROI⁴⁾, CRISTIANA IULIA DUMITRESCU⁵⁾,
M. POPESCU¹⁾, ZOIA STOICA¹⁾

¹⁾Department of Radiology and Medical Imagery

²⁾Department of Periodontology

³⁾Department of Pathologic Anatomy

⁴⁾Department of Otolaryngology

University of Medicine and Pharmacy of Craiova

⁵⁾Cordis Clinics, Craiova

Abstract

Sarcomas are relatively uncommon tumors, accounting for 1% of all malignancies. Sarcomas are commonly classified according to their site of origin: soft tissues or bone. The purpose of the clinic study was to focus the symptoms and the clinic signs. The radio-imagistic study is essential in the evaluation of the maxilla tumors. The histopathologic study was done to determine the histological type, the differentiation level, the invasion level as well as the presence or absence of the metastases in drainage ganglia. The correlation of the findings of this study leads to a clear and correct clinic diagnosis, an adequate local or general therapy and a prognostic. The diagnostic role of imaging is essential and often permits the orientation to benignity or, on the contrary, requires biopsy if the image is an aggressive one or of uncertain nature. Advances in diagnostic imaging have contributed substantially to the management of tumors. The strong collaboration among the physician, imagist and anatomopathologist serves the patient's benefit.

Keywords: maxilla, sarcomas, computed tomography.

Introduction

Sarcomas are relatively uncommon tumors, accounting for 1% of all malignancies. Sarcomas are commonly classified according to their site of origin: soft tissues or bone. Approximately 80% of sarcoma arises from soft tissue, while 20% originate from bone.

Sarcomas involving cartilage (chondrosarcoma) and peripheral nerve tissue (malignant schwannoma) are included in the soft tissue category because they share a mesenchymal origin. Some soft tissue sarcomas may arise in bone (malignant fibrous histiocytoma, fibrosarcoma) and sarcomas of bone may have extra-osseous manifestations; therefore, the classification of soft tissue versus bone sarcoma depends more on histological findings than clinical findings [1].

Material and methods

Within the period July 1995–July 2005 we examined a lot of 373 patients with tumors of facial bone. All the patients were subjected to clinical, radioimagistic and histopathologic examinations. ENT exam consisted in physical data and sinusal endoscopy.

CT scanning was performed with thin sections of 3–5 mm growth, native and after contrast *i.v.* In some cases (72 patients) the image investigation was completed by MRI. MRI is an examination that completes CT scan, being of utmost importance in the

evaluation of extensive lesions in the soft tissues such as pterigomaxillary fosse, orbit or endocranium and dura mater.

The material for histopathology and immunohistochemistry was provided from ENT Department and consisted of ablated tissues.

The work-up was after the usual technique: paraffin inclusion followed by Hematoxylin–Eosin staining.

The tumor diagnosed as angiosarcoma was investigated by immunohistochemistry by LSAB/HRP method with anti CD31 antibodies to confirm the vascular origin.

Results

We met chondrosarcoma in maxilla of a 24-years old patient who clinically presented facial asymmetry, without any changes in the nasal fossae. CT examination delineated the maxilla right tumor with calcifications in the tumor matrix (Figure 1, a–c). The anatomopathologic examination confirmed the diagnosis of differentiate chondrosarcoma (Figure 1, d and e).

We met sarcomas in the nasal fosse in three cases: a chondrosarcoma (Figure 2), and two rhabdomyosarcomas.

We met pleomorphic rhabdomyosarcoma in the nasal fosse of a 14-year-old patient (Figures 3 and 4).

We encountered angiosarcoma at a 14-year-old patient (Figure 5).

We encountered angiosarcoma at a 14-year-old patient. Histopathological study on revealed a multitude of microscopically aspects (Figure 6).

Malignant fibrous histiocytoma is a rare disease and it is accepted as separate entity, distinct from fibrosarcoma (Figure 7).

☐ Discussions

The purpose of the clinic study was to point out the symptoms and the clinic signs. The anamnesis findings can reveal different favorizing factors for malignant neoplasia.

The radioimagic study is essential in the evaluation of the maxilla tumors. We made radiographic, CT and MRI examinations to underline the alterations in shape and bony structure and the modifications at the level of nasal fosse and paranasal sinuses.

The CT exam of the bone frame is highly decisive to delimit the bony modifications and to focus the possible tumor calcifications [2, 3].

Post contrast examination is useful in delineating the infiltration and extension to the nearby sites, appreciating the relationship of the tumor to adjacent vessels and the presence of distant metastases allowing a correct and exact diagnosis.

MRI is superior to CT scan for assessing the extent of tumor involvement [4].

MRI surpasses CT scan in identifying perineural spread and intracranial extension [4, 5].

MRI is useful in evaluating subtle soft tissue changes and can be used to differentiate between inspissated secretions and tumor. This differentiation is not always possible with CT scans [6].

CT scan and MR are complementary in the evaluation of malignant lesions of nasal-sinusal cavity. They have to delineate as accurately as possible the tumor process, to evaluate the peritumoral inflammation and associated intracavitary retentions and to study the extension to infratemporal fosse within pterigopalatin fosse, rhinopharynx or intracranial [7].

Occasionally, imaging findings can suggest the correct diagnosis, but definitive diagnosis requires histological evaluation of a certain representative biopsy specimen.

The histopathologic study was done to determine the histological type, the differentiation level, the invasion level as well as the presence or absence of the metastases in afferent lymph nodes.

The correlation of the findings of this study leads to a clear and correct clinic diagnosis, an adequate local or general therapy and a prognostic.

It is very difficult to precisely delineate a tumor, especially at the level of sinusal cavities, where inflammatory reactive manifestations are often noticed. CT examination permits the localization of the starting point of the tumor: tubes, septum, sinuses, but it is very difficult to determine the starting point of a large tumor.

We identified six sarcomas of maxilla among 373 cases of facial tumors studied.

Males and females are equal affected (3 : 3 ratio).

The encountered topography was as follows:

- one maxillary chondrosarcoma;
- one nasal fosse chondrosarcome
- two nasal fosse rhabdomyosarcomas;
- one angiosarcoma at the level of maxillary and etmoid sinuses;
- one malignant fibrous histiocytoma.

Chondrosarcoma is a cartilaginous tumor, representing 1% of malignant bony tumors. Chondrosarcomas arise in cartilage or bone and account for 20% of primary malignant bone tumors.

Approximately 5–10% of chondrosarcomas are located in the head and neck; they most commonly involve the larynx, followed by the maxilla, mandible, and the base of the skull.

Chondrosarcomas occur in persons of different ages, but incidence peaks in those aged 30–50 years.

Histological grading of chondrosarcomas can be used to separate these lesions into well-differentiated (grade I), moderately differentiated (grade II) and poorly differentiated (grade III) lesions. Well-differentiated lesions contain small, dark nuclei and scant to absent mitosis.

The tumor matrix is variable, consisting of both chondroid and myxoid components that resemble hyaline cartilage; calcification is common. Moderately differentiated lesions have larger nuclei, greater cellularity, a matrix with a more predominant myxoid component and occasional mitotic bodies [1].

These tumors are two times rare than osteosarcomas in the head and neck. They commonly occur in the site of nasal septum.

They can be peripheric, central or juxtacortical.

The tumor can be induced through irradiation. It can rarely be noted in association with Paget disease, fibrous dysplasia or bony cyst.

Chondroid calcification within tumor matrix is pathognomonic [8].

Chondrogenic neoplasms of mandible and maxilla are more often malignant than benign. Histological differentiation between a chondrosarcoma and a benign chondroma can be very difficult. Chondrogenic benign lesions often recur after excision and they become malignant. This is sustained by the theory according to which the diagnosed lesions as well as chondromas are in fact chondrosarcomas.

The differentiate diagnosis between a benign chondroma and a chondrosarcoma can be analyzed on radiologic criteria depending on the tumor dimensions: chondromas are less than 3 cm while chondrosarcomas are bigger than 3 cm. Maxilla chondrosarcomas have a reserved prognostic [9].

Sarcomas in the nasal fosse are rare tumors, representing less than 1% of the tumors in these regions.

Rhabdomyosarcoma is a rare malignant tumor. Histogenetic, rhabdomyosarcoma is a malignant tumor of the striated muscular tissue. It is supposed to arise from non-differentiated mesenchimal cells.

Rhabdomyosarcomas are divided into four groups based on histopathology: embryonic, botryoid, alveolar, pleomorphic types.

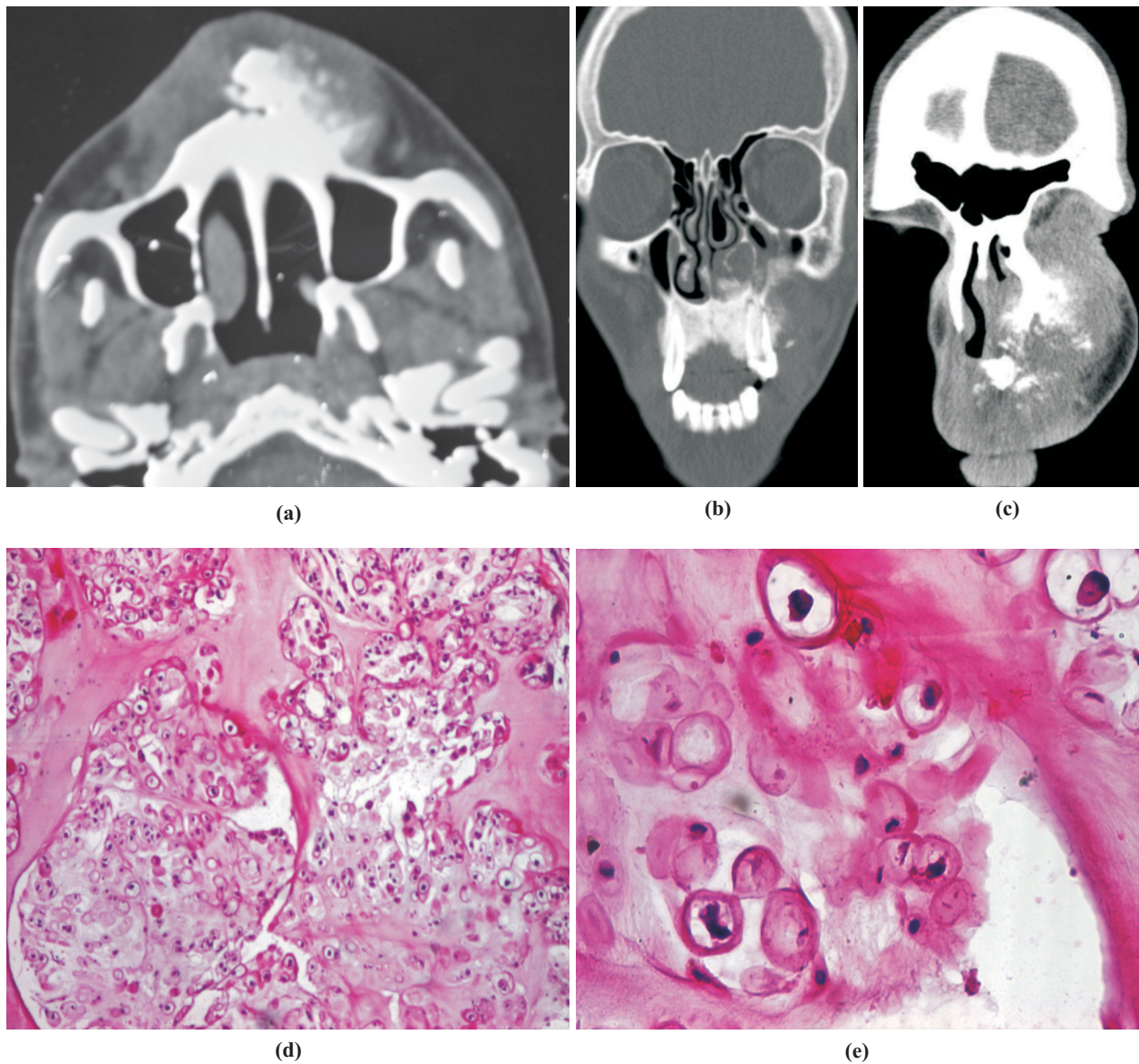


Figure 1 – Maxillary differentiated chondrosarcoma. CT-examination: (a) right maxillary tumor which determines the alteration of the bony structure at the palate level-ostecondensation with (b) alveolar processes 1.1, 1.2, 1.3; (c) the tumor is mainly in the right soft geniene regions, having calcifications in the tumor matrix; (d) neoplastic lobes with dense cells (HE stain, $\times 40$); (e) cellular non-typical aspects (HE stain, $\times 400$)

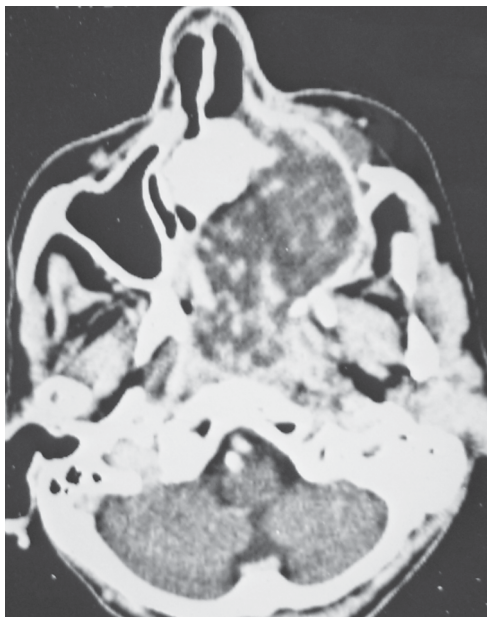

Figure 2 – Poorly differentiated chondrosarcoma. CT-examination. Tumor, non-homogenous, with a chondroid calcification of the matrix, characteristic of chondrosarcoma, at the level of left nasal fossae, left maxillary sinus and ethmoid, with extension into cavum; osteolysis of left intersinuso-nasal wall; osteolysis of nasal septum and invasion into right nasal fossae

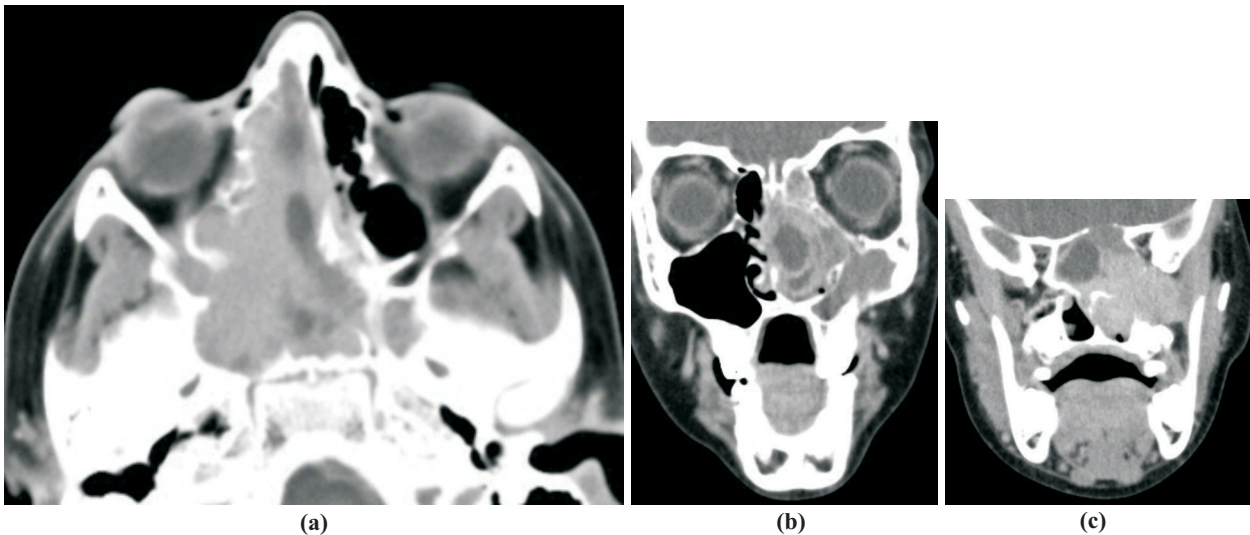

Figure 3 – Pleiomorf rhabdomyosarcoma of nasal cavity. CT-examination revealed a large tumor, non-homogenous, intensely iodophile, with necrosis zones within, at the level of right nasal fossae (a) and ethmoid (b), with extension to the cavum, with osteolysis of intersinuso-nasal wall and invasion of right maxillary sinuses (b) determining osteolysis of the posterior wall and invasion into infratemporal fossae; osteolysis of nasal septum and extension to left nasal fossae (c); osteolysis of cribriform plate and extension in the anterior roof of the base of skull (c), partial osteolysis of the papiraceea lamina, partial osteolysis of the orbit floor (b)

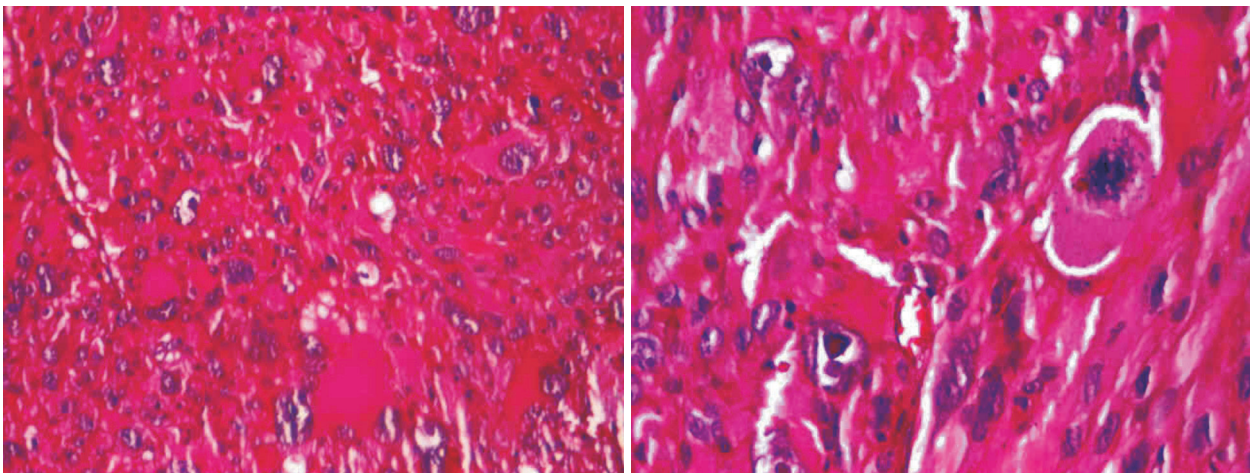


Figure 4 – Pleiomorf rhabdomyosarcoma of nasal cavity: (a) HE stain, $\times 10$; (b) HE stain, $\times 20$

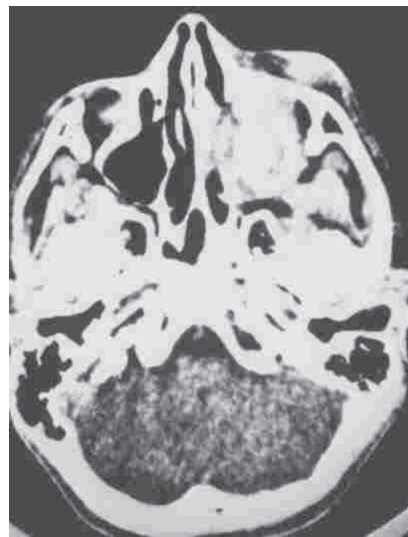
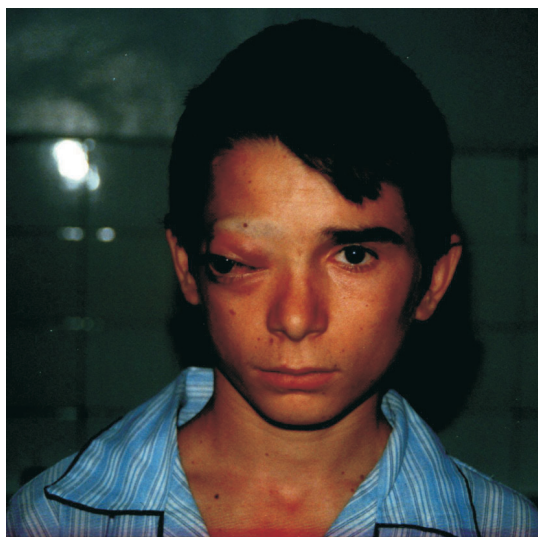

Figure 5 – Angiosarcoma: (a) right exophthalmos: tumor mass in supero-nasal site with displacement of ocular globe downwards and outwards, discreet conjunctival congestion with more dilated and tortuous perilymbic vessels; (b) CT-examination: right ethmoidal tumor extending in the right maxillary sinus determining the lysis of the anterior wall, with the link of papiraceea lamina and invasion of the right orbit

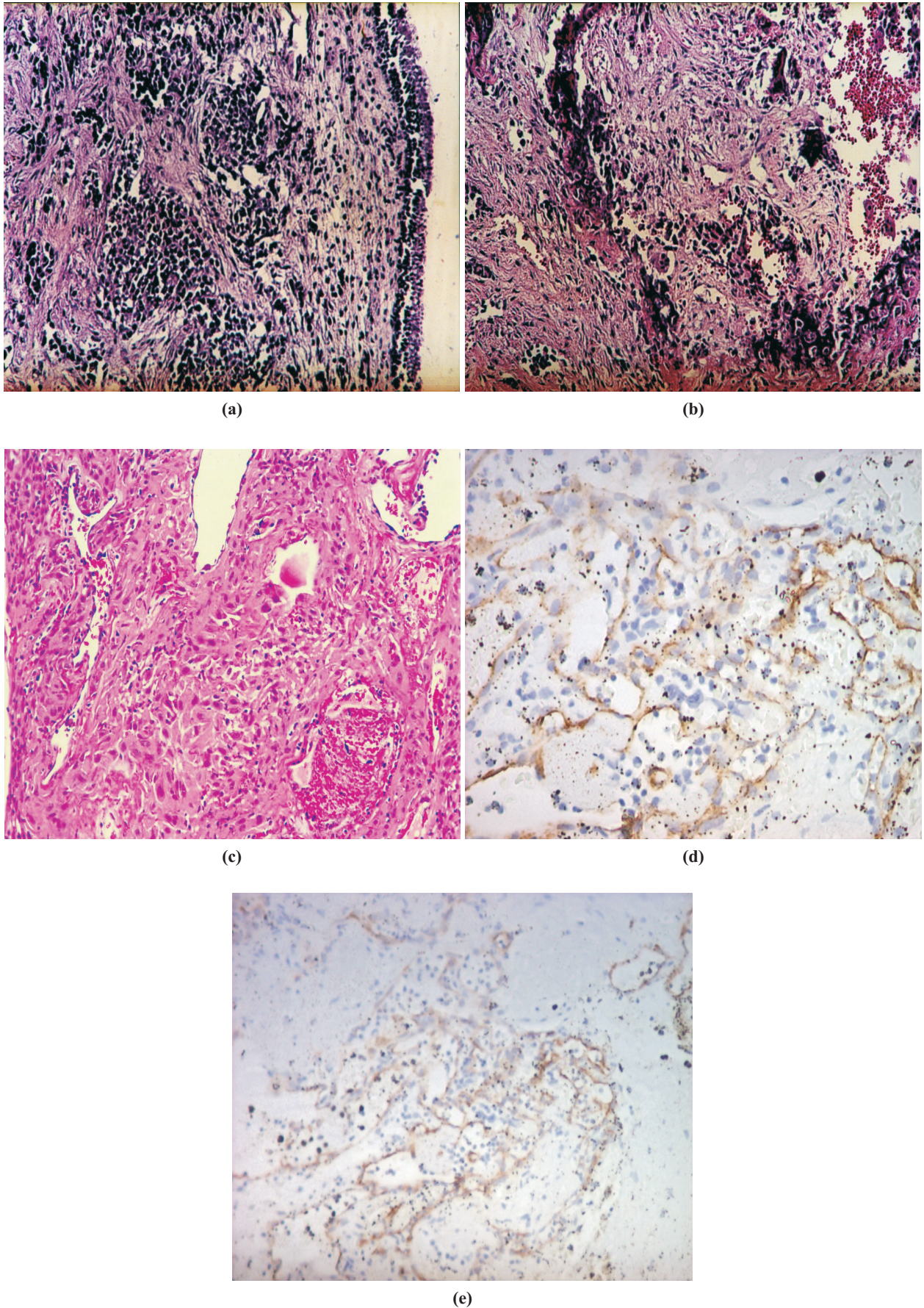
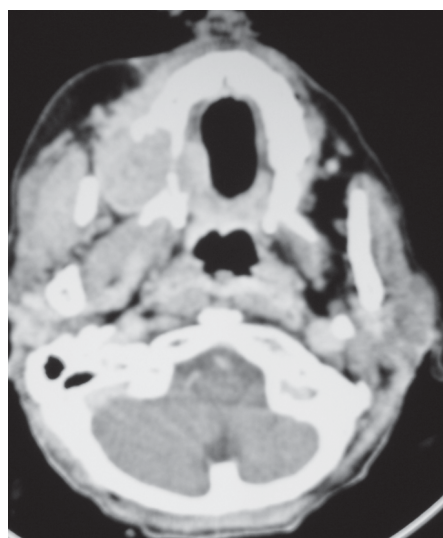
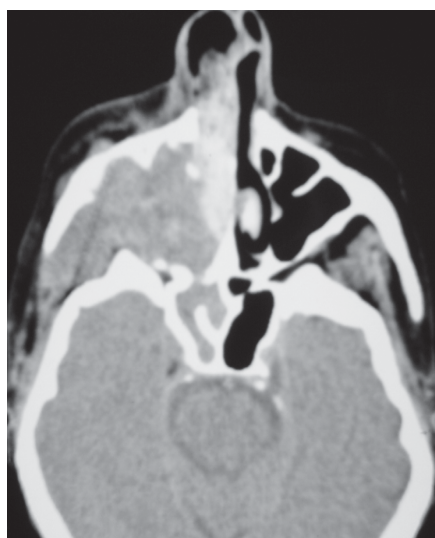


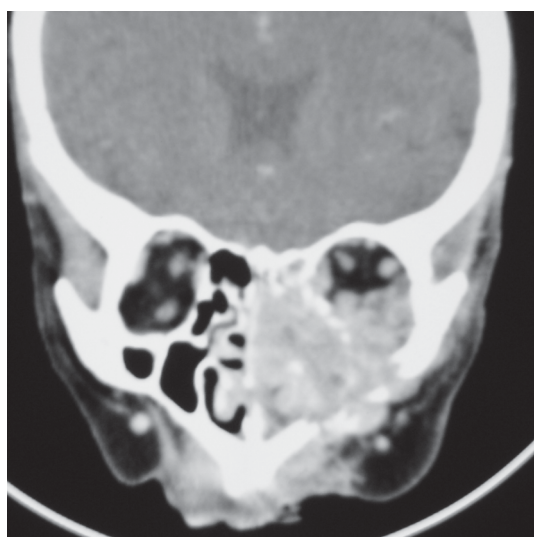
Figure 6 – (a), (b), and (c) Vascular malignant proliferation in the chorion of the sinus mucous membrane angiosarcoma – structure with bony invasion; (d) vessels most of them of slim shape or ramified spaces, separated by atypical endothelia containing few red blood cells; (e) immunostaining for CD31 was positive with high intensity and in large areas in different regions of the tumor, indifferent of neoplastic cell morphology



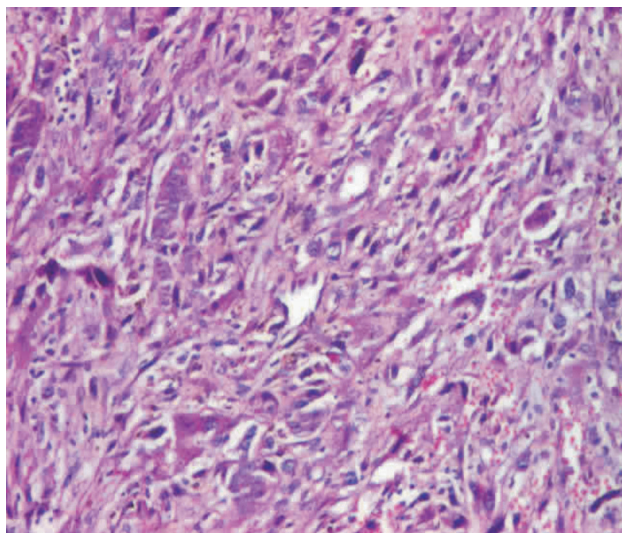
(a)



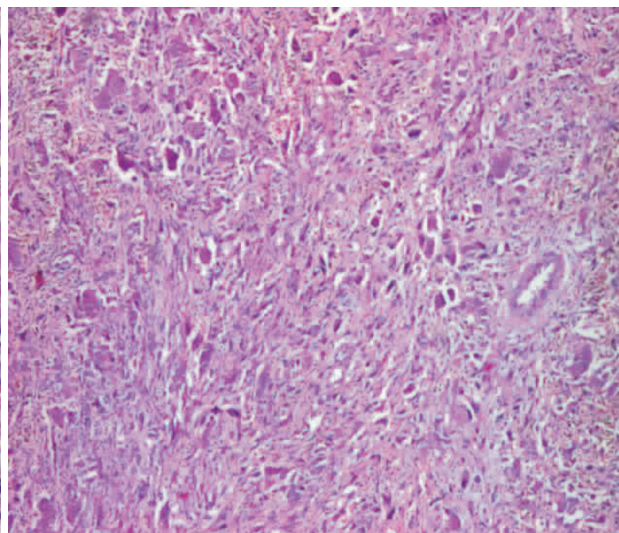
(b)



(c)



(d)



(e)

Figure 7 – Malignant fibrous histiocyctoma with mucoide zones and fuso-cellular zones with bony invasion: (a), (b), and (c). Computed tomography examination. Non-homogenous tissulary tumor, iodophile, with necrosis zone inside, at the level of alveolar processes of right maxilla (a), right maxilla sinus, right ethmoid (b), with lyses of postero-lateral wall and invasion of infratemporal fossae, lysis of anterior wall and invasion of the soft sites of right geniune region, invasion of right orbit through papiraceea lamina, with exophthalmi, invasion of right sfenoidal sinus and invasion of palatine arch (c); (d) HE stain, ob. $\times 4$; (e) HE stain, ob. $\times 10$

Embryonic rhabdomyosarcoma and its botryoid variant account for 75% of head and neck cases and are the two most common histopathologic types among infants and young children. Alveolar rhabdomyosarcoma constitutes 20% of head and neck rhabdomyosarcomas and occurs predominantly in adolescents. Pleomorphic rhabdomyosarcoma is largely a disease of adults [1, 10].

The prognostic of rhabdomyosarcoma is unfavourable, the tumor recurs and metastases rapidly. That is why the American Committee against Cancer and Final results has included it into tumors of 3rd degree [11].

Callender TA *et al.* (1995) specify the factors associated with a reserved prognostic: the mature age, the alveolar type of rhabdomyosarcoma and the tumor size of over 6 cm [12].

We met pleiomorphic rhabdomyosarcoma in the nasal fosse of a 14-year-old patient. Anterior rhinoscopy revealed ulcerous-protrusive tumor occupying in totality the right nasal fosse with involvement of the nasal septum.

The optimum treatment for most rhabdomyosarcomas at the level of head and neck in children includes surgery, chemotherapy and radiotherapy.

There are many studies that appreciate the survival ratio depending on the treatment used. Combining radiotherapy with chemotherapy leads to the best results in local control in cases of rhabdomyosarcomas of nose and paranasal sinuses.

The five years survival rate was of 60% patients treated with chemotherapy and radiotherapy in comparison with only 19% in patients subjected to other treatment forms [10, 12–14].

OMS defines rhabdomyosarcoma as a tumor of high malignancy degree, with various differentiation degrees, with or without transversal striations. Rhabdomyosarcoma is not only characteristic of children but it also occurs at teenagers and young people. Rhabdomyosarcoma is a tumor originating from undifferentiated mesenchymal cells [15].

Angiosarcomas account for less than 1% of all sarcomas. This rare malignancy arises from endothelial cells of either lymphatic or vascular origin. Angiosarcomas typically occur in those aged of 50–70 years, and males are more commonly affected than females, with a 3 : 1 ratio [16, 17].

While most patients are asymptomatic at the time of diagnosis, some have pain or bleeding at the tumor site [1].

We encountered angiosarcoma at a 14-years old patient. Physical examination noted facial asymmetry with bulging in the right naso-genian region and involvement of the internal angle of the orbit, the eyeball being pushed downwards and outwards.

Histopathological study revealed extended areas, which included distinct vascular lumens, rare vascular anastomosis, with irregular diameters and forms, separated by a fibro-collagenous stroma, with frequent areas of hyalinisation (Figure 6, a–c).

Blood vessels endothelia were generally flattened, somehow resembling to normal endothelia, with scarce

big nuclei, hiperchromated, agglomerated and with mitotic activity.

Those aspects suggested the existence of a vascular tumor, which, in spite of the relatively benign aspect of the vascular proliferation, had imprecise limits, with deeply, situated, dissecting vessels, lined with endothelia with nuclear atypia.

In other areas the tumor was almost exclusively formed of a cell proliferation resembling those observed in the poorly differentiated carcinoma.

Neoplastic cells had a round or polygonal shape, large diameter, and strong eosinophilic cytoplasm with round-ovoid, pleiomorphic with frequent atypical mitosis.

Inside the neoplastic proliferation were blood vessels most of them of slim shape or ramified spaces, separated by atypical endothelia containing few red blood cells (Figure 6 d).

Immunostaining for CD31 was positive with high intensity and in large areas in different regions of the tumor, indifferent of neoplastic cell morphology (Figure 6 e).

Nasal-sinusal angiosarcoma is rare (under 1% of all types of sarcomas) and generally appeared in young ages. The characteristics of the case – angiosarcoma had a sinusal localization; it evolved with galloping exophthalmia within two weeks, thus explaining the aggressiveness of the disease.

Malignant fibrous histiocytoma is a rare disease and it is accepted as separate entity, distinct from fibrosarcoma. It is a locally invasive tumor. Its clinical manifestations are similar to those of other malignant maxilla diseases, the pain and tumefaction often present [17] (Figure 7).

American Joint Committee on Cancer (AJCC) and International Union against Cancer (UICC) staging system for soft tissue sarcomas [18]:

Primary tumor

Tx – Primary tumor cannot be assessed.

T0 – No evidence of primary tumor.

T1 – Tumor less than 5 cm in greatest dimension (T1a, superficial; T1b, deep).

T2 – Tumor greater than 5 cm in greatest dimension (T2a, superficial; T2b, deep).

Regional lymph nodes

Nx – Lymph nodes cannot be assessed.

N0 – No lymph nodes metastases.

N1 – Lymph nodes metastases present.

Distant metastases

Mx – Distant metastases cannot be assessed.

Mo – No distant metastases.

M1 – Distant metastases present.

Histopathologic grade

Gx – Grade cannot be assessed.

G1 – Well-differentiated.

G2 – moderately differentiated.

G3 – Poorly differentiated.

G4 – Undifferentiated.

☐ Conclusions

The physical examination has its limits. The sites prone to incorrect clinic diagnosis are the bony structures, soft tissues or great vessels affected by a tumoral formation. In all these cases radioimagistic examination and fine needle aspiration are mandatory to complete the clinical examination.

Clinical expression of facial bone tumors is invariable, not very specific, often neglected by the patient, leading to a late diagnosis.

The different symptoms of these expansive processes, the variety of their forms, the complexity of the affected structure, the rapid evolution highly justify the radioimagistic examination.

The diagnostic role of imaging is essential and often permits the orientation to benignity or, on the contrary, requires biopsy if the image is an aggressive one or of uncertain nature. Advances in diagnostic imaging have contributed substantially to the management of tumors.

The strong collaboration among the physician, imagist and anatomopathologist serves the patient's benefit.

Histopathologic structure of the tumor and its localization are highly important for the prognostic. The radiologist has a great importance in choosing the therapeutic regime.

The comparison of the successive examinations is required to establish the recurrence. Ideally, a CT-examination must be taken within six to twelve weeks following the therapy; the examination will be of reference.

References

- [1] MCMAINS K. C., GOURIN C. G., *Sarcomas of the head and neck*, eMed Pathol, November 2005.
- [2] VOGL V. T., BALZER J., MACK M., STEGER W., *Differential diagnosis in head and neck imaging*, Georg Thieme Verlag, Stuttgart–New York, 1999.
- [3] GALATI LISA, *Malignant tumors of the sinuses*, eMedicine, June 2005.
- [4] FANUCCI E., COSTANZO DI G., SIMIONETTI G., *Sinonasal tumors require team-based approach*, Diagn Imag Eur, June–July 2005, 9–13.
- [5] DUMITRESCU DANIELA, STOICA ZOIA, CONSTANTIN C. et al., *Indicațiile examenului computer tomografic în patologia tumorală a masivului facial*, Craiova Medicală, 2004, 6(3):257–262.
- [6] IDIR A. B. C., DOYON D., Massif facial, cou et rochers. In: DOYON D. CABANIS E. A., IBA-ZIZEN M. T. et al., *IRM, Imagerie par Resonance Magnetique*, 4^{ème} edition, Masson, Paris, 2004, 325–332.
- [7] DUMITRESCU DANIELA, *Ghid imagistic în patologia tumorală a masivului facial*, Ed. Medicală Universitară, Craiova, 2006.
- [8] HARNESBERGER H. R., *Handbook of head and neck imaging*, 2nd edition, Mosby–Year Book Inc., New York, 1995.
- [9] JACKSON T. I., SHAW K., Tumors of the craniofacial skeleton, including jaws. In: *Head & Neck Tumors*, McCarthy G. W., 1999, 3336–3408.
- [10] GERBER M. E., COTTON R. T., Pediatric malignancies. In: *Head & Neck Surgery / Otolaryngology*, Lippincott Williams & Wilkins, 2001.
- [11] MITROI M., ȘURLIN C., COMĂNESCU VIOLETA et al., *Rhabdomyosarcoma of the nasal cavity*, Arch Balkan Med Union, 2003, 38(2):110–115.
- [12] CALLENDER T. A., WEBER R. S., JANAN N. et al., *Rhabdomyosarcoma of the nose and paranasal sinuses in adults and children*, Otolaryngol Head Neck Surg, 1995, 112:252–257.
- [13] CARRAU R. L., MYERS N. E., Neoplasms of the nose and paranasal sinuses. In: *Head & Neck Surgery / Otolaryngology*, Lippincott Williams & Wilkins, 2001.
- [14] HARNESBERGER H. R., HUDGINS P. A., WIGGINS R. H., DAVIDSON H. C., *Tête et cou*, Maloine, Paris, 2004.
- [15] BRISSE H., *Les tumeurs du massif facial – bonnes pratiques d'exploration*, Oncol Ped, janvier 2002.
- [16] FAVIA G., LO MUZIO L., SERPICO R., MAIORANO E., *Angiosarcoma of the head and neck with intra-oral presentation. A clinico-pathological study of four cases*, Oral Oncol, 2002, 38(8):757–762.
- [17] WEISS S. W., GOLDMANN R. J., *Ensinger and Weiss soft tissue tumours*, 4th edition, Mosby, St. Louis, 1994, 917–949.
- [18] International Union against Cancer, *TNM Classification of Malignant Tumors*, 6th edition, Wiley–Liss, New York, 2002.

Mailing address

Daniela Dumitrescu, Assistant Professor, MD, PhD, Department of Radiology and Medical Imagery, University of Medicine and Pharmacy of Craiova, 1 Tabaci Street, 200 642 Craiova, Romania; Phone/Fax +40251–502 263, E-mail: daniela.dumitrescu@gmail.com

Received: August 25th, 2006

Accepted: October 10th, 2006