

# C-erbB2 oncoprotein: prognostic marker in breast cancer

ANCA ROȘIAN, ELENA LAZĂR, ALIS DEMA

Department of Pathology, University of Medicine and Pharmacy "Victor Babeș", Timișoara

## Abstract

**Aim.** The invasive mammary cancer is the most frequent malign tumor of a woman. Among the potential prognostic factors are included the biomarkers which measure or are associated with biological processes involved in the tumoral progression. We study the prognostic importance of the c-erbB2 oncoprotein in the invasive mammary cancer. **Material and methods.** We included in the study 56 female patients suffering of invasive mammary cancer. The tissue fragments were fitted in formol, included to paraffin, commonly colored haematoxylin-eosine(HE); for the determination of the c-erbB2 we used the immunohistochemical method of avidin-biotin (ABC) complex. **Results.** From the total of 56 tumors, 38 (67.9%) presented different degrees of positivity; 18 (32.1%) did not express the oncoprotein c-erbB2. **Conclusions.** The positivity of c-erbB2 oncoprotein was correlated with the size of the tumor; the carcinomas which are not infiltrative ductal, knows as having a better prognostic, were c-erbB2 negative.

**Keywords:** mammary cancer, oncoprotein c-erbB2, immunohistochemistry.

## Introduction

The invasive breast cancer represents a group of malign epithelial tumors characterized by the invasion of adjacent tissues and by an important tendency to give distant metastases.

A large majority of these tumors are derived from the mammary epithelium, more precisely from the cells of the terminal ductal lobular unit (TDLU).

Mammary carcinomas represent a large variety of morphological phenotypes and the specific histopathological types display a particular clinical evolution and prognostic.

The invasive breast cancer represents the most frequent malign tumor in women. The highest risk areas are North America, Europe and Australia, where 6% of the female population develop invasive breast cancer before the age of 75.

The risk of developing breast cancer is low in the underdeveloped regions of Southern Africa, the South of the Sahara region and Eastern Asia, including Japan. In these regions the probability ration foe developing breast cancer under the age 75 in 1:3 in comparison with the developed regions mentioned above.

The prognostic of these pathological entities is very good if diagnosed in the early stages.

A prognostic factor can be defined as any measurement that is used during the diagnostic process or the surgical intervention, and that is associated with survival without signs of illness or general survival, in the absence of systemic adjuvant therapy.

The potential prognostic factors include: *the demographic characteristics* (age, postmenopausal status, ethnic origin), *tumoral characteristics* (axilar lymph nodes status, tumor size hystological subtype), *biomarkers that assess(measure) or are associated with biological processes involved in the tumoural progression* (altered oncogenes, tumoural suppression genes, growth factors, proliferation measurement) and *other factors*. Prognostic factors can be used in foreseeing the natural history of the tumor.

The HER 2/neu 185kd oncoprotein, member of the tyrosinekinase family, is a receptive growth factor, with a 50% similarity to EGFR. Its domain is the surface membrane, the trans-membranous area and the cytoplasm.

The HER-2/neu gene is localized on the 17q21 chromosome and it is translocated into a 185 kd glycoprotein.

The HER-2/neu protein has low expression in the epithelial and myoepithelial cells of the normal mammary tissue. It is over-expressed in comedocarcinoma and in the in situ ductal carcinoma; rarely, low levels can be found in papillary and cribriform tumors in situ.

## Material and methods

In order to determine the c-erbB2 oncoprotein, we utilized the rabbit policlonal anti- human oncoprotein c-erbB2, DAKO, code nr. A485 antibody. This is an affinity antibody, purified by using an immobilized peptide of the c-erbB2 oncoprotein.

We applied ABC Elite methods. The staining procedure consisted of the following phases:

We applied the 6  $\mu$  thick paraffin sections on silan covered slide and we allowed them to dry over night at 37° C.

We prepared three sections of each: for the analysis, for negative control and for the clearly positive tissues, deparaffined and brought up to PBS in the following manner:

- 4  $\times$  5 minutes in xylene;
- 3  $\times$  5 minutes in alcohol 100%;
- 1  $\times$  5 minutes in alcohol 96%;
- 1  $\times$  5 minutes in alcohol 70%;
- 3  $\times$  5 minutes in PBS.

We treated the sections with microwaves, 30 minutes at 80° C.

Methanol-H<sub>2</sub>O<sub>2</sub> treatment for 30 minutes (1 ml H<sub>2</sub>O<sub>2</sub> 30% in 100 ml methanol)

The sections were rinsed repeatedly in PBS.

They were then introduced in PBS 2 × 10 minutes.

Incubation in the first day as follows:

- normal rabbit serum – 20 minutes;
- we drained the normal serum without washing the samples;

- we applied the rabbit policlonal anti- human oncoprotein c-erbB2, DAKO, A485 antibody;

- we incubated over night in moistured enclosure, in the refrigerator, at +4°C.

- we diluted the antibody at 1:200;

Incubation in the second day as follows:

- we drained the primary antibody;

- 2 × 5 minutes washing in Tris 0.5 M/PBS 1:10 solution;

- we applied the secondary biotinilated rabbit antibody, dilution 1:200, for 30 minutes;

- we washed with Tris 0.5 M/PBS 1:10 solution, 2 x 5 minutes;

- we applied the ABC Elite reagent from the Vector kit and incubated for 30 minutes at room temperature;

We washed the sections in Tris 0,5 M/PBS 1:10 solution, 2 x 5 minutes.

We kept the sections in Tris 0,5 M solution for 20 minutes;

We applied the DAB solution:

- application for 6 minutes;

- washing in PBS, 2 x 5 minutes;

- Osmium tetroxyde, 2 minutes;

- we washed in PBS, 2 x 5 minutes;

- haematoxylin-eosin, 3 minutes;

- we washed 3 x in distilled water;

- we introduced the sections in HCl-Alcohol, 4 times, for short time intervals;

- we washed the sections under pouring water for 10 minutes, in order to obtain the blue staining;

- we introduced the sections in alcohol 100% and 3 × in xylene;

- we fixed the sections with Eukit.

Using this staining method, we obtained a strong brown coloration located in the cellular membrane.

## ☞ Results

We performed immunohistochemical determinations of the c-erbB2 oncoprotein for 56 patients with primary mammary carcinoma, treated at the County Hospital in Timișoara.

The average age interval was 37-73 years, with an average of 55.2 years. A number of 16 patients (28.6%) were pre-menopausal, while 40 (71.4%) were post-menopausal.

Fifty (89.3%) of them presented tumors with diameters over 2 cm. In 26 patients (46.4%) the primary tumors were accompanied by the invasion of axillary lymph nodes.

In order to determine the c-erbB2 oncoprotein we applied the immuno-histochemical method that uses the ABC Elite avidin-biotin complex, with the rabbit policlonal anti- human oncoprotein c-erbB2, DAKO antibody.

Using this method on sections fixed in formaldehyde and embedded in paraffin, we obtained a strong brown

coloration located in the cellular membrane and, in some case a weaker coloration of the tumoural cell cytoplasm.

The coloration of the cellular membrane represented the basis for our evaluation of the c-erbB2 immuno-reactivity.

We graded the stain reaction for c-erbB2 on a scale from 0 to 3+; other authors have used this notation, such as: Lynn Hartmann *et al.* from the Mayo Clinic, Rochester, Minnesota (USA) [1].

We noted the negative coloration with “0” and the intense coloration of the cellular membrane, usually associated with a weak or moderate cytoplasmic reactivity, with “3+”.

The sections with weak or focal coloration of the membrane were noted with “1+”, while those with moderate membrane coloration, frequently associated with weak cytoplasmic coloration, with “2+”.

Out of the total number of tumors (56), 38 (67.9%) presented various degrees of positiveness:

- 15 (26.8%) presented 1+ coloration,

- 7 (12.5%) – 2+ and

- 16 (28.6%) – 3+.

A number of 18 tumors (32.1%) had no expression for the c-erbB2 protein (Figures 1-5).

Lynn Hartmann *et al.* performed immuno-histochemical determinations for a number of 354 breast cancers and analyzed the asymptomatic and the general survival. Their findings showed an average asymptomatic survival rate of patients with c-erbB2 3+ less than half lower then the asymptomatic survival for the rest of the patients (2.9 years for c-erbB2 3+, in comparison with 7.1 years for the rest of the study group).

Taking in consideration the much lower survival rates in c-erbB2 3+ patients, the above mentioned authors reached the conclusion that only in these cases the oncoprotein is over-expressed.

We adopted this criterion in the evaluation of the over-expression of c-erbB2 oncoprotein for the 56 cases we studied. We found 28.6% c-erbB2 3+ tumors, a higher percentage then the 20% found by Lynn Hartmann *et al.*

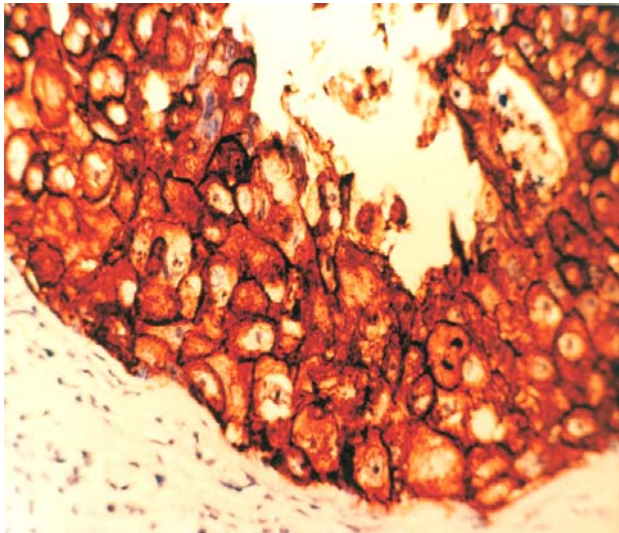
As far as the evaluation of c-erbB2 oncoprotein in primary mammary cancers, the data in literature differ significantly among various research laboratories. These differences appear due to the application of different research methods, the number of studied cases and the manners of interpreting the results.

Literature provides many studies regarding the connections between the c-erbB2 oncoprotein over-expression and the conventional prognostic factors (Table 1).

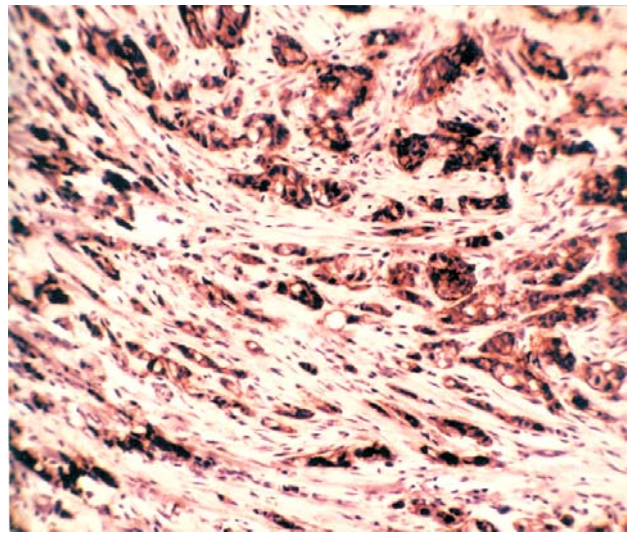
The results of these studies vary significantly; still most of them show concordant data regarding certain prognostic factors.

Our data show no significant correlation between the c-erbB2 positivity and the invasion of axillary lymph nodes (only 6 of 26 patients with positive lymph nodes had positive c-erbB2).

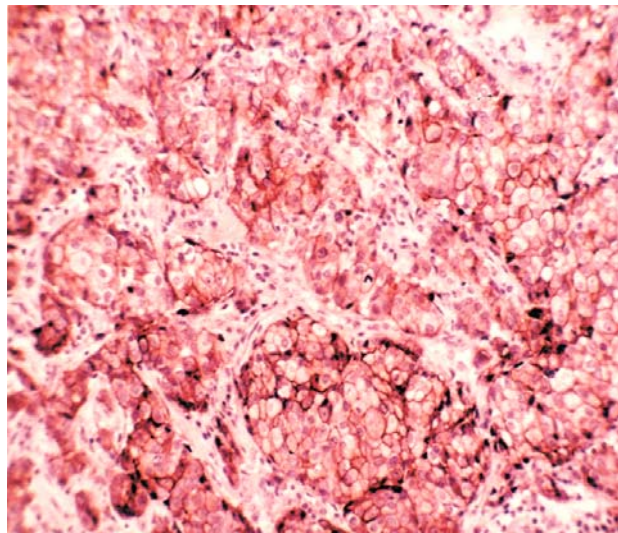
The c-erbB2 expression in our study correlates to some extent with the age of the patients.



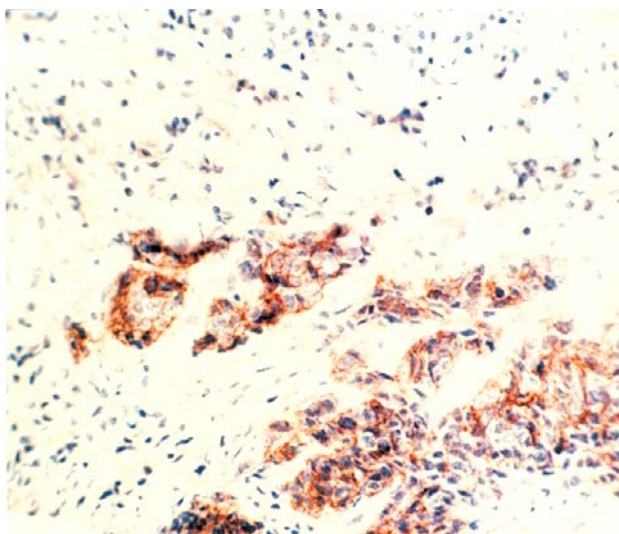
**Figure 1 – Strong staining of the c-erbB2 oncoprotein in a comedocarcinoma (ABC, ×400)**



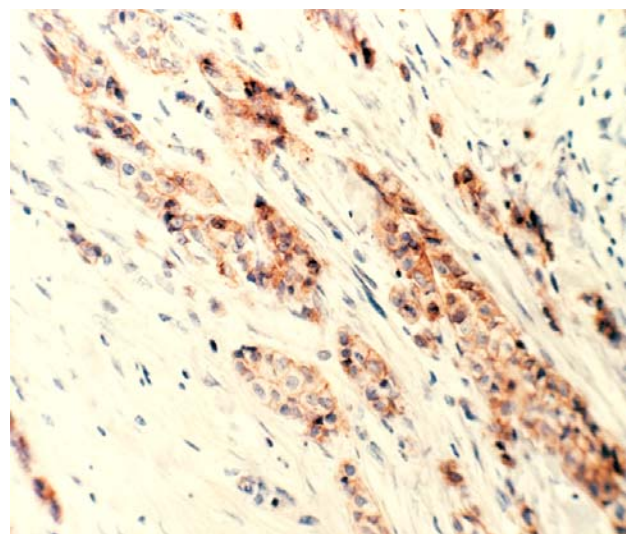
**Figure 2 – Intense expression of c-erbB2 oncoprotein in an infiltrative ductal carcinoma (ABC, ×200)**



**Figure 3 – Intense staining of c-erbB2 in an infiltrative ductal carcinoma associated with G2 medullar carcinoma (ABC, ×400)**



**Figure 4 – Moderate intensity of c-erbB2 in an infiltrative ductal carcinoma (ABC, ×200)**



**Figure 5 – Moderate staining of c-erbB2 in an TIV infiltrative ductal carcinoma (ABC, ×200)**

We found a survival rate of 33% among patients over 50 with positive C-erbB2 and only 21.7% in patients under 50.

We found that the over-expression of c-erbB2 oncoprotein is more frequent in post-menopausal patients (30%) in comparison with pre-menopausal patients (28%), in accordance with the findings of most authors. Also, we found a correlation between the size of the tumor and the over-expression of c-erbB2 oncoprotein:

- 16.7% in tumors under 2 cm diameter;
- 29% in tumors between 2.1–5 cm diameter;
- 37.5% in tumors over 5 cm diameter.

**Table 1 – Correlations between c-erb-B2 oncoprotein and the conventional prognostic factors in our casuistry**

Prognostic factor	No. of cases	c-erb-B2			
		0, 1; 2+		3+	
		No.	%	No.	%
<i>Total</i>	56	40	71.4	16	28.6
<i>The state of lymph nodes</i>					
• positive	26	20	76.9	6	23.1
• negative	30	20	66.7	10	33.3
<i>Age</i>					
37–40	5	3	60	2	40
41–50	18	15	83.3	3	16.7
51–60	11	8	72.7	3	27.3
61–70	19	12	63.2	7	36.8
71–73	3	2	66.7	1	33.3
<i>Size of the tumor [cm]</i>					
< 2	6	5	83.3	1	16.7
2.1–5	31	22	71	9	29
5.1–10	16	10	62.5	6	37.5
>10	3	3	–	–	–
<i>Estrogen Receptor</i>					
ER+	32	24	75	8	25
ER-	24	16	66.7	8	33.3
<i>Menopausal Status</i>					
• pre-menopausal	16	12	75	4	25
• post-menopausal	40	28	70	12	30
<i>Histological Stage</i>					
• G1	23	15	65.2	8	34.8
• G2	20	15	68.8	5	25
• G3	13	10	81.2	3	23.1

We analyzed the relation between the c-erbB2 expression and the histopathological stage of the mammary carcinomas.

Positive c-erbB2 is more frequent in G1 tumours, and decreases in G2 and G3 (34.8%, 25% and 23.1% respectively). Some researchers consider this characteristic insufficient and thus statistically insignificant.

In the studied tumours, we couldn't find a significant relation between the positivity of c-erbB2 oncoprotein and the status of the estrogen receptors (25% of the ER+ cases and 33.3% of the ER- cases were c-erb positive).

Some types of mammary carcinoma, such as the mucinous, tubular, papillary and cribriform carcinomas are known as being associated with a better prognostic then the infiltrative ductal carcinoma; they rarely present a strong over-expression of c-erbB2. This fact is confirmed by our study group, in which none of these presented positive c-erbB2 (Table2).

**Table 2 – Mammary carcinomas in our casuistry; c-erbB2 positive or negative and histological types**

Histological Type	No. of cases	c-erb-B2 +		c-erb-B2 -	
		No.	%	No.	%
Infiltrative ductal carcinoma	25	9	36	16	64
Infiltrative ductal carcinoma associated with other types	10	4	40	6	60
Infiltrative lobular carcinoma	9	2	22.2	7	77.8
Medular carcinoma	6	–	–	6	100
Mucinous carcinoma	1	–	–	1	100
Comedo carcinoma	2	1	50	2	100
Cystic adenoid carcinoma	1	–	–	1	100
<i>Total</i>	56	16	–	40	–

## Discussions

Many published data refer to the connection between the c-erbB2 expression and the conventional prognostic factors. The results of these studies vary significantly but most of them show concordance between certain prognostic factors.

Our data show no correlation between the c-erbB2 positive values and the invasion of axillary lymph nodes (only 6 of 26 patients with positive lymph nodes showed c-erbB2 expression).

Carcinomas with negative axillary lymph nodes have a larger proportion of expressed c-erbB2 – 33.3%, in comparison with a 23.1% for the cases with affected lymph nodes.

Some studies suggest that the c-erbB2 expression in breast cancers with positive lymph nodes represents a relevant prognostic element regarding the asymptomatic survival and the survival in general. As we mentioned above, patients with mammary carcinomas and strong c-erbB2 expression have much lower survival rates.

Most researchers consider that the c-erbB2 expression has no prognostic significance in mammary carcinomas with negative axillary lymph nodes. Lowekin *et al.* [16] show a high frequency of c-erbB2 expression in patients with advanced stages of the illness: 12.4% from the group with negative lymph nodes have oncogene expression, in comparison with 17.4% from the operable group, with positive lymph nodes.

Other extensively studies associations are those between the c-erbB2 status and the histological stage of the tumour, the nuclear stage and the status of hormonal receptors.

In our study group, we more often found c-erbB2 expression in G1 tumours; the percentages then dropped for G2 and G3. Some studies do not show an important positive link between the stage and the c-erbB2 expression [9, 19, 20]; others admit the possibility.

Our study revealed no significant relation between the c-erbB2 positive values and the status of the estrogen receptors. Berg *et al.*, Andane *et al.*, Guerin *et al.* published other studies with the same negative results regarding the hormonal receptors (ER, PR). Others like Berger *et al.*, Slamon *et al.*, May *et al.* show the existence of a weak connection.

Hartmann found a strong relation between the c-erbB2 expression and the lymph nodes invasion, the histological stage and the ER negative value, observing the expression of this oncogene product in a more aggressive biological form of breast cancer.

More recently, the fluorescent in situ hybridization (FISH) proved clearly advantageous in the detection of gene amplification. Both formaldehyde fixed and fresh (frozen) sections and also the cytological specimens are suitable for immuno-histochemistry (IHC) and for FISH. There is an over 90% concordance between the IHC and FISH methods. Their advantages and limits are presented in Table 3.

**Table 3 – Benefits and limits of IHC vs. FISH for HER-2/neu**

IHC	FISH
fixed in formaldehyde or frozen sections fixed in alcohol	fixed in formaldehyde and cytological specimens
easy to perform in any laboratory	needs special preparations
low costs	current costs
rare positive cases can lack amplified genes	more precise
results comparable with current antibodies	can be difficult to interpret; heterogeneousness can be a problem

The concordance between the two methods is higher when membrane immune staining is performed; cytoplasmic staining is not taken into account. The scoring method was performed after the Food and Drug Administration (FDA) Hercept Test Kit was approved. The positive results were scored 3+ for strong and diffuse membrane coloration, with 2+ for a complete membrane coloration of at least 10% of the tumoral cells. Such coloration is usually strong. All other results – under 10% colored tumoral cells or incomplete membrane coloration, were interpreted as negative.

The clinical utility of the HER-2/neu status for patients with invasive breast cancer is:

- as a prediction factor for response to therapy, especially for Doxorubicine;
- for the identification of patients that could respond to monoclonal antibodies therapy.

Muss *et al.* studied the chemotherapeutic response in 1572 female subjects divided into subgroups based on the HER-2 over-expression. They concluded that highest doses of Doxorubicine, Cyclophosphamide and Phluorouracil obtained a significantly better response in HER-2 positive than in HER-2 negative patients.

Tetu and Brisson found that HER-2/neu was not an important predictor for the clinical evolution of untreated patients with positive lymph nodes. Still, it represented an important predictor survival without illness and of the general survival, in subjects treated either with chemotherapy or with hormone therapy.

## ☐ Conclusions

The key diagnostic points of HER-2/neu are:

The over-expression is correlated with the response to Doxorubicine.

The over-expression is correlated with the response to monoclonal antibodies therapy;

There are IHC results comparable with monoclonal

or polyclonal antibodies from DAKO, Ventana (CB11) and Zymed (TAB250).

FISH detects the amplification of the gene, while IHC determines the over-expression of the gene product

FISH and IHC can be performed on paraffin sections and on cytological aspirates.

There are controversies regarding the number of HER-2 false-positive results obtained with IHC.

There is no agreement as to the type of method that should be used;

The use of FISH for HER-2/neu is helpful in cases that are 2+ by IHC or are in the gray area (between 2+ and 3+).

## References

- [1] ADNANE J., GUADRAY P., SIMON M.P. *et al.*, *Proto-oncogene amplification and human breast tumor phenotype*, *Oncogene*, 1989, 4:1389.
- [2] BARNES D.M., LAMMINE G.A., MOLLIS R.R. *et al.*, *An immunohistochemical evaluation of c-erbB2 expression in human breast carcinoma*, *Br J Cancer*, 1988, 58:448.
- [3] BORG A., TANDON A.K., SIGURDSSON H. *et al.*, *HER2/neu amplification predicts poor survival in node-positive breast cancer*, *Cancer Res*, 1990, 50:4332.
- [4] GARCIA I., DIETRICH P., AAPRO M. *et al.*, *Genetic alteration of c-myc, c-erbB2 and c-Ha-ras protooncogenes and clinical associations in human breast carcinomas*, *Cancer Res*, 1989, 49:6675.
- [5] GASPARINI G., DAL FIOR S., POZZA P., BEVILAQUA P., *Correlation of growth fraction by Ki-67 immunohistochemistry with histologic factors and hormone receptors in operable breast carcinoma*, *Breast Cancer Res Treat*, 1989, 14:329-336.
- [6] GUERIN M., GABILLOT M., MATHIEU M.C. *et al.*, *Structure and expression of c-erbB2 and EGFR receptor genes in inflammatory and non-inflammatory breast cancer: prognostic significance*, *Int J Cancer*, 1989, 43:201.
- [7] GUSTERSON B.A., GOLBER R.D., GOLDBIRSCH A. *et al.*, *Prognostic importance of c-erbB2 expression in breast cancer*, *J Clin Oncol*, 1992, 10:1049-1056.
- [8] GULLIK J.W., LOWE S.B., WRIGHT C. *et al.*, *C-erbB2 protein overexpression in breast cancer is a risk factor in patients with involved and uninvolved nodes*, *Br J Cancer*, 1991, 63:434-438.
- [9] HARTMANN L., INGLE J.N., WOLD L.E. *et al.*, *Prognostic value of c-erbB2 overexpression in axillary lymph node positive breast cancer*, *Cancer*, 1994, 74(11):2956-2962.
- [10] LOVEKIN C., ELLIS J.O., LOCKER A. *et al.*, *C-erbB2 oncoprotein expression in primary and advanced breast cancer*, *Br J Cancer*, 1991, 63:439.
- [11] MAY E., MOURIESSE M., MAY-LEVIN F. *et al.*, *A new approach allowing an early prognosis in breast cancer; a ratio of estrogen receptor(ER) ligand binding activity to the ER-specific mRNA level*, *Oncogene*, 1989, 4:1037.
- [12] PARKES H.C., LILLYCROP K., HOWELL A., CRAIG R.K., *C-erbB2 mRNA expression in human breast tumors: comparison with c-erbB2 DNA amplification and correlation with prognosis*, *Br J Cancer*, 1990, 61:39.
- [13] PAUL P., ROSEN M.D., MARTIN L. *et al.*, *Immunohistochemical detection of HER2/neu in patients with axillary lymph nodes negative breast carcinoma*, *Cancer*, 1995, 75(6):1320-1325.
- [14] SESHARDI R., FIRGAIRA F.A., HORSFALL D.J. *et al.*, *Clinical significance of HER2/neu oncogene amplifier in primary breast cancer*, *J Clin Oncol*, 1993, 11:1936-1946.
- [15] PERREN T.J., *C-erbB2 oncogene as a prognostic marker in breast cancer*, *Br J Cancer*, 1991, 63:328-332.
- [16] RAVDIN P.M., CHAMNESS G.C., *The c-erbB2 proto-oncogene as a prognostic and predictive marker in breast cancer: a paradigm for the development of other macromolecule markers*, *Gene*, 2005 (in press).
- [17] RO Y.J., EL NAGGAR A., RO J. *et al.*, *c-erbB2 amplification in node negative human breast cancer*, *Cancer Res*, 1989, 49:6941.

- [18] ROSEN P.P., MARTIN L., CRISPINITA L. et al., *p53 in node negative breast carcinoma: an immunohistochemical study of epidemiologic risk factors, histologic features and prognosis*, J Clin Oncol, 1995, 13(4):821-830.
- [19] Slamon D.J., Godolphin W., Jones L.A. et al., *Studies of the HER2/neu proto-oncogene in human breast and ovarian cancer*, Science, 1989, 244:707.
- [20] TETU B., BRISSON J., *Prognostic significance of HER2/neu oncoprotein expression in node-positive breast cancer: the influence of the pattern of immunostaining and adjuvant therapy*, Cancer, 1994, 73:2359.
- [21] TOIKKANEN S., KUJARI H., *Pure and mixed mucinous carcinomas of the breast: a clinicopathologic analysis of 61 cases with long term follow-up*, Hum Pathol, 1989, 20:758-764.
- [22] WRIGHT C., ANGUS B., NICHOLSON S. et al., *Expression of c-erbB2 oncoprotein: a prognostic indicator in human breast cancer*, Cancer Res, 1989, 49:2087-2090.

**Mailing address**

Roşian Anca, Assistant Professor, M. D., Ph. D., Department of Pathology, "Victor Babeş" University of Medicine and Pharmacy, Square Eftimie Murgu no. 2, 300041 Timișoara, Romania; Phone / Fax +40256–200 256

*Received: 25 September, 2005*

*Accepted: 20 October, 2005*